

Evaluation of Corrective Rhinoplasty in Cleft Lip Nasal Deformity

Ahmed Maged Elmofty, Ahmed Taha Sayed,

Ahmed Mohammed Abd El Fattah Hanno

Department of Plastic, Reconstructive and Burn Surgery, Faculty of Medicine, Al-Azhar University

Corresponding author: Ahmed Mohammed Abd El Fattah Hanno,

Mobile: 01093756025, email: ahmedhanno@yahoo.com

ABSTRACT

Background: Cleft lip nasal deformities are challenging problems in all aspects and there are debates about timing, approaches, techniques as well as types of the used grafts.

Objective: Evaluation of the results of corrective rhinoplasty in post cleft lip nasal deformity at Al-Azhar University Hospitals (Al-Hussien and Said Galal Hospitals).

Patients and Methods: This is a prospective clinical study which included thirty patients having post cleft lip nasal deformity whom underwent corrective rhinoplasty for cleft lip nasal deformity. These patients were managed at Al-Azhar University Hospitals (Al-Hussien and Said Galal Hospitals) during the period from May 2017 to January 2019. **Results:** The vast majority of the operated upon patients had an obvious degree of satisfaction after 6 months to 12 months of postoperative follow up.

Conclusion: Autologous cartilaginous grafts are the most suitable type of nasal grafts, and costal cartilage graft is the most superior between them. Further studies are needed to justify if primary rhinoplasty is beneficial or it disturbs the nasal symmetry and leave scared tissues for a potential future intervention.

Keywords: Cleft nasal deformity, cleft lip.

INTRODUCTION

Primary cleft lip nasal deformity is defined as nasal distortion caused by a cleft lip. Features of unilateral and bilateral cleft lip nasal deformity differ because of asymmetry, but the anatomical basis is very similar ⁽¹⁾. Cleft lip nasal deformity is present in all forms of cleft lip with or without cleft palate ⁽²⁾.

The degree of nasal deformity parallels the severity of labial clefting; complete, which is greater than incomplete which is greater than the lesser form. Even in a mini microform cleft lip, there is a slight nasal abnormality that often becomes more obvious with time ⁽¹⁾. Nasal deformity is also worse whenever there is a cleft of the alveolus and secondary palate ⁽³⁾.

In primary unilateral cleft lip nasal deformity, the wide piriform aperture and maxillary hypoplasia displace the cleft-side alar base laterally, inferiorly, and posteriorly. The anterior nasal spine, antero-caudal septum, and base of the columella tilt toward the noncleft side. The lower lateral cartilage is splayed across the cleft and also dislocated from the ipsilateral upper lateral cartilage. Framework of the nose is hypoplastic compared with the noncleft side ⁽⁴⁾.

Secondary cleft lip nasal deformity is defined as those distortions that persist despite primary operative maneuvers ⁽⁵⁾.

Residual deformity is a result of "failure to correct," undercorrection, or relapse. Iatrogenic deformities include expected (although undesirable) changes and the unintended results of technical error. For example, as the alar base is moved medially in closure of the nasal floor, the lower lateral cartilage bends into recurvatum and a vestibular web often appears. The alar base may be malpositioned and nasal tip cartilages may be damaged. Scarring can result in a stenotic "micronostril" ⁽⁶⁾.

The cleft nasal deformity is a common problem that has both consistent and reliable findings,

as well as distinctive nuances. The deformed soft tissue and skeletal foundation are further complicated by the long-term effects of anatomic growth and surgical scarring⁽⁷⁾.

AIM OF THE WORK

Evaluation of the results of corrective rhinoplasty in post cleft lip nasal deformity at Al-Azhar University Hospitals (Al-Hussien and Said Galal Hospitals).

PATIENTS AND METHODS

This is a prospective clinical study which include thirty patients having post cleft lip nasal deformity whom underwent corrective rhinoplasty for cleft lip nasal deformity. These patients were managed at Al-Azhar University Hospitals (Al-Hussien and Said Galal Hospitals) during the period from May 2017 to January 2019.

The study was approved by the Ethics Board of Al-Azhar University and an informed written consent was taken from each participant in the study.

Inclusion criteria: All patients included in this study had the following criteria: 1^{ry} or 2^{ndry} cleft lip nasal deformity. One stage or multi stages procedures for nasal deformity correction. Male or female. Non syndromic. Unilateral or bilateral cleft lip.

Exclusion criteria: Patient and parent with unrealistic expectations. Syndromic patients or associated with other facial anomalies. Any comorbidities that affect surgery or anesthesia

Preoperative assessment

Clinical parameters: In the preoperative evaluation of secondary cleft lip nasal deformity we took a complete, accurate history and reviewed all prior operative notes. Assessment for cleft rhinoplasty followed standard and systematic nasofacial analysis.

As with an aesthetic rhinoplasty, the evaluation took into account overall facial harmony including the proportion and symmetry of all structures from the forehead to the chin. Special attention focused on the midface, which is often relatively hypoplastic and retrognathic. The thickness and quality of the nasal skin was examined. For each patient, four photographs were taken (full face frontal view, submental oblique view, right profile view, and left profile view). We use anthropometric clinical measurements to assess symmetry by alaris to alaris (al-al). Projection was assessed by subnasale to pronasale (sn-prn), with the ratio of sn-c to sn-prn ideally close to 40 percent. Tip rotation was assessed by measuring the columella-labial angle (**Fig. 1**).

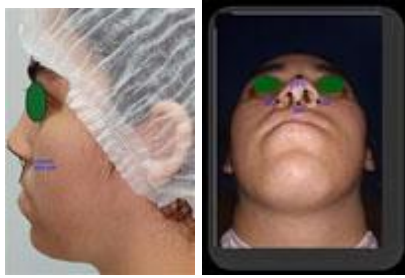

Fig. (1): Anthropometric measurements

Functional Assessment: Intranasal examination often reveals septal deviation, turbinate hypertrophy, vestibular webbing, and external or internal valve collapse. In our cases we used the Cottle maneuver and “adhesive breathing strip test” was used in case of uncover clinically significant nasal obstruction caused by internal valve collapse for children old enough to self-report (i.e., older than 8 years).

ENT consultation to deal with turbinate pathology and any other functional deficit.

Pediatric consultation to discover any other congenital anomalies.

Preoperative investigations: Laboratory: Complete blood count. Coagulation profile. Liver and renal function.

Radiology: CT was done for 20 patient.

The patients were admitted to the hospital on the day of operation fasting about 6 hours preoperative.

Anesthesia: General anesthesia. A conformed oral endotracheal tube fixed on the chin in the midline. A throat pack was carefully placed in the posterior oropharynx to prevent inadvertent ingestion of blood during surgery, which helps to prevent postoperative nausea and vomiting. A low mean arterial pressure was maintained during surgery to maintain a dry surgical field.

Antibiotic prophylaxis Prophylactic dose of 3rd generation cephalosporin was given I.V. upon induction of anesthesia.

Positioning: The patient was placed in the supine position with the neck slightly extended using a small shoulder roll. The operating table is tilted into a slight reverse Trendelenburg position (**Under anesthesiologist’s supervision**) (**Fig.2**)

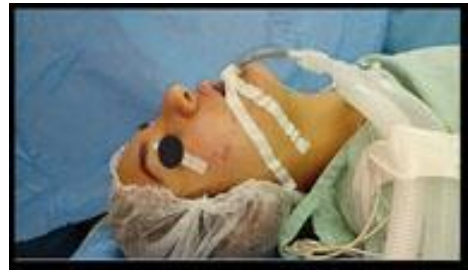

Fig. (2): Patient position (slight extended neck)

Prepping and draping: The nasal vestibules were prepared by swabbing the entire nostril with betadine solution. Sterile tapes were placed over the face and the closed eyelids.

Local hemostasis: A solution of 1% lidocaine with 1:100,000 epinephrine was infiltrated locally in dorsum, septum, tip, alar base, side wall (about 20-30 cc).

Operative technique

Closed rhinoplasty: Closed complete release was done for ipsilateral hypoplastic LLC through lip incision during lip repair with release of malinsertion of orbicularis muscle (**Fig.3**)

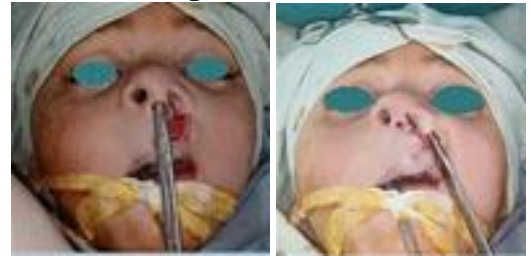

Fig. (3): MAC COMB dissection

Open rhinoplasty

Septal cartilage harvesting: We preferred to harvesting it by open approach because of the improved visualization. Firstly Separation of suspensory ligament between medial crura, then perichondrium was incised posterior to the anterior septal angle to expose the underlying cartilage. Bilateral submucoperichondrial tunnels were dissected deep to the upper lateral cartilages and a scalpel was used to separate the upper lateral cartilages from the dorsal septum. (**Fig. 4**)

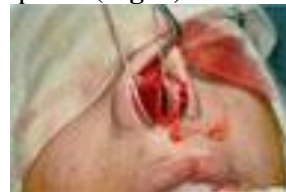

Fig. (4): Exposure of septum

The submucoperichondrial dissection was continued bilaterally to release the entire quadrangular cartilage, then harvesting was done (septal blade was preferred) with adequate L-strut must be preserved (**Fig. 5-7**).

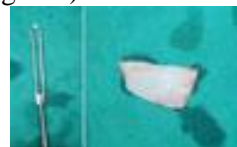

Fig. (5): Quadrangular septum harvested by knife

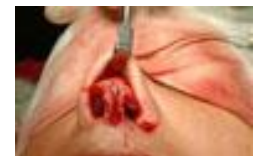

Fig. (6): LLC augmentation.

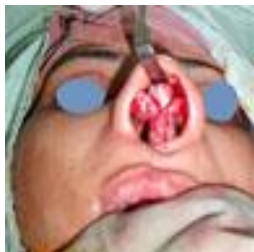

Fig. (7): Onlay graft

Cartilage harvesting (Fig. 8-9)

Other Techniques: Columellar lengthening: By bipediced nasal floor flap during alveolar cleft repair (Fig. 10) or by V to Y technique (Fig. 11).

Hemostasis and closure:

After meticulous hemostasis had been obtained, the skin envelope was redraped and closed (Fig. 12)

DRESSING and SLPLINT.

Nasal back by Vaseline gauze (Fig. 13).

Nasal splint

Internal nasal splint: To prevent septal hematoma on Vaseline gauze to avoid skin necrosis (Fig. 14)

External nasal splint: We used Steri strep for fixation of graft and preventing hematoma and internal nasal splint using Vaseline gauze and external nasal splint using metal or cast splint (Fig. 15).

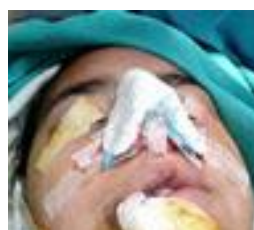

Fig. (14): Internal nasal splint

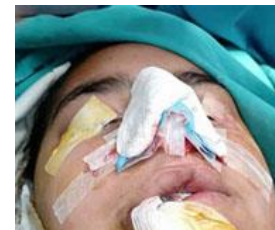

Fig. (15): External nasal splint

Postoperative care: During the first 48 to 72 hours postoperative, prophylactic antibiotic (e.g., amoxicillin/clavulanic acid vial iv, twice times a day for 1 week), and cooling (ice pack with eye care), with analgesia (ibuprofen 600 mg on demand). The patient was instructed to keep the head of the bed elevated at 45 degrees. Nasal tamponades were removed 2 day postoperatively. After one week, the dressing was removed and the patient resumed normal activities. During the first 2 weeks postoperatively nasal congestion was treated with the use of normal saline nasal spray and oxymetazoline nasal sprays (Afrin). The patient was encouraged to breathe through the mouth if there was difficulty with air passage through the intranasal splints. The sutures and nasal splints were removed at the initial visit on postoperative day 5 to 7. The nose might appear swollen and turned up and the tip might feel numb, but the patient was reassured that both were expected and that both would resolve with time. Normal sensation usually returned within 3 to 6 months

Postoperative follow up: All patients were evaluated postoperatively by: postoperative photo (four photographs were taken; full face frontal view, submental oblique view, right profile view, and left profile view). Clinical measurement (al-al)-(columella-labial angle)-(columellar length).

All was done at: Immediate postoperatively. Three months postoperatively. Six months postoperatively. Twelve month postoperatively.

Patient satisfaction: In order to measure outcomes such as patient satisfaction and quality of life we used *rhinoplasty outcome evaluation (ROE)*.

The goal of these instruments is to provide a starting point for individual facial plastic surgeons to evaluate the outcomes of these common procedures in a quantitative fashion. This will allow further assessment of patient satisfaction as well as provide the means by which new or innovative procedures can be compared with more traditional approaches. Scoring of each of these instruments is straightforward and designed to allow the surgeon to easily compare pre- and postoperative measurements. Each of the six items is scored on a 0–4 scale, with 0 representing the most negative response and 4 representing the most positive response. Dividing the total score for each instrument by 24 and multiplying by 100 yields the scaled instrument score. This range is 0–100, with 0 representing the least patient satisfaction and 100 representing the most patient satisfaction⁽⁸⁾ (Fig.16).

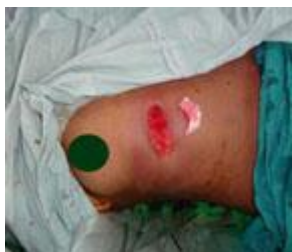

Fig. (8): Harvesting of costal cartilage

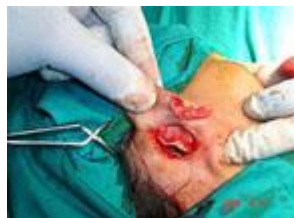

Fig. (9): Harvesting of auricular cartilage

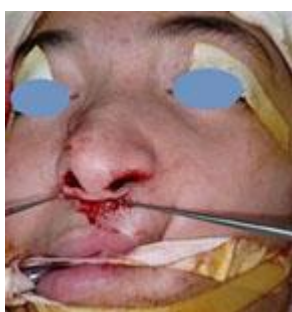

Fig. (10): Lengthening by bipediced nasal floor flap

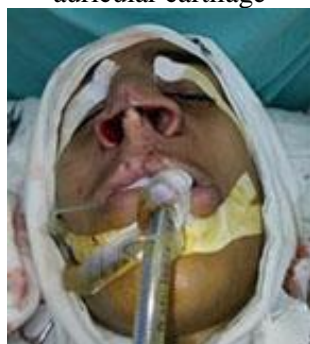

Fig. (11): Lengthening by v-y closure of flap



Fig. (12): Skin closure

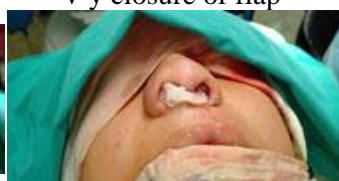

Fig. (13): Nasal back

Rhinoplasty Outcomes Evaluation (ROE)

This questionnaire is designed to assist your surgeon in determining the best patient outcomes following rhinoplasty surgery. Your comments are confidential and may be used to refine surgical procedures for future patients. Please circle the number that best characterizes your current opinion regarding the following questions:

1. How well do you like the appearance of your nose?
 Not at all (0) Somewhat (1) Moderately (2) Very much (3) Completely (4)

2. How well are you able to breathe through your nose?
 Not at all (0) Somewhat (1) Moderately (2) Very much (3) Completely (4)

3. How much do you feel your friends and loved ones like your nose?
 Not at all (0) Somewhat (1) Moderately (2) Very much (3) Completely (4)

4. Do you think your current nasal appearance limits your social or professional activities?
 Always (0) Usually (1) Sometimes (2) Rarely (3) Never (4)

5. How confident are you that your nasal appearance is the best that it can be?
 Not at all (0) Somewhat (1) Moderately (2) Very much (3) Completely (4)

6. Would you like to surgically alter the appearance or function of your nose?
 Definitely (0) Most likely (1) Possibly (2) Probably not (3) No (4)

Fig. (16): Rhinoplasty outcome evaluation (ROE) ⁽⁸⁾.

Statistical analysis

Data were analyzed using Statistical Program for Social Science (SPSS) version 15.0. Quantitative data were expressed as mean± standard deviation (SD). Qualitative data were expressed as frequency and percentage.

The following tests were done:

Independent-samples t-test of significance: was used when comparing between two means.

Probability (P-value)

- P-value < 0.05 was considered significant.
- P-value < 0.001 was considered as highly significant.
- P-value > 0.05 was considered insignificant.

RESULTS

Table (1): Classification of studied patients according to side affection.

		Unilateral	Bilateral
Studied patients (N = 30)	N	24	6
	%	80%	20%

Table (2): Classification of studied patients according to relation to lip surgery.

According to relation to lip surgery		Primary	Secondary	Tertiary
Studied patients (N = 30)	N	10	18	2
	%	33.3%	60%	6.7%

Table (3): Classification according to intraoperative technique (N = 20 patients).

Combined procedures	NO	%	Single procedures	NO	%
Clum. lengthening-tip definition-alar augmentation-septoplasty	7	35%	Clumellar lengthening (soft tissue)	2	10%
Clum. lengthening-tip definition-spreader graft for internal nasal valve-septoplasty	2	10%	Alar transposition	1	5%
Clum. lengthening-tip definition-dorsal hum by hm resection	2	10%	Nasal floor	1	5%
Clum. lengthening-tip definition-dorsal augmentation	5	25%	-	-	-

Table (4): Classification according to nature of graft.

(N = 16)	Autologous graft	Alloplastic (medpore)
Number	13	3
Percentage	81.25%	18.75%

Table (5): Patient classification according to donor of autologous graft (N = 13).

(N = 13)	Costal cartilages	Septal cartilage	Auricular cartilage	Combined (Septal –auricular cartilage)
NO	7	4	1	1
%	53.8%	30.8%	7.7%	7.7%

Table (6): Classification of patient according to main pathological deformity

(N = 20)	Number of cases	percentage
Internal nasal valve collapse	2	10%
Alar collapse	8	40%
Septal deviation	8	40%
The nasal dorsum saddle	5	25%
The nasal dorsum humpy	2	10%
Short columella	18	90%
Poor tip definition	16	80%
Nasal Floor	1	5%

Table (7): Subjective satisfaction distribution among the operated patients.

	Good	Fair	Poor
No. of patients	13	15	2
Percentage	43.3%	50%	6.7%

Table (8): The type of graft used and Satisfaction

Type of graft	No. Of patients	Satisfaction degree					
		GOOD		FAIR		POOR	
		N	P	N	P	N	P
Costal cartilage:	7	6	85.7%	1	14.3%	0	0%
Septal cartilage:	4	2	50%	1	25%	1	25%
Auricular cartilage:	2	0	0%	0	0%	2	100%

Table (9): Subjective satisfaction distribution among the patients by the gender of the patient.

Gender	NO. of patients	Degree of satisfaction					
		Good		Fair		Poor	
		N.	%	N.	%	N.	%
Male	11	8	72.7%	2	18.2%	1	9.1%
Female	9	3	33.3%	4	44.4%	1	11.1%

Table (10): Subjective satisfaction distribution among the patients by stage of surgery

Stage of surgery	NO. of patients	Degree of satisfaction					
		Good		Fair		Poor	
		N.	%	N.	%	N.	%
Primary	10	6	60%	4	40%	0	0%
Secondary	18	6	33.3%	10	55.6%	2	11.1%
Tertiary	2	0	0%	0	0%	2	100%

Table (11): Subjective satisfaction distribution in columellar lengthening among the patients by nature of strut

Nature of material	NO. of patients (16)	Degree of satisfaction					
		Good		Fair		Poor	
		N.	%	N.	%	N.	%
Autologous	13	7	58.3%	5	30.8%	1	8.3%
Alloplastic	3	2	66.7%	0	0%	1	33.3%

Table (12): comparison between preoperative and postoperative anthropometric measurements in studied patients.

Variables		Pre (N =20)	Post (N = 20)	P-value
al-al	Mean	37.1	32.8	< 0.001*
	±SD	2.2	1.9	
sn-C`	Mean	6.9	8.2	0.002**
	±SD	1.4	1.6	
Naso-labial angle	Mean	80.0	88.8	< 0.001*
	±SD	10.3	4.3	

*: p-value < 0.001 is considered highly significant, **: p-value < 0.05 is considered significant.

Table (12): Description of complication in studied patients.

Variables	Studied patients (N = 30)
Surgical site infection	1 (3.3%)
Wound dehiscence	1 (3.3%)
Skin necrosis	1 (3.3%)
Contact dermatitis	3 (10%)

SELECTED CASES

CASE (1)



Fig. (17): Frontal, basal and lateral preoperative views



Fig. (18): Frontal, basal and lateral views 6 months postoperative

CASE (2)

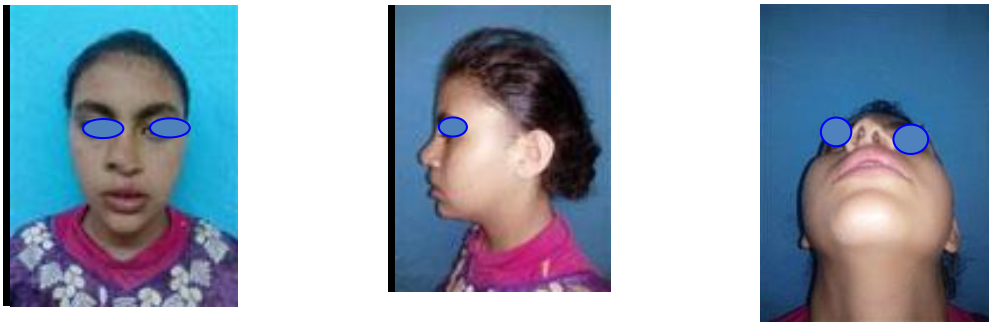

Fig. (19): Frontal, lateral and basal preoperative views




Fig. (20): Frontal, lateral and basal views postoperative

CASE (3)

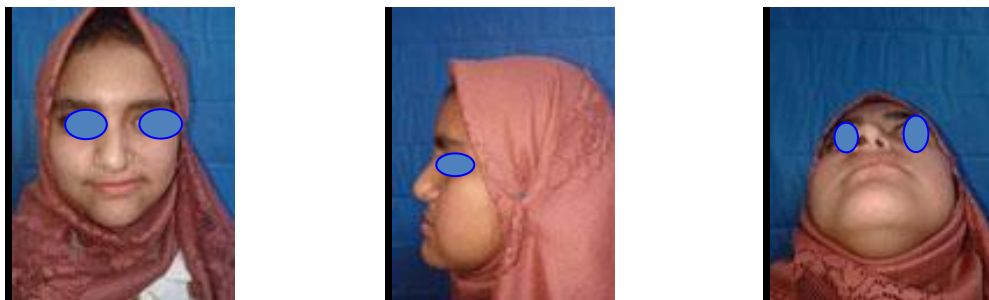

Fig. (21): Frontal, lateral and basal preoperative views

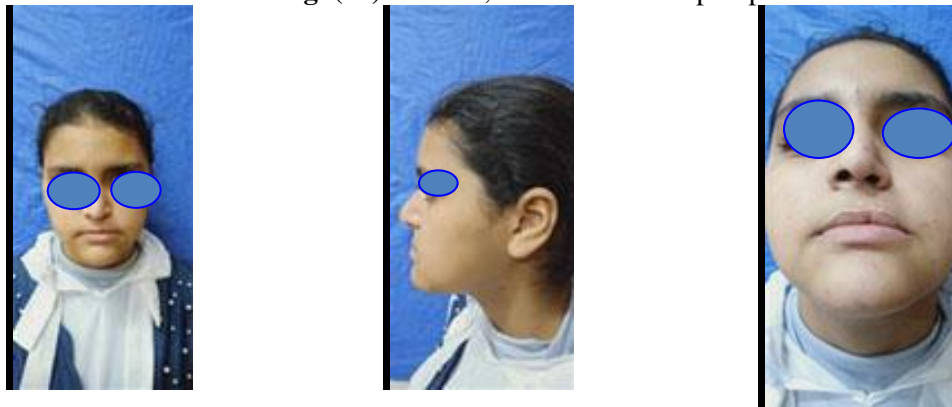


Fig. (22): Frontal, lateral and basal views 6 months postoperative

DISCUSSION

The nose is one of the most visible organs on the face and its appearance contributes enormously to facial aesthetics. Nasal deformity associated with cleft lip has been viewed as one of the most challenging reconstructive problems in rhinoplasty. The complexity of cleft lip rhinoplasty is demonstrated by the abundance of technique that is available for its correction. Yet, there is no conclusively superior technique among those that were described to date. Rhinoplasty for the patient with cleft nasal deformity is one of the most difficult surgeries to plan, execute, and manage. The deformed soft tissue and skeletal foundation are further complicated by the long-term effects of anatomic growth and surgical scarring⁽⁷⁾.

The goals of primary rhinoplasty are to restore symmetry and reposition the nasal structures such that further growth will not exacerbate deformities. Intermediate rhinoplasty, although not always indicated, can be utilized before school age to help achieve greater symmetry and help alleviate future growth deformities. Secondary rhinoplasty is best approached after nasal growth has concluded and done via an open technique to fully visualize the nasal structure. Cleft nasal deformity is a complicated problem that should be addressed during multiple stages of the patient's life⁽⁷⁾.

This current study aimed at exploration the different surgical options and times of intervention to achieve symmetry and satisfaction in cases of cleft lip nasal deformity, evaluate of their esthetic and functional results and demonstrate the subjective satisfaction for each case.

Early (primary) nasal correction at the time of cleft labial repair provides a cartilaginous foundation that minimizes subsequent deformity but does not obviate the likely need for "revisions"⁽⁹⁾. Overcorrecting the cleft-side nostril and its alar cartilage is believed to produce better symmetry compensating for possible relapse during the postoperative period. The overcorrection can be achieved using the Tajima method of rhinoplasty during the primary correction for unilateral cleft liponasal deformity. Relapse of nasal deformities can be reduced using external or internal nasal splinting⁽⁹⁾. We have been using these techniques and experienced superb results. However, long-term evaluation has yet to be performed to document the outcomes. If excellent results are achieved initially, secondary reconstruction will not be necessary.

In this study, thirty patients with post cleft lip nasal deformity were included. 30% was primary, which achieved better symmetry, which allowed nose to grow in a symmetric fashion. This concept agree with Sykes (2010)⁽¹⁰⁾.

The most annoying found deformities are short columella, poor tip definition and septal deviation in contrast to *Chaithanyaa et al.*⁽¹¹⁾ who found that unequal alar positions were the most prominent deformity.

Only closed rhinoplasty was done for primary cases, our early results demonstrated adequate repositioning of the cartilages and no postoperative complications using the Tajima technique and this agrees with *Rottgers and Jiang*⁽¹²⁾.

In primary rhinoplasty we did not dissect more for fear of growth affection. Only simple essential procedures were done as nasal floor and release of LLC and sutures to allow for more symmetric growth, this concept agreed with⁽⁷⁾.

In all secondary cases involved in the current work, external approach was done. This had the advantage of exposing both sides of the nose so that the anatomy on the healthy side was used as reference for correction of the deformed side. In addition this adequate exposure had allowed accurate placement of the cartilage grafts and sutures used to correct deformities. This approach is the most universally accepted one in cleft lip nasal deformity⁽¹³⁾.

The outcomes of the operations were evaluated subjectively as well as objectively regarding to aesthetic and functional perspectives.

Regarding to the general degree of subjective satisfaction, about 93% accepted the final result (either good (43.3%) or fair (50%)) and only 7% had poor satisfaction.

Regarding to the type of the used grafts, we used almost the autologous cartilaginous grafts., this concept does not agree with *Lohuis et al.*⁽¹⁴⁾, who preferred synthetic materials over autologous grafts because of their immediate availability, lack of donor-site morbidity, better adaptability, good immediate results, and low costs. But there are disadvantages of the other substitutes as resorption and difficult handling, so the upper hand still referred to autologous graft⁽¹⁵⁾.

Although generally the use of grafts significantly affect the results regardless to the donor site, the costal cartilage recorded the most satisfying outcome regarding to patient's satisfaction as well as objective evaluation of the nasal tip appearance, followed by the septal cartilage and then and lastly, the auricular cartilage. This conclusion was also stated by *Araco et al.*⁽¹⁶⁾ and *Gunter*⁽¹⁷⁾.

Despite of number of females involved in the current study was more, males recorded higher degrees of subjective satisfaction.

As regard patient satisfaction in relation to stages of surgery, we found that tertiary intervention had bad result as regard skin flap which may be compromised up to necrosis and bad wound healing.

It was found that another touch is needed for few cases after secondary rhinoplasty such as lip scar revision, columellar lengthening, and another LLC support.

As regard the donor site, we were not faced with any operative complication or even serious complaint from the donor site; either costal or auricular. So, the autologous cartilaginous graft could be considered as a safe, cheap as well as relatively

easily obtained nasal tip support with good long-term results. The same absence of donor site complications was achieved by *Tiong et al.* ⁽¹⁸⁾.

Cleft lip nasal deformity are not only associated with cosmetic complaints, but also accompanied by functional symptoms. In this study, two main functional complaints were found, which were nasal breathing difficulty due to deformed valves and nasal tone of speech. Augmentation rhinoplasty with correction of both internal and external nasal valves showed complete improvement in their breathing complaints, but unfortunately failed to achieve the same marvelous results regarding the abnormal voice tone. The same improvement in the nasal breathing was recorded by *Chaithanyaa et al.* ⁽¹¹⁾.

During postoperative follow up of the operated upon patients, we were faced with minor non-aesthetic complications such as epistaxis, minor degree of wound infection and also contact dermatitis from the adhesive tape.

All of them responded well to simple medical conservative measures. However, there was one case of disruption of the transcolumellar incision, this mostly occurred due to relatively short columella in comparison with the columellar strut graft. This case was managed by daily dressings under cover of antibiotics. Postoperative skin necrosis also occurred in mattress suture (fixation of extended LLC strut), which was associated with extreme fibrosis in tertiary case which was managed by daily wet dressing under antibiotic cover.

Cochran and Landecker ⁽¹⁹⁾, stated that complications and suboptimal results do occur, even for experienced surgeons. A thorough knowledge of the principles of postoperative management of these complications can minimize their deleterious effects and preserve an aesthetic outcome.

CONCLUSION

A naturally looking nasal projection and asymmetry not only determines the patients' degree of satisfaction but also is considered the ultimate aesthetic as well as functional goal for the surgeons. Corrective rhinoplasty in cases of cleft lip nasal deformity is a complex procedure.

As in the current study, multiple surgical options (either sutures or grafts) in addition to the secondary procedures were used in the operated upon 30 patients aiming to achieve the desired postoperative results. Nasal grafts are essential for considerable good outcomes for cases of cleft nasal deformity.

REFERENCES

1. **Allori AC and Mulliken JB (2017):** Evidence-based medicine: secondary correction of cleft lip nasal

deformity. *Plastic and reconstructive surgery*, 140(1): 166-176.

2. **Henry C, Samson T, Mackay D (2014):** Evidence-based medicine: The cleft lip nasal deformity. *Plast Reconstr Surg.*, 133:1276–1288.
3. **Patel KB and Mulliken JB (2014):** Correction of the vestibular web during primary repair of unilateral cleft lip. *Plast Reconstr Surg.*, 134:600e–607e.
4. **Atherton JD (1967):** A descriptive anatomy of the face in human fetuses with unilateral cleft lip and palate. *The Cleft palate journal*, 4(2): 104-114.
5. **Kim YS, Cho HW, Park BY, Jafarov M (2008):** A comparative study of the medial crura of alar cartilages in unilateral secondary cleft nasal deformity: The validity of medial crus elevation. *Ann Plast Surg.*, 61:404–409.
6. **Loftus JM and Neale HW (1996):** Cleft lip microstril: The problem and proposed solution. *Cleft Palate Craniofac J.*, 33:348–351.
7. **Kaufman Y, Buchanan EP, Wolfswinkel EM et al. (2012):** Cleft nasal deformity and rhinoplasty. In *Seminars in plastic surgery*, Thieme Medical Publishers, 26(4): 184.
8. **Alsarraf R (2002):** Outcomes instruments in facial plastic surgery. *Facial plastic surgery*, 18(2): 77-86.
9. **Lo L (2006):** Primary correction of the unilateral cleft lip nasal deformity: Achieving the excellence. *Chang Gung medical journal*, 29: 262-267.
10. **Sykes J (2010):** The importance of primary rhinoplasty at the time of initial unilateral cleft lip repair. *Arch Facial Plast Surg.*, 12: 53-55.
11. **Chaithanyaa N, Rai KK, Shivakumar HR, Upasi A (2011):** Evaluation of the outcome of secondary rhinoplasty in cleft lip and palate patients. *Journal of Plastic, Reconstructive & Aesthetic Surgery*, 64(1): 27-33.
12. **Rottgers SA and Jiang S (2010):** Repositioning of the lower lateral cartilage in primary cleft nasoplasty: utilization of a modified Tajima technique. *Annals of plastic surgery*, 64(5): 691-695.
13. **Raspall G, Gonzfilez L and Lagunas J (2010):** Management of the nasal tip by open rhinoplasty. *Journal of cranio-Maxillofacial surgery*, 28:145-150.
14. **Lohuis P, Watts S and Vuyk H (2001):** Augmentation of the nasal dorsum using Gore-Tex: Intermediate results of a retrospective analysis of experience in 66 patients. *Clin Otolaryngol Allied Sci.*, 26:214-217.
15. **Taha A, Helmy Y, Mikki M et al. (2006):** Outcome of autogenous versus alloplastic grafts (medpore) for reconstructive augmentation rhinoplasty. *European journal of pharmaceutical And medical research*, 4(3): 127-132.
16. **Araco A, Gravante G, Araco F et al. (2006):** Autologous cartilage graft rhinoplasties. *Aesthetic Plast Surg.*, 30:169-174.
17. **Gunter J (1999):** Tip rhinoplasty a personal approach. *Plast Reconstr Surg.*, 110(4): 204-226.
18. **Tiong W, Zain M and Basiron N (2014):** 152 Augmentation rhinoplasty in cleft lip nasal deformity: preliminary patients' perspective. *Plastic Surgery International*, 2014: 202560.
19. **Cochran C and Landecker A (2011):** Prevention and management of rhinoplasty complications. *Plast Reconstr Surg.*, 122: 60-71.