

# Evaluation of the Aesthetic Outcome of Glandular Liposculpture Using V - Dissector Liposuction Cannula for Grades I and II Gynecomastia Combined with the Sealing Effect of Autologous Platelet Gel

AHMAD ELHUSSEIN MOHAMED, M.D.\*; MAHMOUD MOHAMED SHAKER ELSAYED, M.Sc.\* and ASMAA K.K. ABDELMAOGOOD, M.D.\*\*

The Departments of Plastic Surgery\* and Clinical & Chemical Pathology\*\*, Faculty of Medicine, Suez Canal University

## Abstract

**Background:** Gynecomastia is defined as an abnormal growth of male breast tissue that is considered the most frequent male cosmetic problem, accounting for roughly 60% of the total male breast problems and 85% of male breast masses. Several traditional treatments, including liposuction, subcutaneous mastectomy, and a combination of both, have been documented. This approach inevitably results in a scar on the anterior chest wall; liposuction alone can result in minimal scarring but has a minimal effect on the tough glandular and fibroconnective tissues.

**Objective:** Evaluation of the aesthetic outcome of glandular liposculpture using V-dissector liposuction cannula for grades I and II gynecomastia combined with the sealing effect of autologous platelet gel.

**Methods:** This was an uncontrolled clinical study, including 25 patients [50 breasts] ageing between 18 and 45 years with idiopathic benign gynecomastia who requested surgical intervention for their gynecomastia. liposuction and liposculpturing with V-dissector liposuction cannula without glandular tissue excision, followed by platelet gel spraying on the cavity. The procedure was completed, and the overall complication rate was recorded, mainly hematoma and seroma.

**Conclusion:** Glandular liposculpture using V-dissector liposuction cannula for grades I and II gynecomastia combined with sealing autologous platelet gel was effective and safe, and both patients and observers were adequately satisfied with an acceptable outcome rating.

**Key Words:** V- dissector – Liposculpture – Gynecomastia.

**Disclosure:** The authors have no conflict of interest to declare.

**Ethical Committee:** The study had the approval of the local Institutional Review Board and the Research Ethics Committee, Faculty of Medicine, Suez Canal University on July 25, 2023, with the approval code 5389#. All participants filled a written informed consent to participate in the study.

**Correspondence to:** Dr. Ahmad El Hussein Mohamed,  
E-Mail: rivercruise85@gmail.com

## Introduction

Gynecomastia is defined as an abnormal growth of male breast tissue. It is the most frequent male breast problem, accounting for roughly 60% of the total male breast abnormalities [1]. Several traditional treatments, including liposuction, subcutaneous mastectomy, and a combination of both, have been documented [2]. Recently, there has been a tendency towards using a less invasive approach to stay away any open excision after the procedure of liposuction [3]. This study aimed at evaluating the aesthetic outcome of glandular liposculpture using V-dissector liposuction cannula for grades I and II gynecomastia combined with sealing autologous platelet gel.

## Patients and Methods

After receiving ethical committee approval (the study had the approval of the local Institutional Review Board and the Research Ethics Committee, Faculty of Medicine, Suez Canal University on July 25, 2023, with the approval code 5389#), All participants provided written informed consent to participate in the study. This study was an uncontrolled clinical study carried out during the period of time extended from 2021 to 2023, as each patient was followed-up for 3 months, including 25 patients [50 breasts] ageing between 18 and 40 years with idiopathic benign gynecomastia who requested surgical intervention for their gynecomastia. A detailed clinical history and physical examination, the patient's body mass index, any chronic illness, grade of gynecomastia, and any breast asymmetry if founded were recorded preoperatively. Radiographic assessment with ultrasound and comprehensive hormonal assays were performed for all patients, including leutinizing hormone [LH], follicular-stimulating hormone [FSH], free testosterone, estradiol, prolactin, and the testicular cancer markers including B-HCG and alpha-fetoprotein. They also had thyroid and liver function testing to

rule out any underlying medical causes of gynecomastia. Patients had liposuction and liposculpturing with a V-dissector liposuction cannula without excision of any glandular tissue, followed by platelet gel spraying on the cavity. The procedure was completed, and the overall complication rate was recorded mainly hematoma and seroma.

Preoperatively, the breasts of all patients were assessed for its consistency (fatty, glandular, or mixed) and symmetry. every patient who had the procedure had complete blood picture and coagulation profile. The patient was anaesthetized, and skin preparation was carried out as usual. The superwet infiltration technique (0.5 to 1.0ml infiltrate: 1ml aspirate) was used. In 1000ml of Ringer's lactate solution, there was 1ml of 1:1000 epinephrine and 25ml of 1% lidocaine (8.4% sodium bicarbonate 7.5ml was added to minimize the irritable sensation of lidocaine during tumescent infiltration in patients with local anesthesia). A 5mm stab incision was made about 0.5–1cm posterior to the anterior axillary fold (Fig. 1), and the infiltration process began with a straight blunt cannula about 3-mm in diameter, with the total amount of the infiltrated fluid ranging between 400ml and 750ml depending on each breast size both breasts were invaded one after the other.

In all cases, suction-assisted liposuction was used. The lipoaspirate was extracted from two holes: The initial infiltration opening and a second one that was done 10 cm below it, just posterior to the anterior axillary fold. This made the “criss-and-cross” movement for liposuction possible (Fig. 2), resulting in a smooth shape. One hand grasped and compressed the breast tissue while the other hand glided the cannula forth and back.

As the cannula tip is sharp (Fig. 3), it is critical to keep the cannula parallel to the chest wall to prevent chest penetration. The cannula of the smallest diameter (3.0mm) was first utilized to create tracks in the dense glandular tissue. Then, for more severe dense glandular tissue removal, bigger diameter cannulas (4.0mm) were typically used. Occasionally, all patients were positioned in the upright position to check the end result contour at the end of the procedure.

Simultaneously, the autologous platelet gel was prepared (1 unit of blood is taken the platelets were extracted through centrifugation. One unit of blood will provide around 40mL of platelets with a 125mL. Their level of Fibrinogen ranges from 2 to 4mg/mL. The count of the platelet ranges between 5 and 10 108/mL. The first pass takes about 22 minutes, and each subsequent pass takes about 12 minutes), and then 7mL of platelets were extracted into a syringe of 10-mL. The thrombin-calcium solution was then injected at a concentration of 1 to 2mL. The syringe was then rotated forth and back gradually. The solution begins to gel after 30 to 60 sec-

onds (Fig. 4). The syringe contents were infiltrated into the cavity or under the skin flaps through the previous stab incisions of liposuction.

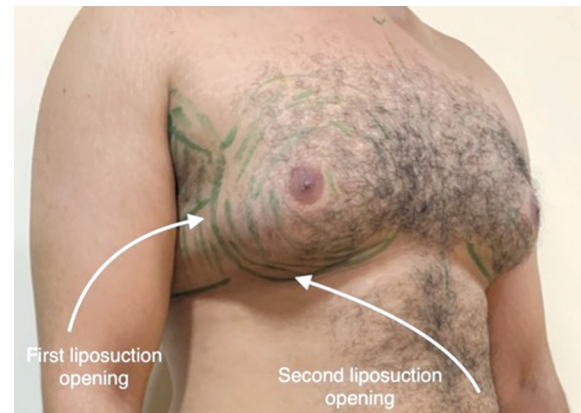


Fig. (1): The preoperative marking and the site of liposuction stab incisions.

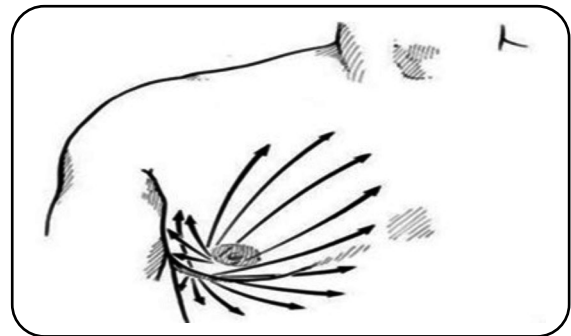


Fig. (2): The “criss-and-cross” direction of the cannula for liposuction [3].




Fig. (3): V-dissector liposuction cannula with a sharpened edge on their opening.

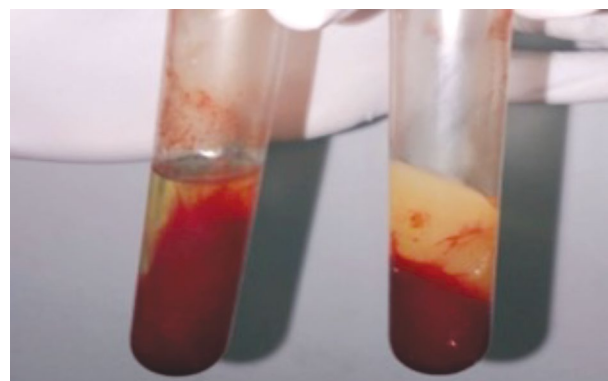


Fig. (4): Autologous platelet gel.

At the end, manual compression was applied to this area for 1 to 2 minutes. The openings of liposuction were left open for drainage, without any drain insertion. A pressure dressing with foam was then applied over the wound and both breasts, and then a liposuction compression garment was applied. The patient was discharged after recovery and then reviewed in the clinic on the third postoperative day, one week, two weeks, one month, three months, and six months postoperatively.

**Patients' Self-Reported Evaluation:** Patient satisfaction was measured using data from the Breast Evaluation Questionnaire (BEQ) [4], which had previously been used to assess the outcomes after gynecomastia [5,6]. It is delivered to all patients who have had gynecomastia surgery 6 months after the procedure, whatever the type of surgery, as feedback for the surgeon. This questionnaire was classified into four sections; the respondent's level of satisfaction with the shape of breast/chest, dressed and undressed, in different situations (alone, presence of partner, women, other men, and doctors); the respondent's level of satisfaction with breast/chest size in different situations (alone, presence of partner, women, other men, and doctors); satisfaction for himself and his partner; and the level of satisfaction with certain characteristics such as symmetry, flatness, shape of the nipple areola complex, numbness, and scars. All questions were answered on a five-point Likert scale (1 = Very unsatisfied; 2 = Dissatisfied; 3 = Neither; 4 = Satisfied; 5 = Very satisfied).

**Observers' Reported Evaluations:** Five independent plastic surgery physicians who were not informed about the patient's procedure type gave their opinions before and after the operation and six months apart. They evaluated the following factors: on a scale of 1 (no improvement) to 5 (great improvement), the improvement in the contour of the front chest wall Breast symmetry, nipple areola complex form and projection, flattens, shape, and overall satisfaction. The improvements were given as a mean (SD) based on the judgements of the five physicians.

#### Statistical analysis:

Data were entered to the computer, and analyzed using IBM SPSS software package version 20.0. (Armonk, NY: IBM Corp). Categorical data were expressed as numbers and percentages. Chi-square test was used to investigate the relation between the categorical variables. Alternatively, Fisher's exact test was used when more than 20% of the cells have expected count less than five. For continuous data, they were examined for normality by the Shapiro-Wilk test. Quantitative data were represented as range (minimum and maximum), mean, standard deviation and median Marginal Homogeneity Test applied to analyze the significance between the different stages. Significance of the obtained results was evaluated at the level of 5%.

## Results

The total number of cases included in this study was 25; nearly one third of them had grade 1 gynecomastia (44%), while the remaining had grade 2 gynecomastia (56%), their mean age was  $24 \pm 5.2$  years (ranged from 18 to 35 years old), 40% of them were smokers; and none of them had any chronic illness. Their mean body mass index [BMI] was  $27.9 \pm 1.9$  kg/m<sup>2</sup> (ranging from 25 to 32kg/m<sup>2</sup>) (Table 1).

The mean operative time was  $1.4 \pm 0.5$  hours (ranged from 1 to 3 hours), and all of the patients were discharged at the same day of the operation. The mean volume of infiltrated fluid-aspirated fat was  $632 \pm 94.5$ ml (ranging from 500ml to 750ml). (Table 1) Regarding the complications, 5 (20%) patients developed post-operative numbness that was almost improved after 3 months of the operation 2 (8%) patient developed post-operative hematomas that was evacuated manually at the second post-operative day without recurrence. No one experienced any of the other common complications like wound dehiscence, infection, or seroma (Table 1).

Table (1): Distribution of the studied patients according to their clinical and demographic characters (n=25).

	No. (%)
<b>Age (years):</b>	
Mean $\pm$ SD	24 $\pm$ 5.2
Median (Min. – Max.)	22 (18 – 35)
<b>BMI (kg/m<sup>2</sup>):</b>	
Mean $\pm$ SD	27.9 $\pm$ 1.9
Median (Min. – Max.)	28 (25 – 32)
<b>Duration of operation (Hours):</b>	
Mean $\pm$ SD	1.4 $\pm$ 0.5
Median (Min. – Max.)	1.5 (1 – 3)
<b>Volume of aspiration (ml):</b>	
Mean $\pm$ SD	632 $\pm$ 94.5
Median (Min. – Max.)	650 (500 – 750)
<b>Grade:</b>	
I	11 (44%)
II	14 (56%)
<b>Complications:</b>	
Infection	0 (0%)
Hematoma	2 (8%)
Seroma	0 (0%)
Numbness	5 (20%)

SD: Standard deviation.

The mean Likert score of (SD) overall BEQ patient's satisfaction score was 4.6 ( $\pm 0.5$ ), in which 64% of the patients were very satisfied and 36% were satisfied (Table 2). The mean Likert score of (SD) Breast Evaluation Questionnaire for all items improved from "dissatisfied" 1.6 ( $\pm 0.38$ ) preoperatively to "satisfied" 4.6 ( $\pm 0.06$ ) postoperative-

ly ( $p=0.001$ ). The mean (SD) increase of Likert score in Breast Evaluation Questionnaire was 3.1 ( $\pm 2.1$ ), and the highest difference (2.9) was noticed in those three items: size of the chest satisfaction by patient; satisfaction with the appearance of the

chest dressed with other men; and satisfaction with the appearance of the chest dressed with other women. The least noticed difference (2.2) was satisfaction with the appearance of the chest dressed with partner (Fig. 5).

Table (2): Comparison between preoperative satisfaction and 3 months postoperative satisfaction according to Breast Evaluation Questionnaire.

	Preoperative	3 months Postoperative	MH	<i>p</i>
<b>1- Size of chest satisfaction by patient:</b>				
Very unsatisfied	17 (68%)	0 (0%)	74.000*	<0.001*
Dissatisfied	8 (32%)	0 (0%)		
Neither	0 (0%)	0 (0%)		
Satisfied	0 (0%)	10 (40%)		
Very satisfied	0 (0%)	15 (60%)		
<b>2- Size of chest satisfaction by doctor:</b>				
Very unsatisfied	11 (44%)	0 (0%)	75.500*	<0.001*
Dissatisfied	14 (56%)	0 (0%)		
Neither	0 (0%)	0 (0%)		
Satisfied	0 (0%)	13 (52%)		
Very satisfied	0 (0%)	12 (48%)		
<b>3- Satisfaction with the appearance of chest dressed alone:</b>				
Very unsatisfied	14 (56%)	0 (0%)	75.000*	<0.001*
Dissatisfied	11 (44%)	0 (0%)		
Neither	0 (0%)	0 (0%)		
Satisfied	0 (0)	11 (44)		
Very satisfied	0 (0)	14 (56)		
<b>4- Satisfaction with the appearance of chest dressed with partner:</b>				
Very unsatisfied	3 (12%)	0 (0%)	86.000*	<0.001*
Dissatisfied	11 (44%)	0 (0%)		
Neither	11 (44%)	0 (0%)		
Satisfied	0 (0%)	11 (44%)		
Very satisfied	0 (0%)	14 (56%)		
<b>5- Satisfaction with the appearance of chest dressed with other men:</b>				
Very unsatisfied	20 (80%)	0 (0%)	73.000*	<0.001*
Dissatisfied	5 (20%)	0 (0%)		
Neither	0 (0%)	0 (0%)		
Satisfied	0 (0%)	9 (36%)		
Very satisfied	0 (0%)	16 (64%)		
<b>6- Satisfaction with the appearance of chest dressed with other women:</b>				
Very unsatisfied	21 (84%)	0 (0%)	71.500*	<0.001*
Dissatisfied	4 (16%)	0 (0%)		
Neither	0 (0%)	0 (0%)		
Satisfied	0 (0%)	11 (44%)		
Very satisfied	0 (0%)	14 (56%)		
<b>6- Satisfaction with the appearance of chest dressed by doctor:</b>				
Very unsatisfied	1 (4%)	0 (0%)	83.000*	<0.001*
Dissatisfied	11 (44%)	0 (0%)		
Neither	13 (52%)	1 (4%)		
Satisfied	0 (0%)	13 (52%)		
Very satisfied	0 (0%)	11 (44%)		

Table (2): Count.

	Preoperative	3 months Postoperative	MH	<i>p</i>
<b>8- Satisfaction with the appearance of chest undressed alone:</b>				
Very unsatisfied	17 (68%)	0 (0%)	74.000*	<0.001*
Dissatisfied	8 (32%)	0 (0%)		
Neither	0 (0%)	0 (0%)		
Satisfied	0 (0%)	10 (40%)		
Very satisfied	0 (0%)	15 (60%)		
<b>9- Satisfaction with the appearance of chest undressed with partner:</b>				
Very unsatisfied	11 (44%)	0 (0%)	76.500*	<0.001*
Dissatisfied	14 (56%)	0 (0%)		
Neither	0 (0%)	0 (0%)		
Satisfied	0 (0%)	11 (44%)		
Very satisfied	0 (0%)	14 (56%)		
<b>10- Satisfaction with the appearance of chest undressed with other men:</b>				
Very unsatisfied	9 (36%)	0 (0%)	77.000*	<0.001*
Dissatisfied	16 (64%)	0 (0%)		
Neither	0 (0%)	0 (0%)		
Satisfied	0 (0%)	12 (48%)		
Very satisfied	0 (0%)	13 (52%)		
<b>11- Satisfaction with the appearance of chest undressed with other women:</b>				
Very unsatisfied	12 (48%)	0 (0%)	77.500*	<0.001*
Dissatisfied	13 (52%)	0 (0%)		
Neither	0 (0%)	0 (0%)		
Satisfied	0 (0%)	8 (32%)		
Very satisfied	0 (0%)	17 (68%)		
<b>12- Satisfaction with the appearance of chest undressed by doctor:</b>				
Very unsatisfied	7 (28%)	0 (0%)	80.500*	<0.001*
Dissatisfied	16 (64%)	0 (0%)		
Neither	2 (8%)	0 (0%)		
Satisfied	0 (0%)	9 (36%)		
Very satisfied	0 (0%)	16 (64%)		
<b>13- Satisfaction with the general appearance of the chest by patient:</b>				
Very unsatisfied	12 (48%)	0 (0%)	77.000*	<0.001*
Dissatisfied	13 (52%)	0 (0%)		
Neither	0 (0%)	0 (0%)		
Satisfied	0 (0%)	9 (36%)		
Very satisfied	0 (0%)	16 (64%)		
<b>14- Satisfaction with the general appearance of the chest by partner:</b>				
Very unsatisfied	11 (44%)	0 (0%)	77.000*	<0.001*
Dissatisfied	14 (56%)	0 (0%)		
Neither	0 (0%)	0 (0%)		
Satisfied	0 (0%)	10 (40%)		
Very satisfied	0 (0%)	15 (60%)		

MH: The Marginal Homogeneity Test.

*p*: Represent 'p-value' for comparing between Pre and Post.\*: Represent the Statistically significant that was at  $p \leq 0.05$ .

The mean Likert (SD) score of patient's satisfactions with flatness, scars, breast shape, and symmetry improved from 1.72 ( $\pm 0.63$ ) to 4.54 ( $\pm 0.09$ ) that was a statistically significant result as the overall satisfaction improved from 68% very unsatisfied and 32% dissatisfied to 60% very satisfied and 40% satisfied [The Marginal Homogeneity Test was 74.000. The  $p$ -value is  $< 0.00001$ ] (Table 3) while in the observers' assessment, the mean Likert (SD) score of satisfactions with flatness, scars, breast shape, and symmetry improved from 1.66

( $\pm 0.18$ ) to 4.61 ( $\pm 0.06$ ) that was a statistically significant result as the overall satisfaction improved from 56% very unsatisfied and 44% dissatisfied to 60% very satisfied and 40% satisfied [The Marginal Homogeneity Test was 77.000. The  $p$ -value is  $< 0.00001$ ] (Table 4) (Fig. 6).

Figures (7,8) shows two cases of preoperative and postoperative pictures for patients who had grades I and II gynecomastia treated with liposuction and liposculpturing.

Table (3): Comparison between patient preoperative satisfaction and patient 3 months postoperative satisfaction according to specific chest measures.

	Preoperative	3 months Postoperative	MH	$p$
<b>1- Patient satisfaction with the chest symmetry:</b>				
Very unsatisfied	14 (56%)	0 (0%)	75.000*	$< 0.001^*$
Dissatisfied	11 (44%)	0 (0%)		
Neither	0 (0%)	0 (0%)		
Satisfied	0 (0%)	11 (44%)		
Very satisfied	0 (0%)	14 (56%)		
<b>2- Patient satisfaction with the NAC:</b>				
Very unsatisfied	3 (12%)	0 (0%)	86.000*	$< 0.001^*$
Dissatisfied	11 (44%)	0 (0%)		
Neither	11 (44%)	0 (0%)		
Satisfied	0 (0%)	11 (44%)		
Very satisfied	0 (0%)	14 (56%)		
<b>3- Patient satisfaction with the chest shape:</b>				
Very unsatisfied	20 (80%)	0 (0%)	73.000*	$< 0.001^*$
Dissatisfied	5 (20%)	0 (0%)		
Neither	0 (0%)	0 (0%)		
Satisfied	0 (0%)	9 (36%)		
Very satisfied	0 (0%)	16 (64%)		
<b>4- Patient satisfaction with the chest flatness:</b>				
Very unsatisfied	21 (84%)	0 (0%)	71.500*	$< 0.001^*$
Dissatisfied	4 (16%)	0 (0%)		
Neither	0 (0%)	0 (0%)		
Satisfied	0 (0%)	11 (44%)		
Very satisfied	0 (0%)	14 (56%)		
<b>5- Patient satisfaction with scars:</b>				
Very unsatisfied	1 (4%)	0 (0%)	83.000*	$< 0.001^*$
Dissatisfied	11 (44%)	0 (0%)		
Neither	13 (52%)	1 (4%)		
Satisfied	0 (0%)	13 (52%)		
Very satisfied	0 (0%)	11 (44%)		
<b>6- Patient satisfaction with the overall results:</b>				
Very unsatisfied	17 (68%)	0 (0%)	74.000*	$< 0.001^*$
Dissatisfied	8 (32%)	0 (0%)		
Neither	0 (0%)	0 (0%)		
Satisfied	0 (0%)	10 (40%)		
Very satisfied	0 (0%)	15 (60%)		

MH: The Marginal Homogeneity Test.

$p$ : Represent ' $p$ -value' for comparing between Pre and Post.

\*: Represent the Statistically significant that was at  $p \leq 0.05$ .

Table (4): Comparison between observer preoperative satisfaction and observer 3 months postoperative satisfaction according to specific chest measures.

	Preoperative	3 months Postoperative	MH	<i>p</i>
<b>1- Observer satisfaction with the chest symmetry:</b>				
Very unsatisfied	12 (48%)	0 (0%)	77.500*	<0.001*
Dissatisfied	13 (52%)	0 (0%)		
Neither	0 (0%)	0 (0%)		
Satisfied	0 (0%)	8 (32%)		
Very satisfied	0 (0%)	17 (68%)		
<b>2- Observer satisfaction with the NAC:</b>				
Very unsatisfied	7 (28%)	0 (0%)	80.500*	<0.001*
Dissatisfied	16 (64%)	0 (0%)		
Neither	2 (8%)	0 (0%)		
Satisfied	0 (0%)	9 (36%)		
Very satisfied	0 (0%)	16 (64%)		
<b>3- Observer satisfaction with the shape:</b>				
Very unsatisfied	12 (48%)	0 (0%)	77.000*	<0.001*
Dissatisfied	13 (52%)	0 (0%)		
Neither	0 (0%)	0 (0%)		
Satisfied	0 (0%)	9 (36%)		
Very satisfied	0 (0%)	16 (64%)		
<b>4- Observer satisfaction with the flatness:</b>				
Very unsatisfied	11 (44%)	0 (0%)	77.000*	<0.001*
Dissatisfied	14 (56%)	0 (0%)		
Neither	0 (0%)	0 (0%)		
Satisfied	0 (0%)	10 (40%)		
Very satisfied	0 (0%)	15 (60%)		
<b>5- Observer satisfaction with scars:</b>				
Very unsatisfied	7 (28%)	0 (0%)	80.500*	<0.001*
Dissatisfied	13 (52%)	0 (0%)		
Neither	5 (20%)	1 (4%)		
Satisfied	0 (0%)	10 (40%)		
Very satisfied	0 (0%)	14 (56%)		
<b>6- Observer overall satisfaction:</b>				
Very unsatisfied	11 (44%)	0 (0%)	77.000*	<0.001*
Dissatisfied	14 (56%)	0 (0%)		
Neither	0 (0%)	0 (0%)		
Satisfied	0 (0%)	10 (40%)		
Very satisfied	0 (0%)	15 (60%)		

MH: The Marginal Homogeneity Test.

*p*: Represent 'p-value' for comparing between Pre and Post.\*: Represent the Statistically significant that was at  $p \leq 0.05$ .

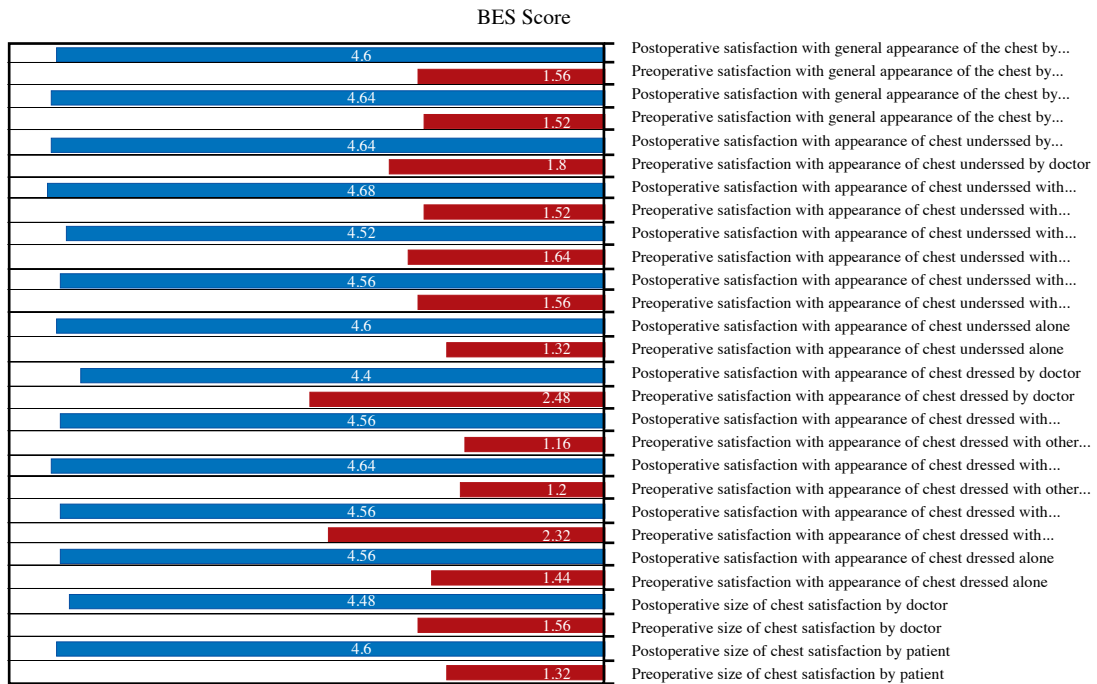


Fig. (5): Comparison between the mean Likert score of preoperative satisfaction and the mean Likert score of 3 months postoperative satisfaction according to Breast Evaluation Questionnaire.

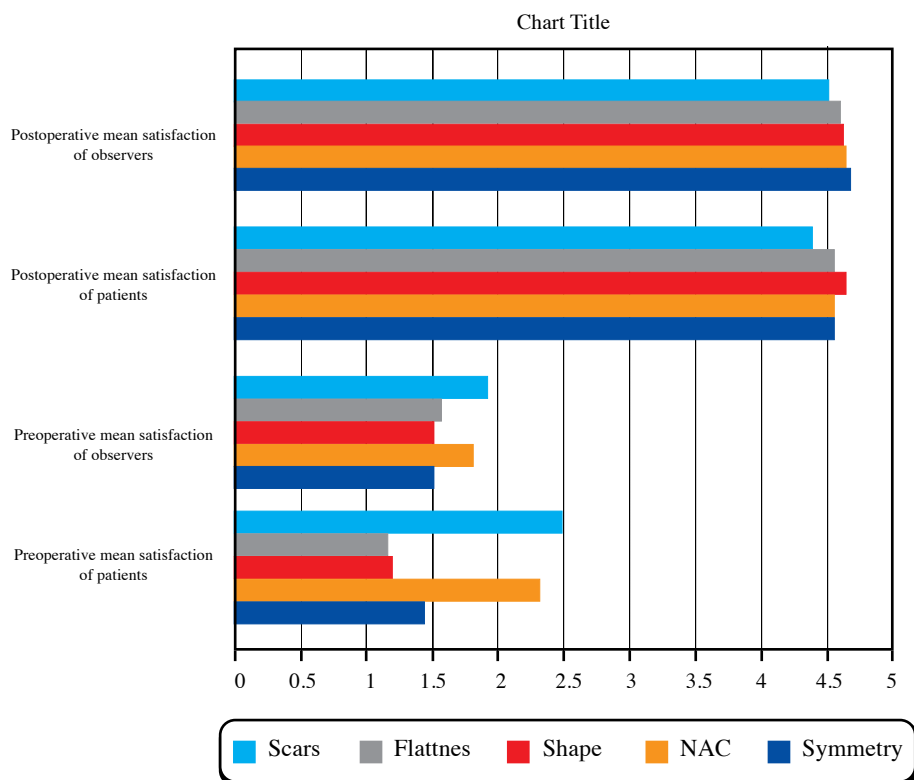


Fig. (6): Comparison between the mean Likert score of the preoperative satisfaction and the 3 months postoperative satisfaction of both patient and observer according to specific chest measures.



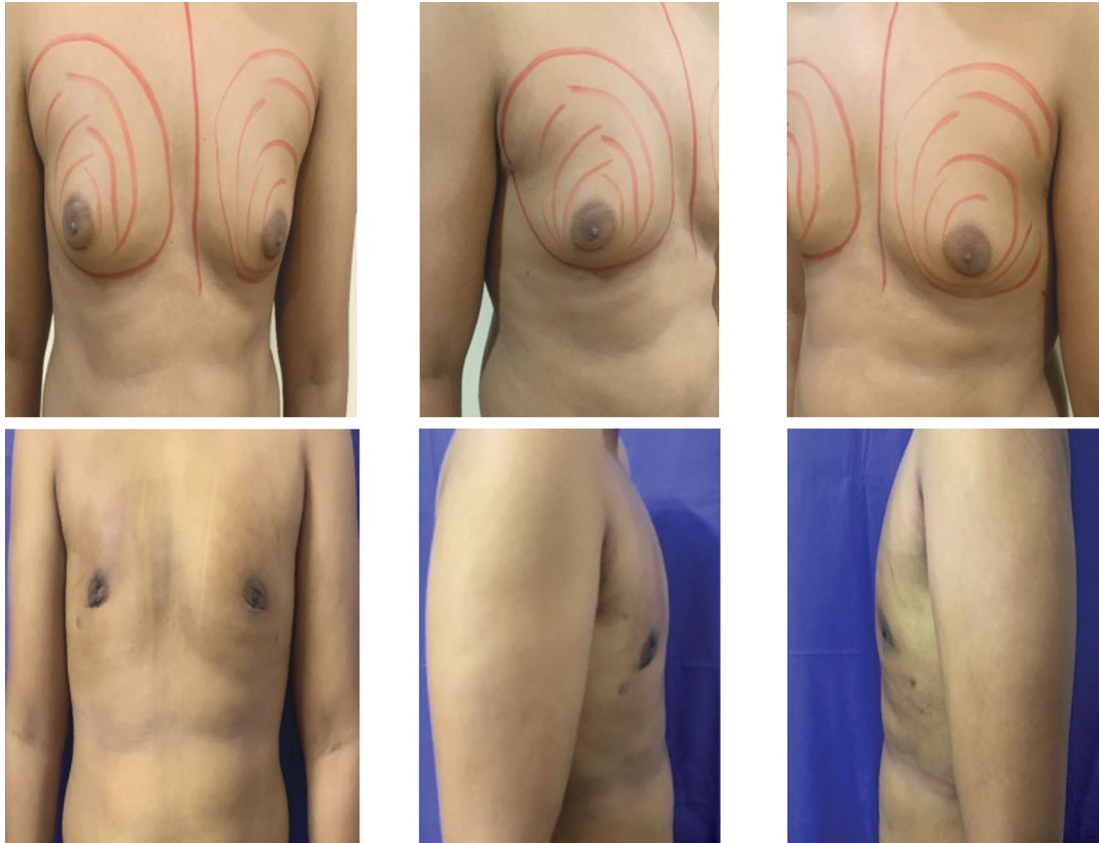


Fig. (7): A 18-year-old patient who was 173cm tall, weighed 85kg, and had a body mass index of  $29.4\text{kg/m}^2$ , had bilateral gynecomastia grade IIB. The LT. row shows the preoperative photographs demonstrating the moderate enlargement of the breast tissue in both sides; the RT. row shows the postoperative results (1 month) with an acceptable flat chest.

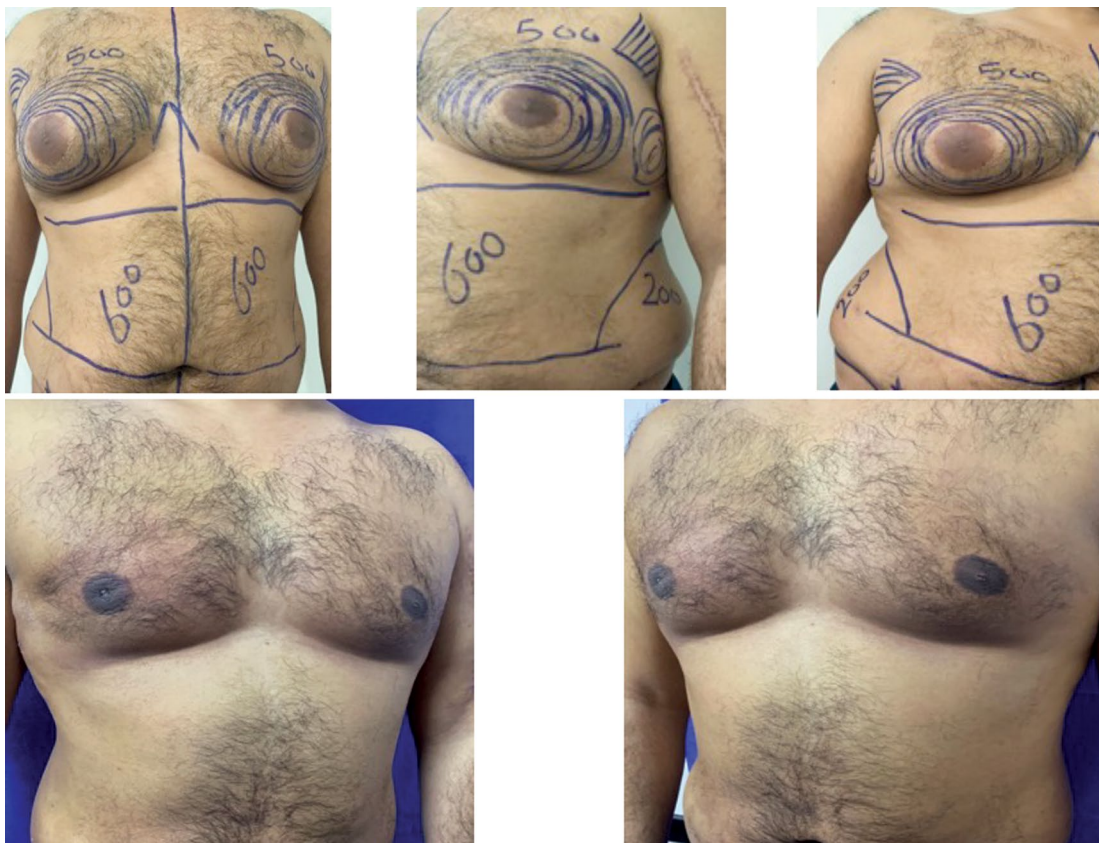

Fig. (8): A 33-year-old patient, 190cm tall, who weighed 95 kg and had a body mass index of  $26.3\text{kg/m}^2$ , had bilateral gynecomastia grade IIB. The upper row shows the preoperative photographs demonstrating the enlargement of the breast tissue in both sides; the lower row shows the postoperative photographs results after 3 months of the intervention.

## Discussion

Gynecomastia is defined as an abnormal growth of male breast tissue. This problem differs from the breast bulge caused by increased adipose tissue accumulation in obesity, which is known as pseudo gynecomastia or lipomastia [1]. Webster divided gynecomastia into three main types based on the predominant tissue type, which was fatty, glandular, or both [7]. In 1973, Simon et al. [8] proposed a categorization depend on the size of gynecomastia. A little apparent expansion of the breast not associated with redundant skin was classified as grade I. Grade II A gynecomastia was defined as moderate breast expansion without any redundancy of the skin, and grade II B gynecomastia was defined as moderate expansion associated with little excess skin. Grade III gynecomastia was classified as extensive expansion associated with redundant skin and ptosis of the breast [7,8].

Consequently, management of this condition is required; of all treatment options, operative mastectomy is the most successful [9]. Several traditional treatments, including liposuction, subcutaneous mastectomy, and a combination of both, have been documented. The most commonly utilized procedure is liposuction combined with subcutaneous mastectomy [10].

The ideal surgical technique for treating gynecomastia is to excise glandular and fatty breast tissue with the elimination of skin laxity and reducing scarring as much as possible [3]. Teimourian and Perlman [11] explained traditional liposuction with glandular excision because of the difficulty of eliminating the strong glandular tissue by liposuction alone. This concept for the treatment of gynecomastia became widely accepted in 1983. However, other surgeons have argued that liposuction alone can treat all grades of gynecomastia [12], with a specific cannula of 2.3mm length that can remove breast tissues more easily [13]. Others have followed Rosenberg's lead and employed special types of cutting gynecomastia cannulas in the form of a cutting cannula that had a sharp opening [14] or a punch biopsy [15]. However, those cutting cannulas are more damaging to blood vessels, increasing the risk of postoperative hematoma and seroma. Leading us to try to find a solution for this problem by using the least traumatizing V-dissector liposuction cannula combined with the sealant effect of autologous platelet gel.

Autologous platelet gel is currently applied in a variety of surgical procedures. It is suitable for application in plastic surgery operations that may be associated with a risk of hematoma including breast procedures, face lift, nasal surgery, and grafting of the skin. Its benefits include improved adhesive properties, a lower incidence of bleeding, and the extra benefit of enhanced concentration of the leukocyte [16].

Platelets can be generated in considerably higher quantities and at a lower cost than cryoprecipitate. Concentrated platelets have the same fibrinogen level as the blood they came from: 2 to 4mg/mL. As this quantity is substantially fewer than in cryoprecipitate, the resulting platelet gel lacks the tensile power of cryo-based fibrin glue. It is, nonetheless, suitable for usage as an effective wound sealant and tissue adhesive material [16].

To simulate a portion of natural blood coagulation, the process of fibrinogen adhesion comprises two components: Thrombin in solution combined with calcium chloride and fibrinogen concentrate, and factor XIII obtained from the patient's entire blood preoperatively. When these components combine, thrombin converts fibrinogen into fibrin monomers. Thrombin activates factor XIII at the presence of calcium ions, inducing cross-linking and hence additional stabilization of the coagulated fibrin. In 2–3 minutes, a firm coagulum is generated [17].

Platelet and leukocyte enriched plasma puffy coat appears to have a number of adventitious effects. Platelets and dense granules contain cytokines and mediators that can increase angiogenesis and the synthesis of collagen, thereby boosting healing of the soft-tissue. Platelet-derived growth factor, platelet-derived epidermal growth factor, fibroblast growth factor, transforming growth factor, and platelet-derived angiogenesis factor are examples of these factors [18,19].

These factors have been shown to promote the regeneration of the epidermis, angiogenesis, and collagen formation. Platelet granule also releases local thrombin, thromboxane A<sub>2</sub>, and adenosine diphosphate draws additional platelets, boosting the hemostatic response [20-22].

The Breast Evaluation Questionnaire is more adaptable and has been verified in breast surgery [4] as well as gynecomastia [5]. It analyses patient satisfaction in greater depth than prior research.

In this study, gynecomastia was found to cause considerable physical and psychosocial concern in young men. The patients mean age at the time of presentation was 24.04±5.25 years, and about two-thirds of them had grade 2 gynecomastia. Most of the patients in this study were overweight, as the mean body mass index was 27.94±1.93kg/m<sup>2</sup>, and more than one third of them were active smokers. Singamsetty R et al. [23] in their comparative study of 30 patients found that the mean (SD) age of the patients was 22.6±4.13 years and almost all of patients had grade II gynecomastia, while Abdelrahman I et al. [6] in their study of 18 patients observed that the mean age (SD) of the patients was 31 years (range: 28–34), and 61% of them had grade I gynecomastia, and their mean body mass index was 27.4kg/m<sup>2</sup> (range: 26.7–29.4).

In this study, the mean total operating time was  $1.44 \pm 0.51$  hours, and the mean volume of aspirated fat was  $632 \pm 94.52$ cc, which was consistent with previous studies [24,25]. Also, the postoperative hospital stay was shorter than in the other previous studies [24,25].

The mean Likert score of BEQ improvement in the overall patient satisfaction in this study was much better than that reported in the published study by Ridha H et al., which used the same assessment tool, in which only 62.5% of patients were satisfied to very satisfied [5], that may be explained in several ways, including differences in how the informed consent was taken from the patients, the preoperative discussions about the expectations of the patients, the technique of the procedure, and the nature and social background of the patients in their study.

Regarding the complications, about 5 patients (20%) had developed post-operative numbness that was almost improved after 3 months of the operation without any other common complications like wound dehiscence, infection, hematoma, or seroma, which were reported in other similar studies [23].

In comparison to the other techniques that have been recently developed nowadays, such as power-assisted liposuction and ultrasound-assisted liposuction (VASER), the technique of this study is much easier to manipulate, time- and cost-effective, and we can establish a superficial plane between the skin and the breast tissue, resulting in no visible scarring on the breast [6]. While they are successful in the right patient, they can only be used on fat-type breasts. When adopting these procedures, there is also a concerning high probability of recurrence (35%) because of remnant glandular tissue. In most cases, it is now used as a preliminary step in open excision [26,27].

### Conclusion:

Glandular liposculpture using V-dissector liposuction cannula for grades I and II gynecomastia combined with sealing autologous platelet gel was effective and safe, and both patients and observers were adequately satisfied with an acceptable aesthetic outcome as the mean Likert score of the overall BEQ patient's satisfaction score was 4.6, in which 64% of the patients were very satisfied and 36% were satisfied.

### References

- 1- Ratnam B.V.: A new classification and treatment protocol for gynecomastia. *Aesthetic Surg J.*, 29: 26e31, 2009.
- 2- Hosnuter M.: An ameliorated approach for sharp resection in gynecomastia surgery. *Indian J. Surg.*, 76: 419e424, 2014.
- 3- Hammond D.C.: Surgical correction of gynecomastia. *Plastic Reconstructive Surg.*, 124 (1 Suppl): 61e-68e. doi: 10.1097/PRS.0b013e3181aa2dc7, 2009.
- 4- Anderson R.C., Cunningham B., Tafesse E. and Lenderking W.R.: Validation of the breast evaluation questionnaire for use with breast surgery patients. *Plastic Reconstructive Surg.*, 118 (3): 597-602, 2006.
- 5- Ridha H., Colville R.J. and Vesely M.J.: How happy are patients with their gynecomastia reduction surgery? *J. Plastic Reconstructive Aesthetic Surg.*, 62 (11): 1473-1478, 2009.
- 6- Abdelrahman I., Steinvall I., Mossaad B., Sjoberg F. and Elmasry M.: Evaluation of Glandular Liposculpture as a Single Treatment for Grades I and II Gynecomastia. *Aesthetic Plastic Surg.*, Oct. 42 (5): 1222-1230. doi: 10.1007/s00266-018-1118-x. Epub 2018 Mar 16. PMID: 29549405; PMCID: PMC6153645, 2018.
- 7- Rohrich R., Ha R., Kenkel J., et al.: Classifications and management of gynecomastia: Defining the role of ultrasound-assisted liposuction. *Plastic Reconstructive Surg.*, 111: 909e23, 2003.
- 8- Simon B.E., Hoffman S. and Kahn S.: Classification and surgical correction of gynecomastia. *Plastic Reconstructive Surg.*, 51: 48-52, 1973.
- 9- Iwuagwu O. and Drew P.: Minimal invasive surgery for gynecomastia: A novel approach. *Can. J. Plastic Surg.*, 12: 145e146, 2004.
- 10- Benito-Ruiz J., Raigosa M., Manzano M. and Salvador L.: Assessment of a suction assisted cartilage shaver plus liposuction for the treatment of gynecomastia. *Aesthetic Surg. J.*, 29: 302e309, 2009.
- 11- Teimourian B. and Perlman R.: Surgery for gynecomastia. *Aesthetic Plastic Surg.*, 7 (3): 155-157, 1983.
- 12- Rosenberg G.J.: Gynecomastia: suction lipectomy as a contemporary solution. *Plastic Reconstructive Surg.*, 80 (3): 379-386, 1987.
- 13- Rosenberg G.J.: A new cannula for suction removal of parenchymal tissue of gynecomastia. *Plastic Reconstructive Surg.*, 94 (3): 548-551, 1994.
- 14- Samdal F., Kleppe G. and Aabyholm F.: A new suction-assisted device for removing glandular gynecomastia. *Plastic Reconstructive Surg.*, 87 (2): 383-385, 1991.
- 15- Luckey R.C.: Modified technique for correction of gynecomastia. *Plastic Reconstructive Surg.*, 89 (4): 767, 1992.
- 16- Melmed E.P.: Autologous platelet gel in plastic surgery. *Aesthetic Surg. J.*, Jul. 21 (4): 377-9. doi: 10.1067/maj.2001.118027. PMID: 19331920, 2001.
- 17- Czin E.A. and Chediak J.R.: Coagulation and hemostasis. In: Salem M.R., ed. *Blood Conservation in the Surgical Patient*. Baltimore; Williams & Wilkins, 45-51, 1996.
- 18- Cromack D.T., Porrás-Reyes B. and Mustoe T.A.: Current concepts in wound healing: growth factor and macrophage interaction. *J. Trauma*, 30 (129 Suppl): S129-S133, 1990.

- 19- Pierce G.F., Cande Berg J., Rudolph R., et al.: Platelet derived growth factor -BB and transforming growth factor beta-1 selectivity modulated glycosaminoglycans, collagen and myofibroblasts in excisional wound healing. *Am. J. Pathology*, 38: 629-632, 1991.
- 20- Hom D.B. and Maisel R.H.: Angiogenic growth factors: their effects and potential in soft tissue wound healing. *Ann. Oto. Rhinology*, 101: 349-354, 1992.
- 21- Knighton D.R., Hunt T.K., Thakral K.K. and Goodson W.H.: The role of platelets and fibrin in healing sequence: An in vivo study of angiogenesis and collagen synthesis. *Ann. Surg.*, 196: 379-388, 1982.
- 22- Green D.M.: Platelet gel as an intraoperatively procured platelet-based alternative to fibrin glue. *Plastic Reconstructive Surg.*, 101: 1161-1162, 1998.
- 23- Singamsetty R., Rout S.K., Giri S.K., Panda R., Behera K.K. and Sable M.N.: Aesthetic Outcome of Gynecomastia Management with Conventional Liposuction and Cross-Chest Liposuction: A Prospective Comparative Study. *Aesthetic Plastic Surg.*, Jun. 46 (3): 1063-1070. doi: 10.1007/s00266-021-02611-x. Epub 2021 Oct 12. PMID: 34636927; PMCID: PMC8507502, 2022.
- 24- Abou Ashour H.: Liposuction excision of gynecomastia through an axillary liposuction opening: A novel technique. *Egypt J. Surg.*, 34 (3): 170-176, 2015.
- 25- Schroder L., Rudlowski C., Walgenbach-Brunagel G., Leutner C., Kuhn W. and Walgenbach K.J.: Surgical strategies in the treatment of gynecomastia grade I-II: The combination of liposuction and subcutaneous mastectomy provides excellent patient outcome and satisfaction. *Breast Care (Basel)*, 10 (3): 184-188, 2015.
- 26- Innocenti A., Melita D. and Ghezzi S.: Closed-suction drains after subcutaneous mastectomy for gynecomastia: Do they reduce complications? *Aesthetic Plastic Surgery*, No. 5, p. 2118-2126, 2021.
- 27- El-Sabbagh A.H.: Combined approach for gynecomastia. *GMS Interdiscip Plast Reconstr Surg DGPW*, 5: Doc. 10, 2016.