

The Effect of Combining Progressive Tension Sutures with Autologous Platelet Gel Sealant Effect on Reducing Seroma Incidence after Lipoabdominoplasty

AHMAD ELHUSSEIN MOHAMED, M.D.*; MAHMOUD MOHAMED SHAKER ELSAYED, M.Sc.* and ASMAA KAMAL KAMAL ABDELMAOGOOD, M.D.**

The Departments of Plastic Surgery* and Clinical & Chemical Pathology**, Faculty of Medicine, Suez Canal University, Ismailia

Abstract

Background: Seroma is frequently a self-limiting condition; it might have negative consequences such as infection, flap necrosis, wound dehiscence, and spontaneous drainage through the surgical site. Seroma treatment is time-consuming as it may necessitate several sessions of aspirations, probable drain insertion, and revision procedures.

Objective: This study aimed to verify whether combining progressive tension sutures with autologous platelet gel sealant decreased the incidence of seroma formation after lipoabdominoplasty.

Methods: This was a prospective, case-controlled, and randomized clinical study of forty female patients, aged 25-55 years, that was carried out from January 2023 to October 2023. All patients were seen at the plastic surgery outpatient clinic at Suez Canal University Hospital. Patients were allocated randomly into two equal groups: the study group [A] had lipoabdominoplasty combined with progressive tension sutures and autologous platelet gel, while the control group [B] had lipoabdominoplasty alone. A closed suction drain was used in both groups, and total drain output was measured every 24 hours after surgery until the drains were removed. Clinical examinations were used as a subjective assessment at 2, 4, 6, and 8 weeks after surgery, while the incidence of wound disruption or skin sloughing was used as an objective assessment of seroma. The results of the two groups were documented and statistically analysed.

Results: Regarding both subjective and objective assessments of seroma formation, there were statistically significant differences between the two groups. The amount of drain output in lipoabdominoplasty with combined PTS and sealant platelet gel (group A) was considerably lower than the control group (p -value <0.00001). The drain removal time (days) was much longer in group B (the control group), with a statistically significant difference between both groups (p -value <0.00001).

The incidence of wound dehiscence and flap necrosis was recorded only in the control group (B).

Conclusion: Combining progressive tension sutures with autologous platelet gel sealant as an adjuvant in lipoabdominoplasty reduced the incidence of seroma formation after this procedure.

Key Words: Lipoabdominoplasty – Seroma – Prevention.

Disclosure: The authors have no conflict of interest to declare.

Ethical Committee: The study had the approval of the local Institutional Review Board and the Research Ethics Committee, Faculty of Medicine, Suez Canal University with the approval code 5410#. All participants filled a written informed consent to participate in the study.

Introduction

Following a dramatic increase in obesity and different bariatric surgeries [1,2], abdominoplasty is currently one of the most frequently performed aesthetic surgical procedures [3]. Although it has been considered a very effective body contouring procedure, it cannot be considered devoid of complications. The reported total complication rates vary from 4% to 80% [4-9]. Seroma formation, considered the most frequent early complication, occurred following abdominoplasty. The rate of its incidence varies greatly from 5% to 43%; however, most authors agree on an incidence rate of 10% [10,11]. Seroma is defined as an accumulation of fluid in a localized area [12]. It is a well-known risk of surgeries associated with the elevation of massive cutaneous flaps [12-14].

Different explanations have been reported to explain the cause of seroma formation after abdominoplasty. The commonly accepted one is that flap harvesting with concurrent shearing results in the creation of a dead space, followed by inflammation and increased permeability of blood and lymphatic

Correspondence to: Dr. Ahmad Elhusssein Mohamed,
E-Mail: rivercruise85@gmail.com

vessels, resulting in the accumulation of fluid [15-19]. High BMI, significant weight reduction, severe dissection, previous supraumbilical scars, and concurrent liposuction are all risk factors for seroma formation [15,20,21].

Despite the fact that seroma is frequently a self-limiting condition, it might have negative consequences such as infection, flap necrosis, wound dehiscence, and spontaneous drainage through the surgical site [22-25]. Seroma treatment is time-consuming, as it may necessitate several sessions of aspirations, probable drain insertion, and revision procedures. All of these add to patient discomfort, cost, and morbidity [26,27]. If neglected, seroma can cause the growth of pseudo bursa, which is fibrous in nature, resulting in surface irregularities and a bad aesthetic consequence [28,29].

Different preventive measures have been reported to reduce the incidence of seroma after surgeries, including drain insertion [30], non-traumatic handling of the skin flaps [31], the use of postoperative compression garments [32], the application of tissue adhesive materials [33], and the application of progressive tension sutures (PTS). Progressive tension sutures are performed by inserting sutures at regular intervals between the fascia and the abdominal skin flaps, which were introduced briefly by Mladick [34]. Baroudi and Ferreira defined it as 'quilting sutures' to minimize shearing forces and dead space [35].

Pollock and Pollock popularized the term "progressive tension suture" because this approach provides closure of the abdominal flap without any tension by distributing it on each suture as the flap advances from proximal to distal [36-39]. There are several technical alternatives to using PTS. Separate stitches are used by some authors [40], while flowing sutures are used by others [41]. Sutures, both absorbable and non-absorbable, were used [12,36]. Some surgeons regard PTS as a substitute for suction drains, while others correlate both methods with a reduction in seroma production [36].

In numerous surgical situations, autologous platelet gel sealant has been used to promote adhesion of the surface, which reduces the rate of seroma formation after surgeries and its drainage. Its advantages include improved tissue adhesive properties, a lower risk of bleeding, and the extra benefit of enhanced leukocyte concentration [42].

The puffy coat of platelet and leukocyte enriched plasma appears to have a number of beneficial effects. Platelets and dense granules contain cytokines and mediators that can increase angiogenesis and synthesis of collagen, thereby promoting healing of the soft tissue. Platelet-derived epidermal growth factor, platelet-derived growth factor, transforming growth factor, fibroblast

growth factor, and platelet-derived angiogenesis factor are examples of these factors [43-45].

Several previous studies evaluated the effects of progressive tension sutures and fibrin sealants in the prevention of seroma, but the combination of both had not been evaluated [34-39]. As platelet gel had the same adhesive properties as fibrin glue but with a low cost and was readily prepared from patients own blood, preventing the risk of compatibility side effects and the chance of infection transmitted by blood and its components [42].

In this study, the combination of progressive tension sutures with autologous platelet gel sealant was evaluated to verify its effectiveness in reducing the incidence of seroma formation after lipoabdominoplasty.

Patients and Methods

After receiving ethical committee approval (the study had the approval of the local Institutional Review Board and the Research Ethics Committee with the approval code 5410#), and their privacy was assured. This was a case-controlled, and randomized clinical study of forty female patients, aged 25-55 years, that was carried out from January 2023 to October 2023. All patients were seen at the plastic surgery outpatient clinic, Suez Canal University Hospital.

Patients were allocated randomly into two equal groups: The study group [A] had lipoabdominoplasty combined with progressive tension sutures and autologous platelet gel, while the control group [B] had lipoabdominoplasty alone.

Inclusion criteria: Female patients aged between 25 and 55 presented with type IV B Rohrich deformities (considerable skin and fat excess with rectus muscle divergence).

Exclusion criteria: Patients who had a past history of any chronic disease such as diabetes mellitus, liver or renal disorder, a known bleeding disorder, smokers, or had a body mass index (BMI) greater than 35 were omitted from participation in this study.

The following data were obtained from each patient: Age, height, weight, body mass index, and previous abdominal operation. The following items were recorded after the procedure: Operation time, volume of lipoaspirate, weight of tissue resected, the total volume of drain output per day, the duration required for drain removal, hospital stay, and the presence of any postoperative adverse effects in the form of seroma formation detected by ultrasonography, dehiscence of the abdominal wound, partial necrosis of the edge of the umbilical wound, and the occurrence of wound infection.

A single preoperative dose of prophylactic antibiotic (3rd generation cephalosporin) was given to all patients 15 to 30 minutes before surgery. All patients were operated upon under spinal anesthesia. At first Liposuction was done as usual then an electrocautery device was used to separate the flap of the anterior abdominal wall from the musculoaponeurotic layer. After making the suprapubic incision and reaching the umbilical zone as previously labelled, the navel was separated from the skin.

Laterally, the flap was dissected from the aponeurosis of the external oblique muscles and then superior all the way up to the xiphoid process through a constructed 10cm wide midline supraumbilical tunnel. At this point, the myofascial plication was set. Plication of the wide rectus abdominis muscle (WRAP) has begun. Regarding plication, the xiphoid process was the superior limit, while the symphysis pubic was the inferior limit. The resected tissue demarcation and excision are the next steps.

The shape of the relocated umbilicus is represented by a vertical ellipse of skin. The skin and subcutaneous tissue below the skin's surface around the new site of the umbilicus were removed vertically.

In both groups, the surgical procedure was the same except that in group A the following steps were added: The autologous platelet gel was prepared by taking 1 unit of blood, and the platelets were extracted through centrifugation. One unit of blood will provide around 40 mL of platelets in

125mL. Their level of fibrinogen ranges from 2 to 4mg/mL. The count of the platelets ranges from 5 to 10 $\times 10^8$ /mL. The full duration of the process takes about 22 minutes. Then 7mL of platelets were extracted into a 10-mL syringe. The thrombin-calcium solution was then injected at a concentration of 1 to 2mL, leaving 1 to 2mL of "air space" in the syringe. The syringe was then rotated back and forth gradually. The solution begins to gel after 30 to 60 seconds [42].

Between the musculoaponeurotic layer and the abdominal skin flap, progressive tension sutures (Vicryl 0) were placed. The initial suture was inserted loosely in the midline at the most upper point of the dissection. In most cases, no more than three sutures were placed above the umbilicus, then half of the prepared autologous platelet gel was sprayed between the supraumbilical quilting sutures, and then all of them were tightened.

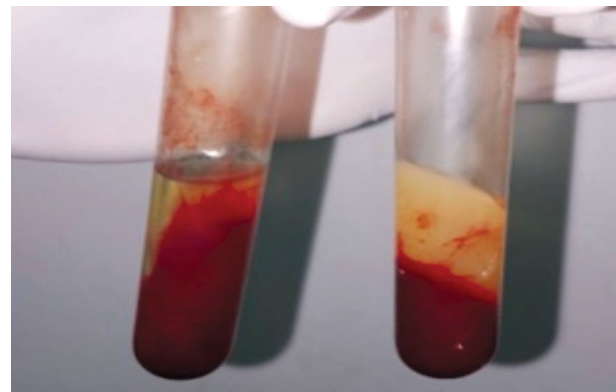


Fig. (1): Autologous platelet gel.

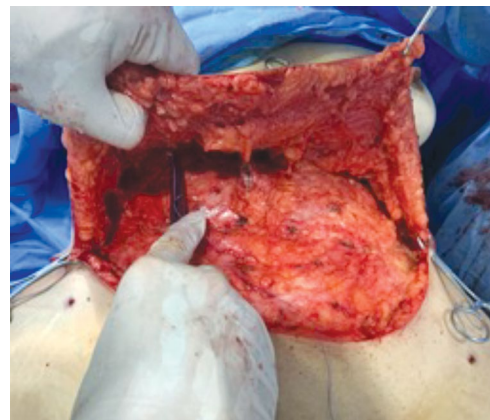
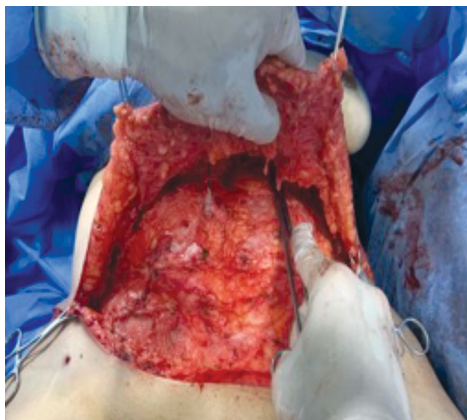


Fig. (2): Application of extra progressive tension sutures.

After the umbilicus has been stabilised, advancement of the distal skin flap was done with progressive tension suture, and then the row of midline sutures was carried on till the infraumbilical zone with 2cm spaced in-between. To account for the extent of dissection, the lateral sutures were placed with greater distance and in a randomly symmetri-

cal pattern. On average, 3 to 5 sutures were placed laterally on each side of the midline. The other half of the prepared autologous platelet gel was sprayed between the infraumbilical quilting sutures before tightening all of them. After the abdominal flap was pulled down, compression was applied for five minutes all over it.

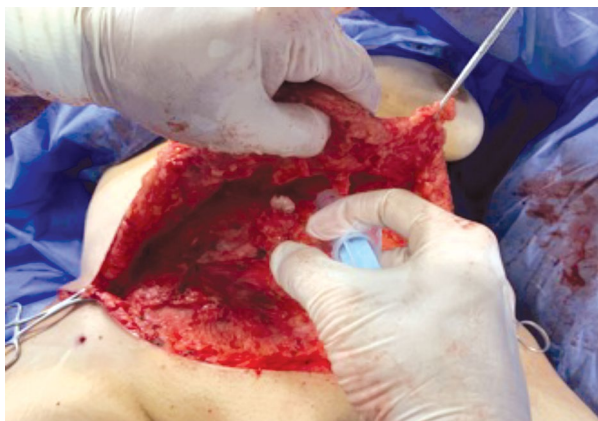

Fig. (3): Application of platelet gel.

Two suction drains (18F) were placed for each patient in both groups. Each drain was placed and withdrawn laterally and had been held in place with a 2/0 silk suture. Finally, skin closure was performed using 3/0 monocryl.

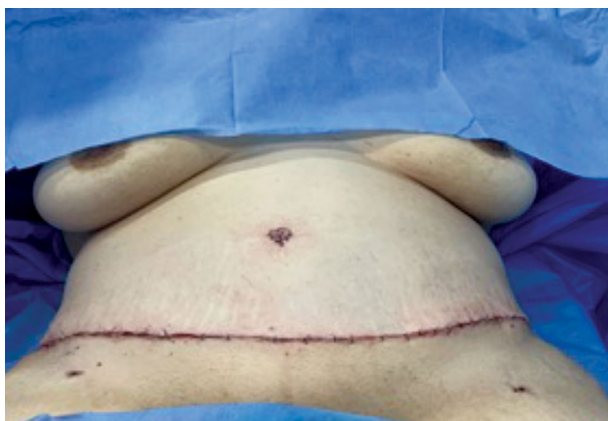


Fig. (4): Immediate postoperative result.

The patients were told to rest for one day in a semi flexed position. Patients were given a prophylactic anticoagulant. (BMI greater than 30). The urinary catheter was removed on the first day postoperatively. Patients were taught to move with a forward lean under observation. Patients were directed to wear compression garments for three months beginning on the first day postoperatively.

The total volume of drain output was measured every 24 hours after surgery until the drains were removed. Clinical evaluations as a subjective assessment at 2, 4, 6, and 8 weeks after surgery were used to detect seroma by reviewing symptoms of seroma, including bulginess, distention, and a sense of fluid collection, in addition to signs including palpation and percussion of the wave sign. The incidence of wound disruption or skin sloughing was

used as an objective assessment of seroma and the outcome of the procedure, as it was a simple method without any additional cost.

Ethical consideration:

The study had the approval of the local Institutional Review Board and the Research Ethics Committee, Faculty of Medicine, Suez Canal University with the approval code 5410#.

Statistical analysis:

The obtained results were analyzed using IBM SPSS software package version 20.0. Numbers and percentages were used to represent categorical data. Chi-square test was used to detect the association between the categorical variables. Alternatively, Fisher's exact test was used when more than 20% of the cells have expected count less than five. For continuous data, they were investigated for normality by the Shapiro-Wilk test. Quantitative data were represented as range (minimum and maximum), mean, standard deviation and median Student *t*-test was applied to compare two groups for normally distributed quantitative variables on the other hand Mann Whitney test was used to compare two groups for not normally distributed quantitative variables. The statistical significance of the detected results was judged at the 5% level.

Results

In this study, forty female patients aged 25-55 years, with a mean of 41 ± 5 years for group A and 41.5 ± 6.2 years for group B, The patients had type IV B Rohrich deformities (considerable skin and fat excess with rectus muscle divergence) with a body mass index ranging from 25 to 35 kg/m² on average (30.9 ± 2.9 kg/m² for group A and 30.9 ± 3.7 kg/m² for group B) (Table 1).

The age (*p*-value is 0.759) and BMI (*p*-value value is 0.962) of both groups were consistent, with no statistically significant findings between both groups (Table 1).

There were significant differences between both groups in terms of operation time (*p*-value = 0.004) and postoperative hospital stay (*p*-value = 0.001); while group A's mean operation time (3.6 ± 0.4 hours) was longer than group B's (3.2 ± 0.3 hours), their mean postoperative hospital stays (2.5 ± 0.7 days) were shorter than theirs (3.5 ± 0.5 days).

In terms of subjective clinical assessment of seroma formation, there were considerable differences between both groups in terms of seroma formation and drain output (Figs. 2,3). The mean amount of drain output in lipoabdominoplasty combined with PTS and sealant platelet gel (group A) was 384.5 ± 34.8 ml in comparison with the control group (group B), which was 494.5 ± 78.9 ml. The result was statistically significant with a *p*-value <0.001. Also, there were significant differences

between both groups in terms of drain removal time (p -value 0.001).

Regarding objective assessment of seroma formation through incidence of wound disruption or skin sloughing, wound dehiscence and partial sloughing of the abdominal flap were higher in the control group (B) with a rate of 10% than in the study group (A), which had no recorded incidence of such complications.

By ultrasonographic assessment, the incidence of seroma formation was 5% in group A patients, while it was 20% in group B patients.

In either group of patients, there were no other significant complications, such as deep venous thrombosis.

Figure (8) shows the preoperative and postoperative photos for an example of one patient in study group A.

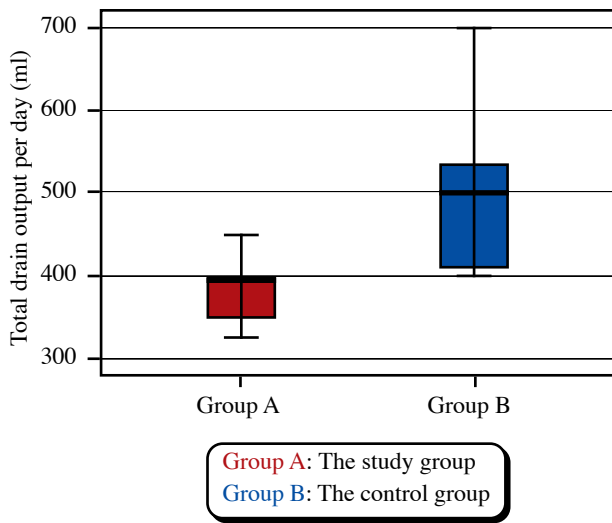


Fig. (5): Comparison between both groups according to total drain output per day (ml).

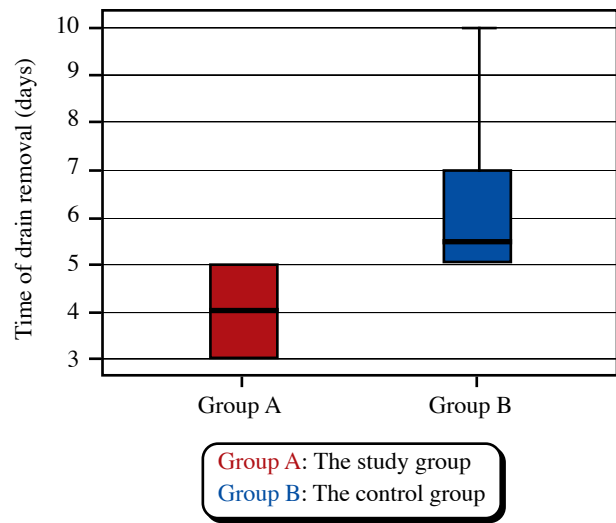


Fig. (6): Comparison between both groups according to time of drain removal (days).

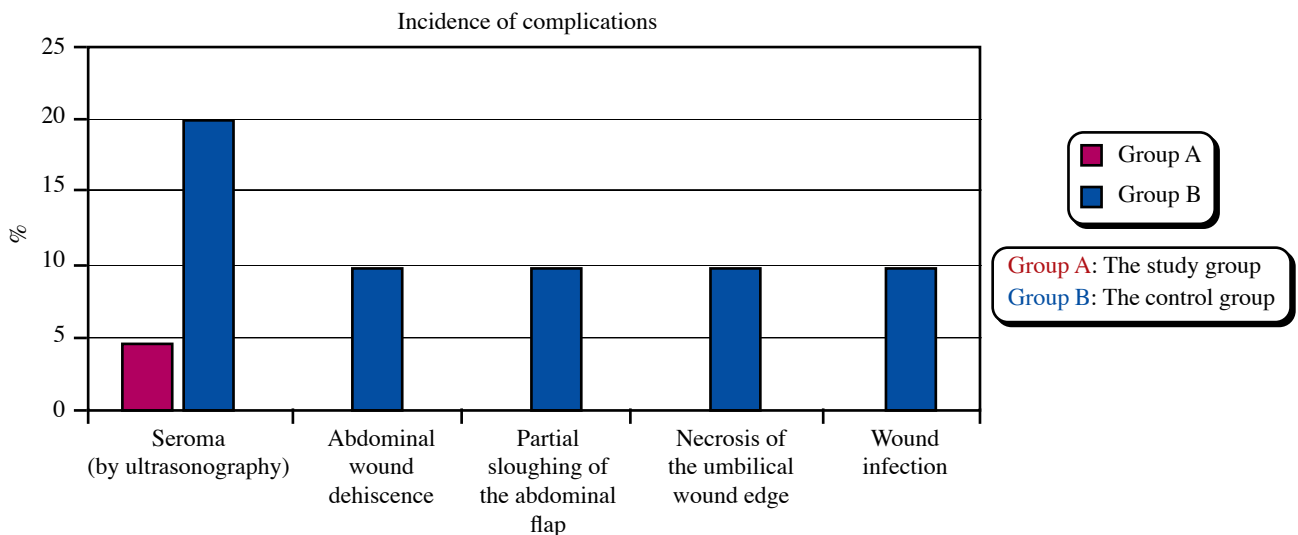


Fig. (7): Comparison between both groups according to complication.

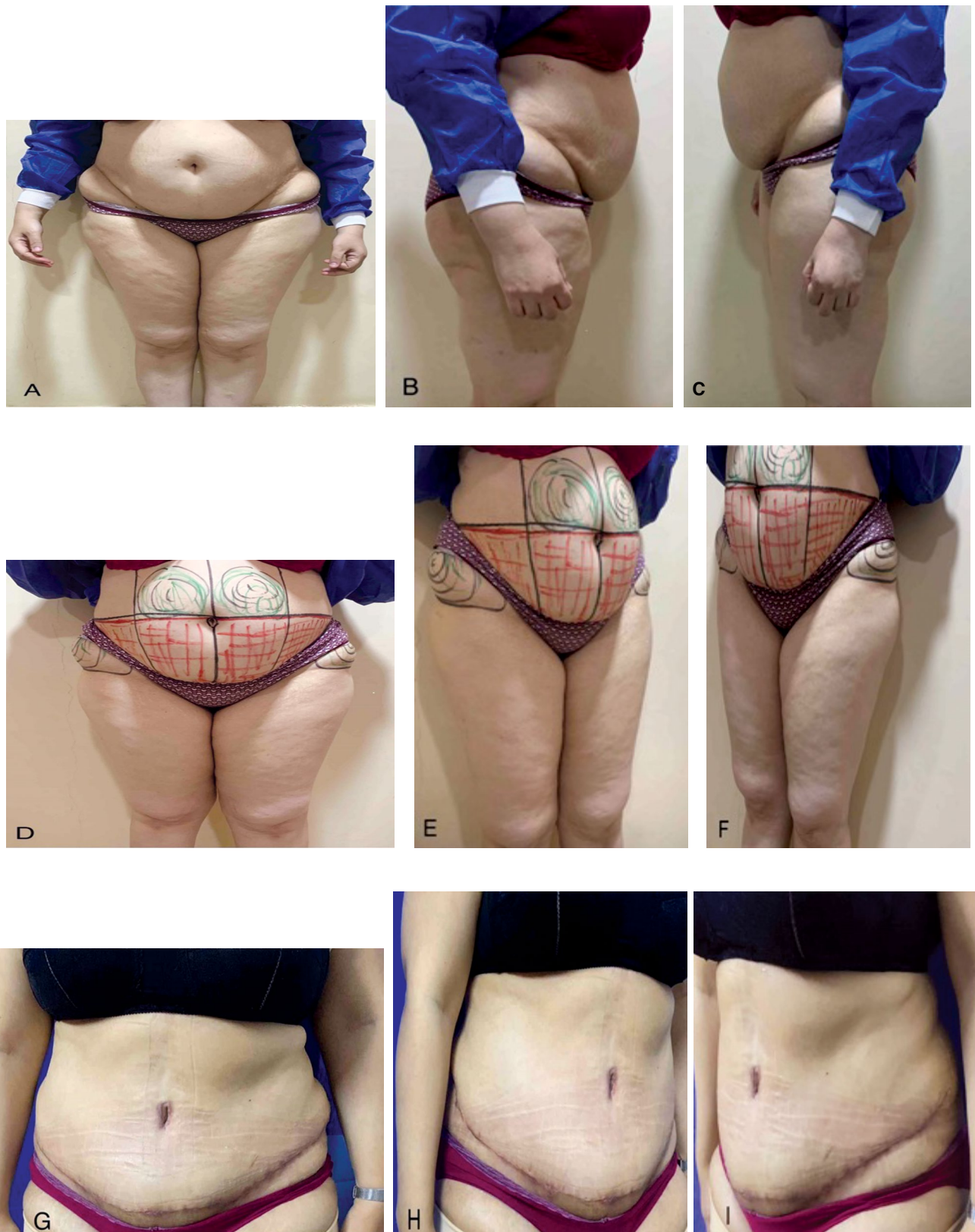

Fig. (8): 39-year-old female patient, married, [A, B, C] illustrate the preoperative photos, [D, E, F] illustrate the preoperative marking, [G, H, I] illustrate the postoperative photos.

Table (1): Comparison between both groups according to different parameters.

| | Group A Study group (n = 20) | Group B Control group (n = 20) | Test of Sig. | P |
|---|------------------------------------|--------------------------------------|-----------------------|-----------|
| <i>Age (years):</i> | | | | |
| Mean ± SD. | 41±5 | 41.5±6.2 | t=0.309 | 0.759 |
| Median (Min. – Max.) | 40 (34-50) | 41 (30-52) | | |
| <i>BMI (kg/ m²):</i> | | | | |
| Mean ± SD. | 30.9±2.9 | 30.9±3.7 | t=0.048 | 0.962 |
| Median (Min. – Max.) | 31 (25-35) | 31.50 (25-35) | | |
| <i>Operation Time (hours):</i> | | | | |
| Mean ± SD. | 3.6±0.4 | 3.2±0.3 | t=3.096* | 0.004* |
| Median (Min. – Max.) | 3.50 (3-4) | 3 (3-3.5) | | |
| <i>Lipoaspirate volume (ml):</i> | | | | |
| Mean ± SD. | 1775±476.7 | 1860±546.2 | t=0.524 | 0.603 |
| Median (Min. – Max.) | 1950 (800-2500) | 1950 (900-2700) | | |
| <i>Resected weight (gm):</i> | | | | |
| Mean ± SD. | 1722.5±452.9 | 1965±431.9 | t=1.733 | 0.091 |
| Median (Min. – Max.) | 1700 (1000-2500) | 2000 (1300-2800) | | |
| <i>Post-operative hospital stay (days):</i> | | | | |
| Mean ± SD. | 2.5±0.7 | 3.5±0.5 | U=60.500* | <0.001* |
| Median (Min. – Max.) | 3 (1-3) | 3 (3-4) | | |
| <i>Total drain output per day (ml):</i> | | | | |
| Mean ± SD. | 384.5±34.8 | 494.5±78.9 | U=39.500* | <0.001* |
| Median (Min. – Max.) | 395 (325-450) | 500 (400-700) | | |
| <i>Time of drain removal (days):</i> | | | | |
| Mean ± SD. | 4±0.9 | 6.2±1.5 | U=35.000* | <0.001* |
| Median (Min. – Max.) | 4 (3-5) | 5.5 (5-10) | | |
| <i>Complication:</i> | | | | |
| No | 18 (90%) | 15 (75%) | χ ² =1.558 | FEp=0.407 |
| Yes | 2 (10%) | 5 (25%) | | |
| - Seroma (by ultrasonography) | 1 (5%) | 4 (20%) | χ ² =2.057 | FEp=0.342 |
| - Abdominal wound dehiscence | 0 (0%) | 2 (10%) | χ ² =2.105 | FEp=0.478 |
| - Partial sloughing of the -Abdominal flap | 0 (0%) | 2 (10%) | χ ² =2.105 | FEp=0.478 |
| - Necrosis of the umbilical wound edge | 0 (0%) | 2 (10%) | χ ² =2.105 | FEp=0.487 |
| - Wound infection | 0 (0%) | 2 (10%) | χ ² =2.105 | FEp=0.487 |

SD: Represent the standard deviation.

t : Represent the student t-test.

U : Represent the Mann Whitney test.

χ²: Represent the Chi square test.

FE: Represent the Fisher Exact

p : Represent the p-value for comparing between both groups.

* : Represent the Statistically significant at p≤0.05.

Discussion

Postoperative seroma is regarded as one of the most prevalent complications following lipo-abdominoplasty. The most common factors responsible for seroma formation are the degree of dissection of the abdominal flaps, increased body mass index, and the addition of liposuction or other therapies with standard abdominoplasty [11].

A number of preventive measures, such as drain insertion [30], non-traumatic handling of skin flaps

[31], the use of compression garments [32], the application of tissue adhesive materials [33], and the application of progressive tension sutures (PTS), have been suggested to lower the incidence of post-operative seroma.

Progressive tension sutures should be distinguished from the quilting sutures explained by Baroudi and Ferreira [34]. To close the dead space, they described a suture technique that approximates the full-thickness skin flap and deep fascia while progressive tension sutures are applied while

advancing the flap, resulting in progressive tension on every suture. Furthermore, as the deep fat has been greatly reduced, sutures are applied from the superficial to the deep fascia.

Autologous platelet gel sealant has been utilized to improve adhesion of the surface in a variety of surgical circumstances, lowering the need for drainage and the incidence of post-operative seroma. Its benefits include improved tissue adhesive qualities, a lower risk of bleeding, and increased leukocyte concentration [42].

Cruz-Korchin et al. [45] investigated the possible benefits of using fibrin glue in abdominoplasty procedures in 2005. Their research discovered that using fibrin glue considerably decreased the period of drainage. When the findings of this study were matched to those of theirs, it was observed that the time of drain elimination (days) was nearly the same as that of our patients in Group A.

Bercial et al. [46] evaluated the application of PTS sutures, suction drains, and fibrin glue in 43 patients following lipoabdominoplasty in 2012 to detect the best strategy for reducing the formation of postoperative seroma. On the 15th day postoperatively, there was a significant difference in the volume of seroma across the 3 groups (p -value of 0.05). There were no considerable differences between groups in the volume of seroma on the post-operative day 30 ($p=0.15$) or the difference in % in the volume of seroma between the post-operative days 15 and 30 ($p=0.56$).

Their findings argue against the findings of this study about the effect of combining PTS with the autologous platelet gel sealant to reduce the occurrence of post-abdominoplasty seroma. The absence of a suction drain contributed to the disparities in the results. This reflects the importance of using a drain with fibrin glue to reduce the incidence of postoperative seroma formation in abdominoplasty seroma.

Andrades et al. [36] conducted a prospective, double-blind, randomized, controlled clinical study comparing four groups: Group 1 (control group without drain insertion or application of progressive tension sutures), Group 2 (only application of progressive tension sutures), Group 3 (sole insertion of drains), and Group 4 (combined application of progressive tension sutures and drain insertion). By omitting the groups that did not employ drains, group 4 (with the application of progressive tension sutures) had considerably lower drain output than group 3 (without the application of progressive tension sutures) throughout the first week postoperatively ($p<0.0001$). The results of their study matched the results of this study regarding the considerable decrease in the volume of post-operative drainage.

The results obtained in this study using platelet sealant are similar to those obtained in earlier studies that found fibrin sealant to be advantageous in aiding hemostasis and reducing seroma formation [36,47,48], but autologous platelet gel sealant is more accessible and cheaper than fibrin sealant.

Conclusion:

According to the findings of both subjective and objective methods that were used in this study, combining progressive tension sutures with autologous platelet gel sealant reduced the incidence of seroma formation after lipoabdominoplasty.

Financial issues: There is no financial interest to declare in relation to the content of this article. No outside findings were received.

References

- 1- The Aesthetic Society's Cosmetic Surgery National Data Bank: Statistics 2020. *Aesthet Surg. J.*, 41 (Supplement 2): 1-16, 2021.
- 2- State Public Health Statistics | America's Health Rankings. <http://www.americashealthrankings.org/explore/2015-annual-report/measure/Obesity/state/ALL>. Accessed May 7, 2016.
- 3- Cosmetic Surgery National Data Bank Statistics. *Aesthetic Surg. J.*, 36 (Suppl 1): 1-29, 2016.
- 4- Neaman K.C. and Hansen J.E.: Analysis of complications from abdominoplasty: A review of 206 cases at a university hospital. *Ann. Plast. Surg.*, 58: 292-298, 2007.
- 5- Teimourian B. and Adham M.N.: A national survey of complications associated with suction lipectomy: What we did then and what we do now. *Plastic Reconstructive Surg.*, 105 (5): 1881-1884, 2000.
- 6- Hurvitz K.A., Olaya W.A., Nguyen A., et al.: Evidence-based medicine: Abdominoplasty. *Plast. Reconstr. Surg.*, 133: 1214-1221, 2014.
- 7- Floros C. and Davis P.K.: Complications and long-term results following abdominoplasty: A retrospective study. *Br. J. Plastic Surg.*, 44 (3): 190-194, 1991.
- 8- Cheng L.F., Lee J.T., Hsu H. and Wu M.S.: Simple skin-stretching device in assisted tension-free wound closure. *Ann. Plast. Surg.*, 78 (3 Suppl 2): S52-S57, 2017.
- 9- Van Uchelen J.H., Werker P.M. and Kon M.: Complications of abdominoplasty in 86 patients. *Plastic Reconstructive Surg.*, 107 (7): 1869-1873, 2001.
- 10- Nahas F.X., Ferreira L.M. and Ghelfond C.: Does quilting suture prevent seroma in abdominoplasty? *Plastic Reconstructive Surg.*, 119 (3): 1060-1066, 2007.
- 11- Zimman O.A., Butto C.D. and Ahualli P.E.: Frequency of seroma in abdominal lipectomies. *Plastic Reconstructive Surg.*, 108 (5): 1449-1451, 2001.

- 12- Lee K.T. and Mun G.H.: Fibrin Sealants and Quilting Suture for Prevention of Seroma Formation Following Latis-simus Dorsi Muscle Harvest: A Systematic Review and Meta-analysis. *Aesthetic Plastic Surg.*, 39 (3): 399-409, 2015.
- 13- Stewart K.J., Stewart D.A., Coghlan B., Harrison D.H., Jones B.M. and Waterhouse N.: Complications of 278 consecutive abdominoplasties. *J. Plastic Reconstructive Aesthetic Surg.*, 59 (11): 1152-1155, 2006.
- 14- Coon D., Gusenoff J.A., Kannan N., El Khoudary S.R., Naghshineh N. and Rubin J.P.: Body mass and surgical complications in the post bariatric reconstructive patient: Analysis of 511 cases. *Ann. Surg.*, 249 (3): 397-401, 2009.
- 15- Kim J. and Stevenson T.R.: Abdominoplasty, liposuction of the flanks, and obesity: analyzing risk factors for seroma formation. *Plastic Reconstructive Surg.* ;117(3): 773-781, 2006.
- 16- Araco A., Gravante G., Araco F., Sorge R. and Cervelli V.: Postoperative seromas after abdominoplasty: A retrospective analysis of 494 patients and possible risk factors. *Plastic Reconstructive Surg.*, 123 (4): 158e-159e, 2009.
- 17- Pogson C.J., Adwani A. and Ebbs S.R.: Seroma following breast cancer surgery. *Eur. J. Surg. Oncol.*, 29 (9): 711-717, 2003.
- 18- Mohammad J.A., Warnke P.H. and Stavrayk W.: Ultra-sound in the diagnosis and management of fluid collection complications following abdominoplasty. *Ann. Plastic Surg.*, 41 (5): 498-502, 1998.
- 19- Nasr M.W., Jabbour S.F., Mhaweij R.I., Elkhoury J.S. and Sleilati F.H.: Effect of Tissue Adhesives on Seroma Incidence After Abdominoplasty: A Systematic Review and Meta-Analysis. *Aesthetic Surg. J.*, 36 (4): 450-458, 2016.
- 20- Matarasso A.: Liposuction as an adjunct to a full abdominoplasty. *Plastic Reconstructive Surg.*, 95 (5): 829-836, 1995.
- 21- Teimourian B.: Management of seroma in abdominoplasty. *Aesthetic Surg. J.*, 25 (5): 510-511, 2005.
- 22- Sforza M., Husein R., Andjelkov K., Rozental-Fernandes P.C., Zaccheddu R. and Jovanovic M.: Use of Quilting Sutures During Abdominoplasty to Prevent Seroma Formation: Are They Really Effective? *Aesthetic Surg. J.*, 35 (5): 574-580, 2015.
- 23- Krueger J.K. and Rohrich R.J.: Clearing the smoke: the scientific rationale for tobacco abstention with plastic surgery. *Plastic Reconstructive Surg.*, 108 (4): 1063-1077, 2001.
- 24- Di Martino M., Nahas F.X., Barbosa M.V.J., et al.: Seroma in lipoabdominoplasty and abdominoplasty: A comparative study using ultrasound. *Plastic Reconstructive Surg.*, 126 (5): 1742-1751, 2010.
- 25- Ersek R.A. and Schade K.: Subcutaneous pseudo bursa secondary to suction and surgery. *Plastic Reconstructive Surg.*, 85 (3): 442-445, 1990.
- 26- Roje Z., Roje Z., Karanović N. and Utrobičić I.: Abdominoplasty complications: A comprehensive approach for the treatment of chronic seroma with pseudo bursa. *Aesthetic Plastic Surg.*, 30 (5): 611-615, 2006.
- 27- Toman N., Buschmann A. and Muehlberger T.: [Fibrin glue and seroma formation following abdominoplasty]. *Chir Z Für Alle Geb Oper Medizen*, 78 (6): 531-535, 2007.
- 28- Zecha P.J. and Missotten F.E.: Pseudocyst formation after abdominoplasty-extravasations of Morel-Lavallée. *Br. J. Plastic Surg.*, 52 (6): 500-502, 1999.
- 29- Pilone V., Vitiello A., Borriello C., Gargiulo S. and Forestieri P.: The use of a fibrin glue with a low concentration of thrombin decreases seroma formation in post bariatric patients undergoing circular abdominoplasty. *Obesity Surg.*, 25 (2): 354-359, 2015.
- 30- Khan U.D.: Risk of seroma with simultaneous liposuction and abdominoplasty and the role of progressive tension sutures. *Aesthetic Plast Surg.*, 32: 93-99, 2008.
- 31- Stoff A., Reichenberger M.A. and Richter D.F.: Comparing the ultrasonically activated scalpel (Harmonic) with high frequency electrocautery for postoperative serous drainage in massive weight loss surgery. *Plastic Reconstructive Surg.*, 120 (4): 1092-1093, 2007.
- 32- Jabbour S., Awaida C. and Mhaweij R.: Does the addition of progressive tension sutures to drains reduce seroma incidence after abdominoplasty? A systematic review and meta-analysis. *Aesthet. Surg. J.*, 37: 440-447, 2017.
- 33- Bercial M.E., Sabino Neto M., Calil J.A., et al.: Suction drains, quilting sutures, and fibrin sealant in the prevention of seroma formation in abdominoplasty: Which is the best strategy? *Aesthetic Plast Surg.*, 36: 370-373, 2012.
- 34- Mladick R.A.: Progressive tension sutures to reduce complications in abdominoplasty. *Plastic Reconstructive Surg.*, 107 (2): 619, 2001.
- 35- Baroudi R. and Ferreira C.A.: Seroma: How to avoid it and how to treat it. *Aesthetic Surg J.*, 18 (6): 439-441, 1998.
- 36- Fang C.L., Hsu C.H., Yang H.Y., et al.: Using of progressive tension sutures and close drainage can prevent seroma occurrence in abdominal wall repair with mesh or direct repair after DIEP flap harvesting. *J. Taiwan Soc. of Plast Surg.*, 27: 1-11, 2018.
- 37- Andrades P., Prado A., Danilla S., et al.: Progressive tension sutures in the prevention of post abdominoplasty seroma: A prospective, randomized, double-blind clinical trial. *Plastic Reconstructive Surg.*, 120 (4): 935-946-951, 2007.
- 38- Pollock H. and Pollock T.: Progressive tension sutures: A technique to reduce local complications in abdominoplasty. *Plastic Reconstructive Surg.*, 105 (7): 2583-2586-2588, 2000.
- 39- Pollock T. and Pollock H.: Progressive tension sutures in abdominoplasty. *Clin. Plastic Surg.*, 31 (4): 583-589, vi, 2004.

- 40- Antonetti J.W. and Antonetti A.R.: Reducing seroma in outpatient abdominoplasty: Analysis of 516 consecutive cases. *Aesthetic Surg J.*, 30 (3): 418-425, 2010.
- 41- Gutowski K.A. and Warner J.P.: Incorporating barbed sutures in abdominoplasty. *Aesthetic Surg. J.*, 33 (3 Suppl): 76S-81S, 2013.
- 42- Melmed E.P.: Autologous platelet gel in plastic surgery. *Aesthetic Surg. J.*, Jul. 21 (4): 377-9. doi: 10.1067/maj.2001.118027. PMID: 19331920, 2001.
- 43- Czinn E.A. and Chediak J.R.: Coagulation and hemostasis. In: Salem M.R., ed. *Blood Conservation in the Surgical Patient*. Baltimore; Williams & Wilkins, 45-51, 1996.
- 44- Nasr M.W., Jabbour S.F., Mhaweij R.I., Elkhoury J.S. and Sleilati F.H.: Effect of Tissue Adhesives on Seroma Incidence. Quoted from Pierce G.F., Cande Berg J., Rudolph R., et al. *Abdominoplasty: A Systematic Review and Meta-Analysis*. *Aesthet. Surg. J.*, 36 (4): 450-458, 2016.
- 45- Cruz-Korchin N. and Korchin L.: The Use of Fibrin Sealant (Tisseel) in Abdominoplasty: 17. *Plastic Reconstructive Surg.*, 116 (3): 23-5, 2005.
- 46- Bercial M.E., Neto M.S., Calil J.A., Rossetto L.A. and Ferreira L.M.: Suction Drains, Quilting Sutures, and Fibrin Sealant in the Prevention of Seroma Formation in Abdominoplasty: Which is the Best Strategy? *Aesthetic Plastic Surg.*, 36 (2): 370-3, 2012.
- 47- Greenberg B.M. and Koumanis D.: *Fibrin Sealants: Use in Abdominoplasty*, 2006.
- 48- Toman N., Buschmann A. and Muehlberger T.: Fibrinkleber und Serombildung Nach Abdominoplasty Chirurg., 78 (6): 531-5, 2007.