

Liposuction Assisted De-Epithelialization Pull-Through Technique for Management of Grade IIB and III Gynecomastia

ROWAN ALMODDATHER ELHADIDY, M.Sc.*; AHMED ABDELMONEM IBRAHIM, M.D.**;
OMAR OSAMA SHOUMAN, M.D.* and AHMED ABDEL FATTAH EL SHERIFA, M.D.*

The Departments of Plastic and Reconstructive Surgery and General Surgery**, Faculty of Medicine, Mansoura University*

Abstract

Background: Gynecomastia is an abnormal and benign enlargement of male breast tissue. It occurs as a result of an imbalance between estrogen and androgen levels that may be due to a physiological or pathological cause. Multiple surgical approaches have been recommended to manage this problem. It is widely accepted that liposuction solely or when combined with subcutaneous mastectomy is effective for the management of low to intermediate grades of gynecomastia. However, liposuction along with subcutaneous mastectomy gives unsatisfactory results in high grades where there is excess redundant skin that needs excision. Several skin incisions have been mentioned in literature for excision of excess skin, however, some of these are accompanied by unaesthetic scars.

Objective: To assess the outcome of surgical correction of high grades of gynecomastia in a single-stage procedure.

Patients and Methods: We conducted a prospective analysis on 20 patients with grades IIB or III gynecomastia who underwent single-stage procedures. Photographs were clinically evaluated by two independent surgeons with respect to chest contour, symmetry, scar, and residual ptosis. Patient satisfaction was surveyed regarding chest contour and scar appearance.

Results: Statistical analysis revealed a significant improvement in patient's clinical measurements after operation, good doctor's scoring and patient satisfaction scoring among studied cases, and accepted complication rates.

Conclusions: The current approach eliminates the need for skin resection in a second surgery, permits immediate skin recontouring, and achieves an acceptable aesthetic scar.

Key Words: Gynecomastia – Circum-areolar incision – Gland excision – Grades IIB and III – Scar.

Ethical Committee: The study was approved by Ethical Committee of Institutional Review Board (IRB), Mansoura Faculty of Medicine (code number MS.22.03.1925).

Disclosure: No conflict of interest, no funding.

Correspondence to: Dr. Rowan Almoddather Elhadidy,
E-Mail: rowan_279@live.com

Introduction

Gynecomastia is an overdevelopment of the breast tissue among men, simulating that of females [1]. The development of feminine breast contour in men intensely interferes with social life and could be accompanied by considerable emotional discomfort and embarrassment, among teenagers and young men.

Several classifications have been proposed. The widely used classification, defined by Hoffman and Simon, is mainly reliant on the surgical needs of the patient: Grade I, mild enlargement only; grade IIA, moderate enlargement only; grade IIB, moderate enlargement with excess skin; grade III, extensive enlargement with considerable excess skin [2].

A lot of techniques for the surgical management of gynecomastia are defined. The first reported surgical procedure was the excision of the excess tissue via a single sub-mammary incision described by Paulus Ageineta (690bc to 625bc) [3]. Because of the importance of acquiring good cosmetic results and restoring a masculine chest contour while avoiding undesirable scars and skin retraction, plastic surgeons are now choosing to make the incision in the areolar region, as defined by Webster in 1946 [4].

Liposuction alone is effective in the treatment of fibrous low-grade gynecomastia, and intermediate grades of gynecomastia [5]. The surgical management of high-grade gynecomastia (Simon's grade IIB, III) has remained difficult as liposuction and traditional subcutaneous mastectomy with no skin excision have often been associated with considerable residual skin redundancy, needing a second surgery for skin excision [6].

The perfect approach is planned to decrease the breast volume as well as to attain a satisfactory breast with subsequent restoration of masculine

chest contour via resection of excessive glandular and fatty tissues, and excess skin, avoiding unpleasant postsurgical scarring to the chest [7,8]. A single-stage procedure including liposuction, gland excision, and circum-areolar skin resection is performed as well as purse-string skin closure to limit the scar to the circum-areolar area [9].

We aim in the current study to assess the efficacy of liposuction followed by peri-areolar de-epithelialization of excess skin and then gland excision by pull-through technique to manage high grades of gynecomastia with skin redundancy.

Patients and Methods

This study was conducted on a total of 20 Egyptian cases with grade IIB or III gynecomastia of different ages from the period between December 2021 and December 2022. All patients were admitted to the Plastic, Burn, and Reconstructive Surgery Center of Mansoura University.

The study included patients with GIIB or GIII, according to Simon's grading presenting to our clinic with skin excess and glandular elements. We excluded patients with massive weight loss, with excessive redundant skin over the lateral chest wall, with signs suggesting secondary gynecomastia as liver disease, renal failure, or endocrinological diseases, or patients with previous breast reduction surgery.

Each patient received a detailed explanation about the procedure, the site of the scar, and possible complications. Informed consents were obtained from all patients. History taking and adequate clinical examination were done to exclude secondary gynecomastia. Routine laboratory investigations were requested.

Photo documents were taken in three views: Anteriorly, laterally, and oblique. Clinical measurements included the distances from the sternal notch to the nipple-areola complex (NAC), the mid-clavicular line to the nipple-areola complex, the inter-areolar distance, and the skin pinch at the mid-clavicular line.

Skin markings were performed with the patient in an upright position. They included the midsternal line in addition to the pectoral line, inframammary fold, and posterior axillary line to delineate the pectoral area. An inner ring surrounding the NAC was outlined then another circum-areolar circle representing the epidermal ring to be de-epithelialized was drawn 1.5-2cm from the outlined NAC. However, in cases with a larger diameter of areola than normal, the de-epithelialized area was extended to reach a near-normal complex diameter. (Fig. 1-A).

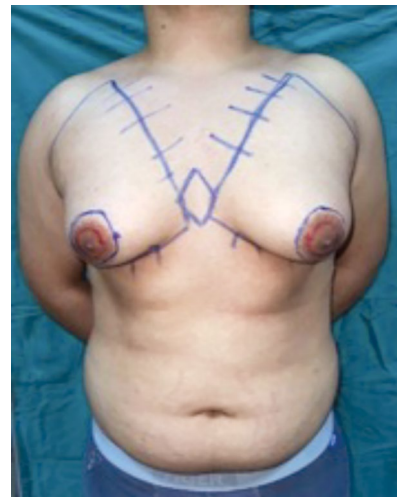

Fig. (1-A): Preoperative marking, outlining the pectoral area and the two circum-areolar rings denoting the area to be de-epithelialized.

Surgical technique: The approach was conducted under general anesthesia with the patient in a supine position and arms abducted 90 degrees from the chest. All the above demarcated areas were infiltrated with approximately 500-750ml of a solution made with either 0.9% Saline or Ringer's Lactate mixed with 1mg of epinephrine for every 1000cc through a 2-3mm skin incision at the anterior axillary line. Liposuction was conducted in 2 planes: Deep and superficial to breast parenchyma. Special consideration was taken while performing liposuction in the expected de-epithelialized area and below NAC, avoiding being markedly superficial to preserve the sub-dermal plexus and vascularity.

Then, the area between the concentric circum-areolar rings was de-epithelialized carefully to avoid compromising the sub-dermal blood flow to the NAC (Fig. 2-A). The residual palpable glandular tissue was situated mainly below the areolar area and was excised by a pull-through maneuver through a snip incision at the lower edge of the de-epithelialized area at 5 to 7 o'clock position, leaving 2cm tissue attached underneath the areola to evade saucer shaped deformity or ischemia of the areola. Adequate hemostasis was ensured, and we didn't need to use drains in our cases. (Fig. 2-B).

Finally, the transdermal incision was closed using PDS 3/0 followed by purse string sutures of the edges of the de-epithelialized ring using PDS 3/0 as well (Fig. 3-A). Skin edges were closed in continuous sutures using Prolene 5/0 (Fig. 3-B). Dressing was done by applying Vaseline gauze, sterilized gauze over NAC, and adherent tape. We applied surgical foam over the lateral and the inframammary areas of the chest to maintain the contour of the breast and to avoid postoperative redundancy. Finally, the compression garment was worn.

Regarding postoperative medications, the following regimen was prescribed for patients: Third generation cephalosporins as ceftazidime for three days, antiedematous as alfa-chymotrypsin, analgesics as diclofenac, and anti-stress ulcer medication for five days.

The patient's hospital stay was 48 hours postoperative, during which the vital signs were observed. Early assessment of the viability of NAC was done at 24 and 48 hours postoperative. This was done through a window made in the dressing after removing the pressure garments then the patient was asked to wear the pressure garments again till the first visit.

The first postoperative follow-up visit was one week later for dressing, assessment of the viability

of NAC, and patient reassurance. Then two weeks postoperative for removal of skin sutures. The postoperative follow-up period was up to six months, evaluating pre- and postoperative photographic documentation, measurements, patient satisfaction, and complications (Figs. 1,4,5).

Data analysis was conducted by SPSS software, version 25 (SPSS Inc., PASW Statistics for Windows version 25). Qualitative data were defined by utilizing numbers and percentages, while quantitative data were defined by utilizing mean \pm SD for normal distribution of data after testing normality by utilizing the Kolmogorov-Smirnov test. The significance of the acquired results was judged at the (0.05) level. The paired *t*-test was utilized for comparison of 2 paired readings for normal distribution of data.

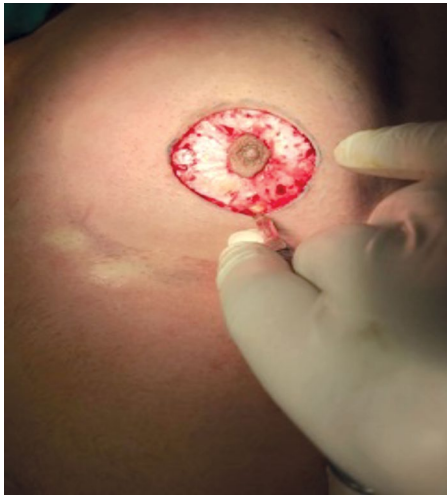

Fig. (2-A): Transdermal incision in the de-epithelialized area at 5 to 7 o'clock to approach the residual gland.

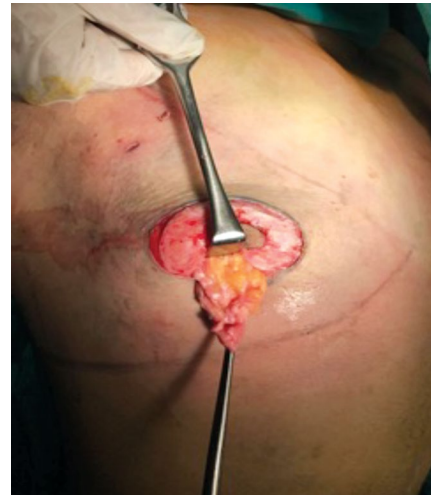

Fig. (2-B): Gland removal by "pull-through" technique.

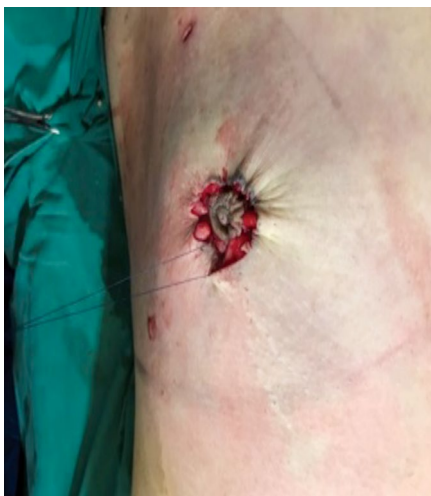

Fig. (3-A): Purse string stitch for closure of the de-epithelialized area.

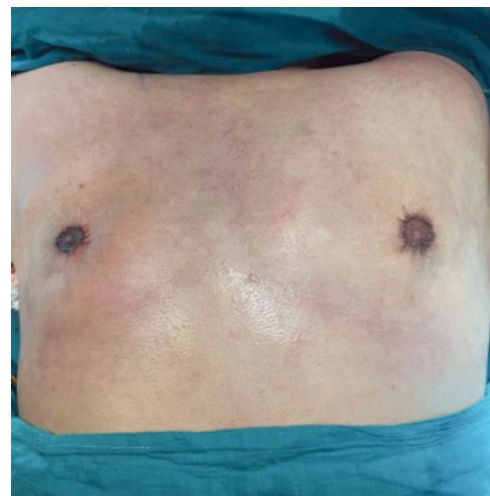


Fig. (3-B): Closure of skin edges by continuous sutures.

Results

Twenty male patients with grade IIB or grade III gynecomastia underwent a single-stage procedure: liposuction, gland excision, and resection of excess lax skin through circum-areolar incision. The age of studied cases ranged from 18 to 42 years old. The mean±SD: 23.45±5.67. (Table 1).

Table (1): Age of the studied cases.

N=20	
Age/years	23.45±5.67 (18-42)

Photo documents were taken preoperative and postoperative as well. The postoperative photographs were evaluated by two independent surgeons to evaluate the postoperative breast symmetry, chest contour, the condition of the scar, and whether there is still ptosis of the breasts. Results of the photographic assessment illustrated that 15% of the cases had unaesthetic scars, 90% achieved symmetry between the level of both breasts, 90% had good masculine chest contour, and 5% experienced residual ptosis. (Table 2).

Table (2): Results of photographic evaluation by two independent surgeons.

	N=20	%
Unaesthetic Scar	3	15.0
Symmetry	18	90.0
Ptosis	1	5.0
Chest contour	18	90.0

There was a statistically significant decrease in clinical measurements after operation as compared to preoperative values with the highest improvement rate detected in right skin pinch (55.3%) followed by left skin pinch (54.2%), Right sternal notch to NAC (10.8%), left sternal notch to NAC (10.72%), Left mid-clavicular point to NAC (9.8%), Right midclavicular point to NAC (9.4%) and Inter-areolar distance (0.48%). (Table 3).

Table (4) demonstrates that out of 20 patients, 11 patients were highly satisfied with the scar appearance, and 7 patients were moderately satisfied. Two patients were mildly satisfied with their scar appearance due to moderate scar widening. Patient's satisfaction as regards chest contour was distributed as follows; 50% excellent, 40% very good, 10% fair.

In our case study, we didn't encounter serious complications. The most frequent complication among the studied cases was unaesthetic scar either wide or hypertrophic (15%) which was managed conservatively with topical silicon, followed by asymmetry (10%), and (5%) for each of the fol-

lowing: Hematoma, seroma, which were managed conservatively by compressive dressing and needle aspiration, and partial NAC ischemia. (Table 5).

Table (3): Comparison between pre-operative and post-operative clinical measurements.

	Pre-operative	Post-operative	Test of significance	% of change
Right sternal notch to NAC	23.10±1.83	20.60±1.57	t=10.64 p<0.001*	10.8%
Left sternal notch to NAC	23.05±1.90	20.58±1.52	t=12.57 p<0.001*	10.72%
Right midclavicular point to NAC	21.40±1.69	19.38±1.56	t=14.67 p<0.001*	9.4%
Left midclavicular point to NAC	21.43±1.96	19.33±1.67	t=13.42 p<0.0001*	9.8%
Right skin pinch	9.95±2.09	4.45±1.49	t=11.09 p<0.001*	55.3%
Left skin pinch	9.90±2.10	4.53±1.63	t=10.40 p<0.001*	54.2%

Table (4): Patient satisfaction degree among studied cases.

Patient satisfaction	N=20	%
<i>Chest contour:</i>		
• Poor	0	0.0
• Fair	2	10.0
• Very good	8	40.0
• Excellent	10	50.0
<i>Scar:</i>		
• Poor	0	0.0
• Fair	2	10.0
• Very good	7	35.0
• Excellent	11	55.0

Table (5): Distribution of the studied cases according to incidence of complications.

Complications	N=20	%
Hematoma	1	5.0
Seroma	1	5.0
NAC ischemia (partial)	1	5.0
NAC ischemia (complete)	0	0.0
Wound infection	0	0.0
Asymmetry	2	10.0
Saucer-like deformity	0	0.0
Unaesthetic scar	3	15.0
Complications		
Hematoma	1	5.0
Seroma	1	5.0
NAC ischemia (partial)	1	5.0
NAC ischemia (complete)	0	0.0
Wound infection	0	0.0
Asymmetry	2	10.0
Saucer-like deformity	0	0.0
Unaesthetic scar	3	15.0

Fig. (4): Case (1): 23 years old male with grade III gynecomastia. (4A) Preoperative anterior view. (4B) 6 months postoperative view. (4C) Preoperative left oblique view. (4D) 6 months postoperative left oblique view.

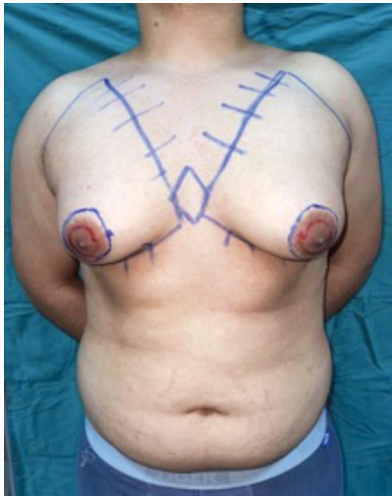


Fig. (4-A): Preoperative anterior view.

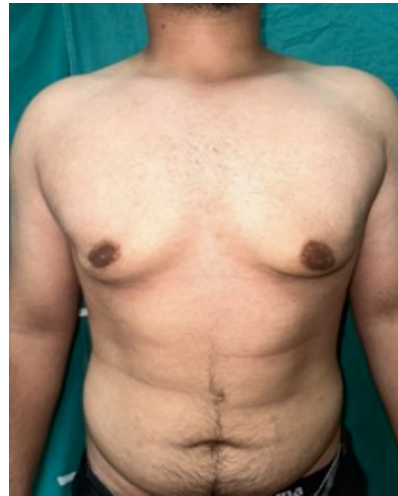


Fig. (4-B): 6 months postoperative anterior view.

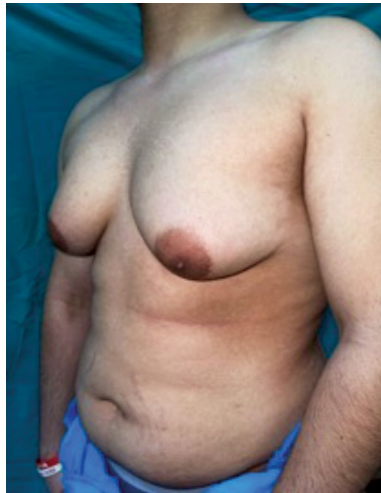


Fig. (4-C): Preoperative left oblique view.

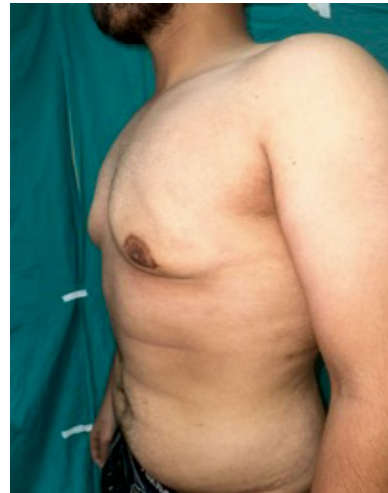

Fig. (4-D): 6 months postoperative left oblique view.

Fig. (5): Case (2): 22 years old male with grade IIB gynecomastia. (5A) Preoperative left lateral view. (5B) 6 months postoperative left lateral view. (5C) Preoperative anterior view. (5D) 6 months postoperative anterior view.

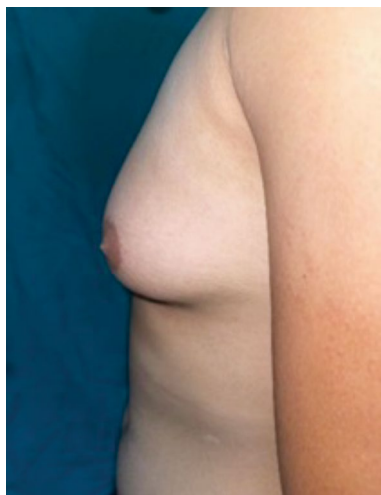

Fig. (5-A)

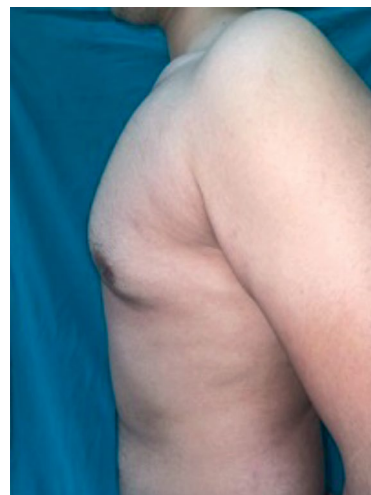

Fig. (5-B)

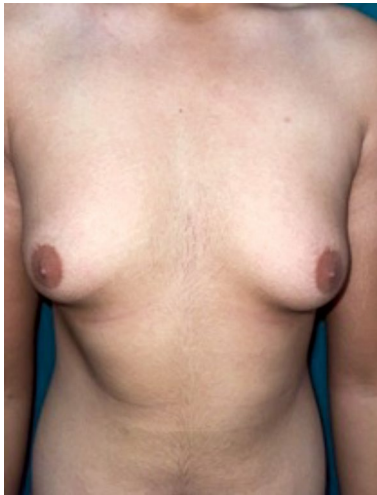


Fig. (5-C)

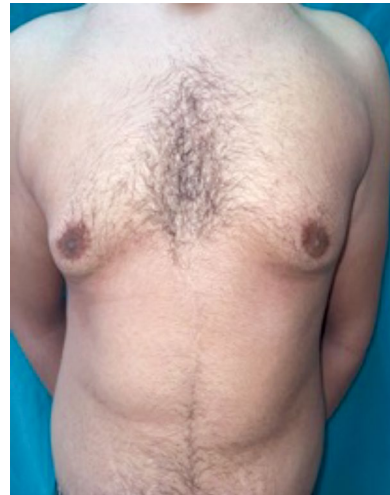


Fig. (5-D)

Discussion

Gynecomastia is the commonest pathology of male breasts with varying incidences in different age groups. The majority of patients of gynecomastia are idiopathic; however, pathologic causes required to be excluded; these involve endocrinal disorders, tumors, and drugs [10].

The main dilemma with grades IIB and III is the excess redundant skin. Many incisions for resection of excess skin have been described by authors. Such as oblique or transverse skin excisions [11]. However, these surgical approaches usually form scars over the male chest, which are aesthetically unappealing. Webster was the first to describe skin resection through a circum-areolar approach for high grades of gynecomastia [4].

We agreed with Cordova et al., that circum-areolar incisions are associated with good aesthetic results in terms of scar [12]. It also addressed large NAC diameter as patients benefit from this excision by reduction of its diameter to 2.5-3cm as proposed by some authors [13].

The current study was performed on 20 patients with ages ranging from 18-42 years with high grades of gynecomastia (G IIB and GIII) using a single-stage procedure. In our technique, along with the concentric circum-areolar rings to address the excess skin, we performed simultaneous liposuction to reduce the breast parenchyma and gland excision through a small transdermal incision.

We outlined an inner circle around the NAC with a diameter of 2.5cm to 3cm and another outer epidermal ring representing the area to be de-epithelialized which was drawn 1.5cm to 2cm from the NAC ring.

Regarding transdermal incision, Cannistra et al., in 2009 published a review of 58 cases man-

aged by peri-areolar incision and double dermal areolar pedicle. They performed transdermal incisions between 2 to 4 o'clock and 8 to 10 o'clock. They reported areolar hypoesthesia in 10% of their cases which was explained by injury of the medial nerve supply of the NAC by the superficial 3rd and 4th anterior cutaneous branches of the intercostal nerves [14].

The vascular pedicle below the NAC, arising from the intercostal vessels, is considered by certain investigators as fundamental for the blood supply of the NAC [15]. On the other hand, the current study agreed with Persichetti et al., that the blood supply from the subdermal plexus is sufficient to maintain the viability of the NAC, allowing the execution of the recommended approach [3].

In our case study, a transdermal incision was therefore made at 5 to 7 o'clock position in the de-epithelialized area to spare the subdermal plexus coming from medial, lateral, and cephalic parts of the areola to confirm adequate neurovascular supply to the areolar complex. This transdermal incision was sufficient for assuring adequate hemostasis and excision of the residual gland by the "pull-through" technique.

We have noticed an acceptable improvement in clinical measurements postoperatively. The mean distance of NAC from the sternal notch was 21cm and 20cm from the midclavicular point. Beckenstein et al proposed that the position of NAC must be 18cm from the midclavicular line and 20cm from the sternal notch [16]. We think that the position of NAC could differ approximately two cm as the shape and the diameter of the patient's chest are variable.

Another benefit of the current approach is that, as the liposuction of the breast covered a large area

from the clavicle to below the inframammary fold, it gave a good contour of the chest. The single-stage procedure including the circum-areolar skin resection with purse string closure allowed immediate re-contouring of the chest avoiding prolonged distress till skin contracture occurs for an acceptable final contour which may not be achieved.

In this patient series study, 3 cases developed unfavorable (wide or hypertrophic) scars. This was explained by excessive skin resection in these cases causing tension of wound edges. This was managed conservatively till improvement. Therefore we agreed with Botta that excess skin resection is a limiting factor for acceptable outcomes and could be associated with unfavorable scar [15].

In our study, we believed that hemostasis depends on both adequate cauterization after gland excision and postoperative compression garments; therefore, we didn't use drains in our cases. However, we encountered 1 case of hematoma and 1 case of seroma which were managed conservatively by compression and needle aspiration. We reported 1 case of partial NAC necrosis. This was supposedly either due to aggressive liposuction under NAC or compromised subdermal plexus during the transdermal incision. This case was managed conservatively by daily dressing till healing.

In our series, there are no documented cases of complete NAC ischemia, saucer deformity, or wound infection. We reported an acceptable overall complications rate with acceptable and satisfactory outcomes and our incidence rate was similar to other surgical approaches of high grades of gynecomastia with liposuction and excess skin resection.

Conclusion:

The current study concluded that; our approach for correction of high grades of gynecomastia with skin redundancy through liposuction, glandular excision, and circum-areolar excision procedure allows the surgeon to achieve acceptable aesthetic results while avoiding unsightly scars or complications. Such approach is a viable modality for cases who need excess skin excision or reduction of the NAC size and are ready to accept the presence of a peri-areolar scar.

References

- 1- Cavina C.: Gynecomastia. In International Textbook of Aesthetic Surgery (pp. 285-294). Berlin, Heidelberg: Springer Berlin Heidelberg, 2016.
- 2- Morselli P.G. and Morellini A.: Breast reshaping in gynecomastia by the "pull-through technique": considerations after 15 years. *European Journal of Plastic Surgery*, May 35: 365-71, 2012.
- 3- Persichetti P., Berloco M., Casadei R.M., Marangi G.F., Di Lella F. and Nobili A.M.: Gynecomastia and the complete circumareolar approach in the surgical management of skin redundancy. *Plastic and Reconstructive Surgery*, Apr. 1; 107 (4): 948-54, 2001.
- 4- Webster J.P.: Mastectomy for gynecomastia through a semicircular intra-areolar incision. *Annals of Surgery*, Sep. 124 (3): 557, 1946.
- 5- Kasielska A. and Antoszewski B.: Surgical management of gynecomastia: An outcome analysis. *Annals of Plastic Surgery*, Nov. 1; 71 (5): 471-5, 2013.
- 6- Tashkandi M., Al-Qattan M.M., Hassanain J.M., Hawary M.B. and Sultan M.: The surgical management of high-grade gynecomastia. *Annals of Plastic Surgery*, Jul. 1; 53 (1): 17-20, 2004.
- 7- Ibrahim SM.: Severe gynecomastia: New technique using superior pedicle NAC flap through a circumareolar approach. *Annals of Plastic Surgery*, Jun. 1; 76 (6): 645-51, 2016.
- 8- Fikry A. and Nasr M.: Surgical management of high grade gynecomastia: Combination of liposuction, glandular resection and a circumareolar skin reduction. *The Egyptian Journal of Plastic and Reconstructive Surgery*, Jul. 1; 42 (2): 323-9, 2020.
- 9- Li C.C., Fu J.P., Chang S.C., Chen T.M. and Chen S.G.: Surgical treatment of gynecomastia: Complications and outcomes. *Annals of Plastic Surgery*, Nov. 1; 69 (5): 510-5, 2012.
- 10- Swerdloff R.S. and Ng J.C.: Gynecomastia: Etiology, diagnosis, and treatment. *Endotext [Internet]*. Jan 6, 2023.
- 11- Hurwitz D.J. and Davila A.A.: Contemporary management of gynecomastia. *Clinics in Plastic Surgery*, Apr. 1; 49 (2): 293-305, 2022.
- 12- Cordova A. and Moschella F.: Algorithm for clinical evaluation and surgical treatment of gynecomastia. *Journal of plastic, reconstructive & aesthetic surgery*, Jan. 1; 61 (1): 41-9, 2008.
- 13- Diyarbakirlioglu M., Ercan A. and Dogan Y.: Correction of high-grade pseudogynecomastia after massive weight loss: Modified inferior dermoglandular pedicled transverse scar reduction. *Aesthetic Plastic Surgery*, Apr. 44: 435-41, 2020.
- 14- Cannistra C., Piedimonte A. and Albonico F.: Surgical treatment of gynecomastia with severe ptosis: Periareolar incision and dermal double areolar pedicle technique. *Aesthetic Plastic Surgery*, Nov. 33: 834-7, 2009.
- 15- Botta S.A.: Alternatives for the surgical correction of severe gynecomastia. *Aesthetic Plastic Surgery*, Jan. 22: 65-70, 1998.
- 16- Beckenstein M.S., Windle B.H. and Stroup Jr. R.T.: Anatomical parameters for nipple position and areolar diameter in males. *Annals of Plastic Surgery*, Jan. 1; 36 (1): 33-6, 1996.