

Effectiveness and Safety of Laparoscopic Approach in The Management of Complicated Appendicitis

AHMED M.Kh. MOHAMED ELSAYED, M.Sc.; MAHMOUD A. SHAKER, M.D.;
MAHER SOLIMAN, M.D. and MOSTAFA ELKADY, Ph.D.

The Department of General Surgery, General Institute of Teaching Hospitals

Abstract

Background: Within the last decade, the laparoscopic appendectomy has gained popularity. During laparoscopic appendectomy, any other pathology that comes to view could be diagnosed rather easier and dealt with in the same time. The decision as to do the laparoscopic appendectomy is usually based on the surgeon's preference rather than on knowledge of the advantage of it.

Aim of Study: The aim of this study is to evaluate laparoscopic appendectomy in complicated appendicitis in a teaching hospital regarding operative time, intraoperative complications, time of return to oral intake, length of hospital stay, postoperative pain and complications.

Patients and Methods: Forty patients with suspected complicated acute appendicitis were admitted to ER in Ahmed Maher Teaching Hospital, from September 2021 to September 2023. All underwent laparoscopic appendectomy. We conducted a prospective study evaluating laparoscopic appendectomy in complicated appendicitis.

Results: In laparoscopic appendectomy the monopolar diathermy was used to divide the mesoappendix and controlling the appendicular artery then the base was cut between two ligatures whether by end loops or intracorporeal suture. Laparoscopic appendectomy is a safe and feasible in management of complicated acute appendicitis. Laparoscopic appendectomy has the advantage of shorter operative room time, less intraoperative complications, less post-operative complications, less time needed for oral intake, and shorter hospital stay.

Conclusion: From the previous study we concluded that laparoscopic appendectomy in complicated appendicitis is a safe and efficient procedure with lower incidence of complications and should be the initial choice for all patients with complicated appendicitis, laparoscopic appendectomy has the advantage of shorter operative room time, less intraoperative

complications, less post-operative complications, less time needed for oral intake, and shorter hospital stay.

Key Words: Laparoscopic appendectomy – Appendicitis.

Introduction

ACUTE appendicitis is one of the most common causes of acute abdominal pain with an incidence of 1.17 per 1000 and lifetime risk of approximately 7%. It remains the most common indication for emergency abdominal surgery [1].

The commonest problem causing a lot of suffering, pain and morbidity. Most commonly patients present with symptoms like pain, vomiting and fever delay may lead to complications like appendicular abscess, mass, gangrene, perforation and peritonitis. Surgery is the main stay of treatment [2].

Laparoscopic surgery is a less morbid procedure that usually results in an uneventful postoperative recovery for many surgical procedures [3].

The distinguishing features of a laparoscopic approach over conventional open approach include shorter hospital stay, quicker return to activity, reduced pain, and better cosmesis [4].

Laparoscopic appendectomy has rapidly developed in recent years. Since Semm published the first complete removal of the appendix via laparoscopic surgery in 1983 and Schreiber performed the first laparoscopic appendectomy in a patient with acute appendicitis in 1987, laparoscopic appendectomy has been included in practically all hospitals worldwide as the usual procedure in emergency departments [5].

Laparoscopic appendectomy has several advantages over the open approach, such as less surgical trauma, a better postoperative recovery, exploration of the entire abdominal cavity especially in obese patients and women at a fertile age [6].

Correspondence to: Dr. Ahmed M.Kh. Mohamed Elsayed,
The Department of General Surgery, General Institute of
Teaching Hospitals

A quick return to normal patient activity, and a better cosmetic outcome. The tendency toward reduced patient morbidity after surgery has enabled the development of techniques requiring an increasingly less invasive access to the operating field [7].

The main advantage of the laparoscopic surgery in abdominal surgery is related to the avoidance of a laparotomy wound and its infection, less pain, short stay in hospital, early return to normal work and cosmosis [8].

Better access and good visualization of the peritoneal cavity through small incisions give LA advantage when compared with OA. Accordingly, complicated appendicitis is better managed by LA [9].

OA for complicated appendicitis, compared with that for uncomplicated appendicitis, requires a larger abdominal incision and longer operating time, giving more surgical stress to the patients. Moreover, the wound is exposed to contaminated fluid which may result in an increased rate of wound infections. Hence, it is logical that LA could have advantages over OA in patients with complicated appendicitis, because LA is associated with less wound surface area exposed to contamination and potentially facilitates direct visualization during peritoneal lavage [6].

Aim of the work:

The aim of the present work is to assess laparoscopic appendectomy in complicated appendicitis in a teaching hospital regarding operative time, intraoperative complications, time of return to oral intake, length of hospital stay, postoperative pain and complications.

Another objective of this study is to make awareness and to clear some of the issues and to provide satisfactory results of laparoscopy in complicated appendicitis.

Patients and Methods

Forty patients with suspected complicated acute appendicitis were admitted to Emergency Unit in Ahmed Maher Teaching Hospital, from September 2021 to September 2023. The suspicion of acute appendicitis to be complicated was achieved by the following criteria: History of present illness more than 3 days, fever more than 39°C, total leukocytic count more than 11000, signs of complications in investigations such as in sonar or CT scan.

Inclusion criteria: Appendicular abscess, non palpable mass, gangrenous appendix, perforated appendicitis, appendicitis with peritonitis, appendicitis with dense adhesions.

Exclusion criteria: Laparoscopic appendectomy without any complication, suspicion of malignancy, pregnant with complicated appendicitis.

The patients were allocated into one group (40) patients who were undergo laparoscopic appendectomy. The study was conducted after receiving approval from the local ethics committee and informed consent from the patients to be included in the study.

Patients were studied according to the following sheet:

History taking with emphasis on personal data (age, sex, residency), pain (site, shifting, radiation, intensity and duration), previous attacks (number, severity and duration), previous abdominal surgery, nausea, vomiting and anorexia.

Physical examination:

Vital signs (pulse, blood pressure and temperature), associated co-morbid conditions that may be relative contraindication for laparoscopy (Patients with hemodynamic instability, advanced sepsis and cardiopulmonary diseases), peritoneal irritation signs (guarding, tenderness, rigidity, Rovsing's sign, and psoas spasm), PR examination.

Investigations:

Laboratory examinations:

Complete blood picture with total and differential White Blood Cell count, prothrombin time, fasting blood sugar, liver and renal function tests, Na and K in markedly dehydrated patients, urine analysis.

Imaging:

Ultrasonography: To assess the tenderness on probing in the right iliac fossa and the presence of right iliac fossa or pelvic collection. Also, to look for the thickened wall prominent of congested appendix and, to exclude any concomitant gynecological finding e.g. tubal pregnancy or ovarian cyst. Also, to exclude any other cause for right iliac fossa pain, e.g. ileocecal intussusception. Plain chest X-ray in suspected perforation, CT in suspicious malignancy.

Gynecological consultation was done to female patients to exclude any gynecological cause for the acute lower abdominal pain if the patient's ultrasonography revealed an ovarian cyst or suspected tubal pregnancy. Markedly dehydrated patients had fluid resuscitation and Foley catheter to ensure adequate urine output. Any electrolyte deficiencies were corrected prior to the induction of general anesthesia.

Prior to the surgical incision, all the patients received a standard regimen of intravenous antibiotics (2gm of 3rd generation cephalosporin and 500mg of Metronidazole). Cleansing the skin of the umbilicus to prevent postoperative infection. All patients had general anesthesia with endotra-

cheal intubation, the urinary bladder is catheterized to prevent interference with visualization or inadvertent puncture, exposure of the abdomen from the level of anterior superior iliac spine to the xiphisternal junction, the rest of the body is covered by sterile drapes. The skin was prepared with 10% povidine iodine solution.

Intra-operative assessment:

Operative time: The time from the incision time till closure of the port site or the wound, intraoperative findings: Perforated, gangrenous, appendicular mass or abscess, appendix position: Retrocecal, pelvic or subcecal, intra-operative complications: Conversion to open procedure.

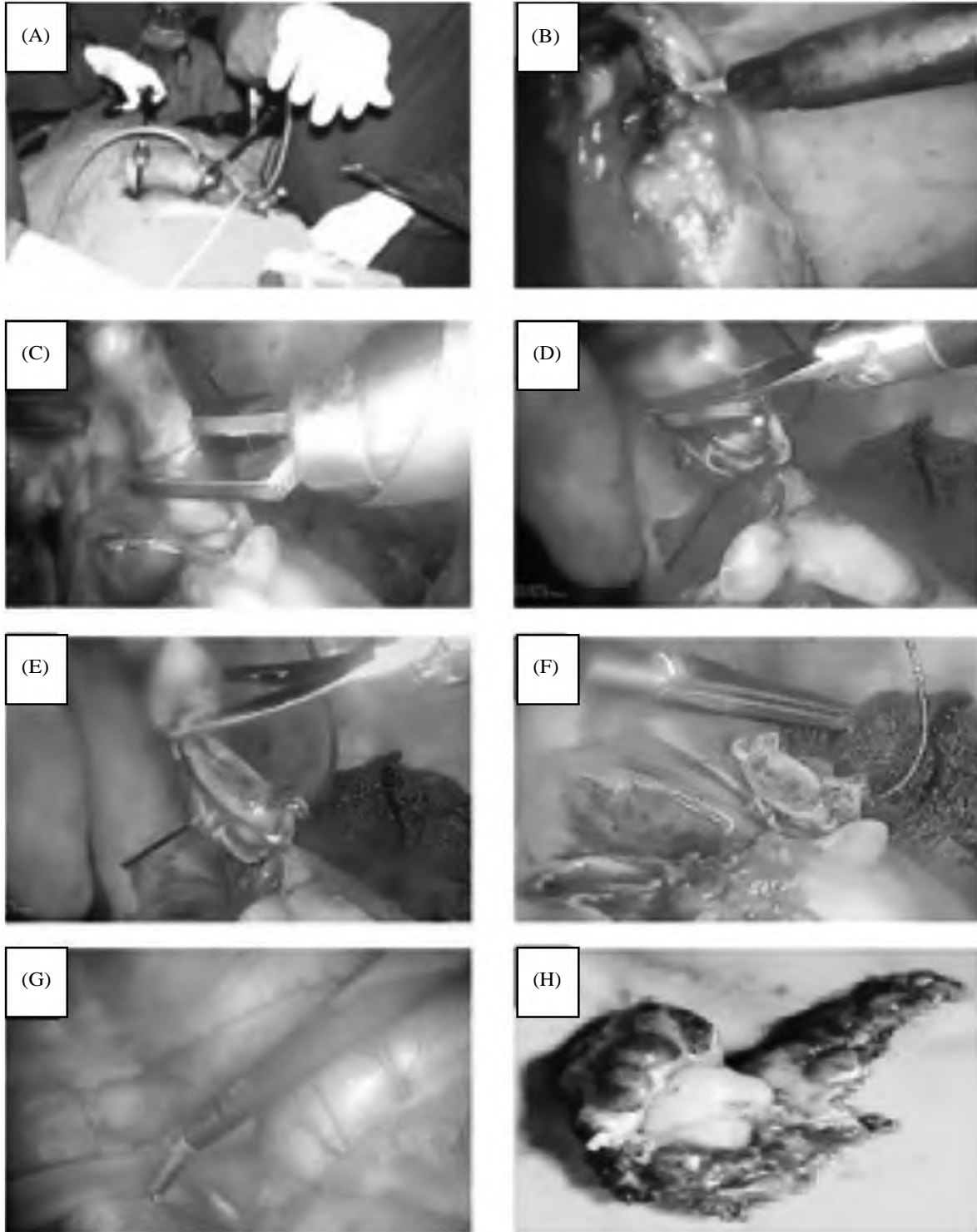


Fig.(1): Steps of laparoscopic appendectomy of gangrenous appendix, (A) Ports positions. (B) Hook diathermy dissection of the mesoappendix. (C) Clipping of the base of appendix. (D&E) Transection of the appendix. (F) Appendiceal stump. (G) Insertion of intraperitoneal drain. (H) Gangrenous appendix after retrieval through the port.

Post-operative follow-up:

Time of return to oral intake, length of hospital stay, time from the surgery till the discharge calculated in days, the need for analgesia, post-operative complications: Fever, intra-abdominal collection, post-operative ileus and wound infection.

Technique of Laparoscopic appendectomy:

The patient was placed supine in a 15° Trendelenburg position with both arms tucked. Rotation to the left was done. The surgeon stood on the patient's left side. The first assistant stood on the surgeon's left side. The monitor was on the patient's right side. After the induction of general anesthesia, a urinary catheter was placed. A pneumoperitoneum was created in standard fashion, using either the Veress needle technique or the open technique according to the surgeon preference. The first trocar (10mm) was introduced at the lower margin of the umbilicus. The intraperitoneal pressure was set to be 14mmHg. Introduction of the scope was done to ensure the clinical diagnosis and identify the position of the appendix so as to determine the best site of insertion of the other trocars. A second 5mm suprapubic trocar was inserted. A third operating trocar was inserted in the left iliac fossa.

After insertion of the ports, a quick diagnostic laparoscopy was performed in order to confirm the diagnosis and assess other pathologies. The surgeon's left hand held an intestinal clamp grasper to retract the cecum and subsequently expose the appendix. Cautery was used to incise the retroperitoneal attachments of the cecum in difficult cases. The surgeon's right hand operated a dissecting instrument or cautery scissors, which were used to create a window in the mesoappendix at the base of the appendix. The mesentery and base of the appendix were secured and divided separately using clips or diathermy for mesoappendix and clips, intracorporeal suture or end loop technique for appendiceal base.

After transection, the appendix was retrieved. After the appendix is removed, hemostasis is achieved. Irrigation and insertion of a drain were done. Trocars were removed under direct vision. Fascia at the 10-mm trocar site was closed, and all wounds were closed primarily (Fig. 1).

Antibiotics were not discontinued but were modified according to the culture results and continued for 7 to 10 days till the patient was afebrile. Patients were given sips of water after passing flatus or feces or after hearing intestinal sounds to avoid paralytic ileus from early introduction of food or liquids. Postoperatively all patients received analgesics in the form of NSAIDs for 24 hours, then analgesics were given upon the patient request. The discharge criteria are met once the patients were afebrile, with audible bowel sounds and were able to tolerate a

liquid diet and oral analgesia. The specimens were sent for pathology for assessing pathological diagnosis.

Results

This study was conducted on 40 patients complaining of acute abdominal pain diagnosed as complicated appendicitis (perforated, gangrenous appendix, appendicular mass, appendicular abscess). The patients underwent laparoscopic appendectomy.

This table shows the description of age and sex of all studied patients. As regard age, the mean age of all studied patients was 28.4±9.7 years with minimum age of 18 years and maximum age of 53 years. As regard sex, there were 14 males (35%) and 26 females (65%) in the studied patients.

This table shows the description of intraoperative findings of all studied patients. There were 8 patients (20%) showed appendicular abscess, 4 patients (10%) showed appendicular mass, 10 patients (25%) showed gangrenous appendicitis and 18 patients (45%) showed perforated appendicitis in the studied patients.

This table shows the description of appendix position of all studied patients. It was pelvic in 10 patients (25%), Retrocecal in 16 patients (40%) and Subcecal in 14 patients (35%).

This table shows the description of operative time in all studied patients. The mean operative time of all studied patients was 51.7±18.5min with minimum time of 40 min and maximum time of 120min.

This table shows the rate of conversion to open procedure of all studied patients. There were 38 patients (95%) continued on laparoscopic procedure while there were only 2 patients (5%) converted to open procedure. One (2.5%) case with appendicular mass was converted to open approach by midline incision due to extensive adhesions, and one (2.5%) case with gangrenous appendix was converted to open approach by lower midline incision due to gangrenous base with friable cecum that required trimming of the base with closure by interrupted suture and application of onlayomental patch.

This table shows the description of return to oral intake in all studied patients. There were 14 patients (35%) returned on the same day, 20 patients (50%) returned on the 1st day and 6 patients (15%) returned on the 2nd day.

This table shows the description of duration of hospitalization in all studied patients. There were 10 patients (25%) hospitalized for 2 days, 14 patients (35%) hospitalized for 3 days, 12 patients (30%) hospitalized for 4 days and 4 patients (10%) hospitalized for ≥5 days.

This table shows the description of total analgesic doses in all studied patients. There were 2 patients (5%) received 2 doses, 14 patients (35%) received 3 doses, 20 patients (50%) received 4 doses and 4 patients (10%) received ≥ 5 doses.

This table shows the description of post-operative complication in all studied patients. There was Fever >38 with collection on U/S in 2 patients (5%), Fever >38 without collection on U/S in 3 patients (7.5%), Post-operative ileus in 2 patients (5%), Wound seroma in 3 patients (7.5%), Wound infected seroma and infection in 2 patients (5%) while there were no complications in 28 patients (70%).

Management of postoperative complications:

Wounds infection: The overall cases of wound infections were 5 cases, all of them are managed conservatively by wound dressing twice daily by saline wash and betadine, also wound culture and sensitivity was done and antibiotics was given according to it.

Intra-abdominal collection: The overall cases of intra-abdominal collection were 2 cases, one of them underwent ultrasound guided drainage by pig-tail, and the other case was a small collection underwent conservative management on antibiotic course according to culture and sensitivity.

Post-operative fever: The overall cases of post-operative fever were 5 cases, all of them are managed by cold fomentations and antipyretics (paracetamol infusion).

Post-operative ileus: The overall cases of post-operative ileus were 2 cases, all of them were managed by correction of electrolytes and rest of intestine (NPO).

Table (1): Description of age and sex of all studied patients.

| | | Studied patients (N = 40) | |
|-------------|---------------|---------------------------|-----|
| Age (years) | Mean \pm SD | 28.4 \pm 9.7 | |
| | Min - Max | 18-53 | |
| Sex | Male | 14 | 35% |
| | Female | 26 | 65% |

Table (2): Description of intraoperative findings of all studied patients.

| | | Studied patients (N = 40) | |
|-------------------------|-------------------------|---------------------------|-----|
| Intraoperative findings | Appendicular abscess | 8 | 20% |
| | Appendicular mass | 4 | 10% |
| | Gangrenous appendicitis | 10 | 25% |
| | Perforated appendicitis | 18 | 45% |

Table (3): Description of appendix position in all studied patients.

| | | Studied patients (N = 40) | |
|-------------------|------------|---------------------------|-----|
| Appendix position | Pelvic | 10 | 25% |
| | Retrocecal | 16 | 40% |
| | Subcecal | 14 | 35% |

Table (4): Description of operative time in all studied patients.

| | | Studied patients (N = 40) | |
|----------------------|---------------|---------------------------|--|
| Operative time (min) | Mean \pm SD | 51.7 \pm 18.5 | |
| | Min - Max | 40-120 | |

Table (5): Description of conversion to open procedure in all studied patients.

| | | Studied patients (N = 40) | |
|------------------------------|-----|---------------------------|-----|
| Conversion to open procedure | No | 38 | 95% |
| | Yes | 2 | 5% |

Table (6): Description of return to oral intake in all studied patients.

| | | Studied patients (N = 40) | |
|-----------------------|----------------------------|---------------------------|-----|
| Return to oral intake | On the same day | 14 | 35% |
| | On the 1 st day | 20 | 50% |
| | On the 2 nd day | 6 | 15% |

Table (7): Description of duration of Hospital stay in all studied patients.

| | | Studied patients (N = 40) | |
|----------------------------------|---------------|---------------------------|-----|
| Duration of Hospital stay (days) | 2 days | 10 | 25% |
| | 3 days | 14 | 35% |
| | 4 days | 12 | 30% |
| | ≥ 5 days | 4 | 10% |

Table (8): Description of total analgesic doses in all studied patients.

| | | Studied patients (N = 40) | |
|-----------------------|----------------|---------------------------|-----|
| Total analgesic doses | 2 doses | 2 | 5% |
| | 3 doses | 14 | 35% |
| | 4 doses | 20 | 50% |
| | ≥ 5 doses | 4 | 10% |

Table (9): Description of postoperative complications in all studied patients.

| | | Studied patients (N = 40) | |
|-----------------------------|-------------------------------------|------------------------------|------|
| Postoperative complications | No complications | 28 | 70% |
| | Fever >38 with collection on U/S | 2 | 5% |
| | Fever >38 without collection on U/S | 3 | 7.5% |
| | Post-operative ileus | 2 | 5% |
| | Wound seroma | 3 | 7.5% |
| | Wound infected seroma and infection | 2 | 5% |

Discussion

Approximately 6% of the populations develop appendicitis in their life time, with peak incidence between the ages of 10 and 30 years, thus making appendectomy the most frequently performed abdominal operation [10].

The treatment of acute appendicitis remained essentially unchanged since its first description by Charles McBurney in 1889. Appendectomy by McBurney's incision remained the procedure of choice for nearly a century until 1983 when Kurt Semm offered an alternative, "laparoscopic appendectomy", but as McBurney's operation is well tolerated with less co-morbidity the benefits of laparoscopic appendectomy have been difficult to establish [11].

The technique of laparoscopic appendectomy was started via gynecologists and was adopted later by the general surgeons [12].

Recently many studies shows that LA provides considerable benefits over OA, including a shorter hospital stay, less postoperative pain, earlier postoperative recovery and lower complication rate [13].

There have been numerous retrospective and uncontrolled series of laparoscopic appendectomy (LA), as well as many prospective randomized studies published to date. Although most of these have concluded that the laparoscopic technique is as good as open appendectomy (OA), there has been considerable controversy as to whether LA is superior or not [14].

Many studies clarified significant advantages of the laparoscopic approach, such as less postoperative pain, shorter hospital stay, chance of exploration of the peritoneal cavity, ease of suction irrigation under vision, and better cosmetic results [15].

With the technological advances and improvements in surgical laparoscopic techniques, laparoscopic surgery has become the standard procedure of choice for many diseases. Laparoscopy, as a min-

imally invasive technique, has unique advantages in several areas, and many scholars have proved its advantages [16].

The rate of LA has been reported to increase in all groups, and 66% of LAs performed in non-perforated appendicitis versus 100% of LAs use for perforated appendicitis in United States [17].

Regarding operating time, the level of surgical experience and the learning curve were the two important factors that could influence operating time. A higher surgical level of experience in LA would indicate a shorter operating time. The present study showed that LA would require much more time than OA, presumably because CA usually indicates more serious abdominal adhesion and peritonitis, increasing the difficulty in LA of manipulating without hand touching, and the inexperience of the surgeons can also contribute to the longer time.

Increased experience of surgeons and nursing staff indeed decreased the operating time [18].

Generally all laparoscopic procedures are more time consuming for the following reasons: Inherent nature of slow maneuver of laparoscopic techniques, time taken by careful slow insufflation, routine diagnostic laparoscopy before starting any laparoscopic procedure [19].

In contrast to the general belief that conversion depends on the surgeon experience, we think that intra-operative situations are the main reason to convert. In the present study, we reported 2 cases of intra-operative difficulties, One case with appendicular mass was converted to open approach by midline incision due to extensive adhesions, and a nother case with gangrenous appendix was converted to open approach by lower midline incision due to gangrenous base with friable caecum that required trimming of the base with closure by interrupted suture and application of onlayomental patch.

Galli et al., explored all suspected cases of PA laparoscopically according to hospital's policy and selected easy cases only to be completed laparoscopically leading to high conversion rate [20].

Duration of hospitalization is an important factor that directly impacts the patients' finances and overall well-being. Our findings show that the duration of hospitalization was significantly shorter in the LA and this is consistent with the study of some studies [21].

In contrast most American / European groups would discharge patients sooner but prolongation of the hospital stays in the current study occurred in some cases due to complications such as ileus, IAA, wound complications; although most of them could be managed on outpatient basis, it is related to cultural reasons, educational level of the patients and their relatives and medicolegal causes.

Postoperative pain was assessed by patient's requirement of non-steroidal anti-inflammatory injection ampoules which are effective analgesic. Furthermore, to diminish shoulder pain from residual gas irritation, suction of CO₂ from the right sub phrenic space and low-pressure pneumoperitoneum were executed in all cases in addition to minimal tissue handling and trauma, which also contributes to reducing pain sensation [22].

Our findings proved a significant advantage of LA in this issue. Similar findings were reported with opioid-combined analgesics as the oral opioid Pentazosine and diclofenac sodium suppositories by Fukami et al. [23].

Pethidine IM with oral loxoprofen sodium used by Katsuno et al., showing less analgesic requirement after LA [24].

The infectious complications, especially SSIs and IAA, are the most common complications of appendectomy, and they are considered significant indicators of a procedure's safety [25].

During the post-operative period we enlisted the major complications, typically extended the hospital stay or necessitated readmission. These included wound infections, post-operative ileus, and intra-abdominal collection. Minor complications defined as the appearance of fever, mild abdominal pain, tenderness, and signs of peritoneal irritation in the right lower abdominal quadrant, and moderately elevated WBC count after the patient was discharged.

The reduction of wound infection is a significant advantage of LA. The chance of wound infection is greater in OA partly because the inflamed appendix is removed from the abdominal cavity directly through the wound, where as in LA it is extracted via a trocar. In addition, the port-site wounds in LA are smaller compared to the longer wounds of OA [26].

Wound infection rate in the present study is lower with laparoscopic appendectomy as 2 cases (5%) (1 case with appendicular mass which converted to open procedure and 1 case with perforated appendix) experienced mild wound infection, while 3 cases (7.5%) developed port site seroma. None of the patients had to be re-operated due to SSI, but were manageable with antibiotics and bedside wound treatment.

We aimed to find predictive factors of Intra-abdominal abscess formation complication in laparoscopic appendectomy. We observed that obesity, leukocytosis $>20,000/\text{mm}^3$, perforated appendicitis and long operative time were related to the development of postoperative intraabdominal abscess (IAA) [27].

Minimally invasive surgery is increasingly accepted in the management of surgical emergencies. However, in 2002 laparoscopic appendectomy (LA) was challenged by a systematic review which showed an increased incidence of IAA nearly three-fold compared with open appendectomy (OA). Possible reasons hypothesized for this difference are that the infected contents may spread throughout the abdominal cavity during pneumoperitoneum or that as in the OA, the appendix is divided outside the abdominal cavity and the stump is inverted after division, the incidence of intraperitoneal contamination would be lower [22].

Certain operative considerations were taken in mind to lower the incidence of IAA: Firstly, low-pressure pneumoperitoneum limits bacterial translocations to blood stream. Secondly, suction of pus immediately at the start of procedure. Thirdly, complete adhesiolysis, to avoid missing pockets of pus. Fourthly, suction irrigation to wash out infected fluid till clear aspirate and finally adequate drainage by multiple drains. Some surgeons may disagree with multiple drains, but we found it useful in decreasing IAA [28].

Asarias et al., stated that IAA is fivefold more common with complicated appendicitis and considered increasing age as a predictive factor [29].

Horvath et al., blamed the use of Roeder knot, excessive irrigation and the Trendelenburg's position for the higher incidence of IAA after LA in PA [30].

While Gupta et al., accused aggressive manipulation of infected appendix and excessive irrigation to increase infectious complications [31].

In contrast, Piskun et al., believed that IAAs have several determinants and their development is based on the magnitude of intra-abdominal inflammation rather than a specific technical issue during excision a perforated appendix [32].

Convenient amount of irrigation fluid was utilized in our cases, providing as little amount as necessary under direct vision then suctioned, and this maneuver was repeated till clear fluid was retrieved. Indeed, the significance of irrigation as a causative agent for IAA is controversial; Moore et al., suggested that irrigation increases IAA [33].

On the other hand, others concluded that there is no difference between irrigation and suction alone in IAA formation [34].

In the present study, 2 cases (5%) developed intraabdominal abscess, one of them underwent ultrasound guided drainage by pigtail, and the other case was a small collection underwent conservative management on antibiotic course according to culture and sensitivity. In the present study, the IAA

rate decreased. A similar report has been recently [35].

This finding might be due to the improvement of surgeons' laparoscopic skills. It has been shown that those patients who underwent successful laparoscopic appendectomy have a better postoperative recovery. The reduced trauma to the abdominal wall is a very significant factor in post-surgical discomfort. The better mobility of the abdominal musculature and the earlier ambulation, reduce the risk of the early post-operative complications of pneumonia and embolism.

A prospective randomized multi-center study was performed to compare the outcome of laparoscopic and open appendectomy in patients with suspected acute appendicitis by Hellberg et al., Patients having laparoscopic appendectomy recovered more quickly than their open counterpart, but interestingly there was no significant difference in sick leave than after laparoscopic operation [36].

In the present study, 2 cases (5%) were unable to tolerate oral feeding developed ileus.

Other studies conducted on 100 patients reporting 2 cases (4%) in L.A. versus 12 cases (24%) in O.A. complaint of prolonged paralytic ileus for more than 48 hours [37].

There were several explanations for the reduction of ileus following LA. Firstly, decreased handling of the bowel during the procedure leads to less postoperative adhesion, and such adhesion may be responsible for ileus. Secondly, patients after LA had less opiate analgesics, which inhibited bowel movements in the postoperative period. Lastly, earlier mobilization after LA may also contribute to the reduction of adhesion [26].

In agreement with other studies we were able to demonstrate that LA is a feasible and safe procedure [22].

Conclusion:

From the previous study we concluded that:

Laparoscopic appendectomy in complicated appendicitis is a safe and efficient procedure with lower incidence of complications and should be the initial choice for all patients with complicated appendicitis. Laparoscopic appendectomy has the advantage of shorter operative room time, less intra-operative complications, less post-operative complications, less time needed for oral intake, and shorter hospital stay.

References

- MUSBAHI A., RUDD D., DORDEA M., GOPINATH B. and KURUP V.: Comparison of the use of Alvarado and AIR scores as an adjunct to the clinical diagnosis of acute appendicitis in the pediatric population. *World Journal of Pediatric Surgery*, 2 (2): p.e000040. 2019.
- MWACHAKA P., EL-BUSAIDY H., SINKEET S. and OGENG'O J.: Variations in the position and length of the vermiform appendix in a black kenyan population. *ISRN anatomy*, 2014.
- MENTULA P., SAMMALKORPI H. and LEPPÄNIEMI A.: Laparoscopic surgery or conservative treatment for appendiceal abscess in adults? A randomized controlled trial. *Annals of surgery*, 262 (2): 237-42, 2015.
- JASCHINSKI T., MOSCH C.G., EIKERMANN M., NEUGEBAUER E.A. and SAUERLAND S.: Laparoscopic versus open surgery for suspected appendicitis. *Cochrane Database of Systematic Reviews*, 11, 2018.
- SORATE Y., JOSHI D. and PAWAR S.: A Prospective Study of Laparoscopic Appendectomy for the Treatment of Acute Appendicitis. *MVP Journal of Medical Science*, 5 (1): 21-5, 2018.
- DI SAVERIO S., BIRINDELLI A., KELLY M.D., CATENA F., WEBER D.G., SARTELLI M., SUGRUE M., DE MOYA M., GOMES C.A., BHANGU A. and AGRESTA F.: WSES Jerusalem guidelines for diagnosis and treatment of acute appendicitis. *World Journal of Emergency Surgery*, 11 (1): 34, 2016.
- FRUTOS M.D., ABRISQUETA J., LUJAN J., ABELLAN I. and PARRILLA P.: Randomized prospective study to compare laparoscopic appendectomy versus umbilical single-incision appendectomy. *Annals of Surgery*, 257 (3): 413-8, 2013.
- KHAN N.: Comparative Study between Laparoscopic Cholecystectomy vs Minimal Invasive Cholecystectomy 3-5 cm. *Ann. Pak. Inst. Med. Sci.*, 11 (3): 119-23, 2015.
- GARG C.P., VAIDYA B.B. and CHENGALATH M.M.: Efficacy of laparoscopy in complicated appendicitis. *International journal of surgery*, 7 (3): 250-2, 2009.
- KUMAR B., SAMAD A., KHANZADA T.W., LAGHARI M.H. and SHAIKH A.R.: Superiority of laparoscopic appendectomy over open appendectomy: The Hyderabad experience. *Rawal Med. J.*, 33 (2): 165-8, 2008.
- SOLTAN H.M., EL-TATAWY A.G. and ALSEGAIEY A.H.: Laparoscopic versus open appendectomy in complicated acute appendicitis. *Menoufia Medical Journal*, 32 (2): 554, 2019.
- KIM D.H., PARK J.H., JOO J.I., JEON J.Y. and LIM S.W.: The Overlapping Running Suture Method Using Single Knotless Barbed Absorbable Suture Material for Abdominal Wall Closure after Single Incision Laparoscopic Appendectomy: Comparison with the Traditional Interrupted Closure Technique. *Journal of Minimally Invasive Surgery*, 21 (4): 160-7, 2018.
- MANDRIOLI M., INABA K., PICCININI A., BISCARDI A., SARTELLI M., AGRESTA F., CATENA F., CIROCCI R., JOVINE E., TUGNOLI G. and DI SAVERIO S.: Advances in laparoscopy for acute care surgery and trauma. *World journal of gastroenterology*, 22 (2): 668, 2016.
- KATKHOUDA N., MASON R.J. and TOWFIGH S.: Laparoscopic versus open appendectomy: A prospective, ran-

- domized, double-blind study. *Advances in Surgery*, Sep. 1; 40: 1-9, 2006.
- 15- CUETO J., D'ALLEMAGNE B., VAZQUEZ-FRIAS J.A., GOMEZ S., DELGADO F., TRULLENQUE L., FAJARDO R., VALENCIA S., POGGI L., BALLI J. and DIAZ J.: Morbidity of laparoscopic surgery for complicated appendicitis: an international study. *Surgical Endoscopy And Other Interventional Techniques*, 20 (5): 717-20, 2006.
 - 16- ROCHA L.L., ROSSI F.M., PESSOA C.M., CAMPOS F.N., PIRES C.E. and STEINMAN M.: Antibiotics alone versus appendectomy to treat uncomplicated acute appendicitis in adults: What do meta-analyses say?. *World Journal of Emergency Surgery*, 10 (1): 51, 2015.
 - 17- MASOOMI H., NGUYEN N.T., DOLICH M.O., MILLS' S., CARMICHAEL J.C. and STAMOS M.J.: Laparoscopic appendectomy trends and outcomes in the United States: data from the Nationwide Inpatient Sample (NIS), 2004-2011. *The American Surgeon*, 80 (10): 1074-7, 2014.
 - 18- THOMSON J.E., KRUGER D., JANN-KRUGER C., KISS A., OMOSHORO-JONES J.A., LUVHENG T. and BRAND M.: Laparoscopic versus open surgery for complicated appendicitis: A randomized controlled trial to prove safety. *Surgical endoscopy*, 29 (7): 2027-32, 2015.
 - 19- MISHRA R.K., HANNA G.B. and CUSCHIERI A.: Laparoscopic versus open appendectomy for the treatment of acute appendicitis. *World J. of Laparoscopic Surg.*, 1 (1): 19-28, 2008.
 - 20- GALLI R., BANZ V., FENNER H. and METZGER J.: Laparoscopic approach in perforated appendicitis: Increased incidence of surgical site infection?. *Surgical endoscopy*, 27 (8): 2928-33, 2013.
 - 21- SHIMODA M., MARUYAMA T., NISHIDA K., SUZUKI K., TAGO T., SHIMAZAKI J. and SUZUKI S.: Comparison of clinical outcome of laparoscopic versus open appendectomy, single center experience. *Heliyon*, 4 (5): e00635, 2018.
 - 22- SAUERLAND S., JASCHINSKI T. and NEUGEBAUER E.A.: Laparoscopic versus open surgery for suspected appendicitis. *Cochrane Database of Systematic Reviews*, (10), 2010.
 - 23- FUKAMI Y., HASEGAWA H., SAKAMOTO E., KOMATSU S. and HIROMATSU T.: Value of laparoscopic appendectomy in perforated appendicitis. *World journal of surgery*, 31 (1): 93-7, 2007.
 - 24- KATSUNO G., NAGAKARI K., YOSHIKAWA S., SUGIYAMA K. and FUKUNAGA M.: Laparoscopic appendectomy for complicated appendicitis: a comparison with open appendectomy. *World journal of surgery*, Feb. 1; 33 (2): 208-14, 2009.
 - 25- CIPE G., IDIZ O., HASBAHCECI M., BOZKURT S., KADIOGLU H., COSKUN H., KARATEPE O. and MUSLUMANOGLU M.: Laparoscopic versus open appendectomy: Where are we now. *Chirurgia (Bucur)*, 109 (4): 518-22., 2014.
 - 26- LI X., ZHANG J., SANG L., ZHANG W., CHU Z., LI X. and LIU Y.: Laparoscopic versus conventional appendectomy-a meta-analysis of randomized controlled trials. *BMC gastroenterology*, 10 (1): 129, 2010.
 - 27- SCHLOTTMANN F., SADAVA E.E., PEÑA M.E. and ROTHOLTZ N.A.: Laparoscopic appendectomy: Risk factors for postoperative intraabdominal abscess. *World journal of surgery*, 41 (5): 1254-8, 2017.
 - 28- EVASOVICH M.R., CLARK T.C., HORATTAS M.C., HOLDA S. and TREEN L.: Does pneumoperitoneum during laparoscopy increase bacterial translocation?. *Surgical endoscopy*, 10 (12): 1176-9, 1996.
 - 29- ASARIAS J.R., SCHLUSSEL A.T., CAFASSO D.E., CARLSON T.L., KASPRENSKI M.C., WASHINGTON E.N., LUSTIK M.B., YAMAMURA M.S., MATAYOSHI E.Z. and ZAGORSKI S.M.: Incidence of postoperative intraabdominal abscesses in open versus laparoscopic appendectomies. *Surgical Endoscopy*, 25 (8): 2678-83, 2011.
 - 30- HORVATH P., LANGE J., BACHMANN R., STRULLER F., KÖNIGSRAINER A. and ZDICHAVSKY M.: Comparison of clinical outcome of laparoscopic versus open appendectomy for complicated appendicitis. *Surgical endoscopy*, 31 (1): 199-205, 2017.
 - 31- GUPTA R., SAMPLE C., BAMEHRIZ F. and BIRCH D.W.: Infectious complications following laparoscopic appendectomy. *Canadian Journal of Surgery*, 49 (6): 397, 2006.
 - 32- PISKUN G., KOZIK D., RAJPAL S., SHAFTAN G. and FOGLER R.: Comparison of laparoscopic, open, and converted appendectomy for perforated appendicitis. *Surgical Endoscopy*, 15 (7): 660-2, 2001.
 - 33- MOORE C.B., SMITH R.S., HERBERTSON R. and TOEVS C.: Does use of intraoperative irrigation with open or laparoscopic appendectomy reduce post-operative intra-abdominal abscess?. *The American Surgeon*, 77 (1): 78-80, 2011.
 - 34- TAGUCHI Y., KOMATSU S., SAKAMOTO E., NORIMIZU S., SHINGU Y. and HASEGAWA H.: Laparoscopic versus open surgery for complicated appendicitis in adults: A randomized controlled trial. *Surgical Endoscopy*, 30 (5): 1705-12, 2016.
 - 35- ZHANG S., DU T., JIANG X. and SONG C.: Laparoscopic appendectomy in children with perforated appendicitis: A meta-analysis. *Surgical Laparoscopy Endoscopy & Percutaneous Techniques*, 27 (4): 262-6, 2017.
 - 36- HELLBERG A., RUDBERG C., KULLMAN E., ENOCHSSON L., FENYÖ G., GRAFFNER H., HALLERBÄCK B., JOHANSSON B., ANDERBERG B., WENNER J. and RINGQVIST I.: Prospective randomized multicentre study of laparoscopic versus open appendectomy. *British Journal of Surgery*, 86 (1): 48-53, 1999.
 - 37- BRÜMMER S., SOHR D. and GASTMEIER P.: Intra-abdominal abscesses and laparoscopic versus open appendectomies. *Infection Control & Hospital Epidemiology*, 30 (7): 713-5, 2009.

دراسة لتقييم فاعلية وأمان المنظار الجراحي فى علاج حالات التهاب الزائدة الدودية المصاحب بمضاعفات

يعد التهاب الزائدة الدودية الأكثر شيوعاً في حالات الطوارئ الجراحية فى البطن فى العالم. معظم المرضى يعانون من أعراض مثل الألم والقيء وتأخير الحمى التى يؤدى إلى مضاعفات؛ مثل الخراج، التهاب الزائدة الدودية، الغرغرينا، ثقب و التهاب الصفاق حيث تكون الجراحة هى الخيار الانسب للعلاج. إن منظار البطن الجراحي هو إجراء أقل اعتلالاً؛ مما يؤدى عادة إلى الشفاء التام بعد العملية الجراحية للعديد من العمليات الجراحية.

تم الحصول على موافقة مستنيرة من جميع المرضى المشاركين فى هذه الدراسة ومعرفة المخاطر والمضاعفات الوارد حدوثها وتحويل العملية إلى فتح جراحى.

يعتمد تشخيص المرضى على النتائج السريرية، وصورة الدم، والموجات فوق الصوتية للبطن.

تتكون هذه الدراسة المستقبلية من (٤٠) مريضاً، سيخضعون لاستئصال الزائدة الدودية بالمنظار

وإثناء الدراسة تم تقييم وقت العملية (الوقت من الشق الجراحى حتى إغلاق الجرح) وحالة الزائدة أثناء إجراء العملية ومضاعفات أثناء العملية مثل التحول الى فتح جراحى ومضاعفات ما بعد العملية.

إن استئصال الزائدة الدودية بالمنظار هو آمن ومجدى فى علاج التهاب الزائدة الدودية الحاد المصاحب بمضاعفات، ومن مميزات استئصال الزائدة الدودية عن طريق منظار البطن الجراحى - مقارنة بالطريقة المفتوحة التقليدية - الإقامة القصيرة فى المستشفى، والعودة إلى النشاط بشكل أسرع، وتخفيف الألم، والحصول على نتائج تجميلية أفضل، ومضاعفات أقل أثناء وبعد العملية.