

GENDER DETERMINATION BY MANDIBULAR C.B.C.T SCANS IN A SAMPLE OF AN EGYPTIAN POPULATION

Masar A. Qaraghoul^{1*} BDS, Hassan M. Abouelkeir² PhD, Rania A. Fahmy³ PhD

ABSTRACT

BACKGROUND: Mandibular parameters can help in sex determination. Sex determination is crucial in character recognition for social and legal reasons.

OBJECTIVES: The current research aimed to assess the precision of mandibular characteristics (coronoid height and projective ramus height) measured by cone beam computed tomography (CBCT) images for identifying sex among a sample of Egyptians.

METHODOLOGY: Two parameters were analyzed on 60 CBCT scans (30 males, 30 females) adults over the age of 18. The coronoid height and projective ramus height were inspected on CBCT images to determine sex. Using the mouse-driven method, millimeter-based parameters were measured.

RESULTS: The measured variables (coronoid height and projective ramus height) showed a statically significant difference between both sexes. With an overall prediction accuracy of 84.2%

CONCLUSION: The mandibular ramus has a high degree of specificity for sex identification by CBCT scans.

KEYWORDS: Mandibular ramus, CBCT, Forensic science, Sex determination

RUNNING TITLE: Is mandibular ramus measurements can determination sex?

1 BDS 2013, Oral Medicine, Periodontology, Oral Diagnosis and Oral Radiology Department, Faculty of Dentistry, Alexandria University, Alexandria, Egypt

2 Professor of Oral Medicine, Periodontology, Oral Diagnosis and Oral Radiology Faculty of Dentistry, Alexandria University, Egypt

3 Assistant Professor of Oral Medicine, Periodontology, Oral Diagnosis and Oral Radiology Faculty of Dentistry, Alexandria University, Egypt

* Corresponding Author:

E-mail: masar.abdalkhalek.dent@alexu.edu.eg

INTRODUCTION

Determining age, sex, stature, and ethnicity is crucial in determining the anatomical profiles of the body remains (1). The identification involves evaluating an individual's various characteristics and looking for similarities determined by previous records (2).

In the current forensic inquiry records, the victim identities are frequently concealed through mutilation and amputation. In cases of a major disaster, sex can be identified with absolute certainty, ranging between 90%–100%, if the adult skeleton is available. Frequently, in such instances, identification is difficult since bones are completely or partially fragmented. (2,3,4).

Each community has unique assessment standards (5). Bone factors that are dimorphic need reliable differential analytical techniques. Visible morphological and metric parameters are reliable and reproducible. Therefore, reliable discriminatory analytical techniques are required for fragmented dimorphic bone (6).

The skull and pelvis bones are the most dimorphic, making them the most important. Without the skull, the mandible can help determine sex (7). The most

dimorphic and strongest skull bone, the mandible, determines sex because males and females mature differently (8).

The mandible has numerous sex-determining characteristics. During growth, the morphological, sizing, and remodeling effects of mastication forces, particularly in the mandible ramus, differ significantly between males and females. The mandible facilitates sex identification in both living and dead humans (9).

Morphometric evaluations of cone beam computed tomography CBCT, orthopantomography (OPT), and dry mandibular images in several studies showed significant sex differences in osteometric parameters like mandibular length, bigonial breadth, bicondylar breadth, coronoid height, and ramus height and breadth. Male parameters were significantly higher (10). Forensic professionals frequently use cone-beam computed tomography imaging for postmortem imaging, particularly in skeletal situations. Many authors have evaluated individuals using anthropometric parameters derived from 3D axial and reconstructed sagittal mandibular CBCT scans (5). This study uses CBCT scans to determine the sex dimorphism of the mandibular bone.

MATERIAL AND METHODS

1. Study design

The mandibular ramus measurements were evaluated retrospectively following the Standards for Reporting Diagnostic accuracy studies STARD (11) recommendations. The study used a sample of sixty CBCTs that satisfied the criteria for exclusion and inclusion. Retrospective CBCT scans were obtained from the Oral Radiology Unit of the Faculty of Dentistry at the University of Alexandria. The Alexandria University Accountable Committee's ethical standards (IRB No. 0390-02/2022) were followed in all procedures. There was no need for informed consent because each CBCT was assumed to be anonymous.

2. Sample Size

The sample size was calculated assuming 80% study power and 5% alpha error. Okkesim and Erhamza⁽⁶⁾ reported the different mandibular parameters that were used to calculate the minimum -required number of patients. Based on a comparison of means, the sample size was calculated to be 30 per group. The total sample size required= the number of groups × number per group= 2 × 30= 60.⁽⁶⁾

Criteria for scan selection

Inclusion criteria

- Patients over 18
- Dentate patient
- The area of measurement was without any bone degenerative changes
- **Exclusion criteria**
- Radiographs showed oral-maxillofacial surgical interventions (any scan having fixation wires or screws was excluded especially in the measurements area)
- Artifacts and distortions in the images.

4. Data collecting and images analysis

Acquiring CBCT scans

Cone beam computed tomography images were obtained using the I-CAT Next Generation high-resolution imaging equipment (Imaging Sciences International, Hatfield, Pa). A standard method says that the I-CAT should have been used on the same equipment (120 kVp , 5mA, acquisition 26.9 seconds, and 0.25 voxel size). All scans with Field of View (FOV) 16×13 were included, and images were assessed directly on the monitor screen (Monitor 15.6 -inch) HD (1366 X 768) Pixels Lenovaidepad 130 PC. To minimize inter- and intra-observer differences, each image evaluated blindly and independently by two observers (radiologist and the student) during two distinct sessions separated by two weeks.

Cone -beam -computed tomography data analysis

Data from CBCT scans that had been exported in the Digital Imaging and Communications in Medicine (DICOM) format used by Cybermed, Inc. to reconstruct a 3D volume, image analysis, and evaluation performed by OnDemand3D™ software

Ramus measurements

The 3D view window was maximized. Start segmentation with the knife to gain the mandible's left or right side, The segmentation knife was used to cut 25 cm-long segments out of the skull on the left side of the operator's screen. For standardization of the measurement, we draw three lines at the highest point of the condylar head and coronoid to determine their most cranial extent and a third line at the angle of the mandible. The desired values were measured with a ruler.

The 3D view was adopted to start the project. The measurements (12) were:

- Coronoid height: measured along the coronoid process' long axis, running from the coronoid point to the sigmoid notch plane.
- Mandibular ramus height: the estimated distance between the highest point of the mandibular condyle and the intersection of its posterior and inferior planes.

Mandibular ramus measures are seen in **Figure (1)**.

Statistical analysis

Normality was checked for all variables using descriptive statistics, plots (histogram, boxplots, and Q-Q plots) normality tests. All variables showed a normal distribution, so means and Standard Deviation (SD) were calculated. Independent samples t-test was used for comparisons of CBCT measurements between males and females while comparing the right and left sides of each sex was performed using paired t-test. Mean differences and 95% Confidence Intervals (CI) were calculated. Data were analyzed using IBM SPSS for Windows (Version 23).

RESULT

In the current study, 60 CBCT scans (30 females, 30 males) were examined to evaluate the selected ramus parameters (coronoid height and projective ramus height)

Table (1) Descriptive statistics of the values of the measurements for both females and males.

The mean and standard deviation of the coronoid height in males and females were found to be 14.46 (2.86) mm, 11.48 (2.78) mm respectively and the projective ramus height was 61.88 (5.27) mm, and 56.33 (4.08) mm in males and females respectively. There was the statistically significant difference was observed between males and females in both parameters whereas confidence interval of the projective ramus height was 5.56 mm and 2.98 mm for coronoid height. Both measured values were significant.

Table (2) Calibration on mandibular measurements was performed for two examiners; inter- and intra-examiner reliability was calculated, and the ICCs were classified using a system suggested by Koo and Li⁽¹³⁾ (2016) as follows: less than 0.50 Z poor agreement; 0.50 to less than 0.75 Z moderate agreement; 0.75 to 0.90 Z Good agreement; Above

0.90 Z Excellent agreement. A P value less than 0.05 was considered statistically significant The intraclass correlation coefficient varied from 0.791 to 0.898, exhibiting good agreement.

Figure (2,3) the ROC curve (receiver operating characteristic curve) for CBCT measurements of both sides.

Figure (2) the projective ramus height had an acceptable ability to predict females (AUC = 0.792).

Figure (3) the Coronoid height had an acceptable ability to predict females (AUC = 0.787).

Generally, an area under the curve AUC of 0.5 shows that the test cannot differentiate between patients. Patients with and without an A score of 0.7 and 0.8 are acceptable for a disease or condition, with excellent scores of 0.8to0.9, and remarkable values greater than 0.9.

Table (3) Agreement (sensitivity, specificity) for mandibular CBCT measurements of both sides to diagnose females from males

A projective ramus height of more than 60.85 mm indicated male and a projective ramus height of less than 60.85 mm indicated female, with a specificity of 71.43%.

A coronoid height greater than 12.15 mm indicated the male sex and a coronoid height less than 12.15 mm indicated the female sex, with a specificity of 92.86%

Table (4) Sex was correctly identified in 26 of 30 female CBCT scans with (85% accuracy) and 24 of 30 male CBCTscanswith (83.3% accuracy).

Table (1): Comparison of CBCT measurements of both sides of the mandible between males and females

	Males	Females	Difference (95% CI)	T-test P value
	Mean (SD)			
Coronoid height	14.46 (2.86)	11.48 (2.78)	2.98 (1.54, 4.43)	<0.001*
Projective ramus height	61.88 (5.27)	56.33 (4.08)	5.56 (3.19, 7.93)	<0.001*

SD: Standard Deviation, CI: Confidence Interval
*statistically significant at p value <0.05

Table 2: Reliability assessment

	Intra-examiner reliability		Intra-examiner reliability	
	ICC (95% CI)	P value	ICC (95% CI)	P value
Coronoid height	0.881 (0.851 - 0.912)	<0.001*	0.881 (0.851 - 0.912)	<0.001*
Mandibular ramus height	0.791(0.711 -0.842)	<0.001*	0.791(0.711 -0.842)	<0.001*

ICC: Intraclass correlation coefficient, CI: Confidence Interval

Is mandibular ramus measurements can determination sex

Table (3) : Agreement (sensitivity, specificity) for mandibular CBCT measurements of both sides to diagnose females from males

	Sensitivity	Specificity	AUC	Cutoff value (mm)	P value of AUC
Coronoid Height	61.11%	92.86%	0.76	F ≤12.15 <M	0.004*
Projective Ramus height	88.89%	71.43%	0.83	F ≤60.85 <M	<0.001*

AUC: Area under curve, F: Female, M: Male

Table (4) Prediction accuracy

	Predicted group		Total	% Accuracy
	Female	Male		
Sex group				
Female	26	4	30	85.0
Male	6	24	30	83.3
Overall Percentage				84.2

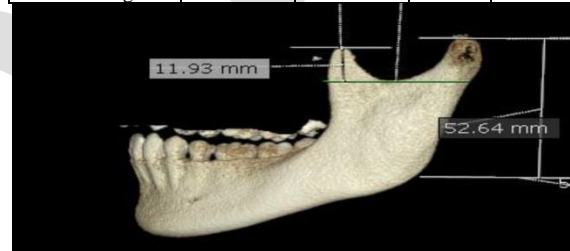


Figure 13d volume rendering view showing liner measurement

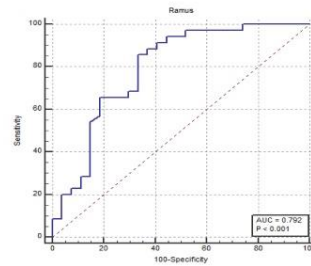


Figure 2: the ROC curve (receiver operating characteristic curve) for projective ramus height of both sides.

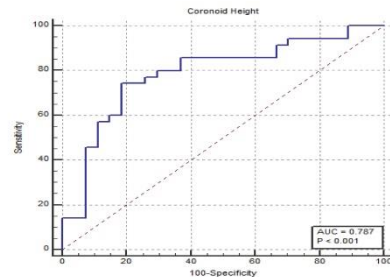


Figure 3: the ROC curve (receiver operating characteristic curve) for coronoid height of both sides.

DISCUSSION

When a complete skull is unavailable, anthropometry of the face and intraoral regions can be used to identify sex. (14).

This study examined the accuracy of some mandibular ramus features for identifying sex in an Egyptian population using CBCT imaging. Sex dimorphism revealed that there were statistically significant differences in coronoid height and projective ramus height between males and females. The age range in this research was over 18 years old as the skull reached full growth(15).

The coronoid height has an acceptable ability to predict females, (AUC;0.787). More than 12.15 mm indicated males and less than 12.15 indicate females with a sensitivity of 61.11%. Projective ramus height has an excellent ability to predict females (AUC of 0.792). More than 60.85 mm indicates male and less than 60.85 mm indicates female, with sensitivity 88.89%, the overall prediction accuracy was 84.2%.

In this study, the overall prediction accuracy was 84.2; similarly, Saini et al. (4) reported that coronoid height had a 74.1% accuracy rate in determining an Indian's sex. Our findings were in accordance with Datta et al; among the parameters measured, they conclude that the most accurate mandibular indicators of sexual dimorphism are the coronoid height and ramus height (16).

When using panoramic images, Ranaweera et al found that the measured variables (maximum ramus breadth, condylar height, coronoid height, projective height, and minimum ramus breadth) recorded significant differences between females and male particularly condylar height was discovered to be more accurate in determining sex (17). While Dayal et al. (18) reported that the ideal variable was found to be mandibular ramus height in the study with a 75.8% accuracy rate. In our study, the projective ramus height recorded acceptable prediction accuracy with range (AUC 0.792) while the excellent scores of 0.8 to 0.9 according to the ROC curve scores

In this study, the predictive accuracy for females and males were (85%, and 83.3%)respectively similarly, Both measurement coronoid height, and projective ramus height, with a statistical significance of $P = 0.005$, were found to be for coronoid height and projective ramus height. 0.004^* , and $<0.001^*$, respectively . Samatha et al. found that the predictability of projective ramus height and coronoid height was 53% for men and 60% for women (19). The best measurement, with a statistical significance of $P = 0.005$, was found to be the mandibular ramus height.

Wankhede et al. (20) studies on varied mandibular parameters and ramus height presented the most accurate sex dimorphism, with an accuracy rate ranging from 81.7% to 85.4% in the Central Indian population, these findings were very close to our

finding whereas the accuracy rate ranging from 83.3% to 85 %

This study confirms the findings of a study by Abu-Taleb et al. (21), who found that men had more ramus metric variables than women and that their calculations were accurate 79.6% of the time.

The outcomes of our study support this as well. Ishwarkumar et al. (22) in South Africa found that the mandibular ramus exhibits the highest sexual dimorphism (P -value = 0.000). The right and left mandibular ramus lengths were significant with sex ($P = 0.040$).

Sambhana et al.'s Indian study (8) found that the mandible's dimorphic accuracy was improved by 50% to 74.7% when only one variable, like mandibular height or coronoid height, was considered. The prediction percentage increased to 75.8% when the ten variables that were examined were used, and women were easier to predict these findings support our investigation, where we used two parameters that explain the raised prediction overall accuracy of 84.2%.

Our results do not agree with the findings of Rai et al., (23) who used measurements of the mandible in a group of Indians ranging from 7 to 20 years to determine sex. The investigators measured the length of the body of the mandible (the distance between the condylion superior and the gnathion), mandibular length (distance between the condylion and the gnathion), and mandible height (distance between the condylion and the gonion). They concluded that mandibular measurements provide information on the age but not the sex, as they found no difference between males and females in the mandibular linear growth.

Furthermore, Motawei et al. reported that ramus length aids in determining an individual's median age (24). These finding dis agrees with our findings

A study by Ishwarkumar et al., (22) in South Africa concluded that the length of the mandibular ramus generally has higher sexual dimorphism than any other mandibular segments (P -value = 0.000). The authors found that the length of the mandibular ramus on the right and left sides were statistically significant with sex (P -value = 0.040) and that disagrees with our findings where there was no statistically significant difference.

Hazari et al., (25) reviewed articles that studied the mandible as a tool for age and sex identification. They stated that out of 16 radiographic studies, 14 showed that the adult mandible could be used with increased sensitivity to identify sex, and two studies showed insignificant results. Of the 20 morphometric studies of dry mandibles, 15 studies showed a positive correlation between sex and mandibular parameters, and five studies did not show any positive correlations between the two parameters

Our findings differ from those of all previous studies because of differences in imaging modality, sample size, and populations. To obtain results that can be used to more precisely identify sex, we urge the conduct of additional thorough studies on a larger number of cases, larger age scales, and different governorates in Egypt and on a larger sample size, larger age ranges, and different governorates to produce results that can be used to more precisely identify sex.

CONCLUSION

According to the findings of this study, there were differences between males and females in coronoid height and projective ramus height. In comparison to an identified individual's standard, these results can be used to identify an individual's sex. Cone beam computed tomography can accurately determine sex based on projective ramus height and coronoid height. Sex can be predicted with projective ramus height with a sensitivity of 88.89% and a specificity of 71.43.

CONFLICT OF INTEREST

The authors declare that they have no conflicts of interest

FUNDING

No funding was received for conducting this study.

REFERENCES

- Garg R, Jacky T, Yung TG, Li YW, Brahanudin TM. To assess the usefulness of the Mandibular Ramus in determining Age and Gender among Malaysians in digital OPGs. *J Int Dent Medical Res.* 2021;14:1472-7.
- Saini V, Srivastava R, Rai RK, Shamal SN, Singh TB, Tripathi SK. Mandibular ramus: An indicator for sex in fragmentary mandible. *J Forensic Sci.* 2011 Jan;56:S13-6.
- Franklin D, O'Higgins P, Oxnard CE, Dadour I. Discriminant function sexing of the mandible of indigenous South Africans. *Forensic Sci Int.* 2008;179:84.e1-5.
- Indira AP, Markande A, David MP. Mandibular ramus: An indicator for sex determination-A digital radiographic study. *J Forensic Dent Sci.* 2012;4:58-62.
- Kharoshah MA, Almadani O, Ghaleb SS, Zaki MK, Fattah YA. Sexual dimorphism of the mandible in a modern Egyptian population. *J Forensic Leg Med.* 2010;17:213-5.
- Okkesim A, Erhamza TS. Assessment of mandibular ramus for sex determination: Retrospective study. *J Oral Biol Craniofac Res.* 2020;10:569-72.
- Mostafa RA, Abou El-Fotouh M. Mandibular morphometric analysis for sex assessment: A retrospective radiographic study. *J. Indian Acad. Oral Med. Radiol.* 2020;32:266-70.
- Sambhana S, Sanghvi P, Mohammed RB, Shanta PP, Thetay AA, Chaudhary VS. Assessment of sexual dimorphism using digital orthopantomographs in South Indians. *J Forensic Dent Sci.* 2016;8:180.
- Humphrey LT, Dean MC, Stringer CB. Morphological variation in great ape and modern human mandibles. *The Anat.* 1999;195:491-513.
- El-Sherbiny MO, El-Shafey MO, Hend M, Rania NS. Sexual Dimorphism of Mandibular Ramus in an Egyptian Sample: A Radiographic Study. *Med J Cairo Univ.* 2019;87:645-51
- Cohen JF, Korevaar DA, Altman DG, Bruns DE, Gatsonis CA, Hooft L, et al. STARD 2015 guidelines for reporting diagnostic accuracy studies: explanation and elaboration. Translation to Russian. *Digital Diagnostics.* 2021;2:313-42.
- Al-Gunaid TH. Sex-related variation in the dimensions of the mandibular ramus and its relationship with lower third molar impaction. *J Taibah Univ Med Sci.* 2020;15:298-304.
- Koo TK, Li MY. A guideline of selecting and reporting intraclass correlation coefficients for reliability research. *Journal of chiropractic medicine.* 2016 Jun 1;15(2):155-63.
- Raj JD, Ramesh S. Sexual Dimorphism in Mandibular Ramus of South Indian Population. *J. Anthropol.* 2013;9:253-8.
- Morriss-Kay GM, Wilkie AO. Growth of the normal skull vault and its alteration in craniosynostosis: insights from human genetics and experimental studies. *Journal of anatomy.* 2005 Nov;207(5):637-53.)
- Datta A, Siddappa SC, Gowda VK, Channabasappa SR, Shivalingappa SB, Dey D. A study of sex determination from human mandible using various morphometrical parameters. *Indian J Forensic Community Med.* 2015;2:158-66.
- Ranaweera WG, Chandrasekara CM, Hraputhanthii HD, De Silva P, Herath LH. Sex determination by mandibular ramus-a digital panoramic study. *Sri Lanka J Forensic Med Sci Law.* 2020 May 17;11(1):10-9.)
- Dayal MR, Spocter MA, Bidmos MA. An assessment of sex using the skull of black South Africans by discriminant function analysis. *Homo. J Comp Hum Biol.* 2008;59:209-21.
- Samatha K, Byahatti SM, Ammanagi RA, Tantradi P, Sarang CK, Shivpuje P. Sex determination by mandibular ramus: A digital orthopantomographic study. *J Forensic Dent Sci.* 2016;8:95-8.
- Wankhede KP, Bardale RV, Chaudhari GR, Kamdi NY. Determination of sex by discriminant function analysis of mandibles from a Central Indian population. *J Forensic Dent Sci.* 2015;7:37-43

21. Abu-Taleb NS, ElBeshlawy DM. Low-dose cone-beam computed tomography in simulated condylar erosion detection: a diagnostic accuracy study. *Oral Radiol.* 2021;37:427-35.
22. Ishwarkumar S, Pillay P, Haffajee MR, Satyapal KS. Morphometric analysis of the mandible in the Durban Metropolitan population of South Africa. *Folia Morphol (Warsz).* 2017;76:82-6.
23. Rai B, Krishan K, Kaur J, Anand SC. Age estimation from mandible by lateral cephalogram: a preliminary study. *J Forensic Odontostomatol.* 2008;27:24-8.
24. Motawei SM, Helaly AM, Aboelmaaty WM, Elmahdy K, Shabka OA, Liu H. Length of the ramus of the mandible as an indicator of chronological age and sex: A study in a group of Egyptians. *Forensic Science International: Reports.* 2020 Dec 1;2:100066.
25. Hazari P, Hazari RS, Mishra SK, Agrawal S, Yadav M. Is there enough evidence so that mandible can be used as a tool for sex dimorphism? A systematic review. *Journal of forensic dental sciences.* 2016 Sep;8(3):174.

ADJ