

ACCURACY OF COMPUTER-ASSISTED DESIGN AND MANUFACTURED (CAD/CAM) THREE- DIMENSIONAL (3D) DEVICE FOR CONDYLAR POSITIONING IN MANDIBULAR BILATERAL SAGITTAL SPLIT OSTEOTOMY (CLINICAL TRIAL)

Aliaa A Habib^{1*}DSc, Ahmed A Sharara¹PhD, Tarek N Yousry²PhD,
Ahmed O Swidan¹PhD

ABSTRACT

INTRODUCTION: Alignment of dental arches in orthognathic treatment after undergoing Le Fort I osteotomy or bilateral sagittal split osteotomy relies on the use of intermediate and final occlusal splints, which do not provide precise control over the positioning of the condyle and ramus segments.

AIM OF THE STUDY: To clinically and radiographically assess the accuracy of CAD/CAM surgical guide for condylar positioning in the bilateral sagittal split osteotomy.

MATERIALS AND METHODS: The study recruited eight patients who had non-syndromic dentofacial deformity and underwent Bilateral Sagittal Split Osteotomy (BSSO) with or without maxillary osteotomy. Surgery was planned according to (CAD/CAM) technology. After osteotomy, a preoperative guide was used, followed by a repositioning guide. Computed tomography scans were conducted on all patients one week preoperatively, immediately, and three months postoperatively to assess the condylar position and facial symmetry.

RESULTS: The data are presented as median values with the 25th and 75th percentiles. Eight patients (37.50% females and 62.50% males) between the ages of 19 and 24 underwent BSSO with or without LeFort I maxillary advancement. The surgical procedure successfully corrected their skeletal deformities. The absolute change between immediate postoperative and preoperative condylar angle was 0.15 [0.00-0.3]°. The absolute change between three months postoperative and preoperative Condylar Angle was 0.20 [0.00-0.30]°.

CONCLUSION: The stability of the condylar head in position and patient postoperative occlusion is well assessed by 3D condylar positioning devices designed and manufactured by CAD/CAM technology in the mandibular BSSO.

KEYWORDS: Computer-Aided Design, Computer-Aided Manufacturing, Mandibular Condyle, Osteotomy, Sagittal Split Ramus.

RUNNING TITLE: Accuracy of CAD/CAM 3D Device for Condylar Positioning in Mandibular BSSO

1 Oral and Maxillofacial Surgery Department, Faculty of Dentistry, Alexandria University

2 Associate Professor of Oral and Maxillofacial Surgery, Faculty of Dentistry, Alexandria University.

3 Orthodontics Department, Faculty of Dentistry, Alexandria University

4 Associate Professor of Oral and Maxillofacial Surgery, Faculty of Dentistry, Alexandria University

* Corresponding Author:

E-mail: draliaahabib@gmail.com

INTRODUCTION

Orthognathic surgery ranks among the most commonly popular techniques to improve facial aesthetics. This surgery may be performed for functional or growth-related reasons in cases with severe Class III occlusion or patients with syndromic or facial clefts ⁽¹⁾. Orthognathic surgery involves surgically modifying the mandible or maxilla to properly align and position the bones and teeth about the skull base. In particular, for individuals with dentofacial deformity, orthognathic surgery and

orthodontic therapy effectively correct malocclusion⁽²⁾.

The conventional orthognathic treatments used today to treat dentofacial deformity include adjunctive operations to enhance the shapes of the hard and soft tissues. Additional surgical procedures that can be performed alongside orthognathic surgery include genioplasty (using either osseous or alloplastic techniques), septorhinoplasty, and neck suction lipectomy⁽³⁾. Surgical repair can range from relocating

a few teeth to completely realigning the mandible and maxilla, depending on the issue's severity. This procedure provides a stable dental arch, effective occlusion, facial and dental symmetry, and healthy orofacial tissues⁽⁴⁾.

The orthognathic technique of BSSO, a commonly utilized procedure, is frequently employed to treat dentofacial deformities. Maintaining condylar position during BSSO remains a technically challenging aspect and can be influenced by the surgeon's experience level. Most maxillofacial surgeons manually position the condylar process within the superior and posterior regions of the glenoid fossa as part of an intuitive repositioning method⁽⁵⁾. Condyle repositioning abilities must be acquired to pass the BSSO exam and prevent harm to the temporomandibular joint. Improper positioning of the condyles is recognized as one of the causal mechanisms that can have detrimental effects on the temporomandibular joint, along with various other issues⁽⁶⁾.

Preserving the condylar position after BSSO is of utmost importance for optimal condylar function, just as it is in the preoperative stage. Condyle sagging, loss of the mandibular angle, internal derangement of the joint, higher risk of relapse, and reduced masticatory function can all result from a changed condylar position⁽⁷⁾. Although most surgeons understand how important it is to realign the condyle, the decision to refrain from performing this procedure is based on several factors, including its high cost, time-consuming nature, the requirement for additional equipment, longer duration of the surgery, patient adaptation needs, and the necessity for advanced surgical expertise in orthognathic procedures⁽⁸⁾. Regardless of the kind of osteotomy and the direction of mandibular movement, a noticeable correlation exists between condylar position and skeletal/occlusal stability⁽⁹⁾. It is widely acknowledged that alterations in condyle position following the surgery may not only encourage the onset of signs and symptoms of temporomandibular disorders. However, it may also result in malocclusion, which raises the possibility of an early or late recurrence⁽¹⁰⁾.

Several approaches have been suggested for placing the proximal portion of the BSSO. In 1976, Leonard was the first to advocate utilizing such a manual. This method kept the ramus from rotating but lacked the sensitivity to accurately recreate the condyle location in all three spatial planes⁽¹¹⁾. Various tools assist in aligning the proximal segment in the anteroposterior (sagittal) direction plane and avoiding rotation has been described in the literature. However, the inability to reproduce the exact condylar position in all three spatial planes persists⁽¹²⁾.

The majority of them use a connection of some kind. Before the osteotomy is finished, insert something firm; similar to a pin, and a connection is established from the proximal segment to the maxillary dentition. Once the distal portion is secured using maxillo-mandibular fixation (MMF), the pin is partially reinserted to realign the proximal segment⁽¹³⁾. Current developments in CAD/CAM technology and Virtual Surgical Planning (VSP) have enhanced preoperative planning, expedited the creation of surgical splints, and demonstrated a high degree of accuracy compared to conventional techniques⁽¹⁴⁾.

Among the various tools available for assisting surgeons in condylar repositioning, computer-assisted navigation can be regarded a valuable diagnostic tool for managing condylar placement⁽¹⁵⁾.

The study aimed to evaluate clinically and radiographically assess the accuracy of CAD CAM surgical guide for condylar positioning in the bilateral sagittal split osteotomy. The null hypothesis of this study will be that there is no significant difference in the accuracy of the position of the condyles with or without using CAD/CAM 3D surgical guide in the bilateral sagittal split osteotomy.

MATERIALS AND METHODS

The study was conducted following the ethical approval granted by the Research Ethics Committee of the Alexandria University Faculty of Dentistry.

Patients

This study involved eight patients from the Alexandria University Outpatients' Clinics of Oral and Maxillofacial Department, Faculty of Dentistry, Alexandria University, Egypt; the study involved individuals who presented with craniofacial deformities that necessitated BSSO with or without maxillary osteotomy. Before the surgery, all patients provided informed consent by signing the appropriate documentation at the Oral and Maxillofacial Surgery Department of Alexandria University's Faculty of Dentistry. Treatment incorporating Virtual Surgical Planning (VSP) and CAD-CAM, which guaranteed precise positioning of the condyles in the glenoid fossae in centric relation (CR) during the BSSO procedure.

Patients suffering from dentofacial deformities not associated with any syndromes necessitating BSSO with or without maxillary osteotomy, were included in the study, with age between 20-40 years, no sex predilection, and good oral hygiene. Smokers, and alcohol or drug abuse patients were excluded.

Materials

Standard 2.0mm mini plates, mono-cortical screws measuring 2.0mm in diameter and 5-7mm in length (Stema Medizintechnik GmbH, Stockach, Germany), Orthognathic surgical instruments set, CT (a slice

thickness of 0.5 mm), and CAD-CAM surgical guide: a) Preoperative guide (occlusal splint with holes positioning arm) (Figure 1A), b) Repositioning guide (preplanned occlusal splint with holes repositioning arm) (Figure 1B) were used.

Methods

Preoperative assessment and examinations

Clinical examination

Complete medical and dental histories were taken, followed by extra-oral and intra-oral inspection to confirm the facial asymmetry and malocclusion and via palpation to assess any tenderness, teeth mobility, and condylar stability.

The standard orthognathic evaluation encompassed an extensive preoperative data collection process, which involved clinical photographs, cephalometric analysis, dental models obtained through both traditional stone models and digital laser scanning, and registration of a centric relation (CR) bite in an upright position using an occlusal splint.

Patients undergo all the necessary laboratory investigations to obtain clearance for operation from the anesthesia specialist. They were instructed to fast at least 8 hours before the surgery.

Radiographic examination

For diagnosis and treatment planning, computerized tomography (CT) was performed for all patients. 3D CAD/CAM surgical guide fabrication by using a virtual plan: a) Preoperative guide (occlusal splint with holes positioning arm) b) Repositioning guide (occlusal splint with holes repositioning arm) was also done (Figure 2).

Preoperative preparations:

Placement of orthodontic brackets on the teeth with scaling and root planning was done for all patients.

Surgical phase

Preoperative medications

A prophylactic antibiotic was administered orally in Amoxicillin/Clavulanic acid (Augmentin 625 mg, GlaxoSmithKline, UK) three times daily for three days.

Surgical procedure

The surgical procedure was conducted with the patient supine under general anesthesia, utilizing nasotracheal intubation. Before the operation, thorough intraoral and extraoral scrubbing using povidone-iodine was performed. Subsequently, sterile towels were used for draping, ensuring that only the surgical area was exposed. A mucoperiosteal intra-oral vestibular incision at the retromolar region was done. A preoperative guide (occlusal splint with holes positioning arm) was applied to make holes in the posterior ramus segment. The preoperative guide was removed to start (BSSO). A bilateral sagittal split ramus osteotomy (BSSO) procedure was carried out. The planned occlusion was obtained using a

repositioning guide (occlusal splint with the same holes used before and repositioning arm), so a precise ramus position was obtained (Figure 3). Two mini plates and mono-cortical screws addressed the osteotomy sites' restricted bone contact area. The surgical wound was sutured using non-resorbable 3/0 silk suture material. Placement of orthodontic arch wire to the brackets, then activation started two weeks postoperatively. Placement of Inter Maxillary Fixation (IMF). Two days postoperatively, a computed tomography (CT) scan was conducted to assess the condyles' sagittal, vertical, and transverse positions and verify their placement within the glenoid fossae. Once measurements were done, the IMF was released.

Postoperative phase

All patients were instructed to apply ice packs extra-orally, starting immediately postoperatively for 12 hours. Patients were given strict instructions to maintain proper oral hygiene. Patients were instructed to eat a blenderized diet two weeks postoperatively.

Postoperative medications

All patients were given a 5-days course of systemic antibiotics; 1 gm Amoxicillin + clavulanate tablets twice daily for the next seven days. Diclofenac potassium 50 mg tab every eight hours for five days and Chlorhexidine antiseptic mouth wash.

Follow up phase

Clinical follow-up:

Pain, edema, wound healing, and facial symmetry were assessed. Pain was assessed by Visual Analogue Scale (VAS)⁽¹⁶⁾. Edema was evaluated by the Laskin scale⁽¹⁷⁾.

For assessment of wound healing, the intra-oral incision was regularly assessed and monitored for any indications of dehiscence, infection, or inflammation during the postoperative period.

Facial symmetry was examined by clinical patient assessment⁽¹⁸⁾ seven days, 14 days, and six weeks postoperatively.

Radiological follow-up

CT scans were done for all patients to assess the condylar position and facial symmetry immediately postoperatively and three months postoperatively (Figure 4).

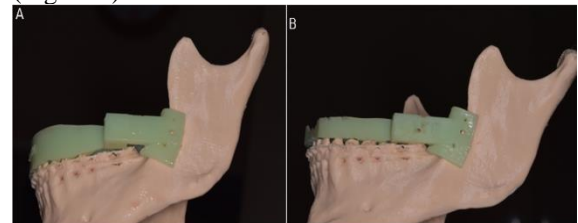


Figure 1(A) : Preoperative guide (occlusal splint with holes positioning arm), **(B)** Repositioning guide (preplanned occlusal splint with holes repositioning arm).

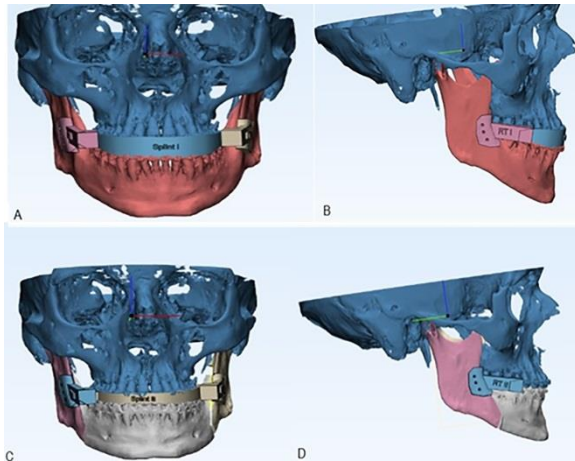


Figure 2:(A): Preoperative guide (occlusal splint with holes positioning arm frontal view), (B) Preoperative guide lateral view, (C) Repositioning guide (occlusal splint with holes repositioning arm frontal view), (D) Repositioning guide lateral view.

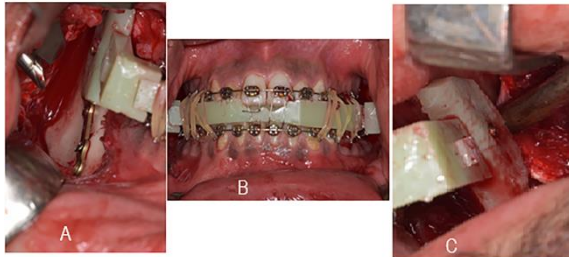


Figure 3:(A) Right arm, (B) Frontal view of occlusal splint, (C) Left arm of the guide Intraoperative view with positioning segments and fixation of the proximal segment with monocortical screws.

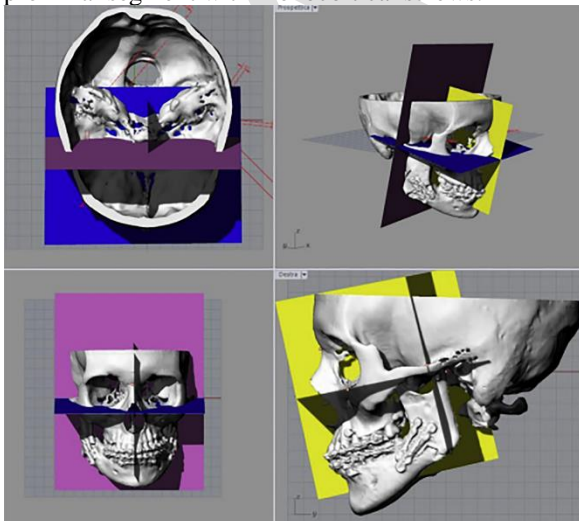


Figure 4: Computer-aided identification of the three planes of the skull for preoperative and postoperative condylar positioning measurements.

RESULTS

Patients age ranged from 19.00 to 24.00 years with a median [25th-75th percentile] of 20.00 [19.50-22.00], 95% Confidence Interval of the median (CI) was 20.00-24.00. Males represented 5/8 (62.50% while females were 3/8 (37.50%).

Occlusion Class II was indicated in 2/8 (25.00%) patients, while Class III was in 6/8 (75.00%). The eight surgical procedures were: BSSO set back 4 mm, BSSO asymmetric set back (LS 2 mm) (RS 3 mm), Le Fort I reposition, BSSO advancement 4 mm, genioplasty, Le Fort I reposition, BSSO advancement 3 mm, BSSO set back 5 mm, BSSO set back 6 mm, BSSO asymmetric set back (LS 3 mm) (RS 5 mm), and BSSO set back 3.5 mm.

Preoperatively, the condylar angle ranged from 148.20 to 156.40 with a median [25th-75th percentile] of 152.85 [150.25-154.80], 95% CI of the median was 149.10-155.30. Immediate postoperatively, it ranged from 148.10 to 156.70 with a median [25th-75th percentile] of 153.00 [150.30-155.10], 95% CI of the median was 148.80-155.80. Three months postoperatively, it ranged from 148.50 to 156.50 with a median [25th-75th percentile] of 153.10 [150.30-154.90], 95% CI of the median was 148.90-155.20.

Repeated measures analysis showed no statistically significant change in the condylar angle among the measurement times ($p=.233$).

Absolute change between immediate postoperative and preoperative Condylar Angle ranged from -0.30 to 0.50 with a median [25th-75th percentile] of 0.15 [0.00-0.35], 95% CI of the median was -0.10-0.40. Absolute change between three months postoperative and preoperative condylar angle ranged from -0.20 to 0.40 with a median [25th-75th percentile] of 0.20 [0.00-0.30], 95% CI of the median was -0.10-0.30. (Table 1).

Immediate preoperatively, the accuracy ranged from 89.20 to 94.30% with a median [25th-75th percentile] of 92.15 [90.25-93.75], 95% CI of the median was 90.00-94.30%. Three months postoperatively, it ranged from 91.40 to 96.30% with a median [25th-75th percentile] of 94.60 [92.35-95.75], 95% CI of the median was 92.00-96.10%.

Repeated measures analysis showed a statistically significant increase in the accuracy between immediately postoperative and after three months ($p=.012$).

Percentage change between immediate postoperative and three months postoperative accuracy ranged from 1.40 to 4.26% with a median [25th-75th percentile] of 2.17 [1.97-2.45], 95% CI of the median was 1.91-2.47 (Table 2).

Table (1): The Condylar Angle at different times of measurements in the studied group

Condylar angle (°)	
Preoperative	
- n	8
- Min-Max	148.20-156.40
- Median	152.85
- 95.0% CI of the median	149.10-155.30
- 25 th Percentile – 75 th Percentile	150.25-154.80
Immediate postoperative	
- n	8
- Min-Max	148.10-156.70
- Median	153.00
- 95.0% CI of the median	148.80-155.80
- 25 th Percentile – 75 th Percentile	150.30-155.10
Three months postoperative	
- n	8
- Min-Max	148.50-156.50
- Median	153.10
- 95.0% CI of the median	148.90-155.20
- 25 th Percentile – 75 th Percentile	150.30-154.90
Friedman Test of significance	$\chi^2_{(df=2)}=3.00$
p-value	$p=.223$ NS
Absolute change between immediate postop. and preop.	
- n	8
- Min-Max	-0.30 - 0.50
- Median	0.15
- 95.0% CI of the median	-0.10 - 0.40
- 25 th Percentile – 75 th Percentile	0.00 - 0.35
Absolute change between three months postop and preop.	
- n	8
- Min-Max	-0.20-0.40
- Median	0.20
- 95.0% CI of the median	-0.10 - 0.30
- 25 th Percentile – 75 th Percentile	0.00 – 0.30

n: number of patients
 Min-Max: Minimum to Maximum
 CI: Confidence interval
 df: degree of freedom
 χ^2 = Chi-Square of Friedman test
 NS: Statistically not significant ($p \geq .05$)

Table (2): The Accuracy (%) at different times of measurements in the studied group

Accuracy (%)	
Immediate postoperative	
- n	8
- Min-Max	89.20-94.30
- Median	92.15
- 95.0% CI of the median	90.00-94.30
- 25 th Percentile – 75 th Percentile	90.25-93.75
Three months postoperative	
- n	8
- Min-Max	91.40-96.30
- Median	94.60
- 95.0% CI of the median	92.00-96.10
- 25 th Percentile – 75 th Percentile	92.35-95.75
Test of significance	$Z_{(WSR)}=2.527$
p-value	$p=.012^*$
Percentage change (%)	
- n	8
- Min-Max	1.40-4.26
- Median	2.17
- 95.0% CI of the median	1.91-2.47

- 25 th Percentile – 75 th Percentile	1.97-2.45
---	-----------

n: number of patients
 Min-Max: Minimum to Maximum
 CI: Confidence interval
 WSR: Wilcoxon Signed Ranks Test
 *: Statistically significant ($p < .05$)

DISCUSSION

Attaining the ideal position of the condyle is of utmost importance to ensure the proper functioning of the condyle, as well as to establish stable occlusion and promote optimal temporomandibular joint (TMJ) function. A wide range of techniques has been suggested to achieve centric relation during surgery. Savoldelli et al. 2018⁽¹⁸⁾ introduced a guide that was temporarily fixed on each device arm using screws to prevent any movement during the guided osteotomy. Afterward, the guide was removed, allowing for the completion of the splitting procedure using conventional methods. Polley and Figueroa in 2013⁽¹⁹⁾, utilized a system comprising removable guides interconnected with an occlusal splint. They employed an initial guide to gain stable reference point. Following skeletal segment mobilization, a final guide, aligned with the drilled landmarks, was utilized to position the skeletal segments.

The current approach employed occlusal-borne and bone-borne guides to achieving proper position of the condyle. Moreover, an occlusal splint with positioning and repositioning arms was utilized to position the arches accurately. Preoperative guide with positioning arm rested on the lateral surface of ramus and occlusal splint translate the occlusal relation of upper and lower arches of the patient to the operating room before bone osteotomy to record the relationship between occlusion. The ramus's bone surface, which detects the condylar head's position inside the glenoid fossae by landmark screw, was done on the ramus. Subsequently, the repositioning guide, accompanied by a preplanned occlusal splint (the final occlusal splint), was utilized to transfer the virtual surgical plan to the operating room. This approach provided meticulous control over the positioning of the proximal bone segments during fixation, effectively preventing condylar sag or rotations. The guide is designed to be simplified, with precise fit. By placing the device in contact with the lateral borders of the ramus's and the dental arches' occlusal surface, the operator can precisely position the mandibular segment with the condyles in centric relation.

On the other hand, the repositioning surgical guide acts as a final occlusal splint to achieve the preplanned occlusion and new relation between dental arches after orthognathic osteotomy. Its repositioning arms can help stabilize proximal bone during fixation

without bone or condylar rotation. A mono-cortical screw passes through the guide to make a landmark screw in the ramus bone laterally, then removed. Second, once the repositioning guide with its final occlusal splint is applied, it stabilizes the ramus segment and ensures proper fixation. For obtaining the relationship between the arches, various methods employed, such as traditional splints, wax bite registrations, or centric occlusion, particularly in cases of single-jaw surgery where preoperative orthodontic treatment has achieved stable Class I occlusion.

Consequently, all mandibular fragments following BSSO were accurately positioned, with both condyles in centric relation. This achievement was accomplished by implementing a CAD-CAM. There is a scarcity of data on condylar positioning devices (CPDs) compared to traditional methods, and the existing data are conflicting and inconclusive^(15,20). Costa et al. (2008)⁽¹⁵⁾, reported that a limited number of publications were identified. Only six studies were found about condylar position devices (CPDs). Out of these, three studies supported the use of CPDs; one study supported their use specifically in patients with temporomandibular disorders.

In contrast, the remaining studies did not endorse CPDs due to the lack of evidence in improving skeletal stability or temporomandibular joint (TMJ) function, regardless of the type of skeletal deformities being treated. The Ling-Chun Wang et al. study 2020 did not utilize any positioning device other than the 3D surgical navigation plates, which were custom-made based on the Computer-Aided Three-Dimensional Simulation and Navigation in Orthognathic Surgery (CASNOS) protocol. The CASNOS protocol provided orthodontists and surgeons with a precise approach to treating orthognathic patients, mainly when translating the simulation into the actual surgery using navigation procedures⁽²¹⁾. Our results demonstrated that the position of the condyle, assessed by distances between specific points, exhibited significant similarity. These findings suggest that the condyles were appropriately positioned and centered within their glenoid fossae. Using CAD/CAM guides to achieve centric occlusion and condylar CR confirms the feasibility of obtaining precise and consistent outcomes.

CONCLUSION

3D condylar positioning devices (CPDs), designed and manufactured by CAD/CAM technology in a mandibular bilateral sagittal split osteotomy, assess the stability of condylar position and postoperative occlusion.

REFERENCES:

1. Paletta F, Johnson D, Guevara C, Zhu TR. Complications of Orthognathic Surgery – Prevention of Complications of Orthognathic Surgery. In: Ferneini EM, Castiglione CL, Banki M, editors. *Complications in Maxillofacial Cosmetic Surgery: Strategies for Prevention and Management*. 1st ed. Switzerland: Springer International Publishing; 2017. p. 159-81.
2. Murphy C, Kearns G, Sleeman D, Cronin M, Allen P. The Clinical Relevance of Orthognathic Surgery on Quality of Life. *Int J Oral Maxillofac Surg* 2011;40:926-30.
3. Khechoyan DY. Orthognathic Surgery: General Considerations. *Semin Plast Surg* 2013;27:133-36.
4. Göelzer J, Becker O, Junior OH, Scolari N, Melo MS, Heitz C, et al. Assessing Change in Quality of Life Using the Oral Health Impact Profile (Ohip) in Patients with Different Dentofacial Deformities Undergoing Orthognathic Surgery: A before and after Comparison. *Int J Oral Maxillofac Surg* 2014;43:1352-9.
5. Lee C, Yang B, Kim J, Oh S, Park K. Centric-Relation Bite as a Condylar Positioning Device in Bimaxillary Surgery. *J Oral Maxillofac Surg* 2013;71:e65-e6.
6. Mousoulea S, Kloukos D, Sampaziotis D, Vogiatzi T, Eliades T. Condylar Resorption in Orthognathic Patients after Mandibular Bilateral Sagittal Split Osteotomy: A Systematic Review. *Eur J Orthod* 2017;39:294-309.
7. Oh S-M, Lee C-Y, Kim J-W, Jang C-S, Kim J-Y, Yang B-E. Condylar Repositioning in Bilateral Sagittal Split Ramus Osteotomy with Centric Relation Bite. *J Craniofac Surg* 2013;24:1535-8.
8. Jäger A, Kubein-Meesenburg D, Luhr H. Longitudinal Study of Combined Orthodontic and Surgical Treatment of Class II Malocclusion with Deep Overbite. *Int J Adult Orthod Orthognath Surg* 1991;6:29-38.
9. Gerressen M, Stockbrink G, Smeets R, Riediger D, Ghassemi A. Skeletal Stability Following Bilateral Sagittal Split Osteotomy (BSSO) with and without Condylar Positioning Device. *J Oral Maxillofac Surg* 2007;65:1297-302.
10. Rotskoff KS, Herbosa EG, Villa P. Maintenance of Condyle-Proximal Segment Position in Orthognathic Surgery. *J Oral Maxillofac Surg* 1991;49:2-7.
11. Leonard M. Preventing Rotation of the Proximal Fragment in the Sagittal Split Operation. *J Oral Surg* 1976;34:942-7.

12. Choi B-J, Kim B-S, Lim J-M, Jung J, Lee J-W, Ohe J-Y. Positional Change in Mandibular Condyle in Facial Asymmetric Patients after Orthognathic Surgery: Cone-Beam Computed Tomography Study. *Maxillofac Plast Reconstr Surg* 2018;40:1-8.
13. Ellis III E. Condylar Positioning Devices for Orthognathic Surgery: Are They Necessary? *J Oral Maxillofac Surg* 1994;52:536-52.
14. Ritto F, Schmitt A, Pimentel T, Canellas J, Medeiros P. Comparison of the Accuracy of Maxillary Position between Conventional Model Surgery and Virtual Surgical Planning. *Int J Oral Maxillofac Surg* 2018;47:160-6.
15. Costa F, Robiony M, Toro C, Sembronio S, Polini F, Politi M. Condylar Positioning Devices for Orthognathic Surgery: A Literature Review. *Oral Surgery, Oral Medicine, Oral Pathology, Oral Radiology, and Endodontology* 2008;106:179-90.
16. Seymour RA, Simpson JM, Charlton JE, Phillips ME. An Evaluation of Length and End-Phrase of Visual Analogue Scales in Dental Pain. *Pain* 1985;21:177-85.
17. Laskin DM. *Cirurgia Bucal Y Maxilofacial: Médica Panamericana*; 1987.
18. Savoldelli C, Vandersteen C, Dasonville O, Santini J. Dental Occlusal-Surface-Supported Titanium Guide to Assist Cutting and Drilling in Mandibular Bilateral Sagittal Split Osteotomy. *J Stomatol Oral Maxillofac Surg* 2018;119:75-8.
19. Polley JW, Figueroa AA. Orthognathic Positioning System: Intraoperative System to Transfer Virtual Surgical Plan to Operating Field During Orthognathic Surgery. *J Oral Maxillofac Surg* 2013;71:911-20.
20. Cortese A, D'Alessio G, Brongo S, Amato M, Sarno MR, Claudio PP. New Techniques in Relation to New Concepts of the Aesthetic of the Face: Technical Considerations and Aesthetic Evaluation. *J Craniofac Surg* 2016;27:e693-e5.
21. Chang Y-J, Lai J-P, Tsai C-Y, Wu T-J, Lin S-S. Accuracy Assessment of Computer-Aided Three-Dimensional Simulation and Navigation in Orthognathic Surgery (Casnos). *Journal of the Formosan Medical Association* 2020;119:701-11.