

HORIZONTAL ALVEOLAR RIDGE EXPANSION IN POSTERIOR ATROPHIC MANDIBLE USING OSSEODENSIFICATION TECHNIQUE (A CLINICAL TRIAL)

Mohammad M. Mohammad^{1*} BDS, Saeeda M. Osman² PhD, Dina M. Nader² PhD

ABSTRACT

BACKGROUND: Narrow ridges can cause difficulties in restoring function by dental implants; many techniques can be used to overcome this problem such as bone grafting and ridge expansion techniques, with ridge expansion being the better, more reliable option. A recent technique that can achieve ridge expansion is osseodensification. Osseodensification using Densah burs is a technique that condenses bone using specially designed burs rotating in an anticlockwise direction, which will help in increasing the ridge width as well as insertion torque of the implant

AIM OF THIS STUDY: Clinical and Radiographic evaluation of ridge expansion in posterior atrophic mandible using osseodensification with simultaneous implant placement.

MATERIALS AND METHODS: 12 patients with narrow posterior mandibular ridge with width ≤ 6 mm received implants using osseodensification technique. The amount of ridge expansion, primary and secondary stability at 4 months and marginal bone loss were evaluated at 4 and 8 months.

RESULTS: 4 months post-operative bone width was increased by 43.61% and after 8 months bone width was increased by 39.29% in the cervical region and increased by 11.48% at 4 months and 9.89% at 8 months in the middle region and increased by 12.64% at 4 months and 10.57% at 8 months in the apical region. There was also a significant increase in bone density around the implants ($p \leq 0.05$)

CONCLUSION: Based on the results of this study we concluded that osseodensification is a safe and effective way for expanding narrow posterior alveolar ridges, while increasing bone density around the implant which positively affects the primary and secondary stability; without complications such as dehiscences and fractures of the buccal plate of bone.

KEY WORDS: Osseodensification, densah burs, ridge expansion, implant stability, osseointegration.

RUNNING TITLE: Expansion of posterior atrophic mandible with osseodensification technique

1 B.D.S Faculty of Dentistry PharosUniversity

2 Professor of Oral and Maxillofacial Surgery Department, Faculty of Dentistry, Alexandria University, Alexandria, Egypt

3 Lecturer of Oral and Maxillofacial Surgery Department, Faculty of Dentistry, Alexandria University, Alexandria, Egypt

* **Corresponding Author:**

E-mail: mohammd.montasser@gmail.com

INTRODUCTION

A frequently encountered issue in implant dentistry is the presence of an atrophic mandibular ridge, especially ridges with width below 6 mm since this will leave less than 1.5 mm of bone buccal and lingual to the narrowest implant which will compromise the blood supply and will leave a higher chance of implant fenestration (1).

For some ridges implant treatment may be hindered by having some conditions that such as; lower than optimum ridge width, which might be due to periodontal conditions, trauma or tooth loss (2).

The need for ridge augmentation surgeries is decreased when using narrow diameter dental implants between 3 mm and 3.5 mm, It is important to maintain a sufficient amount of Imm (implant) bone thickness around the implant, but in situations where the bone width is very narrow, it may still be necessary to perform augmentation surgeries (2).

Albrektsson et al. (1981) identified several factors that are associated with the success of implants,

including (1) implant-related factors such as design, surface topography, composition, shape, biocompatibility and dimensions, (2) host-related factors such as bone quality, density, and volume, (3) surgical factors such as achieving primary stability, preventing infection, and avoiding mechanical and thermal damage, (4) biomechanical factors such as loading conditions, and (5) systemic factors such as parafunctional habits, systemic diseases and medications that affect bone healing.(3)

With primary stability being the most essential factor for attaining success (4).

The friction between implant surface and walls of osteotomy at the time of surgery, without implant movement is called primary implant stability, while the process of bone remodeling and osseointegration which is the direct structural and functional contact between bone and implant surface is called biological or secondary stability(5).

Many techniques, such as, Guided Bone Regeneration (GBR), using allografts, xenografts, bone block grafting from intra oral sites such as external oblique ridge and chin has been used to treat cases with narrow ridge width (6-8).

Osseodensification, which is a new way of biomechanical bone preparation to place dental implants, which means that the bone has a limited ability to change its shape or form under pressure or stress. using densifying burs that is fluted such that it densify the bone with minimal heat formation. It is a non-bone cutting technique which was developed by Huwais in 2013 using specially designed burs (Densah™ Burs) that help in densifying bone during the osteotomy preparation, which will in turn helps in ridge expansion (9).

These Burs condenses and preserves bone by compaction autografting during the preparation of the osteotomy, which then increases the density of bone in the peri-implant area and thereby increases mechanical stability of dental implant, also this bone compaction increases the ridge width (9).

To significantly decrease the implant placement procedures time, horizontal ridge expansion is done simultaneously with implant placement (8).

The main purpose of the study was to evaluate the ability of the osseodesification technique to expand mandibular posterior atrophic ridges and simultaneously place dental implants.

PATIENTS AND METHODS

Study Design

This was a clinical trial that was carried out after getting the research ethics committee approval (17/10/2021- 0306-10/2021), Faculty of Dentistry - Alexandria University. Participants were given a complete description of the nature of the study then they signed an 'informed consent' saying that they were ready to participate in this study with the commitment to attending follow up visits.

The minimum sample size has been determined using data from a previous study that was conducted to assess the extent of ridge expansion following osseodensification. Koutouzis T. et al. (2019) (10) concluded that the dimensions of the mandibular alveolar ridge can be altered using osseodensification which expands the ridge, with the ridge crest being the area of highly anticipated expansion due to the presence of sufficient trabecular bone. Based on the results of the later study. Adopting a power of 90% to detect a standardized effect size in amount of ridge expansion of 1.215 and a 95% ($\alpha=0.05$) significance level, the minimum required sample size for single-arm (non-randomized) trial was found to be 12 patients (11). Any withdrawal was amended by substitution to control the withdrawal bias (12). A GPower version 3.1.9.2 was used to calculate the sample size (13).

Participant of this study were chosen from the out-patient clinics of the Oral and Maxillofacial Surgery Department, Faculty of dentistry, Alexandria University.

Inclusion Criteria Patients having narrow edentulous posterior mandibular ridge with width \leq

6mm (13); The patients included in the study were between the ages of 24 and 50 years old. Patients with a good oral hygiene (14-16).

Exclusion Criteria Patients having systemic condition that directly influence the remodeling of bone such as Osteoporosis, Medically Related Osteonecrosis of the Jaw (MRONJ), Rheumatoid arthritis, uncontrolled Diabetes mellitus and Ectodermal Dysplasia (17).; Heavy smokers (18); Ongoing chemotherapy or radiotherapy; Parafunctional habits; Surgical site with acute infection; Patients with mental retardation; Pregnant Patients; Alcohol or drug abuse

Preoperative Phase Personal history was obtained by getting the full personal data of the participants in details including their names, age, gender, occupation, address and phone number; Previous dental and medical history.

Intraoral examination

Inspection was carried out to detect bone integrity and any abnormality. Palpation was made to assess cortical bone, tenderness

Radiographic examination

Preoperative Cone beam CT scanning was done for the selected patients before the surgery to evaluate the dimensions of the ridge and location of the implant, relation to vital structure and determine the dimensions of the implant in terms of its length and width. **Figure 1**

Pre-operative Medication: Augmentin 1gm (Augmentin, Galaxosmithkline- Australia) tablet twice per day was given before the surgery by one day

Operating phase

All the surgeries were conducted after the administration of local anesthesia on the dental chair. Inferior Alveolar nerve block with Long Buccal nerve infiltration anesthesia using 4% Articaine with 1:100,000 epinephrine was administered; Using a Bard-Parker scalpel no.15, a full thickness mucoperiosteal flap was made on the the mid crest **Figure 2**; First osteotomy was made using conventional drill rotating in clockwise direction in cutting motion. **Figure 2**; Implant osteotomy was then expanded using the osseodensification drilling protocol (densah burs) **Figure 3**; In osseodensification technique for ridge expansion the pilot drill was used with rotating speed from 800 - 1200 rpm in a cutting clockwise direction until we reach the suitable length, then the sequential drilling is done using densah burs in an anticlockwise direction under copious sterile saline irrigation with speed of 800 – 1800 rpm in an up and down motion till reaching the desired length. **Figure 4**; After implant insertion the primary stability was measured using the Osstel monitor to obtain ISQ readings (19). **Figure 5**; Flap was returned to its position and sutured

Post operative Medications: (a) Augmentin 1gram tablet was continued every 12 hours for 5 days. (b) Alphintern (Chymotrypsin and Trypsin) as anti-inflammatory drug, will be given 1hour immediate post operatively and continued every 8 hours for 3 days. (c) Hexitol (Chlorhexidine) warm mouthwash especially after meals started from the second postoperative day and continued to the end of the week.

Post operative Radiographic and Clinical evaluation:

CBCT was conducted after 4 and after 8 months to evaluate the process of osseointegration and to assess the amount of ridge expansion and amount of bone formation. (With exposure parameters from 8-16 mamp and 8-10 kv).

Readings were measured from the outer part of the buccal cortical bone to outer part of the lingual cortical bone to evaluate the amount of ridge expansion made.

These measurements were taken at 3 different points from a sagittal cut of the CBCT of the implants. **Figure 6** First point at cervical level of the implant; Second point at middle third of the implant; Third point at the apical third of the implant

These measurements were then be compared to the baseline measurements taken before implant placement through the preoperative CBCT.

Then Secondary Stability was measured using Osstel at 4 months and marginal bone level was evaluated at 4 and 8 months .

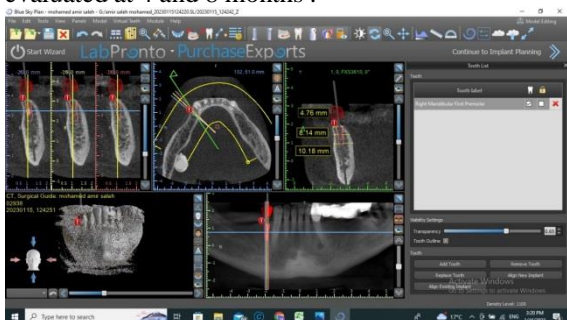

Figure 1: Pre operative CBCT with surgical planning and virtual implant placement with normal drilling protocol.

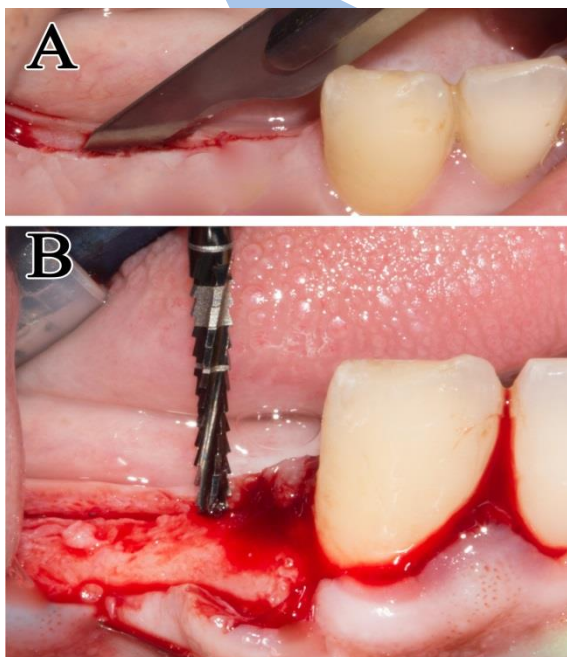


Figure 2: (A) Incision . (B) pilot drill.



Figure 3: Pre operative CBCT with surgical planning and virtual implant placement with normal drilling protocol.

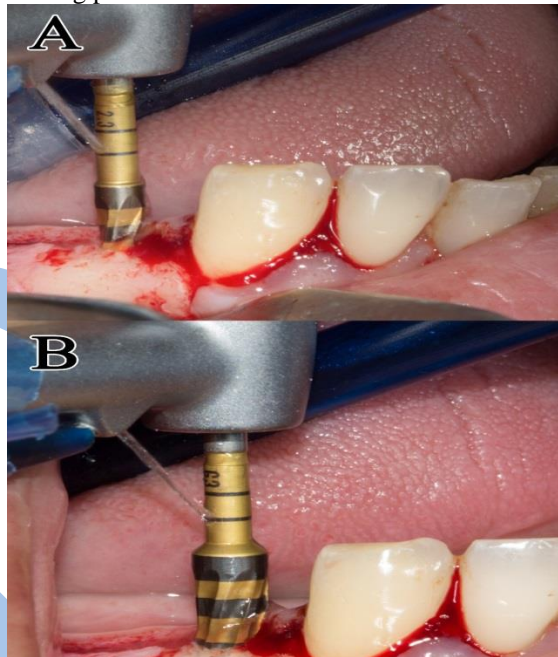


Figure 4: Bone expansion using Desah Drills.

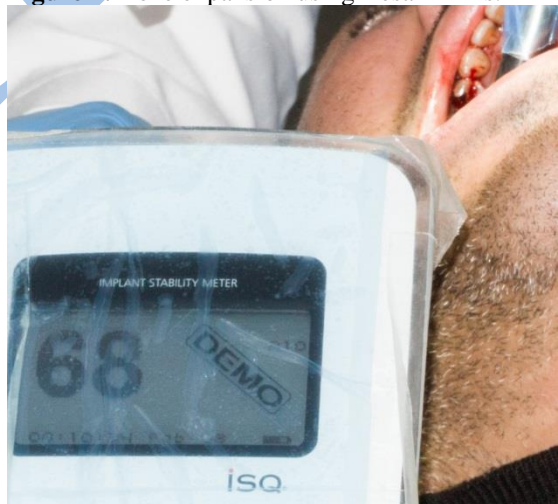

Figure 5: Measuring primary stability using Osstel.

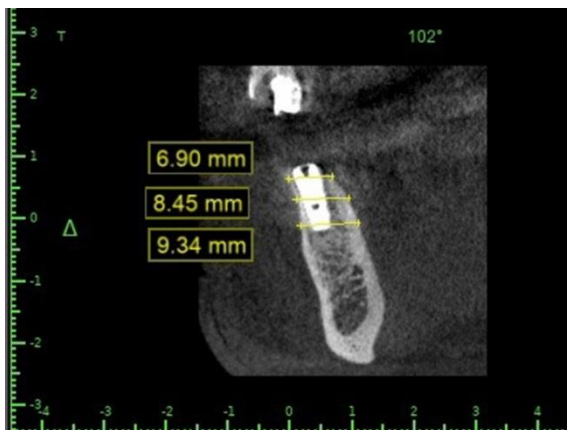


Figure 6: Sagittal View of CBCT post operative.

Statistical Analysis

The computer received data through IBM SPSS software package version 24.0.

Qualitative data were presented as numbers and percentages. To compare categorical variables across different groups, the Chi-square test was employed.

Quantitative data were described using the mean and standard deviation for data that followed a normal distribution.

When comparing two independent populations with normally distributed data, the analysis was conducted.

The significance test results were reported as two-tailed probabilities, and the significance level was set at 5% to determine the significance of the findings.

RESULTS

Radiographic Results

Cervical Third

Compared to the measurements taken preoperatively, a significant increase was seen after 4 months by 43.61% as well as after 8 months by 39.29 %, (P = 0.001). There was no statistically significant difference between cervical bone width after 4 months and cervical bone width after 8 months (P=0.348). **Table 1**

Middle Third

Compared to the measurements taken preoperatively, there was significant increase in bone width after 4 months by 11.48% as well as after 8 months by 9.89% (P = 0.045). There was no statistically significant difference between bone width in the middle third after 4 months and after 8 months (P=0.741). **Table 1**

Apical third

Compared to the measurements taken preoperatively, a significant increase in the bone width was seen after 4 months by 12.64% as well as after 8 months by 10.57% (P = 0.044). There was no statistically significant difference between apical bone width after 4 months and after 8 months (P=0.608).

Table 1
Marginal bone level

When comparing marginal bone level around the implant after 4 months and 8 months, there was no statistically significant difference found. **Table 2**

Clinical Results

Primary and Secondary Stability at 4 months

When comparing primary stability to secondary stability there was no statistically significant difference (P = 0.375). **Table 3**

Table (1): Comparison between width Preoperative and at 4 and 8 months

Width	Preoperative	4 months	8 months
Cervical		6.0-	
Range	4.63-5.88	8.23	5.92-8.2
Mean	5.09	7.31	7.09
SD	0.40	0.66	0.79
Percent change from base line		43.61	39.29
ANOVA test			44.79
P value			0.001*
P1			0.001*
P2			0.001*
P3			0.384 N.S.
Middle 1/3	7.51-	8.14-	
Range	10.18	11.12	7.2-11.09
Mean	8.19	9.13	9.00
SD	0.75	1.00	1.10
Percent change from base line		11.48	9.89
ANOVA test			3.402
P value			0.045*
P1			0.022*
P2			0.046*
P3			0.741 N.S.
Apical	7.91-	9.34-	
Range	11.08	12.46	8.3-12.44
Mean	9.18	10.34	10.15
SD	1.11	1.10	1.26
Percent change from base line		12.64	10.57
ANOVA test			3.439
P value			0.044*
P1			0.020*
P2			0.048*
P3			0.698 N.S.
Average bond width	4.63-	6.00-	
Range	11.08	12.46	5.92-12.44
Mean	7.49	8.93	8.75
SD	1.94	1.56	1.65
Percent change from base line		19.22	16.82
ANOVA test			7.502
P value			0.002*
P1			0.001*
P2			0.001*
P3			0.656 N.S.

ANOVA = One way ANOVA test

P was significant if ≤ 0.05

* Significant difference

N.S. Not Significant difference

P1 comparison between width before and width after 4 months.

P2 comparison between before and width after 8 months.

P3 comparison between width after 4 months and width after 8 months.

Table (2): Comparison between primary stability and secondary stability after 4months.

	Primary stability (osstell reading) ISQ	Secondary Stability after 4 months
Range	56-82	54-75
Mean	67.80	66.88
SD	8.31	5.44
t-test	0.966	
P value	0.375 N.S.	

T= student t-test

P was significant if < 0.05

* Significant at level 0.05

Table (3): Changes in marginal bone level after 4 months when compared to marginal bone level after 8 months.

	after 4 months	after 8 months	U-test	P value
Buccal				
Range	0-0.5	0-0.71	4.25	0.103 N.S.
Mean	0.17	0.34		
SD	0.21	0.30		
Median	0.00	0.38		
Lingual				
Range	0-0.77	0-0.83	3.211	0.354 N.S.
Mean	0.28	0.34		
SD	0.29	0.31		
Median	0.28	0.33		
Mesial				
Range	0-0.79	0-0.82	0.113	0.468 N.S.
Mean	0.30	0.43		
SD	0.38	0.36		
Median	0.00	0.50		
Distal				
Range	0-0.76	0-0.77	0.288	0.681 N.S.
Mean	0.38	0.41		
SD	0.34	0.33		
Median	0.57	0.60		
Average Marginal bone level				
Range	0.0-0.79	0.0-0.83	6.002	0.06 N.S.
Mean	0.28	0.381		
SD	0.31	0.32		
Median	0.125	0.375		

U= Mann Whitney test

P was significant if < 0.05

N.S. Not Significant at level 0.05

DISCUSSION

Narrow posterior alveolar ridges pose a challenge in restoration of dentition using dental Implants, several techniques are used for restoration of width such as GBR, ridge expansion techniques such as ridge splitting and distraction osteogenesis (20).

The technique of osseodensification aims to prepare the implant site through multi-stepped preparing concept with specially designed burs rotating in

anticlockwise direction which in turn lateralizes autogenous bone into the neighboring spongy bone, and therefore expands the bone with minimal heat elevation and controlled bone deformity (21).

This technique of compaction autografting increase bone density and improves bone with poor quality which uses elastic bone properties to facilitate bone bulk preservation (22).

The aim of this technique is to autograft bone at the apex and periphery of the implant by condensing the bone. This will increase the implant and bone contact area which in turn increases the density of bone around the implant which then increases the insertion torque of the implant and implant primary stability (23).

The purpose of this study was to evaluate the effectiveness of using the Osseodensification technique, specifically the Densah bur, to expand the atrophic ridge in the posterior mandibular region. Additionally, the study aimed to assess the stability of the implant both immediately after placement and over time, and to determine the density of the bone that surrounds the implant.

According to Koutouzis et al., (24) cases that were selected for ridge augmentation varied in width from 3 -6 mm. Therefore, the target width in the cases of our study was selected to be ≤ 6 mm. That is because we need a at least 1.5 mm of bone buccal and lingual to the implant to ensure an adequate blood supply (25).

Nasseri et al., (26) stated that patient having dental implants that are heavy smokers tend to have bone loss around the implants which causes implant failure, that's why subjects of this study were selected to be non-smokers. In addition Chitumalla et al., (27) stated that patients with Para functional habits such as bruxism, who received dental implants, experienced complications such as fracture of implants, ceramic fracture, screw loosening, screw fracture and decementation of prosthesis (28).

CBCT is a Mandatory tool in the full process of dental implantology, Starting from pre-surgical planning and detection of vital anatomical structure and virtually placing implants to check there proximity to these structure as well as asses bone levels all around the implant before even placing them (29), to ensure the success of our procedure and the proper placement of the implant and check marginal bone loss around the implant as described by Greenberg et al., (30) All of these features makes the CBCT a greater option in radiographic assessment of the cases rather than computerized tomography (CT) or panoramic x-ray (31, 32), in the present trial CBCT was conducted to the participant on 3 different occasions, Preoperatively, after 4 months to evaluate amount of bone expansion and bone density and after 8 months to evaluate marginal bone loss after insertion of the

final prosthesis and bone expansion when compared to the previous CBCT.

Concerning the surgical protocol conducted in this study, procedures were performed under local anesthesia, and as Kim et al., (33) described, all cases in this study had a mid crestal horizontal incision to allow access to the crest of the ridge for placement of implant which is believed to offer better remodeling of the bone post operatively and increase the ability of having a good secondary implant stability and thus be able to early load the prosthesis on the implant, however flap reflection has a great impact on dimensional changes of alveolar ridges which is related to the periosteal rupture which when left in place eventually decreases the rate of bone resorption as stated by Araujo et al., and Blanco et al., (34, 35).

This current study displayed an average increase in bone width by 19.22%, also a remarkable increase in the density of bone around the implants which contributed to primary stability. This goes in line with the results obtained by Jarikian et al conducted a recent study that revealed similar results to this study (36), where a 2.36mm average expansion of bone was seen after placing 14 implants using osseodensification technique.

In the current study, The Resonance Frequency Analysis (RFA) was used for the assessment of the primary stability of the implant through the Osstell ISQ system. This method was the method of choice in evaluating the stability of the implant because of its reliability and noninvasiveness (37).

ISQ values were checked twice. First, immediately post operative to check the primary stability of the implant which showed high ISQ values with a mean of (67.80 ± 8.31) and second after 4 months post-operative to assess the secondary stability which also showed high ISQ values with a mean of (66.88 ± 5.44) which indicated a well osseointegrated implants, the ISQ values of the secondary stability were slightly lower than the ISQ values of the primary stability but the decrease was statistically not significant. Although data are limited on the ISQ values during the healing period, the 12 cases have demonstrated continued stable ISQ values during the first 4 months of healing. This information gave us an idea on the stability of the implant during the healing process were it was stable rather than having been reduced while remodeling occurs. This comes in correlation with the results obtained by Suzuki et al which showed slight decrease in ISQ reading in some of the research subjects (38). The results observed in the study can also be explained by the use of compaction autografting. This technique involves using autogenous compacted bone particles as a foundation for new bone formation. As the bone turnover process takes place, the graft particles can be rapidly replaced, leading to a potentially natural transition from primary to secondary stability (19).

In their study, Trisi P. and colleagues examined how effective the osseodensification (OD) technique is in improving bone ridge density, width, and implant secondary stability (39). They conducted both a biomechanical and histological analysis by placing 20 implants in the iliac crest of two sheep. The test group received implants using the osseodensification technique, while the control group received implants using a conventional drill on the opposite side. The bone width and volume in the test group showed a noticeable increase. In the osseodensification site the most increase in width was seen in the coronal third of the implant osteotomy, which in parallel had thicker trabecular bone due to compaction autografting (39). These results come in parallel with the results of our study where the bone density before drilling had a mean ROI value of (464.0 ± 131.9) when compared to the ROI values of bone around implant after osseodensification with a mean value of (1467.2 ± 151.2) .

Regarding marginal bone loss, it was measured after 4 months having a mean average of 0.28 having no statistically significant difference when comparing the reading of the marginal bone level after 4 months with the readings after 8 months which was 0.381. These results agree with those obtained by Knight et al which also showed no significant difference in marginal bone levels around implants placed by osseodensification technique (40).

Osseodensification maintains the bone volume by condensing the cancellous bone because of the viscoelastic distortion and compacted autografting of bone through the whole length of the implant osteotomy. Also having collagen improves the revascularization of bone after the osteotomy which is preserved due to the non-cutting feature of the osseodensification which in terms helps in formation of new bone and bone remodeling. At 4 months after implant placement in this study, the average bone width increased by 19.22% and at 8 months increased by 16.82% when compared to the baseline measurements before drilling. Even though there was a thin labial bone left in some cases. This did not result in any dehiscence when cases were followed up after 8 months, this may be due to the osteogenic potential of the remaining labial bone.

This trial suggests that utilizing the osseodensification technique for preparing implant osteotomies has a beneficial impact on increasing the width and density of bone in narrow posterior alveolar ridges. As a result, this technique can be considered a dependable and secure approach to use in such situations.

CONCLUSION

From the study results we can deduce that osseodensification is a safe and effective way for expanding narrow posterior alveolar ridge. while having the advantage of increasing bone density around the implant while positively affecting the

primary and secondary stability of the implant without complications such as dehiscences and fractures of the buccal plate of bone.

CONFLICT OF INTEREST

The authors did not receive any particular funding for this work.

FUNDING

No dedicated funding was obtained for this work.

REFERENCES

- Sohn DS, Lee HJ, Heo JU, Moon JW, Park IS, Romanos GE. Immediate and delayed lateral ridge expansion technique in the atrophic posterior mandibular ridge. *J Oral Maxillofac Surg.* 2010;68:2283-90.
- Klein MO, Schiegnitz E, Al-Nawas B. Systematic review on success of narrow-diameter dental implants. *Int J Oral Maxillofac Implants.* 2014;29 Suppl:43-54.
- Albrektsson T, Zarb G, Worthington P, Eriksson AR. The long-term efficacy of currently used dental implants: a review and proposed criteria of success. *Int J Oral Maxillofac Implants.* 1986;1:11-25.
- Gaikwad AM, Joshi AA, Nadgere JB. Biomechanical and histomorphometric analysis of endosteal implants placed by using the osseodensification technique in animal models: A systematic review and meta-analysis. *J Prosthet Dent.* 2022;127:61-70.
- Sezin M, Croharé L, Ibañez JC. Microscopic Study of Surface Microtopographic Characteristics of Dental Implants. *Open Dent J.* 2016;10:139-47.
- Bottino MC, Thomas V, Schmidt G, Vohra YK, Chu TM, Kowolik MJ, et al. Recent advances in the development of GTR/GBR membranes for periodontal regeneration--a materials perspective. *Dent Mater.* 2012;28:703-21.
- Chavda S, Levin L. Human Studies of Vertical and Horizontal Alveolar Ridge Augmentation Comparing Different Types of Bone Graft Materials: A Systematic Review. *J Oral Implantol.* 2018;44:74-84.
- Sultana A, Makkar S, Saxena D, Wadhawan A, Kusum CK. To compare the stability and crestal bone loss of implants placed using osseodensification and traditional drilling protocol: A clinicoradiographical study. *J Indian Prosthodont Soc.* 2020;20:45-51.
- Bergamo ETP, Zahoui A, Barrera RB, Huwais S, Coelho PG, Karateew ED, et al. Osseodensification effect on implants primary and secondary stability: Multicenter controlled clinical trial. *Clin Implant Dent Relat Res.* 2021;23:317-28.
- Koutouzis T, Huwais S, Hasan F, Trahan W, Waldrop T, Neiva R. Alveolar Ridge Expansion by Osseodensification-Mediated Plastic Deformation and Compaction Autografting: A Multicenter Retrospective Study. *Implant Dent.* 2019;28:349-55.
- Charan J, Biswas T. How to calculate sample size for different study designs in medical research? *Indian J Psychol Med.* 2013;35:121-6.
- Pannucci CJ, Wilkins EG. Identifying and avoiding bias in research. *Plast Reconstr Surg.* 2010;126:619-25.
- Faul F, Erdfelder E, Lang AG, Buchner A. G*Power 3: a flexible statistical power analysis program for the social, behavioral, and biomedical sciences. *Behav Res Methods.* 2007;39:175-91.
- Cortellini S, Favril C, De Nutte M, Teughels W, Quirynen M. Patient compliance as a risk factor for the outcome of implant treatment. *Periodontol 2000.* 2019;81:209-25.
- Maló P, de Araújo Nobre M, Gonçalves Y, Lopes A. Long-Term Outcome of Implant Rehabilitations in Patients with Systemic Disorders and Smoking Habits: A Retrospective Clinical Study. *Clin Implant Dent Relat Res.* 2016;18:649-65.
- Donos N, Calciolari E. Dental implants in patients affected by systemic diseases. *Br Dent J.* 2014;217:425-30.
- Kasat V, Ladda R. Smoking and dental implants. *J Int Soc Prev Community Dent.* 2012;2:38-41.
- Herrero-Climent M, Santos-García R, Jaramillo-Santos R, Romero-Ruiz MM, Fernández-Palacin A, Lázaro-Calvo P, et al. Assessment of Osstell ISQ's reliability for implant stability measurement: a cross-sectional clinical study. *Med Oral Patol Oral Cir Bucal.* 2013;18:e877-82.
- Lahens B, Neiva R, Tovar N, Alifrag AM, Jimbo R, Bonfante EA, et al. Biomechanical and histologic basis of osseodensification drilling for endosteal implant placement in low density bone. An experimental study in sheep. *J Mech Behav Biomed Mater.* 2016;63:56-65.
- Tolstunov L, Hamrick JFE, Broumand V, Shilo D, Rachmiel A. Bone Augmentation Techniques for Horizontal and Vertical Alveolar Ridge Deficiency in Oral Implantology. *Oral Maxillofac Surg Clin North Am.* 2019;31:163-91.
- Wu D, Isaksson P, Ferguson SJ, Persson C. Young's modulus of trabecular bone at the tissue level: A review. *Acta Biomater.* 2018;78:1-12.
- Schmitz E, Zanettini C, Zanettini L. Horizontal alveolar ridge expansion in anterior atrophic maxilla using rotatory instruments (bone expander®): a case report. *J Dent Health Oral Disord Ther.* 2019;10:317-22.
- Neiva R, Tanello B, Duarte W, Coelho P, Witek L, Silva F. Effects of osseodensification on Astra TX and EV implant systems. *Clin Oral Implants Res.* 2018;29:444-.
- Lipton D, Trahan W, Hasan F, Neiva R, Waldrop T, Koutouzis T, et al. Osseodensification as a novel implant

- preparation technique that facilitates ridge expansion by compaction autografting. *Am Acad Periodontol Sci Annu Meet.* 2015.
25. Larjava H. *Oral wound healing: Cell biology and clinical management.* Singapore: Wiley-Blackwell; 2012. pp 287-312.
 26. Naseri R, Yaghini J, Feizi A. Levels of smoking and dental implants failure: A systematic review and meta-analysis. *J Clin Periodontol.* 2020;47:518-28.
 27. Chitumalla R, Halini Kumari KV, Mohapatra A, Parihar AS, Anand KS, Katragadda P. Assessment of Survival Rate of Dental Implants in Patients with Bruxism: A 5-year Retrospective Study. *Contemp Clin Dent.* 2018;9:S278-s82.
 28. Clementini M, Rossetti PH, Penarrocha D, Micarelli C, Bonachela WC, Canullo L. Systemic risk factors for peri-implant bone loss: a systematic review and meta-analysis. *Int J Oral Maxillofac Surg.* 2014;43:323-34.
 29. Fokas G, Vaughn VM, Scarfe WC, Bornstein MM. Accuracy of linear measurements on CBCT images related to presurgical implant treatment planning: A systematic review. *Clin Oral Implants Res.* 2018;29 Suppl 16:393-415.
 30. Greenberg AM. Advanced dental implant placement techniques. *J Istanbul Univ Fac Dent.* 2017;51:S76-s89.
 31. Deeb G, Antonos L, Tack S, Carrico C, Laskin D, Deeb JG. Is Cone-Beam Computed Tomography Always Necessary for Dental Implant Placement? *J Oral Maxillofac Surg.* 2017;75:285-9.
 32. Tyndall DA, Price JB, Tetradis S, Ganz SD, Hildebolt C, Scarfe WC. Position statement of the American Academy of Oral and Maxillofacial Radiology on selection criteria for the use of radiology in dental implantology with emphasis on cone beam computed tomography. *Oral Surg Oral Med Oral Pathol Oral Radiol.* 2012;113:817-26.
 33. Kim JR, Kim SH, Kim IR, Park BS, Kim YD. Low-level laser therapy affects osseointegration in titanium implants: resonance frequency, removal torque, and histomorphometric analysis in rabbits. *J Korean Assoc Oral Maxillofac Surg.* 2016;42:2-8.
 34. Araújo MG, Lindhe J. Ridge alterations following tooth extraction with and without flap elevation: an experimental study in the dog. *Clin Oral Implants Res.* 2009;20:545-9.
 35. Blanco J, Nuñez V, Aracil L, Muñoz F, Ramos I. Ridge alterations following immediate implant placement in the dog: flap versus flapless surgery. *J Clin Periodontol.* 2008;35:640-8.
 36. Jarikian S, Jaafar MH, Al-Nerabieah Z. Clinical evaluation of two techniques for narrow alveolar ridge expansion: clinical study. *Int J Dentistry Oral Sci.* 2021;8:1047-52.
 37. Al-Jetaily S, Al-Dosari AA. Assessment of Osstell™ and Periotest® systems in measuring dental implant stability (in vitro study). *Saudi Dent J.* 2011;23:17-21.
 38. Suzuki S, Kobayashi H, Ogawa T. Implant stability change and osseointegration speed of immediately loaded photofunctionalized implants. *Implant Dent.* 2013;22:481-90.
 39. Trisi P, Berardini M, Falco A, Podaliri Vulpiani M. New Osseodensification Implant Site Preparation Method to Increase Bone Density in Low-Density Bone: In Vivo Evaluation in Sheep. *Implant Dent.* 2016;25:24-31.
 40. Knight WM. Comparison of Marginal Bone Loss in Conventional Versus Osseodensification Implant Site Preparation: A Retrospective Study 2021.