

TITANIUM MESH COATED WITH NATURAL HYDROXYAPATITE NANOCRYSTALS IN ORBITAL RECONSTRUCTION (RANDOMIZED CONTROLLED CLINICAL TRIAL)

Asmaa M. Ali^{1*} *M.Sc*, Riham M. El-Dibany² *PhD*, Mohamed M. Shoukry² *PhD*,
Yasser M. Helmy³ *PhD*

ABSTRACT

BACKGROUND: One of the most frequent facial fractures is an orbital fracture, and multiple wall restoration is frequently required following high-energy trauma. Correct planning, thorough surgical dissection, and appropriate selection of the kind, size, and shape of the reconstruction material are all necessary for a successful outcome. The appropriate material to use to restore the orbital floor and walls is still up for debate. For that aim, numerous materials have been described from various sources. The ultimate goals involve treating the bony orbital deficiency while restoring anatomy, volume, function, and esthetics. While each type of material has benefits and drawbacks, the ability to fulfill those.

AIM OF THE STUDY: This study evaluated the difference in the bone density after orbital floor fracture reconstruction with titanium mesh coated with natural nanohydroxyapatite by electrophoretic deposition versus conventional titanium mesh.

PATIENTS & METHODS: This study was carried out clinically on 12 adult patients with fractures of the orbital floor that should be treated with internal fixation and open reduction. The patients were divided into 2 groups, (group A): patients where the reconstruction was done using coated titanium mesh with hydroxyapatite nanocrystals and (group B): the repair and reconstruction of the defect was using conventional titanium mesh.

RESULTS: The radiographic differences in bone density between the study and control groups were statistically significant.

CONCLUSION: The ongoing study displayed better bone density outcomes in reconstructed orbital floor defects with coated titanium mesh when compared to uncoated titanium mesh.

KEYWORDS: Orbital floor, complex fracture, nano-hydroxyapatite, titanium mesh, bone density.

RUNNING TITLE: Evaluation of two different techniques in orbital defect repair.

1 Oral and Maxillofacial Surgery Department, Faculty of Dentistry, Alexandria University, Egypt.

2 Professor of Oral and Maxillofacial Surgery, Faculty of Dentistry, Alexandria University, Alexandria, Egypt.

3 Researcher, Institute of Graduate Studies and Research, Alexandria University, Alexandria, Egypt.

* Corresponding Author:

E-mail: asmaaezzaat@gmail.com

INTRODUCTION

Maxillofacial fractures impact the frontal, zygomatic, palatine, lacrimal, nasal incisive in addition to the maxillary bone (1). Major blunt trauma is a common cause of the majority of maxillofacial fractures, which is frequently caused by car crashes, height falls, or animal fights (2). The maxillofacial frame's exposed anatomic placement makes it vulnerable to traumatic injury, and collisions where fragmented and displaced fractures are possible with high impact forces (3). The frontal sinus and nasal cavity are large air-filled areas that are surrounded by the maxillofacial bones, which are thin and wedged between strong bones like the cranial base and the jaw (3).

In humans, the key therapeutic objectives are restoring facial contour, stabilizing the principal skeletal supports, and achieving proper function and esthetics (4). Michelet et al work, as well as the revisions of Champy et al. (5), widespread usage of stiff steel miniplates for treating human face fractures (6). Mesh osteosynthesis evolved in a similar time frame to plate osteosynthesis, while in the United States in the early 1960s, a rigid steel mesh was in use. (6).

In 1968, a mesh made of titanium was developed, which marked a significant advancement in mesh technology. It was fabricated as a flexible semirigid fixation system to medicate a wide range of

maxillofacial fractures caused in the Vietnamese War. The procedure has since been improved and is now frequently used for a wide variety of maxillofacial surgeries (6,7). As it is biologically compatible, malleable, high in strength, low weight, widely available, minute inflammatory reaction, and imaging artifact, titanium is the perfect material for maxillofacial reconstruction (8,9).

Despite the fact that titanium has been widely employed in clinical contexts, such as dental and orthopedic implants, the nature of titanium alloy is biologically inert and lacks osteoinductivity for bone tissue, a satisfactory bioactivity performance was not always attained upon contact with the bone (8).

The osseointegration process has been optimized in recent years for metallic implants and to avoid bacterial attachment to their surfaces (10). The osseointegration of titanium and related alloys may be improved by the deposition of bioactive coatings with controlled surface topography. It is well known that collagen, water, and nanohydroxyapatite make up the majority of the complex tissue that makes up bone (10). Hydroxyapatite nanocrystals (HA) resembles the natural intracellular matrix of bone due to its biocompatibility, bioactivity, and osteoconductivity, also it is indistinguishable from the mineral phase of human bone tissue. By strengthening connections with the bone mineral phase, it can enhance proteins and bone tissue cells adhesion and is actively interfere in the bone matrix metabolism (10,11).

Because of the poor mechanical properties of HA, it has been utilized as a coating on metallic material's surfaces to combine the substrate's strength and hardness with HA's bioactivity. It's also been proposed that applying HA coatings to metal can improve its corrosion resistance and lessen metallic ion release while also enhancing its bone bonding capacity (12,13).

A hydroxyapatite nano-crystalline bone graft has been presented for intrabony defect augmentation treatments. It has osteoconductivity, bioresorbability, and intimate touch as advantages. It's customary to describe a material containing nanostructures as having a lot of molecules on its surface. When used as a bone graft substitute in both human and animal applications, crucial size deficiencies quickly healed. (12-14). By stimulating osteoblast activity, HA nanocrystals bond to bone and promote bone repair. It's been used to treat periimplantitis and ridge augmentation (15).

A variety of coating techniques, such as plasma spraying, ion beam dynamic mixing, sol-gel, and pulse laser deposition, have been investigated to coat the surface of the metallic substrate with HA nanocrystals. Some of the drawbacks of such processes include uneven coating creation across geometrically complex surfaces, thermal breakdown of HA during the high temperature process, low crystallinity, sluggish process, and poor coating adhesion to substrates. (16). As a

result, there has been an increase in interest in the use of various approaches in recent years, such as the electrophoretic deposition (EPD) procedure (16,17).

The electrophoretic deposition is a quick and low-cost procedure that has several advantages over competing methods. The method's simplicity, great recreatability, constrain the coating thickness, temperature, capacity to form a laminate, and lastly usefulness for therapeutic uses are only a few of the benefits (17). EPD is commonly used in surgery to coat titanium with HA to enhance osseointegration and interactivity between bone and the titanium. Additionally, titanium can be coated with HA to improve biocompatibility and bone remodeling. (18). Despite the fact that numerous researchers have researched the result of EPD of HA on titanium, no studies on its consequence on titanium mesh have been found (18). As a result, the purpose of this work was to estimate the influence and mechanical properties of EPD of HA nanocrystals on titanium mesh.

MATERIALS AND METHODS

The study is a Randomized Controlled Clinical Trial, that will be set-up and reported according to the CONSORT guidelines*.

Eligible patients will be allocated randomly into 2 equal groups with 6 patients in each group according to the titanium mesh that will be used in reconstruction by simple randomization using computer generated random numbers (19). Participants were chosen from Alexandria University Teaching Hospital's Emergency Ward. The Faculty of Dentistry at Alexandria University's Oral and Maxillofacial Surgery Department performed the operations on the chosen patients.

Group 1: (Study group) was subjected to reconstruction or defect repair utilizing titanium mesh covered with HA nanocrystals.

Group 2: (Control group) patient that was subjected to reconstruction using uncoated titanium mesh.

Sample size was estimated assuming 5% alpha error and 80% study power. The mean gained bone density after 3 months using titanium mesh without grafting was 494.6 HU (20) and it was estimated to be 324.5 HU for titanium mesh with particulate bone graft. (21) Based on comparison of two independent means and $SD=78$ (22), Total sample size = Number per group x Number of groups = $6 \times 2 = 12$ patients, with the minimum sample size calculated to be 5 patients per group, increased to 6 patients to make up for lost to follow up instances.

Informed Consent

Informed written consent was obtained from all participating patients after explaining the procedure, possible complications, and their rights to withdraw from the study. The Ethics committee of the Faculty of Dentistry, Alexandria University, approved the study.

Inclusion criteria

1. Age groups from 16 to 60 years old for both sexes.
2. According to cordeiro's classification limited size defects (23).
3. Midface comminuted fractures (24).
4. Pure orbital fractures unilateral or bilateral or in conjunction with other facial fractures (24).
5. Midface repair after removal of pathological lesions (24).
6. Reconstruction of frontal sinus and fronto-naso-ethmoidal fractures (24).

Exclusion criteria

1. Fractured bones with infections
2. Long-term systemic illnesses
3. Soft tissue defects.
4. Patients with burn injuries
5. Patients who have carcinomas and sarcomas in their oral cavities.
6. Patients declined to participate.
7. Load bearing sites.

Materials

8. Titanium mesh and screws (Medi- Tec Company, Cairo, Egypt).
9. Natural Hydroxyapatite Nano Graft (Nanograft: Egyptian European pharmaceutical company- Alamreya, Alexandria). □ □
10. Computed tomography (CT) device (Ingenuity Core; Philips Medical Systems, Cleveland, OH).
11. Ultraviolet (UV)-curable photopolymer resin (eResin-PLA, ESUN, Wuhan, Shenzhen, China. esun3d.net.).
12. Stereolithography (SLA) 3D-printer with its post-curing unit (Sony SCS 8100. Manufactured by Sony; Zhou-Zi St., Nei Hu, Taipei 114, Taiwan).

Preparation of the titanium mesh:

The nanohydroxyapatite was synthesized in the Institute of Graduate Studies and Research, Alexandria, Egypt and the titanium mesh was coated with hydroxyapatite nanocrystals using electrophoretic deposition (EPD) at the Chemistry Laboratories, Faculty of Science, Alexandria University.

Ethanol was used to clean the titanium mesh, and the plates were then immersed in pure butanol (El-Nasr medicinal chemical company, Alexandria Egypt) for 24 hours. Natural nano-hydroxyapatite was used to make a 5% (wt/wt) suspension.

Nanohydroxyapatite has a porosity of 60-80% and a diameter of 10-60 nm. Pure butanol was combined with 5 gms of nano-hydroxyapatite. To avoid air bubbles, ultrasonication of the suspension for one hour. The EPD procedure was carried out in electrophoretic deposition apparatus.

Sintering was done in a vented oven at 1000°C for 6 hours, and the samples were sterilized by gamma radiation at 2.5 Mrad at the Nuclear Energy Organization in Cairo before being used in our investigation. (Figure 1)

Intervention

I. Presurgical phase

Preoperative assessment was performed including history taking, intraoral and extra-oral clinical examination and radiological evaluation using CT scan with axial, coronal, sagittal and 3D reconstruction views. Preoperative virtual treatment planning and the design process of the 3D printed reduction guide was done. (Figure 2)

II. Surgical phase

Open reduction and internal fixation was performed for all the patients. For Group (1) the coated titanium mesh was adapted and placed in the orbital floor for reconstruction of the defect. For Group (2) the conventional uncoated titanium mesh was adapted and placed in the orbital floor for reconstruction of the defect. (Figure 3)

III. Follow-up Phase

The follow-up schedule was 24 hours, 1 week, 4 weeks, and 3 months postoperatively. The clinical follow-up included evaluation of the infra orbital nerve sensory function and postoperative ocular complications such as enophthalmous or limited eye movements. Postoperative CT scan was taken within 2 days after surgery to evaluate adequate reduction of the fractured segments. (Figure 4)

Statistical analysis

Version 20.0 of the IBM SPSS software package (Armonk, NY: IBM Corp.) was used to evaluate the data once they were loaded into the computer. Quantitative data were described using range (minimum and maximum), mean, and standard deviation.

At the 5% level, significance of the results was determined.

The used tests were

- 1 - Student t-test for quantifiable variables with a normal distribution are used to compare the two study groups.
- 2 - ANOVA Use the Post Hoc Test (modified Bonferroni) with repeated measures to compare more than two periods or stages for normally distributed quantitative variables.




Figure (1): a-Titanium Mesh, b- natural nanohydroxyapatite, c- electrophoretic deposition process, d- vented oven for sintering

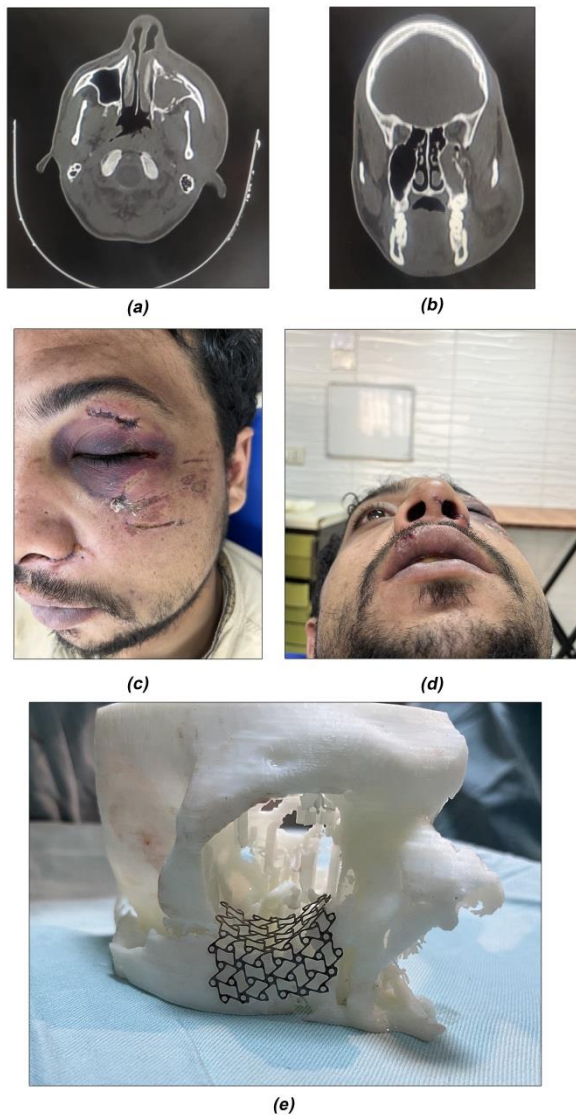

Figure (2): a- axial view of CT scan showing floor fracture of the left orbit, b- coronal view of CT scan showing orbital floor fracture of the left orbit, c- preoperative photograph showing signs of orbital fracture, d- worm eye view showing depression in the traumatized site due to fracture, e- stereolithograph model with adapted titanium mesh.

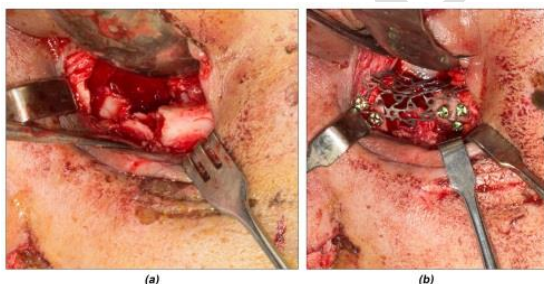


Figure (3): a- Intraoperative photograph showing orbital floor fracture, b- intraoperative photograph showing placement of the coated titanium mesh for reconstruction of the orbital floor.

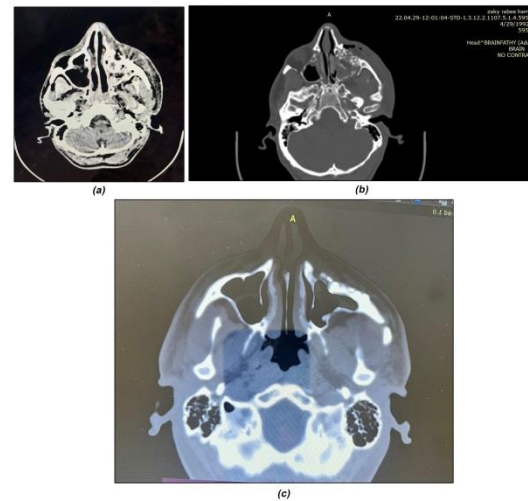


Figure (4): a- immediate post operative axial view of CT scan of reconstructed orbital floor with coated titanium mesh, b- axial view of CT scan of one month postoperative of reconstructed orbital floor with coated titanium mesh, c- axial view of CT scan of 3 month postoperative of reconstructed orbital floor with coated titanium mesh.

RESULTS

Epidemiology and demographic data

The age of the patients was between 19 and 49 years old, with a mean age of 28.9 ± 8.62 . For group A, the mean age was 28 ± 10.55 ; for group B, it was 29.83 ± 5.98 . Physical violence was the etiologic factor in 25% of cases, while road traffic accidents (RTA) accounted for 58.3% of cases. Falls accounted for 16.6% of cases. (Table1)

Radiographical results

Postoperative measurements showed statistically significant difference in the bone density between the immediate postoperative and the 3 months postoperative CT scans when measured using OsiriX software.

The improve in the bone density in the immediate postoperative the mean range was 187.8 ± 37.63 for the study group and for the control group 145.3 ± 72.73 . While the increase in the bone density was significantly increased in the 3 months postoperative with a mean range of 985.3 ± 144.4 for the study group and 365.8 ± 70.43 for the control group. (Table 2) (Figure 5)

The comparison between the preoperative the immediate postoperative and the 3 months postoperative was statistically significant at $p \leq 0.05$. (Table 3)(Figure 6)

CT scans showed good bone formation in the study cases where the natural nanohydroxyapatite coated titanium mesh was used in the reconstruction of the orbital floor within 3 months more than the control where the conventional titanium mesh was used.

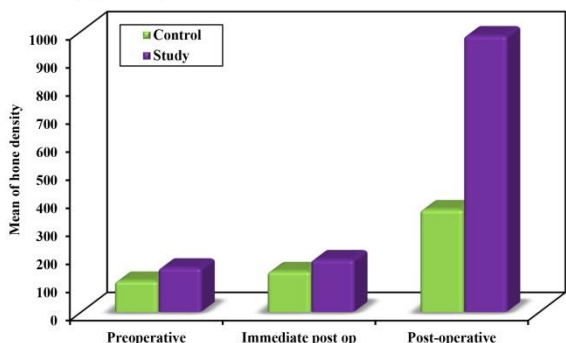


Figure (5): Comparison between the two studied groups according to bone density

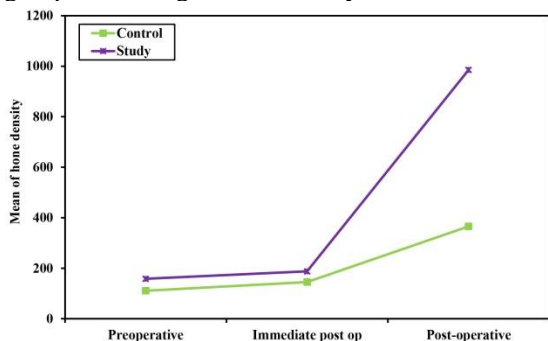


Figure (6): Comparison between the three studied periods according to bone density

Table 1: Comparison between the two studied groups according to demographic data.

	Group A (n = 6)		Group B (n = 6)	
	No.	%	No.	%
Sex				
Male	5	83.33	4	66.66
Female	1	16.66	2	33.33
Age (years)				
Min. – Max.	19.0 – 49.0		22.0 – 41.0	
Mean ± SD.	28 ± 10.55		29.83 ± 5.98	
Median	22.5		29.5	

Table (2): Comparison between the two studied groups according to Hone density

Hone density	Control (n = 6)	Study (n = 6)	t	p
Preoperative				
Min. – Max.	69.04 – 223.1	108.4 – 195.3	1.696	0.121
Mean ± SD.	111.05 ± 56.35	158.3 ± 38.47		
Immediate post op.				
Min. – Max.	84.67 – 285.3	142.1 – 229.8	1.272	0.232
Mean ± SD.	145.3 ± 72.73	187.8 ± 37.63		
Post-operative				
Min. – Max.	290.3 – 462.9	839.8 – 1244.0	9.446	<0.001*
Mean ± SD.	365.8 ± 70.43	985.3 ± 144.4		
Increase				
Min. – Max.	182.6 – 380.1	663.0 – 1133.7	7.628*	<0.001*
Mean ± SD.	254.8 ± 76.72	827.1 ± 166.7		

IQR: Inter quartile range SD: Standard deviation
t: Student t-test

Increase between **Post-operative** and **Preoperative**
p: p value for comparing between the two studied groups
*: Statistically significant at $p \leq 0.05$

Table (3): Comparison between the three studied periods according to hone density

Hone density	Preoperative	Immediate post op.	Post-operative	F	p
Control (n = 6)					
Min. – Max.	69.04 – 223.1	84.67 – 285.3	290.3 – 462.9	48.629*	0.001*
Mean ± SD.	111.05 ± 56.35	145.3 ± 72.73	365.8 ± 70.43		
Sig. bet. periods.	$p_1=0.027^*, p_2=0.001^*, p_3=0.005^*$				
Study (n = 6)					
Min. – Max.	108.4 – 195.3	142.1 – 229.8	839.8 – 1244.0	138.999*	<0.001
Mean ± SD.	158.3 ± 38.47	187.8 ± 37.63	985.3 ± 144.4		
Sig. bet. periods.	$p_1=0.012^*, p_2<0.001^*, p_3<0.001^*$				

SD: Standard deviation
F: F test (ANOVA) with repeated measures, Sig. bet. periods was done using **Post Hoc Test (adjusted Bonferroni)**
p: p value for comparing between the three studied periods
 p_1 : p value for comparing between the **Preoperative** and **Immediate post op**
 p_2 : p value for comparing between the **Preoperative** and **Post-operative**
 p_3 : p value for comparing between the **Immediate post op.** and **Post-operative**
*: Statistically significant at $p \leq 0.05$

DISCUSSION

Over the years, scientists and surgeons have found that reconstructing maxillofacial continuity abnormalities has been a difficult undertaking. The basic goal of maxillofacial reconstruction is the facial form, function, and full occlusion rehabilitation (25).
The study was made on 12 patients that was divided into 2 groups each of 6 patients the study group was using the titanium mesh coated with natural nanohydroxyapatite in reconstruction of the orbital floor and the control group which consisted of 6 patient where we used the conventional titanium mesh in reconstructing the orbital floor.
In this investigation, titanium mesh was employed to stabilize orbital floor fractures. This follows a study published in 2023 (26), in which Munoli, Bhanushali and Jagannathan reported the precontoured titanium mesh that preserves the anatomy of the orbital wall and is quick, simple, repeatable, and has a low learning curve. Prefabricated titanium mesh can be a good

reconstructive alternative for orbital fractures with careful patient selection and application (27).

Although titanium (Ti) and its alloys are the most extensively used materials in dentistry, due to their superior biocompatibility, corrosion resistance, excellent mechanical qualities, and efficiency (28), one of its major drawbacks is its inability to form a link with living host tissue (18).

The application of HA as a surface coating on mechanically resistant metallic implants, including titanium, in an effort to facilitate bone attachment to the implant, has thus been one of the most significant advancements in bone repair during the past 30 years (29).

Because of its special qualities, such as the capacity to chemically bond to bone, the inability to cause inflammation, and the capacity to enhance bone induction through direct osteoblastic activity, the nanohydroxyapatite has been widely used as an additive material, in order to enhance existing and extensively used dental materials according to a study conducted in 2020 by Peterssen et al (30).

As delineated by Avcu et al in 2019 (31), EPD was chosen as the coating method of choice because it has various edge over different techniques, including a quick coating time (2-3 min), good recreatability, repeatability, low cost, and ensures process speed. This method also allows for the control of coating thickness, homogeneity, and deposition rate.

In agreement with Rasouli et al in 2018 (32) and Taranu et al in 2022 (33), overlaying physiologically active compounds over biologically inert metallic implants, such as hydroxyapatite, aims to speed up bone production and improve mechanical qualities during the early stages of osseointegration. Kaur described electrophoresis-based HA deposition as the best technology for coating uneven surfaces in 2019 (34).

Regarding the clinical follow-up of this study, all patients showed uneventful healing with no evidence of infection, allergies or wound dehiscence in any of the patients. This proves the excellent biocompatibility of both the titanium and the HA nanocrystals.

In both the immediate postoperative time and the post-operative period, there was a statistically significant difference in the radiographic examination between the study and the control groups.

Osteoconduction and osteoinduction of HA scaffolds are well known, according to Wang, Cao, Hua et al. in 2022 (35). Osteoblastic cell adhesion, development, and differentiation are supported by HA surfaces, and new bone is produced by creeping substitution from nearby living bone.

The scaffolds are seeded with cells that will create new centers for bone formation, such as osteoblasts and mesenchymal cells that have the capacity to commit to an osteoblastic lineage, before they are

implanted. This is how osteogenesis is finally triggered (35).

Hydroxyapatite nanocrystals coatings have traditionally been believed of as osteoconductive. HA coatings have been proven to enhance new bone growth when there are gaps of 1-2 mm between the coated implant and the surrounding bone as well as on an implant surface with a line-to-line fit. Additionally, the HA covering reduces the development of fibrous tissue that would ordinarily happen as a result of tiny motions of an uncoated titanium implant (36).

In addition to offering a method to speed up osseointegration, hydroxyapatite coatings also serve to seal the interface against wear particles and macrophage-associated periprosthetic osteolysis (37,38). While some studies have found no changes between coated and untreated implants, the majority have indicated enhanced fixation with a reduction in the number of radiolucencies around a HA coated titanium alloy (39,40).

The study's overall findings showed that the study group's bone healing and osteoblastic activity were superior to those of the control group and occurred more quickly. These radiography results demonstrated that HA nano-crystals coated titanium mesh may be used as a suitable bone substitute and reconstructive material and that its osteoconductive qualities can encourage bone regeneration in bone defects.

CONCLUSION

This study demonstrated better bone density outcomes in reconstructed orbital floor defects using titanium mesh coated with HA nanocrystals by EPD after 3months postoperatively.

CONFLICT OF INTEREST

The authors declare that they have no conflicting of interests

FUNDING

The authors received no specific funding for this work.

REFERENCES

1. Vallefucio R, Bird F, Gordo I, Brissot H, Fina C. Titanium mesh osteosynthesis for the treatment of severely comminuted maxillofacial fractures in four dogs. *J Small Anim Pract.* 2021;62:903-10.
2. De Paolo MH, Arzi B, Pollard RE, Kass PH, Verstraete FJM. Craniomaxillofacial trauma in dogs-part I: Fracture location, morphology and etiology. *Front Vet Sci.* 2020;7:241.
3. Medeiros YL, Loures AO, Silva BN, Rehe PR, Devito KL, Carvalho MF. Tomographic analysis of nasomaxillary and zygomaticomaxillary buttress bone thickness for the fixation of miniplates. *J Oral Maxillofac Surg.* 2021;50:1034-9.

4. Błaszczuk B, Studziński M, Ładziński P. Coincidence of craniocerebral and craniofacial injuries. *J Oral Maxillofac Surg.* 2019;47:287–92.
5. Michelet FX, Deymcs JB, Dessus B. Osteosynthesis with miniaturized screwed plates in maxillofacial surgery. *J Oral Maxillofac Surg.* 1973;1:79-84.
6. Salavadi RK, Sinha R, Vadepally AK, Uppada UK. Comparative evaluation of conventional miniplates, three-dimensional miniplates and lag screws for internal fixation of parasymphysis fracture of mandible-a double-blind randomized clinical study. *J Maxillofac Oral Surg.* 2022;21:283-9.
7. Kaur N, Kaur T, Kaur J, Kaur Y, Kapila S, Sandhu A. Efficacy of titanium mesh osteosynthesis in maxillofacial fractures. *J Maxillofac Oral Surg.* 2018.;17:417-24.
8. Riviş M, Roi C, Roi A, Nica D, Văleanu A, Rusu LC. The implications of titanium alloys applied in maxillofacial osteosynthesis. *Appl Sci.* 2020;10:3203.
9. James J, Oblak ML, Zur Linden AR, James FMK, Phillips J, Parkes M. Schedule feasibility and workflow for additive manufacturing of titanium plates for ranioplasty in canine skull tumors. *BMC Vet Res.* 2020;16:180.
10. Moskalewicz T, Warcaba M, Cieniek Ł, Sitarz M, Gajewska M, Boccaccini AR. Hydroxyapatite/sodium alginate coatings electrophoretically deposited on titanium substrates: Microstructure and properties. *Appl Surf Sci.* 2021;540:148353.
11. Stöblein S, Grunwald I, Stelten J, Hartwig A. In-situ determination of time-dependent alginate-hydrogel formation by mechanical texture analysis. *Carbohydr Polym.* 2019;205:287-94.
12. Ezzat AM, Khalil AA, El-Dibany RM, Khalil NM. The use of titanium mesh coated with hydroxyapatite nanocrystals in mandibular fracture (experimental study). *Alex Dent J.* 2017;42:92-7.
13. Ren J, Zhao D, Qi F, Liu W, Chen Y. Heat and hydrothermal treatments on the microstructure evolution and mechanical properties of plasma sprayed hydroxyapatite coatings reinforced with graphene nanoplatelets. *J Mech Behav Biomed Mater.* 2020;101:103418.
14. Dewi AH, Ana ID. The use of hydroxyapatite bone substitute grafting for alveolar ridge preservation, sinus augmentation, and periodontal bone defect: A systematic review. *Heliyon.* 2018;2;4:e00884.
15. Shaikh MS, Zafar MS, Alnazzawi A. Comparing nanohydroxyapatite graft and other bone grafts in the repair of periodontal infrabony lesions: A systematic review and meta-analysis. *Int J Mol Sci.* 2021;22:12021.
16. Ansari Z, Kalantar M, Soriente A, Fasolino I, Kharaziha M, Ambrosio L, Raucci MG. In-situ synthesis and characterization of chitosan/hydroxyapatite nanocomposite coatings to improve the bioactive properties of Ti6Al4V substrates. *Materials.* 2020;13:3772.
17. Aydın İ, Bahçepinar Aİ, Kırman M, Çipiloğlu MA. HA coating on Ti6Al7Nb alloy using an electrophoretic deposition method and surface properties examination of the resulting coatings. *Coatings.* 2019;9:402.
18. Lu X, Wu Z, Xu K, Wang X, Wang S, Qiu H, et al. Multifunctional Coatings of Titanium Implants Toward Promoting Osseointegration and Preventing Infection: Recent Developments. *Front Bioeng Biotechnol.* 2021;9:783816.
19. Buehler JA, Tannyhill RJ 3rd. Complications in the treatment of midfacial fractures. *Oral Maxillofac Surg Clin North Am.* 2003;15:195-212.
20. Zachariades N, Papavassiliou D, Papademetriou I. The alterations in sensitivity of the infraorbital nerve following fractures of the zygomaticomaxillary complex. *J Craniomaxillofac Surg.* 1990;18:315-8.
21. Jamal BT, Pfahler SM, Lane KA, Bilyk JR, Pribitkin EA, Diecidue RJ, et al. Ophthalmic injuries in patients with zygomaticomaxillary complex fractures requiring surgical repair. *J Oral Maxillofac Surg.* 2009;67:986-9.
22. Susarla SM, Bojovic B. Acute intraorbital hemorrhage following reduction of a displaced orbitozygomaticomaxillary complex fracture. *Craniomaxillofac Trauma Reconstr.* 2015;8:221-7.
23. Erol B, Tanrikulu R, Görgün B. Maxillofacial fractures. Analysis of demographic distribution and treatment in 2901 patients (25-year experience). *J Craniomaxillofac Surg.* 2004;32:308-13.
24. Blumer M, Kumalic S, Gander T, Lanzer M, Rostetter C, Rucker M, et al. Retrospective analysis of 471 surgically treated zygomaticomaxillary complex fractures. *J Craniomaxillofac Surg.* 2018;46:269-73.
25. Abdelaziz D, Hefnawy A, Al-Wakeel E, El-Fallal A, El-Sherbiny IM. New biodegradable nanoparticles-in-nanofibers based membranes for guided periodontal tissue and bone regeneration with enhanced antibacterial activity. *J Adv Res.* 2020;28:51-62.
26. Munoli A, Bhanushali J, Jagannathan M. Outcome of precontoured titanium mesh in the reconstruction of orbital blowout fractures. *Indian J Plast Surg.* 2023;56:62-7.
27. Wevers M, Strabbing EM, Engin O, Gardeniers M, Koudstaal MJ. CT parameters in pure orbital wall fractures and their relevance in the choice of treatment and patient outcome: A systematic

- review. *Int J Oral Maxillofac Surg.* 2022;51:782–9.
28. Jeyaraj P. Frontal bone fractures and frontal sinus injuries: Treatment paradigms. *Ann Maxillofac Surg.* 2019;9:261-82.
 29. Costan VV, Boisteanu O, Timofte D, Dabija M. The value of titanium mesh in cranio-maxillofacial reconstructive surgery. *Revista de Chimie.* 2019;70:3021-3
 30. Yeo IS. Modifications of dental implant surfaces at the micro-and nano-level for enhanced osseointegration. *Materials.* 2019;13:89.
 31. Petersen LL, Baas J, Sørensen M, Bechtold JE, Søballe K, Barckman J. Accelerated bone growth, but impaired implant fixation in allograft bone mixed with nano-hydroxyapatite - an experimental study in 12 canines. *J Exp Orthop.* 2022;9:35.
 32. Avcu E, Baştan FE, Abdullah HZ, Rehman MA, Avcu YY, Boccaccini AR. Electrophoretic deposition of chitosan-based composite coatings for biomedical applications: A review. *Prog Mater Sci.* 2019;103:69-108.
 33. Rasouli R, Barhoum A, Uludag H. A review of nanostructured surfaces and materials for dental implants: surface coating, patterning and functionalization for improved performance. *Biomater Sci.* 2018;6:1312-38.
 34. Taranu BO, Ianasi P, Rus SF, Bucur AI. Simultaneous precipitation and electrodeposition of hydroxyapatite coatings at different temperatures on various metal substrates. *Coatings.* 2022;12:288.
 35. Wang D, Cao H, Hua W, Gao L, Yuan Y, Zhou X, et al. Mesenchymal stem cell-derived extracellular vesicles for bone defect repair. *Membranes (Basel).* 2022;12:716.
 36. Soballe K, Hansen ES, Brockstedt-Rasmussen H, Bunger C. Hydroxyapatite coating converts fibrous tissue to bone around loaded implants. *J Bone Joint Surg Br.* 1993;75:270-8.
 37. Rahbek O, Overgaard S, Lind M, Bendix K, Bunger C, Soballe K. Sealing effect of hydroxyapatite coating on peri-implant migration of particles. An experimental study in dogs. *J Bone Joint Surg Br.* 2001;83:441-7.
 38. Geesink RG. Osteoconductive coatings for total joint arthroplasty. *Clin Orthop Relat Res.* 2002;395:53-65.
 39. Lee JM, Lee CW. Comparison of hydroxyapatite-coated and non-hydroxyapatite-coated noncemented total hip arthroplasty in same patients. *J Arthroplasty.* 2007;22:1019-23.
 40. Lombardi AV Jr, Berend KR, Mallory TH. Hydroxyapatite-coated titanium porous plasma spray tapered stem: experience at 15 to 18 years. *Clin Orthop Relat Res.* 2006;453:81-5.