



Studies on clostridial infections in broiler chicken and ducks in Damietta governorate

FatmaElzhraswlam ,Youssef, I .Y, Soad , A .N .and Setta , A . M.

Department of Poultry and Rabbit Diseases, Faculty of Veterinary Medicine, Cairo University, Giza, Egypt
Reference Laboratory for Vet. Quality Control on Poultry production, Animal Health Research Institute ,Dokki ,Giza

Abstract

Clostridial infections are important concern to poultry industry because of severe economic losses and increased mortalities. This study was carried to investigate the current situation of *C. Perfringens* infection in broilers and ducks in Damietta governorate, Egypt. A total of 141 intestinal and liver samples were collected from diseased and dead broiler chickens with diarrheic chickens (n=129) and ducks (n=12) from private farms to be examined for *Clostridium perfringens*. The rate of isolation was 48.22% while isolation rate in broiler chickens and ducks was 47.22% and 58.33% respectively. In-vitro sensitivity test was made against different types of antibiotics showing that the examined isolates were highly sensitive to amoxicillin, ampicillin and doxycycline. Detection of toxins by animal inoculation by using Guinea pigs and identification of the isolates using PCR were done. Experimental infection was done in broiler chickens. Signs and post mortem lesions were recorded also re-isolation was done as well as histopathological findings were recorded.

Key words : *C. perfringens* – Necrotic enteritis – Experimental infection – Histopathological findings – Cooked meat media – PCR .

Introduction

Clostridia are commonly found in the environment, occurring in soil, sewage, and water, as well as in the intestine of both man and animal. Members of the genus clostridium are recognized as enteric pathogen for man, domestic animals and wild life (songer, 1996). *Clostridium perfringens* (*Cl. perfringens*) is a part of normal gut flora, which commonly involved in diseases in most domestic animals and some wildlife including horses, poultry, rabbits, sheep, goats, cattle, mink, ostrich, dogs and cats (Nillo, 1993). Necrotic enteritis is an important sporadic disease of broiler chicken, that first reported by (Parish, 1961) to be caused mainly by *C. perfringens* (Prukker *et al.*, 1995).

Materials and methods

Samples : A total 141 samples (intestine n =90 and liver n =51) were collected from diseased broiler chickens with diarrheic chickens (n=129) and ducks (n=12) from private farms to be examined for *Clostridium perfringens*.

Isolation and Identification : Was done according to Willis (1997) the collected samples were inoculated into tubes of freshly prepared boiled and cooled cooked meat medium (Oxoid) and incubated anaerobically for 24 hours at 37°C. A loopful of inoculated fluid medium was streaked onto neomycin sulphate sheep blood agar plates according to Carter and Cole (1999). The

Mucosal damage inducing factors such as coccidiosis (parasitism), high fiber litters, dietary changes and poor hygienic and housing conditions are predisposing factors. These may produce a favorable growth environment for *C. perfringens*, resulting in its over growth and production of potent toxins that leads to necrotic enteritis (Vissienet *et al.*, 1994). Necrotic enteritis (NE) in poultry is caused by *C. perfringens* type A or C (Ficken, 1991). Necrotic enteritis occurs when there is an increase in the intestinal population of *C. perfringens* following ingestion of a large number of bacteria (Riddell and Kong, 1992) or an upset in the normal intestinal microflora (Fukata *et al.*, 1987).

streaked plates were incubated anaerobically for 24 hours at 37 C using a gaspak anaerobic jar.

Biochemical identification: according to the scheme of Koneman *et al.*, (1992) and Macfaddin, (2000). The *C. perfringens* isolates were subjected to biochemical identification patterns, including haemolytic activity on sheep blood agar, lecithinase activity on egg yolk agar, catalase test, indole test, urease test, sugar fermentation (lactose, glucose, sucrose and maltose) and liquefaction test.

Typing of *C. perfringens* toxins by dermonecrotic test in albino Guinea pigs: preparation of the toxins was done

according to Bullen, (1952) Application and interpretation of the test in albino Guinea pigs were adopted after Oakley and Warrak,(1953) and Quinn et al., (2002)

In vitro antibiotic sensitivity test:The disc diffusion technique was applied according to

National Committee for Clinical Laboratory Standards (NCCLS), (1998).

Genotyping of C.perfringens using polymerase chain reaction (PCR)
:Oligonucleotide primers used for detection of alpha and beta toxins by conventional PCR was carried out according to Yoo et al. (1997).

Table (1): Oligonucleotide primers sequences

Source:Midland Certified Reagent Company_ oilgos (USA).

Toxin	Primer	Sequence	Amplified product
Alpha toxin	F	GTTGATAGCGCAGGACATGTTAAG	402bp
	R	CATGTAGTCATCTGTTCCAGCATC	
Beta toxin	F	ACTATACAGACAGATCATTCAACC	236 bp
	R	TTAGGAGCAGTTAGAACTACAGAC	

Extraction of DNA was done According to QIAamp DNA mini kit instructions.

Preparation of PCR master mix :was done according to according to Emerald Amp GT PCR mastermix (Takara) Code No. RR310A kit DNA samples were amplified in a total volume of 25µl of the following reaction mixture: 12.5µl of PCR master mix, 1µl of both of forward and reverse primer for each toxin gene (alpha and beta), 4.5µl of PCR grade water, and 6µl of the template DNA. Thermal cycling designed as initial denaturation for 5 min at 94°C, the samples were subjected to 35 cycles of denaturation at 94°C for 1 min, annealing at 55°C for 1 min and extension at 72°C for 1 min. After the last cycle, a final extension was performed for 10 min. at 72°C. The detection of amplified products were analyzed by electrophoresis on agarose gel which supplemented with ethidium bromide in order to visualize the DNA on an UV transilluminator .(Sambrook et al., 1989).

Experimental induction of NE in broiler chickens:

A total number of 40 Cobb broiler chicks obtained at 1 day of age were reared for experimental study .They were housed in the same room and chickens had ad libitum access to drinking water and feed .At 20th day of age they were divided into two groups ,group 1 containinig 11 chicks were kept without inoculation as negative control group and group 2 containing 29 chicks were inoculated each orally by (1ml × 10⁸cfu)of 24 hrs. cooked meat broth culture of the identified toxigenic Cl.perfringens isolates .The plate count technique was carried out according to Cruickshank et al., (1975) for the determination of the viable count of cell per ml suspension. Each bird in infected group was inoculated

orally 1ml (1× 10⁸cfu) with clostridial isolate according to Abd El-GwadandAbd El-Kader (2001). Both groups were kept for 10 days with daily observation for clinical signs .At the end of the observation period, all experimental and control birds were slaughtered and subjected to postmortem and bacteriological examination for reisolation of the inoculated organisms. The presence of C.perfringens was confirmed by colony morphology, Gram-staining,negative reaction in catalase, indole, and urease test , as well as histopathological examination .Samples were taken from intestine and liver at 3,5, and 7 day post infection . Feed consumption and average body weight were recorded in control and infected group as shown in

Results and discussion

Clinical signs of diseased birds and post-mortem examination of dead ones: The diseased birds exhibited general signs in the form of depression, reluctance to move, pronounced apathy, ruffled feather and watery diarrhoea .Moreover, the pathological lesions of dead birds revealed friable small intestine (duodenum and jejunum) distended with gas. The intestinal mucosae were covered by yellowish or green pseudo membrane.

A total of 141 samples collected from freshly dead broilers, and ducks were investigated for the presence of C.perfringens ,out of which 68 isolates were detected (48.22%) Abd El- Hamid et al., (2015) .The isolation from broilers was (47.28%) and ducks (58.33%)that results were relatively similar to results obtained by Abd El-Hamid et al .,(2015) who recorded isolation from broilers (77.4%) and while El-Jakeet al ., (2013) recorded isolation from broilers (75%) and ducks (66.6%).

Concerning the incidence of *C.perfringens* among dead birds from intestine and liver samples the rate of isolation was 51.11% and 43.13% respectively as shown in table (2) and table(3). This table indicated that there were significant rise in isolation rate of *C.perfringens* from intestinal samples compared with liver samples and this could be attributed to the fact that *C.perfringens* a normal inhabitant in intestine and is considered as mean predisposing

factor to necrotic enteritis (Silva, et al., 2009). This results partially agreed with Abd El-Hamid et al., (2015) who recorded that isolation from intestine and liver was (79%) and (41.3%) respectively. The present results were higher than results obtained by El-Refaey (1999); Craven et al., (2001) who recorded that the incidence of *C.perfringens* isolation from intestine was 33.3% and 20%, respectively.

Table (2):Incidence of *C.perfringens* in examined intestinal samples from broiler chickens and ducks in Damietta govenorate.

* Incidence was calculated according to total samples number.

No. of examined farms		No. of examined intestinal samples	No. of +ve <i>C.perfringens</i> isolates	* Incidence of <i>C.perfringens</i> in examined farms (%)
broilers	٨٤	84 pool samples	43	51.19
ducks	٦	6 pool samples	٣	50
Total samples		٩٠	٤٦	51.11

Table (3):Incidence of *C.perfringens* in examined liver samples from broiler chickens and ducks .

No. of examined farms		No. of examined liver samples	No. of +ve <i>C.perfringens</i> isolates	*Incidence of <i>C.perfringens</i> in examined farms (%)
broilers	٨٤	45 pool samples	18	40%
ducks	٦	6 pool samples	4	66.6%
Total samples		٥١	22	٤٣.١٣

Characterization of bacterial isolates: All bacterial isolates exhibited the characteristic features of *C. perfringens*. The colonial characters on blood agar showed dew drops smooth greyish convex colonies with a double zone of haemolysis. Microscopic characters revealed gram positive non motile rods.

Biochemical identification of the isolates showed catalase, indole, urease negative while lecithinase, gelatinase were positive and a haemolytic activity on sheep blood agar showing double zone of haemolysis. Gas and acid from lactose, glucose, sucrose and maltose were seen. Negler's reaction was positive.

Dermonecrotic reaction in albino Guinea pigs was used for differentiation of different *C.perfringens* types, the result was type A showed an irregular area of yellowish to greenish necrosis and the lesion tend to spread downward (alpha toxin).

In vitro sensitivity of *C.perfringens* isolates to different antimicrobial agent: Sensitivity of *C.perfringens* isolates to antimicrobial agents was studied. *C.perfringens* isolates were sensitive to amoxicillin, ampicillin, penicillin

and doxycycline while, resistant to gentamicin, streptomycin and colistin but they intermediate sensitivity to Sulphaquinoxalin/Trimethprim and Ceftriaxone. These results agreed with Abd-El Gwad and Abd-El Kader (2001) who said that *C. Perfringens* isolates were highly sensitive to ampicillin, ciprofloxacin, amoxicillin, colistine, lincomycin and moderately sensitive to enrofloxacin, chloramphenicol, erythromycin, oxytetracycline, nalidixic acid, while neomycin, gentamycin, streptomycin had no effect at all. Such data was partially agree also with Silva et al., (2009) who revealed that *C.perfringens* isolates were sensitive to penicillin, avilamycin, monensin and narasin but resistant to tetracycline and bacitracin. These findings relatively came with that recorded by Heba (2012) who found amoxicillin and ampicillin were the most effective therapy and prevention of *C. perfringens* infection while enrofloxacin and oxytetracycline were intermediate sensitivity.

Result of PCR

In this study we used PCR technique as a recent, rapid, reliable and accurate diagnostic tool for

characterization proved that 12 examined field isolates were *C.perfringens* type A(Alpha toxin) at 402bp as inFig no.(3)and all isolates were negative for beta toxins. This agreed with Effat et al. (2007) who reported that the same single amplicon, with the same size representing the alpha toxin encoding gene was amplified from all *C. Perfringens*field isolates causing outbreaks of severe NE during the winter of 2006 in Egypt.This result is hand to hand toAbd El-Hamid et al ., (2015).

Experimental infection was done in broiler chickens by using forty –one day old baby chicks obtained from commercial hatchery . The infectious dose was used according to Abd El-Gwad and Abd El-Kader (2001) with 1ml (1×10^8 cfu) of the identified toxigenic *C.perfringens* isolate orally. The chicks were experimentally infection at 20days old.

The clinical signs were recorded as depression , ruffled feathers and pasty brown diarrhea that agree with Al-Sheikhly and Al-Saieg, (1980) and Gadzinski and Julian, (1992) .

The post mortum lesions were recorded as liver showed congestion , friability and subcapsular hemorrhage as Fig (4)while intestine showed enteritisand duodenum, jejunum and ileum, are thin walled, friable, dilated and filled with gas as Fig(5) and (6) this lesion is hand to hand with those recorded by Broussard et al., (1986) , Mostafa, (1992), andAbd El-Gwadand Abd El-Kader (2001)

Reisolation was done from the intestine and liver with rates (68.9%),(48.27%) respectively as Table () neighbor joining study with Abd El-Hamid et al ., (2015).

Organs for histopathological examinations were collected from intestine and liver .The examination showing of liver 3 & 5 and 7 days post infection revealed, congestion of central

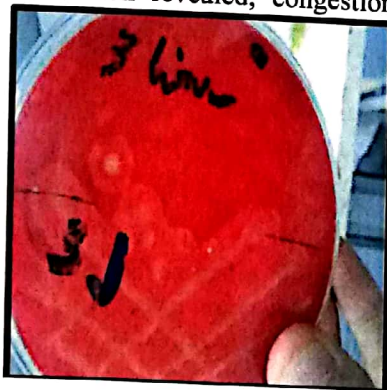
vein and hepatic sinusoids, many cases showed periportal inflammatory cells infiltration ranged in severity from mild to heavy infiltration either with mononuclear cells, heterophils or bothwith different severity,similar findings were recorded byPrescott (1977) and Heba (2012).

Histopathological examination of intestines 3 days post infection showed heavy mononuclear and heterophilic cells infiltration of lamina propriaIntestinal lesions became more obvious and severe in 5 day posy infection, some cases showed severe intestinal congestion and hemorrhagewith mononuclear cells infiltration and necrosis in the intestinal glands. Heterophilic cells infiltration of lamina propria was also detected in many cases.Many other cases showed severe necrotic enteritis manifested by complete destruction and necrosis of lamina epithelialis.Thereforhistopathological examination of intestine 7 days post infection showed necrotic enteritis in many cases with complete destruction of intestinal glands similar histopathological alterations were also observed previously in broiler chickens by Hofshagen and Stenwig, (1992) and in rabbits by Heba(2012)Fig(7) and Fig(8).

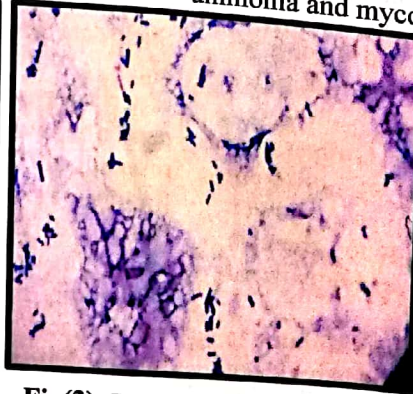Concerning body weight the infected group has lower body weight than control group and this observed result was agree with Al-Sheikhly and Al-Saieg, 1980 and Gadzinski and Julian, 1992).

Conclusion

C.perfringens has a highly pathological effect on broiler and ducks .*C. Perfringen*stype A was the most predominant etiology of necrotic enteritis in the examined chicken flocks in Dameitta governorate.Good concern should be taken to prevent such infection in poultry farms through biosecurity and predisposing factors such as coccidiaovercrowding, badlitter, increase ammonia and mycotoxins.

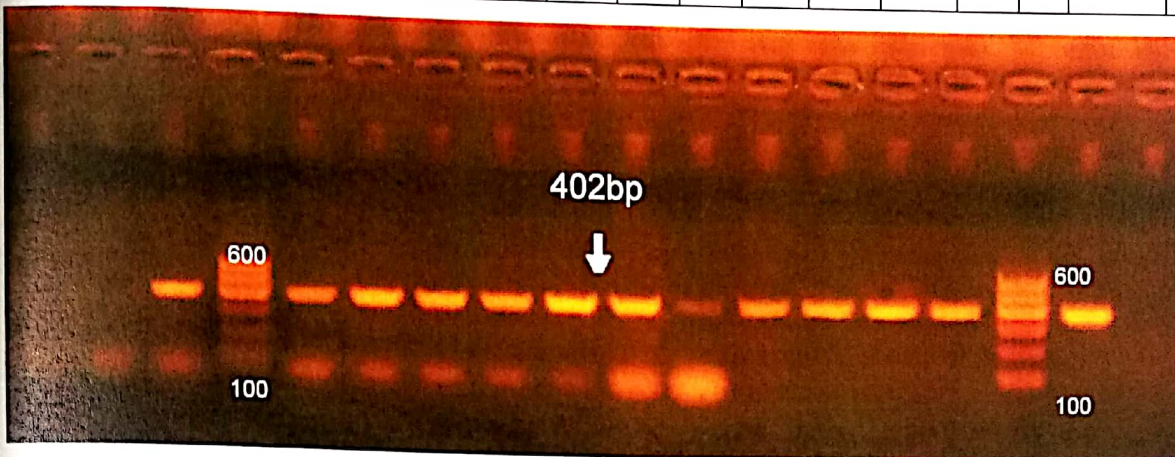


Fig(1):The isolates grow on 10% sheep blood agar medium showing the double zone of haemolysis

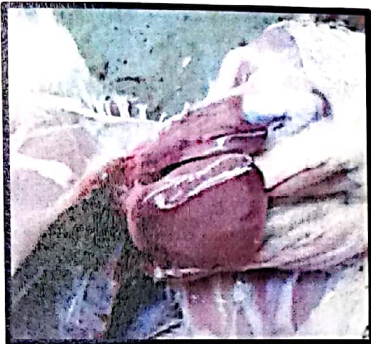

Fig(2):Gram +ve bacilli of isolates showing small straight bacilli with rounded end & parallel sides and spores were usually absent.

1	2	3	L	4	5	6	7	8	9	10	11	12	13	14	L	Pos	Neg
---	---	---	---	---	---	---	---	---	---	----	----	----	----	----	---	-----	-----



Fig(3):Agarose gel electrophoresis for detection of *C.perfringens* alpha-toxin gene .



Fig(4): Liver showing congestionand friability

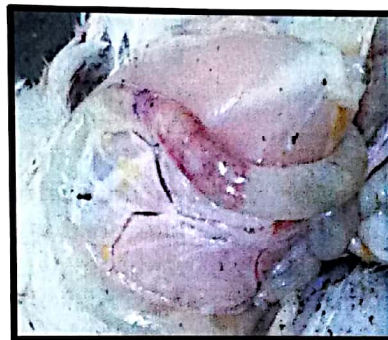

Fig (5):Ballooning of small intestine

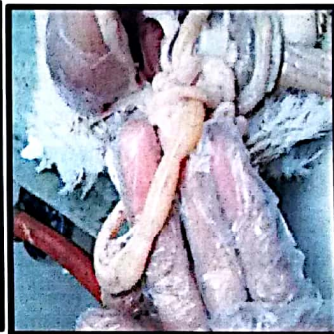


Fig (6)Intestine showing inflammation

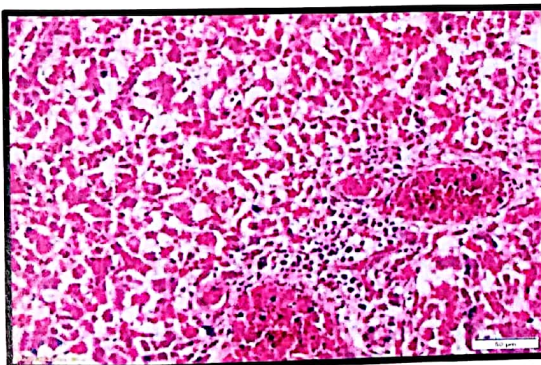


Figure (7): Liver of chicken 7 days post infection, showing severe congestion and necrosis of hepatocytes (H&E)

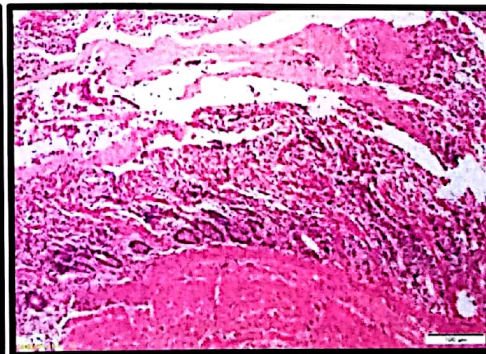


Figure (8): Intestine of chicken 7 days post infection, showing severe necrotic enteritis (H&E)

Acknowledgment

Gratful thanks to poultry and Rabbit diseases department, faculty of veterinary medicine, Cairo University for performing experimental infection and also to Reference Laboratory

for Vet. Quality Control on Poultry production, Animal Health Research Institute ,Dokki ,Giza for laboratory work and conducting the PCR

References

- Abd El-Hamid H. S., Ellakany H. F., Bekhit A. A., Elbestawy A. R. and S. Bedawy (2015): "Clinical and Laboratory Studies on Chicken Isolates of Clostridium Perfringens in El-Behera, Egypt". *J. World's Poult. Res.* 5(2): 21-28, June 25
- Abd El-Gwad, A.M. and H.A. Abd El-Kader (2001): "The occurrence of Clostridium perfringens in the intestine of broiler chickens in Assiut governorate". *Assiut University Bulletin for Environmental Researches*, 4 (2).
- Abd El-Moez, Sh.; Hamza, D.A.; Dorgham, S.M.; Ahmed, B.M.; Khairy, E.A. and R.H. Hedia (2014): Molecular Characterization and Genetic Diversity among Clostridium perfringens Isolates. *Int. J. Curr. Microbiol. App. Sci.*, 3(4): 125-134.
- Al-Sheikhly, F. and A. Al-Saieg (1986): "Role of coccidia in the occurrence of necrotic enteritis of chicken." *Avian Dis.*, 24 324-333.
- Broussard, C.T.; Hofacre, C.L.; Page, R.K. and O.J. Fletcher (1986): "Necrotic enteritis in cage-reared commercial layer pullets". *Avian Diseases*, 30(3): 617 -619.
- Bullen, J.J. (1952): "Clostridium welchii type D in the alimentary tract of normal sheep." *J. Path. Bact.*, 64: 201-210.
- Carter, G.R. and J.R. Cole (1990): "Diagnostic procedures in veterinary bacteriology and mycology." 5th Ed., Academic Press, Harcourt, Brace Jovanovich, Publisher, New York, Boston, Tokyo, Toronto.
- Cruickshank, R.; Duguid, J.P.; Marmion, B.R. and R.H.A. Swain (1975): "Medical Microbiology.", 12th Ed., Livingstone, London, New York. pp. 812-825.
- Effat MM, Abdallah YA, Soheir MF and MM. Rady (2007): Characterization of Clostridium Perfringens field isolates implicated in necrotic enteritis outbreaks on private broiler farms in Cairo, by multiplex PCR. *African Journal of Microbiology Research*, pp: 29-32.
- Ficken, M. D. (1991): "Necrotic enteritis In Diseases of poultry.", ed. Calnek, B. W., Barnes, H.J.; Beard, C.W., Reid, W.M. and Yoder, H.W. Jr. eds. Iowa State University Press, Ames, Iowa. PP. 264-267.
- Fukata, I., Kageyama, A., Baba, E. and A. Arakawa (1987): "Effect of infection with Eimeria tenella upon the cecal bacterial population in monoflora chickens." *Poult. Sci.*, 66 (5): 841-844 .
- Gazdzinski, P. and R.J. Julian (1992): "Necrotic enteritis in turkeys". *Avian Diseases*, 36: 792-798.
- Heba M. salem (2012) : "Studies on some clostridial enteric diseases affecting weaned rabbits in Egypt " M.V.Sc. Thesis .Poultry and Rabbit diseases, Vet. Med. Cairo University
- Hofshagen, M. and H. Stenwig (1992): "Toxin production by Clostridium perfringens isolated from broiler chickens and capercaillies (Tetrao urogallus) with and without necrotizing enteritis." *Avian Disease*, 36: 837 – 843.
- Mostafa, E. M. (1992): Studies on the incidence of Clostridial organisms in domestic rabbits. M.V.Sc. Thesis (Microbiology), Faculty of Veterinary Medicine Zagazig University.
- Koneman, E.W.; Allen, S.D; Dowell, V.R. and H.W. Summers (1992): "Colour atlas and text book of diagnostic microbiology." 4th Ed. J.B. Lippincott, New York, London.
- Macfaddin, J.F. (2000): "Biochemical test for identification of medical bacteria" 3rd Ed. Lippincott Williams and Wilkins, Washington, Philadelphia, USA.
- National Committee for Clinical Laboratory Standards (NCCLS), (1998): Performance standards for antimicrobial disc susceptibility tests. 8th Ed. International Supplement. M-100-S7, Vol. 18 No. 1. National

- Thoen, eds).Iowa State University Press, Ames, 114-123.
- Oakley, C.L. and G.H. Warrack (1953):** "Routine typing of *Clostridium welchii*." J. Hyg. Gamb., 51: 102-107.
- Parish, W.E. (1961):** "Necrotic enteritis in fowl (*Gallus gallus domesticus*). "Histopathology of the disease and isolation of a strain of *Clostridium welchii*." J. Comp. Pathol., 71: 377-393.
- Prescott, J. F. (1977):** Tyzzer's disease in rabbit Britain. Veterinary record, 100(14):285-286.
- Prukner RE, Milakovic NL, Ivesa PS and N. Grigis (1995):** *Clostridium chauvoei* in hens Avian Pathol. 24(1): 201-206.
- Quinn PJ, Markey Bk, Carter ME, Donnelly WJC, Leonard FC and D. Maguire (2002) :** Microbiology and Microbial Diseases. 2nd Ed., Blackwell Science, 84-96.
- Riddell, C. and X.M. Kong (1992):** "The influence of diet on the incidence of necrotic enteritis in broiler chickens". Avian Dis. 36: 499-503.
- Sambrook, J.; Fritsch, E. F. and Maniatis, T. (1989):** Purification of closed circular DNA by equilibrium centrifugation in Cs-Clethidium bromide gradients. Molecular Cloning: a laboratory manual, New York, CSH laboratory.
- Silva, R.O.S.; Salvarani, F.M.; Assis, R.A.; Martins, N.R.S.; Piers, P.S. and F.C.F. Lobato (2009):** "Antimicrobial susceptibility of *Clostridium perfringens* strains isolate from broiler chickens." Braz. J. Microbiol., 40: 262-264.
- Songer, J.G. (1996):** "Clostridial enteritic disease of domestic animals." Clin. Microbiol Rev., 9: 216-234.
- Wissienon T, Johannsen U., and B. Köhler (1994):** Pathology and pathogenesis of *Clostridium perfringens* type A enterotoxaemia in fowls. Experimental reproduction, clinical picture and mortality rate. Monatsheft für veterinärmedizin. 49(1): 23- 28.
- Willis, A.T. (1977):** "Anaerobic Bacteriology, Clinical and laboratory practice . " 3rd Ed., Butter Worth, London.
- Yoo H.S., Lee S.U., Park K.Y. and Y.H. Park (1997):** " Molecular typing and epidemiological survey of prevalence of *Clostridium perfringens* types by multiplex PCR. " J. clin. Microbiol., 35 (1), 228-232.
- Yamagishi, T. ; Sugitani, K. ; Tanishima, K. and S. Nakamura (1997):** Polymerase chain reaction for differentiation of five toxin types of *C. perfringens*. Microbiol. Immunol., 41(4) : 295-299.

المستخلص العربي

في هذه الرسالة تم فحص عدد ١٤١ عينة من أمعاء وكبد دجاج تسمين و بط نافقة حديثا حيث تم جمعها من مزارع خاصة في محافظة دمياط. حيث تم عزل ٦١ عينة للكلوستريديوم بيرفرينجينز من ٨٤ مزرعة دجاج التسمين بإجمالي ١٢٩ عينة أمعاء وكبد (٨٤)، (٤٥) على الترتيب حيث كانت نسبة العزل الإجمالية (٤٧.٢٨%) بينما من الأمعاء (٤٣) بنسبة (٥١.١٩%) والكبد (١٨) بنسبة (٤٠%) بينما تم عزل ٧ عينات لنفس الميكروب من ٦ مزارع بط بإجمالي ١٢ عينة أمعاء وكبد (٦)، (٦) على الترتيب حيث كانت نسبة العزل الإجمالية (٥٨.٣٣%) بينما من الأمعاء (٣) بنسبة (٥٠%) والكبد (٤) بنسبة (٦٦.٦٦%) وهذا العينات كانت تعاني من أفات مرضية و تشريحية لعدوى الكلوسترديوم بيرفرينجينز. وقد تم تطبيق تفاعل الناجلز على عترات الكلوسترديوم بيرفرينجينز المعزولة لمعرفة تأثير الليسيين لسم الألفا لمح البيض باستخدام أجار مح البيض الغني وأوضحت النتائج تكون طبقة تمائل اللؤلؤ محيطة بالمستعمرات وقد تم أيضا في هذه الدراسة تصنيف عترات الكلوسترديوم بيرفرينجينز المعزولة باستخدام تفاعلات تنكز الجلد (بالحقن داخل الجلد في خنازير غينيا الألبينو) وأوضحت النتائج عند مكان الحق ظهرت منطقة تتراوح من اللون الأصفر إلى اللون الأخضر تمائل لسم الألفا. وبإجراء إختبار الحساسية لعدد ٧ عترات معزولة عشوائيا وجد أنها عالية الحساسية لكل من بنسلين ، الأموكسيسيلين ، أمبيسلين ، دوكسيسيكلين، وأوكسيسيكلين بينما لم يتأثر الجنتاميسين والإستربتومايسين والنيومايسين. وبإجراء تفاعل البلمرة المتسلسل لعدد ١٤ عترات معزولة عشوائيا تم التعرف على ١٢ عترة معزولة لسم الألفا بينما لم تظهر أي من النتائج لسم البيتا .

وبإجراء العدوى الصناعية بهذا الميكروب في دجاج تسمين عند عمر ٢٠ يوم عن طريق الفم لم يحدث أي وفيات بينما كانت الأفات المرضية والتشريحية تشبه إلى حد كبير تلك المسجلة في العدوى الطبيعية وهذا وقد تم عزل الميكروب مرة أخرى من الطيور بعد ذبحها حيث سجلت نسبة العزل من عينات الأمعاء ٦٨.٩% والكبد ٤٨.٢٧% .