

# Manual Vacuum Aspiration Alone Versus Manual Vacuum Aspiration Preceded by Methotrexate in Management of Caesarean Scar Pregnancy

Original  
Article

*Ehab Yasser Hamed Mohammed<sup>1</sup>, Mahmoud Mohamed Abdelrazik<sup>2</sup> and Ahmed Abd El Hamid El Zayadi<sup>2</sup>*

*Department of Obstetrics and Gynecology, <sup>1</sup>Sherbin Central Hospital, <sup>2</sup>Mansoura University, Egypt*

## ABSTRACT

**Purpose:** In this work, we tried to evaluate the effects of systemic methotrexate (MTX) in caesarean scar pregnancy (CSP) in patients treated with ultrasound-guided manual vacuum aspiration (MVA).

**Patients and Methods:** A prospective non randomized comparative study that was initially conducted on 50 cases diagnosed with caesarean scar pregnancy at Mansoura University hospital in one year from August 2021 till August 2022. In the assessment of treatment outcome, we included patients who met the following criteria: (1) they were diagnosed with undisturbed caesarean scar pregnancy. (2) The residual myometrial thickness was more than 3mm and (3) No contraindication for systemic MTX.

Twenty four cases therefore were excluded as they didn't meet the inclusion criteria, the other 26 cases were divided into two groups, (group 1) included 16 cases who underwent suction using MVA and (group 2) included 10 cases who received intramuscular (MTX) injection (dose of 50 mg/m<sup>2</sup>) followed by MVA. The clinical characteristics and the outcomes were analysed. Treatments were regarded as successful if there were complete resolution of the CSP mass, no complications, and no requirement to re-treat.

**Results:** Among (group 1), two cases were complicated with scar hematoma which resolved spontaneously and one case was complicated with severe bleeding and needed urgent laparotomy and hysterectomy was done.

While in (group 2) all of the cases were successful without any detected complications or need for additional treatment. There were no significant differences among the two groups in demographic and clinical characteristics, such as maternal age, gravidity, parity, fetal cardiac activity, gestational age at diagnosis, thickness of anterior lower uterine wall on US, type of CSP, initial human chorionic gonadotropin (HCG) levels and number of previous caesarean sections.

**Conclusion:** By grouping CSP patients who shared similar demographic and clinical characteristics we found that when suction by MVA is preceded by MTX injection, it tends to give better results with less complications detected and without further needed intervention.

**Key Words:** B-HCG, bleeding, CSP, MTX, MVA, suction curettage, ultrasound guided.

**Received:** 04 November 2023, **Accepted:** 11 December 2023

**Corresponding Author:** Mahmoud Mohamed Abdelrazik, Department of Obstetrics and Gynecology, Mansoura University, Egypt, **Tel.:** +20502946830/40, **E-mail:** dr\_mahmoudhosam@yahoo.com

**ISSN:** 2090-7265, May 2024, Vol.14, No. 2

## INTRODUCTION

Caesarean scar pregnancy (CSP) is a rare but serious complication of caesarean section<sup>[1]</sup>. The reported incidence of CSP ranges from 1:1,800 to 1:2,226, occurring in 0.15% of women with previous caesarean deliveries<sup>[2]</sup>. The incidence of CSP is increasing rapidly because of the increased rate of caesarean section<sup>[3]</sup>.

There are two types of CSP; endogenous where the gestational sac is implanted at the site of previous caesarean scar and develops towards the uterine cavity and

exogenous where the sac is implanted into the CS defect and grows towards the uterine serosa and urinary bladder<sup>[4]</sup>.

The exact pathogenesis is not clearly understood but the endometrial and myometrial disruption could be the predisposing factors in abnormal uterine implantation<sup>[5]</sup>.

Clinical presentations of CSP vary from vaginal bleeding, abdominal pain or even asymptomatic in cases which were diagnosed during the routine first trimester sonographic screening<sup>[6]</sup>.

This pregnancy can cause serious complications, such as placenta previa uterine rupture, haemorrhage, infertility or even death<sup>[7]</sup>.

The main lines of treatment are suction curettage, MTX injection either systemically or local injection, laparoscopy and laparotomy<sup>[8]</sup> but there is no consensus on the treatment and management, and individualized therapy should be performed<sup>[9]</sup>. Some complicated cases may require application of different methods of treatment<sup>[10]</sup>.

The aim of this study was to evaluate the effects of systemic methotrexate in caesarean scar pregnancy (CSP) in patients treated with ultrasound-guided manual vacuum aspiration (MVA).

## PATIENTS AND METHODS

---

This study is a prospective non randomized comparative study, it was totally conducted on fifty cases diagnosed with caesarean scar pregnancy in one year from August 2021 till August 2022 at Obstetrics and Gynecology department, Mansoura university hospitals (tertiary hospital), Mansoura University, Egypt. The patients included in this study were who met the following criteria: (1) they were diagnosed with undisturbed caesarean scar pregnancy. (2) The residual myometrial thickness was more than 3mm (endogenic type) and (3) No contraindication for systemic MTX. Excluded from the study cases with residual myometrial thickness less than 3mm or cases with disturbed caesarean scar ectopic.

A full detailed history of each patient was taken with explanation of the study protocol, the expected complications of the management procedures were explained to the patients then informed consent was obtained.

Transabdominal ultrasound (TAS) and transvaginal ultrasound (TVS) were carried out by Samsung HS60 ultrasound machine. Diagnosis of CSP was based on the following TVS criteria<sup>[11]</sup>:

1. An empty uterine cavity with a clearly demonstrated endometrium and empty cervical canal.
2. The presence of a gestational sac, with or without fetal cardiac activity, embedded and surrounded by the myometrium, in the anterior part of the uterine isthmus.

3. A thin myometrial layer between the gestational sac and the bladder.
4. peritrophoblastic flow surrounding the CSP appearing on Doppler flow sonography.
5. Negative “sliding sign” (inability to displace the gestational sac from its position using gentle pressure with a transvaginal probe).

Twenty four cases therefore were excluded as they didn't meet the inclusion criteria, the other 26 cases were divided into two groups, (group 1) included 16 cases who underwent suction using MVA and (group 2) included 10 cases who received intramuscular (MTX) injection (dose of 50 mg/m<sup>2</sup>) followed by MVA. MVA was done under general anaesthesia using cannula 7 mm. Curettage was done under ultrasound guidance till the sac completely disappeared. Intramuscular (MTX) injection (dose of 50 mg/m<sup>2</sup>) was followed by MVA within one week. Foley's catheter insertion for compression at site of ectopic pregnancy to ensure haemostasis was done when needed. The clinical characteristics and the outcomes were analysed.

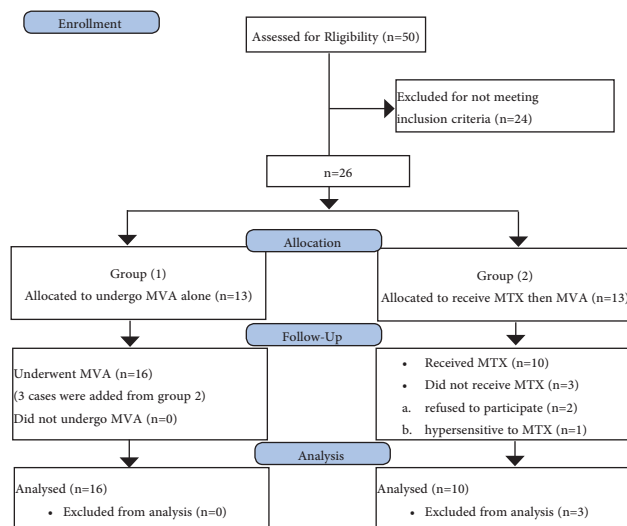
## Statistical analysis

Data analysis was performed by SPSS software, version 18 (SPSS Inc., PASW statistics for windows version 18. Chicago: SPSS Inc.). Qualitative data were described using number and percent. Quantitative data were described using median (minimum and maximum) for non-normally distributed data and mean± Standard deviation for normally distributed data after testing normality using Kolmogorov-Smirnov test. Significance of the obtained results was judged at the (0.05) level.

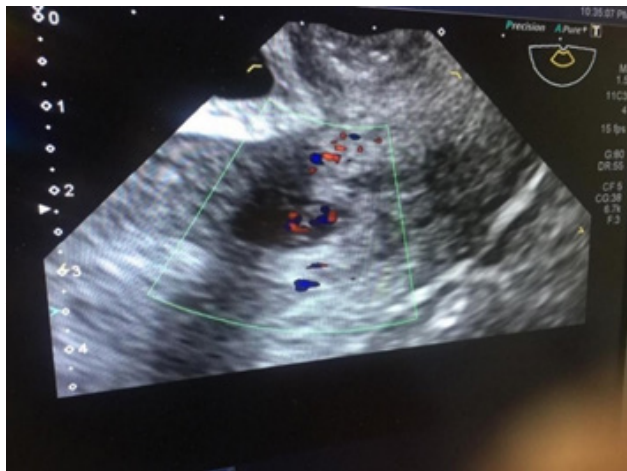
## RESULTS

---

The clinical characteristics of both groups were summarized in (Table 1) the two groups were similar in age, gravidity, parity, positive fetal heart beat, gestational age at diagnosis, thickness of anterior lower uterine wall on US, type of CSP, initial human chorionic gonadotropin (HCG) levels and number of previous caesarean sections. The table shows no statistically significant difference between the two groups as regards success rate and demographic and clinical characteristics except time since last CS, which was higher in group 2 (Figures 1,2)



**Fig. 1:** Consort flow diagram showing the algorithm for enrollment and allocation of subjects.



**Fig. 2:** Imaging of CSP: TVS of 7 weeks CSP

**Table 1:** Clinical characteristics of the two groups

Parameters	MVA alone (N=16)	MTX then MVA (N=10)	<i>p</i> Value
Maternal age (years)	30.375±3.20	34±6.39	0.065
Gravidity	4.75±1.65	5.5±2.8	0.396
Parity	2.625±0.81	3.6±2.01	0.094
Number of previous CS	2.31±0.79	3.4±2.07	0.067
Time since last CS (years)	4.41±2.64	7.4±3.54	0.02*
Gestational age (weeks)	7.44±1.37	7±0.94	0.382
Positive cardiac activity (%)	12.5	20	0.606
Residual myometrial thickness (mm)	5.875±1.5	4.7±1.49	0.063
Endogenic Type (%)	93.75	90	1.0
Basal β-HCG (mIU/mL)	21246.31±26202.73	17382.4±19408.76	0.692

The clinical presentation of both groups was presented in (Table 2). In (group 1), 68.75% of the cases presented with vaginal spotting, 12.5% presented with pain and 18.75% were asymptomatic, while in (group 2) 60% of the cases presented with vaginal spotting and 40% of the cases were asymptomatic.

**Table 2:** Clinical presentations of the two groups

Presentation	Treatment		Test of significance
	MVA alone N=16	MVA preceded by MTX N=10	
Asymptomatic	3 (18.75)	4 (40)	MC=25.02 P=0.07
Rupture uterus	0 (0)	0 (0)	
Pain	2 (12.5)	0 (0)	
Bleeding	11 (68.75)	6 (60)	

The outcomes of treatment were shown in (Table 3). Among (group 1, MVA alone), two cases were complicated with hematoma which resolved spontaneously and one case was complicated with severe bleeding and needed urgent laparotomy and hysterectomy. While in (group 2), all of them were successfully treated without any detected complications or need for additional treatment.

**Table 3:** Outcomes of the two groups

Parameters	MVA alone (N=16)	MTX then MVA (N=10)	<i>p Value</i>
Severe bleeding & urgent laparotomy (hysterectomy) NO & (%)	(1) 6.25	0	1.0
Scar hematoma (%)	(2) 12.5	0	0.507
Success rate (%)	81.25	100	0.262

## DISCUSSION

There is no universal management option for CSP<sup>[12]</sup>. It appears that combining different treatment modalities is more beneficial than single therapy<sup>[8]</sup>.

In this study we tried to compare the effect of adding systemic MTX to MVA versus MVA alone for managing CSP. Our findings show that hematoma formation at the site of CSP and severe vaginal bleeding that required hysterectomy were observed in patients treated with MVA alone. Although the difference is not statistically significant, but this may be attributed to the small sample size. It seems that this combined therapy is clinically effective.

The results of our study agree with Özdamar and his associates in a study carried out on 33 cases of CSP that were managed through suction curettage either alone or in combination with systemic or intracavitary administration of methotrexate, the success rate was nearly the same, Fourteen out of 16 cases who were treated with suction curettage alone, and 15 out of 17 patients who received MTX prior to suction curettage revealed successful resolution of the CSP without any complication<sup>[13]</sup>.

The clinical results and safety of suction curettage with or without MTX administration before curettage for treatment of CSP were studied by Sevket and associates<sup>[14]</sup>. The estimated blood loss and major complication rate were similar. They found that 'suction curettage only' group required less treatment time and came to the conclusion that suction curettage is an effective treatment for CSP. The same result was confirmed by Wang and associates<sup>(10)</sup>.

In our study no further therapy was required in MTX-MVA group. This may be related to the effect MTX that

reduce size of the mass and decrease vascularity. This finding is consistent with Shao and associates<sup>[15]</sup>. Datta reported that suction evacuation together with MTX was a successful option with good maternal outcome<sup>[16]</sup>.

The shortcomings of this study include the small number of patients and lack of long term follow up. There are still unanswered concerns about the future fertility, the risk of uterine rupture and recurrence at the location of the scar in subsequent pregnancies. Further randomized controlled trials with longer follow-up duration are required.

Based on this study, both treatment modalities, either MVA alone or MVA preceded by systemic MTX could treat effectively the majority of CSP patients, but the combined therapy resulted in less hematoma formation, haemorrhage and conversion to hysterectomy.

## Ethical approval

The study was approved by the Mansoura Faculty of Medicine Institutional Research Board (MFM-IRB).

## CONFLICT OF INTERESTS

There are no conflicts of interest.

## REFERENCES

- Li H, Liu X, Xie L, *et al.* Diagnostic accuracy and cut-off of contrast-enhanced ultrasound in caesarean scar pregnancy. *Eur J Obstet Gynecol Reprod Biol.* 2020 Mar; 246:117-122..
- Harb HM, Knight M, Bottomley C, *et al.* Caesarean scar pregnancy in the UK: a national cohort study. *BJOG.* 2018 Dec; 125(13):1663-1670
- Tanaka K, Coghill E, Ballard E *et al.* Management of caesarean scar pregnancy with high dose intravenous methotrexate infusion therapy: 10-year experience at a single tertiary centre. *Eur J Obstet Gynecol Reprod Biol.* 2019;237: 28-32.
- Vial Y, Petignat P, Hohlfield P. Pregnancy in a cesarean scar. *Ultrasound Obstet Gynecol.* 2000 Nov;16(6):592-593
- Najam S, Malik SE, Aqeel S *et al.* Viable Caesarean Scar Pregnancy: A Case Report. *Biomedica.* 2020 Mar; 36 (1):10-14.
- Luo L, Ruan X, Li C, *et al.* Early clinical features and risk factors for cesarean scar pregnancy: a retrospective case-control study. *Gynecol Endocrinol.* 2019 Apr; 35(4):337-341.
- Ou J, Peng P, Li C, *et al.* Assessment of the necessity of uterine artery embolization during suction and

- 
- curettage for caesarean scar pregnancy: a prospective cohort study. *BMC Pregnancy Childbirth*. 2020 Jun 29; 20(1):378.
8. Petersen K, Hoffmann E, Rifbjerg Larsen C, *et al.* Cesarean scar pregnancy: a systematic review of treatment studies. *Fertil Steril*. 2016 Apr;105(4):958-967.
  9. Gulino FA, Pappalardo E, Ettore C *et al.* . Cesarean scar pregnancy: descriptive paper of three different types of management on a series of clinical cases. *Prz Menopauzalny*. 2020 Jul; 19(2):61-65.
  10. Wang S, Beejadhursing R, Ma X, *et al.* . Management of Cesarean scar pregnancy with or without methotrexate before curettage: human chorionic gonadotropin trends and patient outcomes. *BMC Pregnancy Childbirth*. 2018 Jul 4; 18(1):289.
  11. Jayaram PM, Okunoye GO, Konje J. Cesarean scar ectopic pregnancy: diagnostic challenges and management options. *Obstet Gynaecol*. 2017; 19(1):13–20.
  12. Hanacek J, Herman H, krepelka P *et al.* Cesarean scar pregnancy. *Ceska Gynekol*.2022; 87(3):193-197
  13. Özdamar Ö, Doğer E, Arlier S, *et al.* . Exogenous cesarean scar pregnancies managed by suction curettage alone or in combination with other therapeutic procedures: A series of 33 cases and analysis of complication profile. *J Obstet Gynaecol Res*. 2016 Aug; 42(8):927-935.
  14. Sevket O, Keskin S, Ates S, *et al.* . Is methotrexate administration needed for the treatment of caesarean section scar pregnancy in addition to suction curettage? *Eur J Contracept Reprod Health Care*. 2014 Apr;19(2):128-133.
  15. Shao MJ, Hu MX, Xu XJ, *et al.* . Management of caesarean scar pregnancies using an intrauterine or abdominal approach based on the myometrial thickness between the gestational mass and the bladder wall. *Gynecol Obstet Invest*. 2013;76(3):151-157.
  16. Datta S and Jha C. Suction evacuation with methotrexate as a successful treatment modality for caesarean scar pregnancies : case series. *Soultan Qaboos Univ Med J*.2015 Nov; 15(4):e539-545.
-