

Effect of vitamin d deficiency on hypertrophic scarring: A meta-analysis

Samira A. Ahmed^{1*}

¹Department of Dermatology, Faculty of medicine, Fayoum University, Fayoum, Egypt

*Correspondence: Samira A. Ahmed, dr.samiraabdelkawey@gmail.com; Tel.:(002) 01062432934.

Received: 3 December, 2023

Accepted: 31 January, 2024

Reviewed: 11 January, 2024

Published online: 21 May 2024

Abstract:

Vitamin D is a fat-soluble vitamin, vital for different systems of the human body including endocrine and immune systems, endothelial function and wound healing. This meta-analysis follows the PRISMA flow diagram. The study assesses the relationship between vitamin D deficiency and hypertrophic scar incidence and determined vitamin D replacement therapy's effect on hypertrophic scar width and scale in patients who have a deficiency in vitamin D. After the search and screening, one study was eligible for our meta-analysis. Results of the meta-analysis show that scar improvement occurred significantly with p -value < 0.05 after vitamin D replacement in the group (1) and the low level of Vancouver score represented this but scar width did not change after treatment in both study groups. Our study may provide evidence that Vitamin D supplement may be used as an adjuvant treatment for hypertrophic scars as it reduces vascularity, pliability, pigmentation, and height of scars with little effect on scar width.

Keywords: Vitamin D; hypertrophic scarring; Meta-analysis.

1. Introduction

Surgeons all over the world aim to have unapparent scar tissue after any surgical procedure. Scar tissue could be in atrophic, hypertrophic or keloid forms [1]. Hypertrophic scarring (HTS) represents a major clinical problem [2]. Genetics, skin types, structural causes surgery causes and scar sites are supposed to play a role in hypertrophic scarring [3].

Less traumatic ways during surgery, no presence of the foreign body and infected hematoma in the wound and primary closure of the wound have a great incidence in reducing scars. After surgery, we should perform wound care, remove suture materials at a reasonable time and avoid sunlight exposure. Genetic properties of the patient, besides these factors, are important factors determining scarring. The

incidence of hypertrophic scarring in Asians and Africans is higher than in other races [4].

Vitamin D, a group of steroids, is a fat-soluble vitamin and it is endogenously synthesized. It has an effect on the mineralization of bone and calcium-phosphorus metabolism and also anti-

inflammatory and immunomodulatory effects. A vitamin D deficiency is considered when serum vitamin D level becomes below 25 ng/ml. It is associated with cardiovascular diseases, metabolic syndrome, common cancers, autoimmune and infectious diseases [5].

2. Subjects and methods

This meta-analysis follows the PRISMA flow diagram and guidelines of Cochrane Handbook.

Inclusion criteria

- Age: 10–50 years.
- Sex: Both male and female.
- Patients with HTS -lasting for at least one year.
- Patients should have vitamin D < 25 ng/ml.

Exclusion criteria

- Patients with collagen tissue disease.
- Patients with DM.
- Patients with neurological and psychiatric disease.
- Patients with history of using cigarette, alcohol or drugs.
- Children and pregnant women.

2.1. Information Sources

Scopus, PubMed, Web of Science, and Cochrane CENTRAL databases were searched until April 2021 for related records. The strategy includes the following 4 articles: effect of vitamin D deficiency in hypertrophic scarring, role of vitamin D and cytokines in vitiligo, vitamin D signaling in psoriasis; and vitamin D levels in acne vulgaris patients.

2.2. Search and Study Selection

Interventional and observational studies included peoples with acne and stress disorders. The included articles were screened in three steps. first one imported the results from electronic databases to a Microsoft Excel 7 sheet by using EndNote Software 8. The second one was made by two independent authors, including a title

and abstract screening of the articles, which were imported into Excel. The third one was full-text screening of the citations from step two. Manually, we searched references of the papers for missed studies.

2.3. Data Collection

Data were collected regarding: A) the baseline demographics of included participants. B) Outcome endpoints, which included BDNF in serum C) The 3rd category included risk of bias assessment data. Microsoft Excel was used for data collection.

2.4. Risk of bias Assessment

Two authors assessed the risk of bias between studies by using Cochrane's risk of bias tool for clinical trials. It assesses proper randomization, allocation concealment, and adequate blinding through 7 domains. Each one is put to "high", "unclear", or "low" risk of bias.

3. Results

A Systematic review of 4 articles found that vitamin D is implicated in hypertrophic scarring (**Figure 1**). This

2.5. Main outcomes and measures

All outcomes were formulated prior to data collection; outcome included a decreased level of vitamin D in hypertrophic scarring and a decreased serum level of vitamin D in patients with different dermatological diseases such as vitiligo, acne and psoriasis.

2.6. Analysis

Meta-analysis was performed using Review Manager software, and our study contained continuous and dichotomous outcomes. Continuous data by means of mean difference (MD) and 95% confidence interval (CI) were analyzed, while dichotomous data was done by using risk ratio (RR) and 95% CI. All the data showed the mean and standard deviation from different independent experiments. The comparisons between two groups were done by the student t-test method and we used a one-way analysis of variance (ANOVA) to compare the difference between at least three groups A *p-value* of < 0.05 is statistically significant.

meta-analysis showed that vitamin D significantly decreased in patients with a hypertrophic scar.

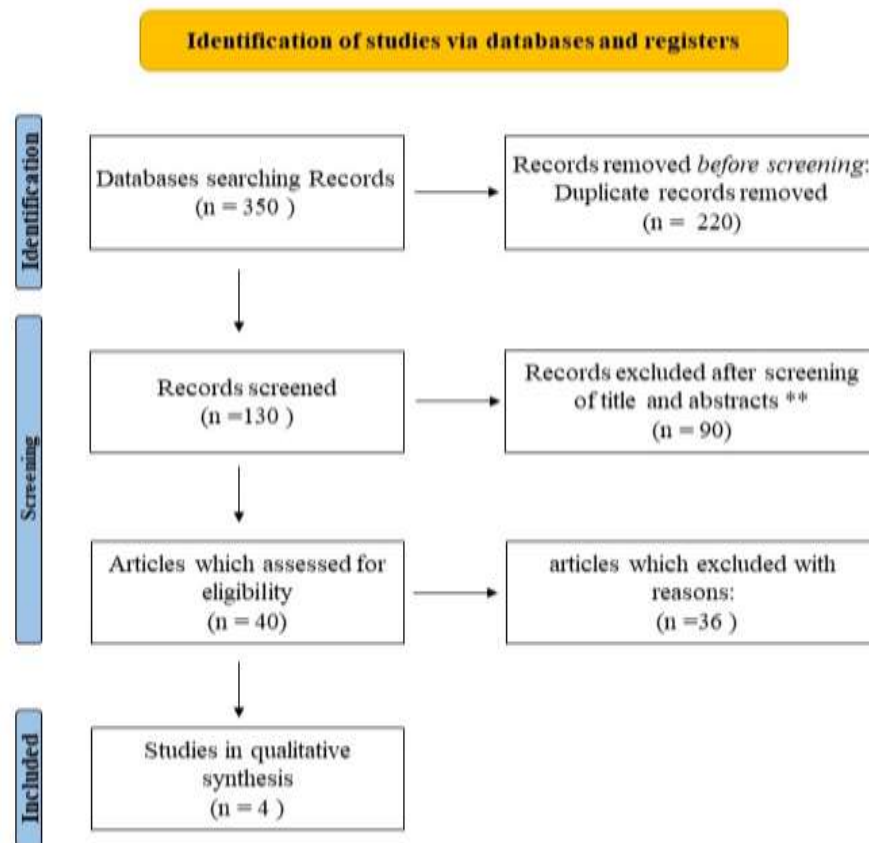


Figure 1: PRISMA Flow diagram of literature search process.

In psoriasis, deficiency of vitamin D is an environmental factor which is involved as an immune-mediated disorder and it is confirmed that vitamin D deficiency may be found in psoriatic patients and associated with its severity.

Many studies reported lower vitamin D serum levels in vitiligo rather than in normal populations as low vitamin D concentration has a vital role in the development of vitiligo by affecting Th1- and Th17-related immune responses.

25 OH vitamin D serum levels were higher in patients with acne vulgaris than healthy ones ($P = .001$). So, vitamin D can play a considerable role in acne vulgaris development or acne vulgaris can have a -ve effect on the synthesis of vitamin D (**Tables 1-3**). Results of meta-analysis shows that vitamin D level significantly decreased in patients with hypertrophic scarring (**Table 4, 5**).

Table 1: Comparisons of demographic characters in different study groups.

Variable	Vitamin D G1 (n=15)	Placebo G2 (n=15)	P-value
Age (years)	24±7.5	27.8±12	0.3
Sex	Male	7 (46.7%)	0.5
	Female	8 (53.3%)	
Residence	Urban	9 (60%)	0.99
	Rural	6 (40%)	

Data were expressed as Mean ± SD.

Table 2: Comparisons of vitamin D level & Vancouver score and scar width before treatment in different study group.

Variable	Vitamin D G1 (n=15)	Placebo G2 (n=15)	P-value
Vitamin D	20.3±4.2	18.3±5.9	0.3
Vancouver score	6.9±2.6	6.3±2.4	0.5
Scar width (mm)	4.4±3.2	5.3±3	0.4

Data were expressed as Mean ± SD.

Table 3: Comparison of vitamin D level, Vancouver score and scar width before and after treatment among group 1.

Variable	Vitamin D G1 (n=15)	Placebo G2 (n=15)	P-value
Vitamin D	20.3±4.2	27.6±1.9	<0.001*
Vancouver score	6.9±2.6	0.87±0.9	<0.001*
Scar width (mm)	4.4±3.2	3.7±2.9	0.1

Data were expressed as Mean ± SD. *Significant.

Table 4: Oral vitamin D2 treatment effectiveness taken in patients with psoriasis.

Study	Dose	Period of Administration	Efficacy Observed	Type/Severity of Psoriasis	Effectiveness	Treatment Side Effects
Disphanurat et al., 2019	20,000 IU/ two weeks	six months	Three to six months	Chronic plaque-type psoriasis—mild psoriasis	PASI score decreased at 3-6 months, moderate improvement	No

Table 5: Severities of acne vulgaris assessed by GAGS and their relation with vitamin D serum levels (ng/mL) before treatment.

	Number	Vitamin D (Mean \pm SD) (ng/mL)	Min	Max	ANOVA <i>P-value</i>
Moderate	66	18.54 \pm 8.30	6.0	35.7	
Severe	18	14.56 \pm 3.98	10.5	20.1	0.001*
Very severe	6	11.32 \pm 6.45	8.6	14.1	

*Significant.

Table 6: Comparison among healthy control subjects and patients with acne vulgaris at baseline as regard of age, sex, BMI, and vitamin D (ng/mL).

Parameter	Mean \pm SD		<i>P-value</i>
	Patients = 90	Controls = 60	
Age (year)	20.73 \pm 3.32	23.80 \pm 7.37	0.231
	Sex		
Male	42 (46.7%)	27 (45%)	0.496
Female	48 (53.3%)	33 (55%)	
BMI	23.26 \pm 4.18	22.22 \pm 5.39	0.893
Vitamin D (ng/mL)	17.34 \pm 7.58	44.83 \pm 11.91	0.001*

4. Discussion

Every year, about 55 million people undergo elective operations, and 25 million are operated on and have surgical scars [4]. This condition may lead to aesthetic concerns, psychological stress, and deterioration of skin function [10].

Wound healing represents a complex process that progresses in perfect balance. The maturation phase comes after the inflammation and proliferation phases and completed within a year, so we conducted our research on cases who had HTS for more than 1 year [11].

Hypertrophic scars happen through fibrous tissue proliferation within the scar's limits. It becomes inactive within a matter of time. Whereas in keloid, there are fibroblast collagen fibrils and immature blood vessels with abnormal proliferation, which occurs in the dermis and extends beyond the original wound boundaries. The treatment of HTS and keloids is complex. No fixed modality is curable, despite the many treatment facilities that have been proposed. Hypertrophic scars are still an important case of study for an optimum treatment [12].

Vitamin D is a vitamin that may be synthesized endogenously or ingested in

the diet. It has many vital functions, like plasma calcium level regulation, bone resorption increase, parathormone synthesis and release reduction, insulin production, renin synthesis reduction, and myocardial contractility enhancement. It can play an essential role in the activation of T- and B-lymphocytes and its immunomodulatory effect. Also, it represents anti-inflammatory activity through decrease the conversion of macrophages to foam cells [13].

Vitamin D deficiency, which is caused mainly by limited access to sunlight, is associated with non-communicable and infectious diseases. HTS formation is precipitated by fibroblasts, keratinocytes, mast cells, and other cells and also expresses the vitamin D receptor. Vitamin D affects skin proliferation and differentiation either directly or through its interaction with calcium. At a low concentration (10⁻⁹ mM or less), 1.25 (OH)₂ D₃ was found to enhance keratinocyte proliferation [14].

Our study comes in agreement with this hypothesis, as 63.3 percent of our cases were females in their child bearing period. The prolactin hormone affect wound healing also through influencing

angiogenesis and immunomodulation and VEGF synthesis may be increased by adding prolactin to monocyte/macrophage cell cultures. In pregnancy, there is hormonal fluctuations especially in prolactin so in our study pregnant patients were excluded [15].

According to our study sample, the etiology of HTS was surgical in 53.3% (16 patients) and traumatic in 46.6% (14 patients), which goes with Kant et al findings as they mentioned that scars occurred on surgical incisions (70.9%) while wounds because of trauma were (burns, 14.7%; others, 14.4%), so surgical cause was the most common etiology of HTS [16].

According to the site of HTS, our study showed that the trunk and extremities were the commensal sites with (46.6%) and (50%) incidence rates, respectively, while the face was (3.3%) with less incidence, which agrees with Wei et al.'s findings as they also found that the trunk and extremities were the commensal sites with incidence rate (89%) among their study group [17]. This may be due to poor wound healing, as parasternal and ridge areas have increased tension, which lead to the development of HTS and keloids [11].

Also, skin type is an important factor which plays a significant role in formation of HTS. By Fitzpatrick classification, healing by HTS in individuals with type III, IV, V and VI is more than in ones with types I and II which goes with our study findings as (26.6%) were skin types II and (70%) were skin type III [18].

Terzi and Güven found a correlation in their study between vitamin D levels and scar formation. The levels of vitamin D decreased in patients with higher scores on the VSS, that indicates severe scar, which matches with our results, where there was a strong correlation between a deficiency of vitamin D (post-traumatic and post-surgical intervention) and hypertrophic scar formation [19].

Our study showed that the increase of vitamin D was associated with a significant decrease in Vancouver score (p-value < 0.001) in patients who received oral vitamin D (2000 U) daily for 1 month, as 100 % of our study groups had vitamin D deficiency and HTS at the time of assessment within 1 year of the HTS, which proved scar improvement after correction of vitamin D deficiency. Consistent with our findings, the Mamdouh et al study

claimed that there was a significant decrease in VSS parameters (vascularity, pigmentation, pliability, and height of scars) after treatment with intralesional vitamin D injection. There was a significant decrease in scar thickness by sonography [20].

Conclusion

This study revealed a decrease in serum level of vitamin D in patients with hypertrophic scar. A decrease of vitamin D level in relation to acne vulgaris and in vitiligo patients were significant in psoriatic patients as compared to control.

Funding: This study is not funded.

References

1. Tziotziou C, Profyris C, Sterling J. Cutaneous scarring: Pathophysiology, molecular mechanisms, and scar reduction therapeutics Part II. Strategies to reduce scar formation after dermatologic procedures. *J Am Acad Dermatol.* 2012;66(1):13-24; quiz 25-6. doi: 10.1016/j.jaad.2011.08.035.
2. Aarabi S, Longaker MT, Gurtner GC. Hypertrophic scar formation following burns and trauma: new approaches to treatment. *PLoS Med.* 2007;4(9):e234. doi: 10.1371/journal.pmed.0040234.
3. Ince B, Dadaci M, Oltulu P, Altuntas Z, Bilgen F. Effect of Dermal Thickness on Scars in Women with Type III-IV Fitzpatrick Skin. *Aesthetic Plast Surg.* 2015;39(3):318-24. doi: 10.1007/s00266-015-0466-z.
4. Gauglitz GG, Korting HC, Pavicic T, Ruzicka T, Jeschke MG. Hypertrophic scarring and keloids: pathomechanisms and current and emerging treatment strategies. *Mol Med.* 2011;17(1-2):113-25. doi: 10.2119/molmed.2009.00153.
5. İnce B. Vitamin D and systemic effects of Vitamin D deficiency. *Selcuk Med J* 2018;34(2): 84-89 DOI: 10.30733/std.2018.01052
6. Barendregt J, Doi S. *MetaXL User Guide: Version 1.0.* Wilston, QLD EpiGear International Pty Ltd. 2009.
7. Borenstein M, Hedges L, Higgins JPT, Rothstein HR. *Comprehensive meta-analysis (Version 2.2.027) [Computer software].* Englewood, CO. 2005.

In a total 4 articles searching the role of vitamin D in hypertrophic scarring and different dermatological diseases, all studies found a potent association with acne vulgaris, vitiligo and psoriasis.

This study has many limitations, including that it is a case-control studies, so they may be liable to associated with retrospective nature and don't demonstrate the causation.

Conflicts of Interest: All authors declare they have no conflicts of interest.

8. Higgins JP, Thompson SG. Quantifying heterogeneity in a meta-analysis. *Stat Med.* 2002;21(11):1539-58. doi: 10.1002/sim.1186.
9. McHugh ML. The Chi-square test of independence. *Biochem. Med* 2013; 23:143–149.
10. Huang C, Akaishi S, Ogawa R. Mechanosignaling pathways in cutaneous scarring. *Arch Dermatol Res.* 2012;304(8):589-97. doi: 10.1007/s00403-012-1278-5.
11. Ince B, Uyar I, Dadaci M. Effect of Vitamin D Deficiency on Hypertrophic Scarring. *Dermatol Surg.* 2019;45(2):274-279. doi: 10.1097/DSS.0000000000001680.
12. Nainpuriya Y, Mewara BC. Trends in keloids an hypertrophic scars. *Int J Surg Sci* 2021;5(2):261-265. DOI: 10.33545/surgery.2021.v5.i2e.704
13. Parva NR, Tadepalli S, Singh P, Qian A, Joshi R, Kandala H, Nookala VK, Cheriya P. Prevalence of Vitamin D Deficiency and Associated Risk Factors in the US Population (2011-2012). *Cureus.* 2018;10(6):e2741. doi: 10.7759/cureus.2741.
14. Piotrowska A, Wierzbicka J, Żmijewski MA. Vitamin D in the skin physiology and pathology. *Acta Biochim Pol.* 2016;63(1):17-29. doi: 10.18388/abp.2015_1104.
15. Foitzik K, Langan EA, Paus R. Prolactin and the skin: a dermatological perspective on an ancient pleiotropic peptide hormone. *J Invest Dermatol.* 2009;129(5):1071-87. doi: 10.1038/jid.2008.348.
16. Kant S, van den Kerckhove E, Colla C, van der Hulst R, Piatkowski de Grzymala A. Duration of Scar Maturation: Retrospective Analyses of 361 Hypertrophic Scars Over 5 Years. *Adv Skin Wound Care.* 2019;32(1):26-34. doi: 10.1097/01.ASW.0000547415.38888.c4.
17. Ruan Z, Sun C, Lang Y, Gao F, Guo R, Xu Q, Yu L, Wu S, Lei T, Liu Y, Zhang M, Li H, Tang Y, Gao T, Gao Y, Lu X, Li Z, Chang T. Development and Validation of a Nomogram for Predicting Generalization in Patients With Ocular Myasthenia Gravis. *Front Immunol.* 2022;13:895007. doi: 10.3389/fimmu.2022.895007.
18. Sachdeva S. Fitzpatrick skin typing: applications in dermatology. *Indian J Dermatol Venereol Leprol.* 2009;75(1):93-6. doi: 10.4103/0378-6323.45238.
19. Terzi R, Güven M. Bone Mineral Density After Burn Injury and Its Relation to the Characteristics of Scar Tissue. *J Burn Care Res.* 2016;37(3):e263-7. doi: 10.1097/BCR.0000000000000241.
20. Mamdouh M, Omar GA, Hafiz HSA, Ali SM. Role of vitamin D in treatment of keloid. *J Cosmet Dermatol.* 2022;21(1):331-336. doi: 10.1111/jocd.14070.