



Prevalence and Distribution of *Cysticercus tenuicollis* (*Taenia hydatigena*) Cysts from slaughtered Goats at Akinyele, Ibadan, Nigeria

Akinkunmi O. Idowu^{1,2}, Olamilekan G. Banwo^{1*} and Olalekan T. Jeremiah¹

¹Department of Veterinary Medicine, University of Ibadan, PO Box 200005, Nigeria

²College of Veterinary Medicine, Federal University of Agriculture, Abeokuta, Nigeria

*Corresponding Author: Olamilekan Gabriel Banwo, E-Mail: olamilekanbanwo@gmail.com

ABSTRACT

This study aimed to determine the prevalence of *Cysticercus tenuicollis* among 500 Red Sokoto goats slaughtered at the Akinyele abattoir in Ibadan between October and December. This period targeted the wet month, transition from rainy to dry season, and the dry month. Post-mortem examinations were conducted on goats for *C. tenuicollis*. Cysts that were recovered underwent identification based on their morphology, with both their number and location documented. The study found an overall prevalence rate of 38.2%. Among the 416 males and 84 females examined, 160 (38.5%) and 31 (36.9%), respectively, were found to be infected, with no significant differences observed between the sexes. Prevalence in October was 47.1% (106/225), November was 40.5% (75/185), and December was 11.1% (10/90), with higher rates in wet months transitioning to lower rates in dry months, with a significant association between prevalence and month. Among the 281 cysts identified, they were distributed across the liver (18, 6.4%), mesentery (98, 34.9%), and omentum (165, 58.7%). Notably, *C. tenuicollis* was most commonly found in the omentum, accounting for 58.7% of the cases. The distribution of cysts by location and the analysis of potential risk factors for sex and age showed a significant association with age but not with sex. Although more cysts were observed in males, the difference was not statistically significant. This study provides valuable baseline data on the prevalence of *C. tenuicollis* in goats during the study period. The high prevalence and distribution patterns identified can serve as crucial insights for designing effective control strategies, including targeted anthelmintic treatments and improving meat inspection protocols.

Keywords: Akinyele Central Abattoir, *Cysticercus tenuicollis*, Goats cysticercosis, Prevalence.

Original Article:

Received

Accepted

Published in

J. Appl. Vet. Sci., 9(3): Proof

INTRODUCTION

In Nigeria, the livestock sector plays a crucial role, contributing significantly to the overall agricultural income. Ruminants, such as sheep, goats and cattle constitute an important livestock group within Nigeria's farming systems supporting agricultural livelihoods and food production nationwide. According to **FAO (2022)**, Nigeria has a population of 60 million goats, 25 million sheep and 20 million cattle. However, the majority of these animals are concentrated in the northern region of the country compared to the southern region (**Devendra, 1999**).

Cysticercus tenuicollis is the larval stage (metacestode) of *Taenia hydatigena* (*T. hydatigena*). Adult worms of *T. hydatigena* have been reported to have been found in the small intestines of dogs, cats, mice, and wild carnivores, like the wolf and the fox, as the definitive hosts (**Jenkins et al., 2014**). The adult

worm of *T. hydatigena* lays eggs which pass out in the faeces of the host and are ingested by a wide range of herbivorous animals (intermediate hosts) during grazing. After ingestion, the egg's shell is digested and the oncospheres are liberated and migrate through the intestinal walls, reaching the liver through the hepatic portal system. The oncospheres may remain in the liver or migrate to the omentum, mesenteries, or peritoneal cavity (**Payan-Carreira et al., 2008**).

C. tenuicollis have serious impacts on their intermediate hosts. The migration of these cysticerci in the liver may cause hepatitis cysticercosa leading to haemorrhagic and fibrotic tracts and serofibrinous peritonitis. In very heavy infections, the migrating larvae destroy the hepatic cells causing eosinophilic infiltration and severe inflammation that may prove to be fatal (**Corda et al. 2020**). Additionally, these larvae may occupy space, displacing healthy omental tissue and disrupting the network of blood vessels within the

omentum. This disruption can potentially affect blood flow to the omentum and nearby organs. This condition has the potential to induce inflammation and scar tissue formation (fibrosis) around the cysts, which can further compromise the functionality of affected organs (Scala *et al.*, 2016). In recent years, it has become increasingly clear that greater priority should be given to *C. tenuicollis* because of its economic impact due to the condemnation of offal containing these larvae, particularly in resource-poor countries.

The prevalence of *C. tenuicollis* found in goats reported by various authors, ranged from 4.8 to 65 %, globally (Singh *et al.*, 2015; Sissay *et al.*, 2008). Despite studies on the prevalence, morphology, and genetics of *C. tenuicollis* in other regions, there is limited research on this parasite in Ibadan. This study aimed to fill this gap by estimating the prevalence of *C. tenuicollis*, its distribution in organs and tissues, and the associated risk factors among Red Sokoto goats at the Akinyele abattoir in Ibadan, Oyo State, South West Nigeria. Therefore, this study contributes to a better understanding of the impacts and epidemiology of this parasite in the local context.

MATERIALS AND METHODS

1. Study area

This study was conducted at the Akinyele Municipal abattoir in Ibadan, Nigeria, targeting the late rainy season and early dry season transition. Using the Red Sokoto breeds of goats originating from smallholder farms around Ibadan and Iseyin; the Guinea savannah, Sahel, and sub-arid climatic zones of northern Nigeria; and border countries such as Niger, Chad, and Mali (Jeremiah and Banwo, 2019).

2. Study design and sample size

A cross-sectional study was conducted over three months to visually examine slaughtered goats for *C. tenuicollis*. The study aimed to determine the

prevalence of *C. tenuicollis* and its distribution in organs and tissues among slaughtered goats during the specified period and location. The study focused on 500 Red Sokoto breeds of goats, comprising 416 males and 84 females, the primary commercial breed slaughtered at the abattoir, necessitating the use of this breed for this study.

3. Collection of parasites

Several organs and tissues were examined, which included the heart, oesophagus, diaphragm, liver, kidneys, lungs, internal and external masseter muscle, peritoneal cavity, and skeletal muscles. Samples showing potential cysts upon preliminary visual inspection at the abattoir were collected and transported to the parasitology laboratory for confirmation of *C. tenuicollis*. Recovered cysts were identified based on morphological characteristics to determine the prevalence of *C. tenuicollis* among the goats slaughtered during the specified period and location. The age of slaughtered goats was determined using dentition as described by Greenfield and Arnold (2008) classifying them as young (0-18 months) or adult (18 months and older). Upon visual inspection of visceral organs, the number and location of any cysts were recorded. Individual cysts were transferred into sterile containers for further examination in the laboratory. *C. tenuicollis* were initially distinguished based on features such as possessing a long-necked single scolex and virtually translucent cyst fluid. This helped confirm identification and inform prevalence calculations.

4. Statistical analysis

The data were summarised in tables using descriptive statistics in frequency and percentage. A Chi-square (χ^2) test was used to test for an association between the prevalence and location of *C. tenuicollis* and the categorical variables, age, sex, and selected months. Confidence intervals (CI) of 95% were calculated (Banwo *et al.*, 2023).

RESULTS

Examination of the visceral organs of 500 Red Sokoto goats carcasses at the Akinyele Municipal abattoir, Ibadan, Oyo state South West Nigeria revealed that 191 (38.2%) of the examined goats were infected with *C. tenuicollis* upon visual inspection (Table 1).

Table 1: Prevalence of *C. tenuicollis*

C. tenuicollis cysts	No. of samples	Prevalence (%)	95% CI
Positive	191	38.2	35.0% - 42.1%
Negative	309	61.8	57.0% - 64.0%
Total	500	100	100% - 100%

Prevalence and Distribution of Cysticercus tenuicollis

Out of the 416 males and 84 females, 160 (38.5%) and 31 (36.9%) were infected, respectively. Among 337 adults and 163 young goats, 127 (37.7%) and 64 (39.3%) were infected, respectively. Statistical analysis using Chi-square test revealed no significant association between the prevalence of *C. tenuicollis* and the variables (sex and age; p-value (P) 0.857 and 0.821, respectively).

During the study period, the prevalence of *C. tenuicollis* in October was 47.1% (106/225), in November it was 40.5% (75/185), and in December it was 11.1% (10/90), depicting a wet month and a transition to a dry month, respectively. In terms of month prevalence, there was a significant association between the prevalence of *C. tenuicollis* and month prevalence, showing increased prevalence in wet months and a reduction as it transits to the dry period ($X^2=18.93$, $P<0.001$) (**Table 2**).

Table 2: Influence of sex, age, and selected months in Prevalence of *C. tenuicollis*

Variable	Number examined	Number infected	Prevalence (%)	X^2 value	df	P value
Sex						
Male	416	160	38.5	0.032	1	0.857
Female	84	31	36.9			
Age						
Young	163	64	39.3	0.052	1	0.821
Adult	337	127	37.7			
Months						
October (Wet)	225	106	47.1	18.93	2	<0.001*
November (Transition)	185	75	40.5			
December (Dry)	90	10	11.1			

* = Statistically significant ($p < 0.01$).

In this study, out of 191 infected goats, 281 cysts were found in total. The distribution of the location of the cyst in the hosts is as follows: liver (18, 6.4%) (**Fig. 1**); mesentery (98, 34.9%); and omentum (165, 58.7%) (**Fig. 2**). The mesentery and omentum are both folds of the peritoneum, a membrane lining the abdominal cavity in animals. However, they have distinct locations and functions. *C. tenuicollis* was found to be more abundant in the omentum, which was 165 (58.7%) than in other locations (**Table 3**). The number of cysts in each infected goat ranged from one to seven. Most of these cysts (**Fig. 3**) were transparent white, with a single scolex appearing as a white spot.

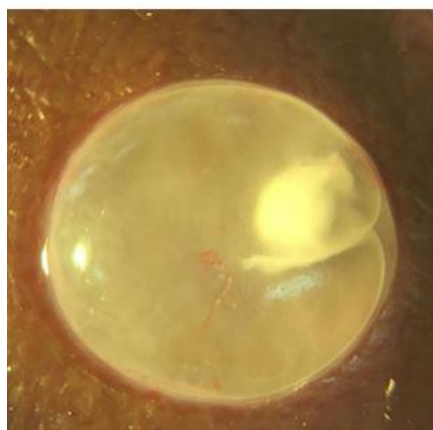


Fig.1: *C. tenuicollis* in liver of goat

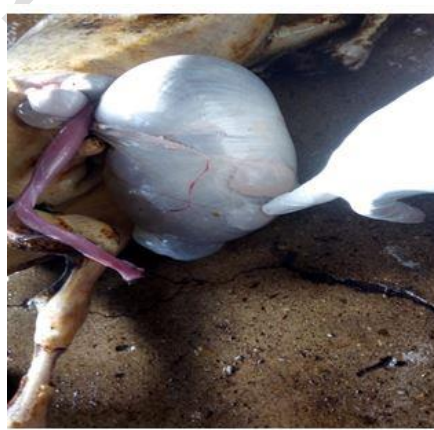

Fig. 2: *C. tenuicollis* in omentum of goat

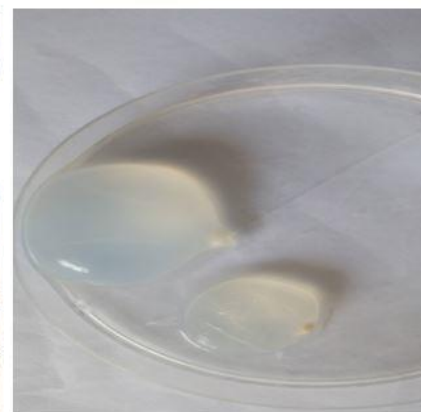


Fig. 3: Cyst in a petri dish; transparent white, with a single scolex appearing as a white spot

Table 3: Summary of *C. tenuicollis* by location

Location	Frequency	Proportion
Liver	18	6.4
Mesentery	98	34.9
Omentum	165	58.7

The distribution of cyst in terms of location and the risk factor, age shows a significant association ($X^2=31.81$, $P<0.001$) (Table 4). The distribution of cysts among sexes was not significant ($P=0.245$) but there were more cysts in the male carcasses than in the female.

Table 4: Association between cyst location and the risk factors sex and age in infected Goats:

Variable	Number examined	Number infected	Location			X ² value	df	P value
			Liver	Mesentery	Omentum			
Sex								
Male	416	160	10	61	89	2.816	2	0.245
Female	84	31	2	7	22			
Age								
Young	163	64	12	12	40	31.81	2	<0.001*
Adult	337	127	0	56	71			

DISCUSSION

Abattoirs can serve as a source of data for assessing the health of animal populations. Examining animals at the abattoir allows for insights into the prevalence and distribution of diseases affecting livestock populations (Banwo et al., 2023). *C. tenuicollis* is an intermediate stage of the tapeworm *Taenia hydatigena* that commonly infects livestock, including goats. It is an important cause of economic losses in goat farming worldwide due to the condemnation of infected organs at slaughter, reduced productivity, and the risk of transmission to humans (FAO, 1995). Adult *Taenia hydatigena* parasitises the small intestine of canids such as dogs and wolves. Eggs are shed in the faeces of infected dogs and ingested by grazing goats (Ng-Nguyen et al., 2021). The larval stages are found in the liver, spleen, and other organs of ruminants and rodents. The larval stages are highly pathogenic in the intermediate hosts causing harmful destruction, during their migration, in the tissues and organs (Nwosu et al., 1996).

In the present study, we reported an overall prevalence of 38.2%. This may be due to the practice of free-ranging grazing which increases contact with pastures and water contaminated by eggs from infected dog faeces, raising the risk of ingesting the eggs and developing cysticercosis. This might also be associated with limited deworming of definitive canid hosts which allow greater egg shedding. Environmental factors may also be favourable for the long-term survival of the eggs, while poor sanitation and drainage at farms and

slaughterhouses facilitate the spread of eggs and exposure of goats. Previous studies in Ibadan, Nigeria reveal prevalence rates of 21.4% in sheep and 33.3% in goats (Nwosu et al., 1996; Opara et al., 2006). The prevalence of *C. tenuicollis* in goats in this study was higher than those previously reported by (Nwosu et al., 1996), might be as a result of change in agricultural practice and poor pasture management. Also, the potential increase in population of the definitive host can increase the dispersal of eggs in the environment.

Several international studies have also examined *C. tenuicollis* prevalence in goats. In Nigeria, a prevalence of 34.2% has been reported (Dada and Belino, 1978). Tunisian and Ethiopian studies found 8.9% and 20.3% prevalence among goats, respectively (Khaled et al., 2020; Ahmed et al., 2024). In India, one study estimated 4.8% prevalence in goats (Singh et al., 2015). Collectively, these demonstrate *C. tenuicollis* commonly infects goat populations across diverse countries and regions worldwide.

The prevalent distribution among the two sexes reveals that prevalence is higher in males than in females but non-significant. Previous studies have reported varying findings on the relationship between cyst prevalence and host sex. Some researchers found prevalence was higher in males compared to females (Oryan et al., 2012; Mekuria et al., 2013). The current study helps add to our understanding of how this relationship may differ across populations and geographical locations.

This study reports no statistically significant association between age and prevalence of *C. tenuicollis*, although infection occurred more in adults than young goats, young goats had a higher proportional prevalence. This is in agreement with other studies that reported no association between age and prevalence (Mekuria *et al.*, 2013; Adamu *et al.*, 2010). This lack of significance may be because the adult animals lived longer and had greater cumulative exposure to parasite eggs during grazing compared to younger animals. Additionally, more adult than young goats were sampled in this study. Managemental practice could also influence exposure, as younger animals may be kept separately from adults or receive more controlled feeding in some systems, potentially limiting their contact with contaminated environments relative to free-ranging adult goats. Thus, while adults exhibited numerically higher prevalence, differences in management and exposure patterns over time could confound the relationship between age and observed *C. tenuicollis* infection.

In the present study, there was a significant association between the month prevalence and *C. tenuicollis* prevalence. The significantly higher prevalence of *C. tenuicollis* in the wet month, October (47.1%) as compared to the dry month, December (11.1%) could relate to environmental factors like increased egg viability, pasture contamination, and survival being favoured under wet, humid conditions. This is in agreement with the report of (Singh *et al.*, 2015). This study highlights a distinct trend where the prevalence of *C. tenuicollis* was markedly higher during the wet month, October (47.1%), and further establishes a clear link between environmental conditions and parasite prevalence, enhancing the understanding of the dynamics of *C. tenuicollis* infections in goats.

This study confirms the liver, mesentery, and omentum as key sites harbouring *C. tenuicollis*. A total of 281 cysts were recorded distributed in the liver (18, 6.4%), mesentery (98, 34.9%), and omentum (165, 58.7%). Assessment of the association between cyst location and potential risk factors of sex and age in infected goats showed a statistically significant association with age. The omentum had the highest occurrence of cysts relative to sex and age, while the liver contained the least. This agrees with previous works reporting the omentum as a major site for *C. tenuicollis* (Samuel and Zewde, 2010; Ahmed *et al.*, 2024). Liver cysts were solely observed in young animals, with none seen in adults. According to this study, age appears to influence cyst distribution patterns between locations. Specifically, younger goats exhibited liver cysts while adults did not. These findings suggest a clear link might exist between host age and the preferential establishment of cysts at specific

anatomical sites. Targeting high-risk locations in older animals could aid control efforts.

CONCLUSION

The result of this study shows that the overall prevalence of *C. tenuicollis* in the Red Sokoto goat recorded was 38.2%. and the cysts were found to be more in the omentum (58.7%), which was more than in other locations. To control infection levels, small ruminants should undergo targeted deworming every three months, with focused efforts before and after rainy periods when transmission risk is highest. Grazing practices should avoid areas contaminated by dog faeces, and ruminants should not be raised jointly with dogs on the same farm to limit environmental exposure. For the sake of the sake of public health, there should be adequate meat inspection coverage at abattoirs across Nigeria to prevent the spread of infected meat. The combined prevention efforts at the farm and slaughter level can collaboratively reduce the economic and health impacts of this parasitic infection.

Acknowledgements

The authors appreciate the technical assistance of the Staff of the State Veterinary Department and Department of Veterinary Medicine Laboratory, University of Ibadan, Nigeria.

Conflict of interest

The authors declare that there is no conflict of interest regarding the publication of this article.

REFERENCES

- ADAMU, S., OKAFOR, F.C., and OBOEGBULEM, S.I., 2010. Prevalence of cysticercosis in goats slaughtered in Zaria abattoir, Nigeria. *Nigerian Veterinary Journal*, 31(1), 61–64.
- AHMED, M. A., HAJI, A. A., HUSSEN, A. H., and MAHAMED, S. A., 2024. Prevalence, Cysts Distributions, Associated Risk Factors and Economic Importance of *Cysticercus Tenuicollis* in Small Ruminant Slaughtered at Jigjiga Municipal Abattoir, Somali Regional state, Ethiopia. *Asian Journal of Advanced Research and Reports*, 18(1), 92–101. <https://doi.org/10.9734/ajarr/2024/v18i1599>
- BANWO, O.G., OYEDOKUN, P.O., OLUMIDE O. AKINNIYI, O.O., and JEREMIAH, O.T., 2023. Bovine Fasciolosis in Slaughtered Cattle at Akinyele, Ibadan, Nigeria. *Journal of Applied Veterinary Sciences*, 8 (4): 104–110. <https://dx.doi.org/10.21608/javs.2023.228105.1261>
- CORDA, A., DESSI, G., VARCASIA, A., et al., (2020) Acute visceral cysticercosis caused by *Taenia hydatigena* in lambs: ultrasonographic findings. *Parasit Vectors* 13:1–7. <https://doi.org/10.1186/s13071-020-04439-x>

- DADA, B. J., and BELINO, E. D., 1978.** Prevalence of hydatidosis and cysticercosis in slaughtered livestock in Nigeria. *The Veterinary record*, 103(14), 311–312. <https://doi.org/10.1136/vr.103.14.311>
- DEVENDRA, C., 1999.** Goat challenges of increased productivity and improved livelihoods. *Outlook on Agriculture*, 28, 215-226. <https://doi.org/10.1177/003072709902800404>
- FOOD AND AGRICULTURE ORGANIZATION (FAO), 1995.** *Cysticercus tenuicollis*: An important cause of economic losses in goat farming worldwide. Rome, Italy: FAO.
- FOOD AND AGRICULTURE ORGANIZATION (FAO), 2022.** FAOSTAT Database. Retrieved from <http://www.fao.org/faostat/en/#data/QA>
- GREENFIELD, H. J., and ARNOLD, E. R., 2008.** Absolute age and tooth eruption and wear sequences in sheep and goat: Determining age-at-death in zooarchaeology using a modern control sample. *Journal of Archaeological Science*, 35(4), 836-849. <https://doi.org/10.1016/j.jas.2007.06.003>
- JENKINS, D. J., UWIN, N. A. R., WILLIAMS, T. M., MITCHELL, K. L., LIEVAART, J. J., and ARMUA-FERNANDEZ, M. T., 2014.** Red foxes (*Vulpes vulpes*) and wild dogs (dingoes (*Canis lupus dingo*) and dingo/domestic dog hybrids), as sylvatic hosts for Australian *Taenia hydatigena* and *Taenia ovis*. *International Journal for Parasitology: Parasites and Wildlife*, 3, 75–80. <https://doi.org/10.1016/j.ijppaw.2014.03.001>
- JEREMIAH, O. T., and BANWO, O.G., 2019.** Haematologic profile and prevalence survey of haemonchosis in various breeds of slaughtered cattle in Ibadan, Nigeria. *Nigerian Journal of Animal Production*, 46(3), 151-162. <https://doi.org/10.51791/njap.v46i3.954>
- KHALED, K., TEBER, G., BOUAICHA, F., AMAIRIA, S., REKIK, M., and GHARBI, M., 2020.** Infestation of small ruminants by the metacestode stage of *Taenia hydatigena* in slaughterhouse, North East Tunisia. *Veterinary medicine and science*, 6(2), 204–208. <https://doi.org/10.1002/vms3.222>
- MEKURIA, E., SHIMELIS, S., BEKELE, J., and SHEFERAW, D., (2013).** Sheep and goats *Cysticercus tenuicollis* prevalence and associated risk factors. https://www.academia.edu/32986071/Sheep_and_goats_Cysticercus_tenuicollis_prevalence_and_associated_risk_factors
- NG-NGUYEN, D., VAN NGUYEN, T., VAN NGUYEN, T. et al., 2021.** Prevalence and risk factors of *Taenia hydatigena* in dogs, pigs, and cattle in the Central Highlands of Vietnam. *Parasitol Res* 120, 3245–3253 (2021). <https://doi.org/10.1007/s00436-021-07276-8>
- NWOSU, C. O., OGUNRINDAE, F., and FAGBEMI, B. O., 1996.** Prevalence and seasonal changes in gastrointestinal helminthes of Nigerian goats. *Helminthologia*, 70, 329-330. <https://doi.org/10.1017/s0022149x00015625>
- OPARA, M. N., UKPONG, U. M., OKOLI, I. C., and ANOSIKE, J. C., 2006.** Cysticercosis of slaughter cattle in southeastern Nigeria. *Annals of the New York Academy of Sciences*, 1081(1), 339-346. <https://doi.org/10.1196/annals.1373.048>
- ORYAN, A., GOORGIPOUR, S., MOAZENI, M., and SHIRIAN, S., 2012.** Abattoir prevalence, organ distribution, public health and economic importance of major metacestodes in sheep, goats and cattle in Fars, southern Iran. *Tropical Biomedicine*, 29(3), 349-359.
- PAYAN-CARREIRA, R., SILVA, F., RODRIGUES, M., and DOS ANJOS PIRES, M., 2008.** *Cysticercus tenuicollis* vesicle in fetal structures: Report of a case. *Reproduction in Domestic Animals*, 43(6), 764-766. <https://doi.org/10.1111/j.1439-0531.2007.01014.x>
- SAMUEL, G., and ZEWEDE, G. G., 2010.** Prevalence, risk factors, and distribution of *C. tenuicollis* in visceral organs of slaughtered sheep and goats in Central Ethiopia. *Tropical Animal Health and Production*, 42(6), 1049-1051. <https://doi.org/10.1007/s11250-010-9537-y>
- SCALA, A., URRAI, G., VARCASIA, A., et al., 2016.** Acute visceral cysticercosis by *Taenia hydatigena* in lambs and treatment with praziquantel. *J Helminthol* 90:113–116. <https://doi.org/10.1017/S0022149X14000601>
- SINGH, B. B., SHARMA, R., GILL, J. P., and SHARMA, J. K., 2015.** Prevalence and morphological characterisation of *Cysticercus tenuicollis* (*Taenia hydatigena* cysts) in sheep and goat from north India. *Journal of parasitic diseases : official organ of the Indian Society for Parasitology*, 39(1), 80–84. <https://doi.org/10.1007/s12639-013-0284-7>
- SISSAY, M. M., UGGLA, A., and WALLER, P. J. (2008).** Prevalence and seasonal incidence of larval and adult cestode infections of sheep and goats in eastern Ethiopia. *Tropical animal health and production*, 40(6), 387–394. <https://doi.org/10.1007/s11250-007-9096-z>