

COMPARISON OF POSITIVE CLINICAL AND COMPUTERIZED VISUAL TREATMENT OBJECTIVES IN PREDICTION OF SOFT TISSUE PROFILE OF SKELETAL CLASS II PATIENTS.

Kanza Khan¹, Sohrab Shaheed², Arsalan Khan³, Faizan Ul-Hassan⁴, Nasir Mushtaq⁵, Ayesha Iftikhar⁶.

Abstract

Introduction: The aim of this study was to compare the soft tissue prediction obtained via positive clinical visual treatment objective (VTO) with computerized VTO in patients with skeletal Class II malocclusion.

Methods: 30 skeletal class II patients with ANB>4 were included in the study. Computerized VTO was done using pretreatment lateral cephalograms and profile picture at rest using the Viewbox software. Clinical VTO was obtained by asking the patient to protrude lower jaw in 5mm increments and the obtained profile photographs superimposed on the initial profile at rest. Distances in soft tissue points between computerized VTO and clinical VTO were measured in millimeters at eight cephalometric soft tissue landmarks. Paired-sample t tests were done for intergroup comparisons. **Results:** For most of the variables, no significant differences were found between the groups. In the X-axis the most accurate prediction was found to be mentolabial sulcus while soft tissue menton was the least accurate landmark succeeded by soft tissue gnathion. In the Y-axis, stomion superius prediction and labrale inferius prediction were the most accurate measurements while mentolabial sulcus prediction was the least accurate. None of the differences were clinically significant.

Conclusions: The soft tissue outcomes of positive clinical VTO are clinically acceptable in both sagittal and vertical planes and can be used for estimating post treatment soft tissue profile in skeletal class II patients.

Key words: soft tissue prediction; orthognathic surgery; superimposition

Main points

We compared the soft tissue changes produced by computerized VTO prediction to the clinical VTO by mandibular protraction in skeletal class II patients.

There is paucity of data comparing soft tissue predictions using computerized VTO with positive clinical VTOs.

Most of the variables had statistically insignificant differences and none of the variables were clinically significant.

Introduction

Patients with skeletal discrepancies often pursue combined orthodontic and surgical treatment due to social and psychological concerns with the expectation of improved function and esthetics. It is essential for the patient to properly comprehend the treatment and to visualize the anticipated outcome.[1,2]

1 Resident, Department of Orthodontics, Rehman College of Dentistry, Peshawar, Pakistan

2 Professor and Head of Department, Department of Orthodontics, Rehman College of Dentistry, Peshawar, Pakistan.

3 Assistant Professor, Department of Orthodontics, Sardar Begum Dental College, Peshawar, Pakistan

4 Assistant Professor, Department of Orthodontics, Rehman College of Dentistry, Peshawar, Pakistan

5 Professor, Department of Orthodontics, Rehman College of Dentistry, Peshawar, Pakistan.

6 Associate Professor, Department of Orthodontics, Rehman College of Dentistry, Peshawar, Pakistan

Visualized treatment objectives (VTOs) are a means of predicting and visualizing such treatment goals and to simulate the soft tissue response of the planned surgical and dental movements.[3] According to Ricketts, a VTO is defined as a visual plan to forecast the normal growth of the patient and anticipated influences of treatment, to establish individual objectives that are to be achieved for that patient.[4] Several methods of such VTOs exist and are available to the clinicians for better planning and achieving stable and esthetic outcomes.[4]

Manual methods of obtaining VTOs on lateral cephalogram tracings are frequently used but they can be faulty due to the possibility of inaccurate tracing, landmark identification and other random errors.[5,6] Computerized VTO prediction, on the other hand, utilize numerous software programs that mock the soft tissue changes and enable better visualization for both the patient and the clinician.[7] Similarly a chair-side method in which a skeletal Class II patient protracts the mandible into skeletal Class I position can demonstrate profile improvement and is recognized as positive clinical VTO.[8] The speed and visual nature of the clinical VTO gives it an advantage over the manual and computerized VTO.[8]

Several studies have compared the accuracy of computerized VTO prediction, by comparing actual surgical outcomes with computerized VTOs, concluding that there is good approximation between the actual post treatment profile and the prediction.[3,7,9–14] However, there is paucity of data comparing

soft tissue predictions using computerized VTO with positive clinical VTOs.

The aim of this study was to compare the accuracy of the positive clinical VTO prediction in skeletal Class II patients with the computerized VTO prediction. Our hypothesis was that there are no differences between computerized VTO predictions and clinical VTO predictions. In case of sufficient accuracy of clinical VTO, we can use the positive clinical VTO for treatment planning of skeletal class II patients.

Material and Methods

This study was conducted at the orthodontics department of orthodontics, Rehman College of Dentistry, Peshawar, Pakistan after getting ethical approval from the institutional review board (20-02-089). A total of 30 patients presenting to the Orthodontics department were recruited in the study from 1st August 2021 to 30th November 2021. Informed consent was taken from all the patients before their involvement in this study. The inclusion criteria were skeletal class II patients (ANB>4), high contrast preoperative lateral cephalometric radiographs permitting identification of all required hard tissue and soft tissue landmarks and good quality photographs. The exclusion criteria were patients with craniofacial deformities/asymmetry, previous orthodontic treatment, and patients with a beard.

Lateral cephalograms of all the patients were digitally acquired (CS 9000) before initiation of orthodontic treatment, in the natural head position (with Frankfort horizontal plane parallel to the ground) with teeth in centric

occlusion and relaxed lip posture. Lateral profile pictures at rest of the same patients were taken with a digital camera (Canon 60D; f/5, ISO-100, exposure time 1/25s) at a standard distance of 3 ft.

For clinical Virtual Treatment Objective (VTO) pictures, the patients were asked to protrude lower jaw by increments of 5mm that was measured with a standard scale. Only 6 patients were able to protrude their mandible up to 10mm. We regarded VTO pictures as our study unit instead of patients. This resulted in a total of 36 pictures.

For computerized VTO prediction, lateral cephalograms of patients were traced digitally in Viewbox software version 4.1.0.8 (Dhal

Software TM, Greece). After digital tracing on the lateral cephalogram, lateral profile photographs were loaded and aligned with the radiograph. Mandibular advancement was done in increments of 5mm till incisors were in class I. A morphed image (with exponential warping function; distance fall off 20, smoothness 50, block size 10) of predicted advancement was obtained which was superimposed on the initial profile picture at rest keeping the glabella, soft nasion, pronasale and subnasale as reference area (Fig. 1). Differences were measured in millimeters in both the axes (X and Y) using the digital ruler tool in the Viewbox Software at eight cephalometric soft tissue landmarks as defined in table 1.

Figure 1- Morphed image of predicted advancement superimposed on the initial profile picture at rest.

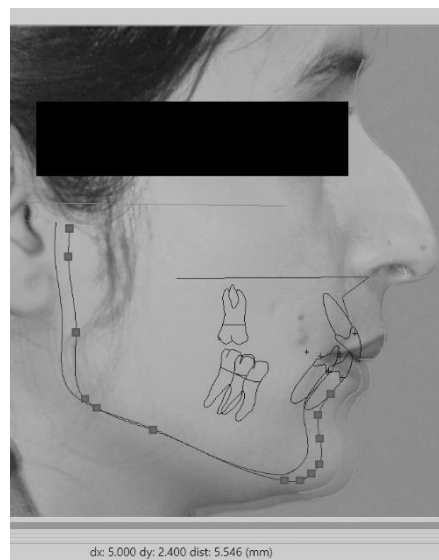


Table 1. Definition of landmarks

Landmark	Definition
Labrale superius (LS)	The midpoint of the vermilion border of upper lip
Stomion superius (SS)	The midpoint of the lower border of upper lip
Stomion inferius (SI)	The midpoint of the upper border of lower lip
Labrale inferius (LI)	The midpoint of the vermilion line of lower lip
Mentolabial sulcus (MS)	The most posterior midpoint on the labiomental soft tissue contour
Soft tissue pogonion (PO')	The most anterior midpoint of the soft tissue chin.
Soft tissue gnathion (GN')	The midpoint of soft tissue Pogonion and soft tissue menton
Soft tissue menton (MN')	The most inferior point on the soft tissue chin

Similarly, the clinical VTO picture was superimposed on the actual profile picture at rest (keeping the same reference areas) and differences were measured from the same landmarks.

Differences in soft tissue outline between the actual profile and the prediction, and between the actual profile and positive clinical VTO were evaluated in the sagittal (x-axis) and vertical (y-axis) planes separately (Fig. 2). Similarly, distances in soft tissue landmarks between computerized VTO and the clinical VTO were calculated. For measurement purpose, computerized VTO profile was

considered as a reference. In X-axis, if clinical VTO landmark was ahead of the computerized VTO profile, then this distance was considered +ve and if behind the computerized VTO profile then -ve. Similarly in Y-axis if clinical VTO landmark was below the computerized VTO profile outline, then it was considered +ve and if it was above then this distance was considered -ve.

To determine the reliability of the measurements, data were reevaluated by the same operator and another operator 1 week after the first measurement, which revealed good reliability (table 2).

Figure 2- Computerized VTO and clinical VTO superimposed on initial profile at rest, respectively.

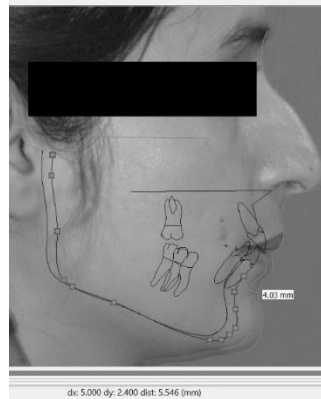


Table 2. Pearson's correlation coefficients

Variables	Intraclass	Interclass
LS-X ¹	0.95	0.88
LS-Y ²	0.94	0.96
SS-X ³	0.89	0.77
SS-Y ⁴	0.94	0.96
SI-X ⁵	0.81	0.80
SI-Y ⁶	0.89	0.87
LI-X ⁷	0.93	0.97
LI-Y ⁸	0.97	0.92
MS-X ⁹	0.98	0.98
MS-Y ¹⁰	0.96	0.97
PO-X ¹¹	0.97	0.94
PO-Y ¹²	0.75	0.80
GN-X ¹³	0.84	0.82
GN-Y ¹⁴	0.76	0.77
MN-X ¹⁵	0.83	0.81
MN-Y ¹⁶	0.97	0.88

¹ Labrale superius measured in X-axis

² Labrale superius measured in Y-axis

³ Stomion superius measured in X-axis

⁴ Stomion superius measured in Y-axis

⁵ Stomion inferius measured in X-axis

⁶ Stomion inferius measured in Y-axis

⁷ Labrale inferius measured in X-axis

⁸ Labrale inferius measured in Y-axis

⁹ Mentolabial sulcus measured in X-axis

¹⁰ Mentolabial sulcus measured in Y-axis

¹¹ Soft tissue pogonion measured in X-axis

¹² Soft tissue pogonion measured in Y-axis

¹³ Soft tissue gnathion measured in X-axis

¹⁴ Soft tissue gnathion measured in Y-axis

¹⁵ Soft tissue menton measured in X-axis

¹⁶ Soft tissue menton measured in Y-axis

Statistical analysis

The normality of the data was assessed using the Shapiro-Wilk test, which showed all the numerical variables to be normally distributed.

Means and standard deviations were computed for ages and all the linear measurements. The comparisons between clinical VTO and computerized VTO were analyzed through paired-sample *t* test.

All the statistical analyses were performed in SPSS (version 25; IBM, Armonk, NY). *p* value less than 0.05 was considered significant.

Results

There were 30 participants out of which 23 were females (76.7%) and 7 were males (23.3%). The age of the participants ranged from 10-28 years. Table 3 shows the baseline statistics of the sample. Number of females was about three times more than the males.

Table 3. Baseline statistics

	male	females	total
Age	19±5.48	19.22±6.02	18.93±5.75
Overjet	8.985±3.49	7.5±2.13	7.85±2.52
ANB	5.46±1.32	6.15±1.59	5.95±1.60
SN-MP	29±7.55	31.76±5.51	31.12±6.02
UI-SN	114.93±9.52	110.61±8.27	111.62±8.61

Paired *t* tests were used to compare the clinical VTO with the computerized VTO prediction (table 4) which revealed statistically significant differences in stomion superius, soft tissue

gnathion, soft tissue pogonion and soft tissue menton in x-axis and mentolabial sulcus in y-axis (Fig. 3 and Fig. 4).

Table 4 (a). Paired differences between computerized and clinical VTO values(mm) in x-axis

Landmarks	Mean	Std. Deviation	95% Confidence Interval		p value
			Lower	Upper	
Labrale superius	0.19	0.73	0.44	-0.05	0.121
Stomion superius	0.66	0.84	0.94	0.37	0.000*
Stomion inferior	0.13	1.43	0.61	-0.36	0.602
Labrale inferior	0.12	1.27	0.55	-0.31	0.568
Mentolabial sulcus	0.05	1.74	0.64	-0.54	0.864
Soft tissue pogonion	0.79	1.65	1.34	0.23	0.007*
Soft tissue gnathion	1.06	1.84	1.68	0.44	0.001*
Soft tissue menton	1.29	1.96	1.95	0.63	0.000*

Table 4 (b) Paired differences between computerized and clinical VTO values(mm) in y-axis

Landmarks	Mean	Std. Deviation	95% Confidence Interval		p value
			Lower	Upper	
Labrale superius	-0.17	1.19	0.57	-0.23	0.400
Stomion superius	-0.11	1.08	0.48	-0.26	0.543
Stomion inferior	0.24	1.66	0.32	-0.80	0.394
Labrale inferior	0.12	2.16	0.61	-0.85	0.737
Mentolabial sulcus	1.18	1.75	-0.59	-1.78	0.000*
Soft tissue pogonion	-0.49	1.94	1.15	-0.17	0.140
Soft tissue gnathion	-0.36	1.60	0.90	-0.18	0.187
Soft tissue menton	-0.32	2.24	1.08	-0.44	0.398

In the X-axis landmarks, the most accurate prediction was found to be mentolabial sulcus (0.05mm, 95% CI +0.64 to -0.54) while soft tissue menton was the least accurate landmark (1.29mm, 95% CI 1.95 to 0.63) followed by soft tissue gnathion (1.06mm, 95% CI 1.68 to 0.44). In the Y-axis, stomion superius

prediction (0.11mm, 95% CI 0.48 to -0.26) and labrale inferius prediction (0.12mm, 95% CI 0.61 to -0.85) were the most accurate measurements while mentolabial sulcus prediction was the least accurate (1.18mm, 95% CI -0.59 to -1.78).

Figure 3- Differences in the landmark positions in comparison to the original profile with each method in X axis

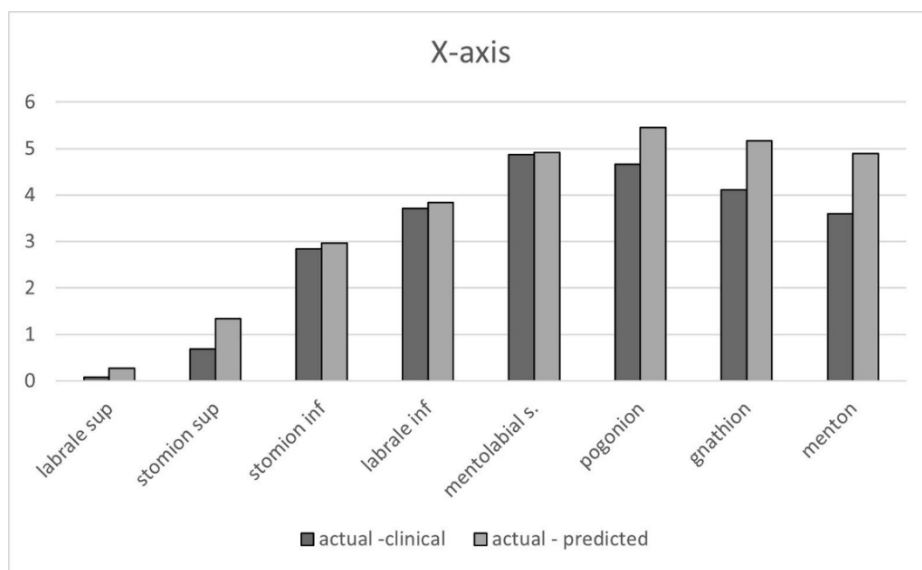
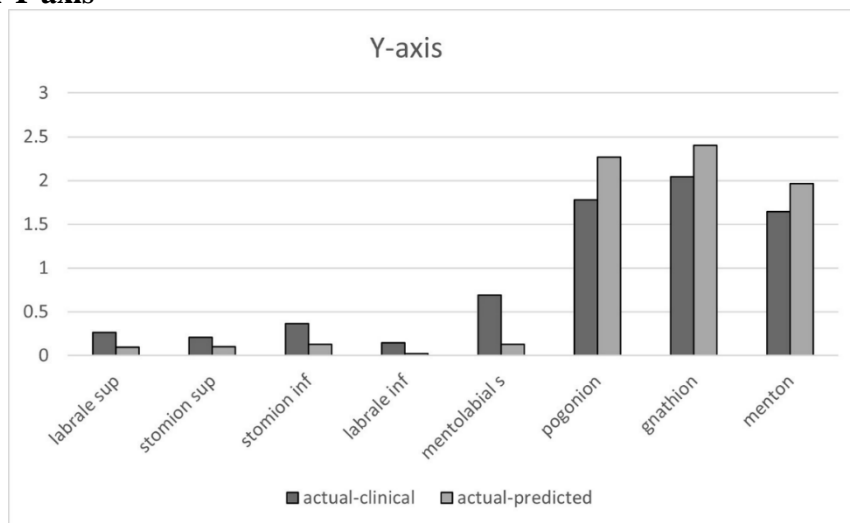


Figure 4- Differences in the landmark positions in comparison to the original profile with each method in Y axis



Discussion

In this study we compared the soft tissue changes produced by computerized VTO prediction using Viewbox software, to the clinical VTO by mandibular protraction in skeletal class II patients and found that none of the variables had statistically significant differences except for a few i.e., stomion superius, soft tissue menton, soft tissue gnathion and soft tissue pogonion in x-axis while mentolabial sulcus in y-axis (Fig. 3 and Fig. 4). However, none of these were clinically significant.

Different methods are commonly used to predict post-surgical changes e.g., manual lateral cephalometric surgical prediction, computer-assisted cephalometric surgical prediction, computerized video imaging prediction and positive clinical VTO (intentional mandibular protraction). We chose clinical VTO because it's by far the most convenient method, chairside picture can be easily taken and there is no hassle of uploading and digitizing pictures, and the patient can see the predicted profile improvement in seconds. We superimposed the pictures by setting the reference area at nose because it has been proved to be the most accurate and reliable region that the software could predict.[4,13–15]

Previous studies have used cephalometric softwares such as Dolphin™,[10,11,16] Quick Ceph™,[17] Dentofacial Planner™,[12] and Orthognathic Treatment Planner™ [18] to simulate surgical treatment outcomes and compare them with actual post-surgical changes. We used Viewbox software because

of its availability, user-friendly interface, and ease of use.

Based on several previous studies, we chose a difference of 1.5mm as clinically acceptable prediction error because significant statistical differences may not always imply clinical significance.[16,19–21] The average discrepancy between the clinical VTO and predicted changes were small ranging from 0.05 to 1.2 mm; only 3 of the 16 soft tissue landmarks measured had differences greater than 1mm and none had errors greater than 1.5mm.

In our study, mean differences were more precise for the vertical plane than for the sagittal plane in contrasting from various studies[5,9,14] but consistent with the findings of Lu et al[15] who proposed that this might occur because sagittal algorithms are primarily involved in the computer-generated surgery.

The most accurate landmark in x-axis was mentolabial sulcus (0.048 mm, 95% CI) while stomion superius (0.11mm, 95% CI) and labrale inferius in y-axis (0.12mm, 95% CI). This could be because labrale and mentolabial sulcus are easiest to measure and are good for identification because they have clear boundaries. In contrast, soft tissue menton (1.28mm, 95% CI) was the least accurate landmark in x-axis followed by soft tissue gnathion (1.06mm, 95% CI), while mentolabial sulcus (0.56mm, 95% CI) was the least accurate in y-axis. A possible explanation could be that while intentionally protruding the mandible stomion superius moves upwards, while no such movement occurs during software simulation.

The largest differences were found in the landmarks near the chin area, in both sagittal and vertical planes which in accordance with various studies which compared the computer generated soft-tissue profile with actual postsurgical changes.[11,13,16,22] The explanation for less accurate soft tissue chin prediction might be due to the unstable trait of the soft tissue thickness associated with the body mass index as reported by Zhang et al[16] and as reported by Xia et al[23] because of multiple directional movements of the soft tissues in the chin region . Other reasons could be that chin sometimes seems distorted in computerized VTO picture after morphing, so maybe not so accurate. Also, soft tissue thickness and tonicity may play a role in less accuracy of chin area.

The literature also reveals the lower lip predictions to be the least accurate.[13–15,24,25] However In our study we did not observe any major differences in lower lip predictions which is in agreement with the study by Nadjmi et al.[22] These differences in literature could be due to the reason that we did not compare computer generated predictions with the actual post-surgical changes.

For most of the variables we could not reject the null hypothesis. In general, the predictions of computerized VTO and clinical VTO were in agreement. Therefore, it can be assumed that the positive clinical VTO can be used to predict class II surgical treatment outcomes for diagnosis and treatment planning and can be considered in routine due to ease of use and efficiency.

Although we attempted to maintain standardization, there may still be some random errors in performing accurate measurements, changes in the image quality or technique, or differences in the prediction algorithms. To study and elucidate the potential causes of these inaccuracies, more research is required.

The sample size is still relatively small and age range was too broad. More subjects should be included in future studies to improve population representation. Further studies should be done comparing clinical VTO with actual post-surgical or post growth modification profiles.

This study focused on the soft-tissue profile as seen on lateral cephalogram which makes it difficult to predict the postoperative appearance accurately. Patients are often concerned about this because they are often interested in knowing the details of the anticipated facial appearance after surgery. Additionally, the predicted correction of face asymmetry cannot be accomplished with this procedure, which is a concern to the patients as they are often interested in knowing the details of the expected facial appearance following surgery. Also, this method is not suitable for the predicted correction of facial asymmetry.

Conclusions

The soft tissue outcomes of positive clinical VTO are clinically acceptable in both the sagittal and vertical planes.

In individuals with skeletal class II, positive clinical VTO can be used to predict the post-treatment soft tissue profile.

REFERENCES

1. Cunningham SJ, Hunt NP, Feinmann C. Psychological aspects of orthognathic surgery: a review of the literature. *Int J Adult Orthodon Orthognath Surg.* 1995;10(3):159–72.
2. Kolokitha OE, Topouzelis N. Cephalometric Methods of Prediction in Orthognathic Surgery. *J Maxillofac Oral Surg.* 2011 Jan;10(3):236–45.
3. Gossett CB, Preston CB, Dunford R, Lampasso J. Prediction Accuracy of Computer-Assisted Surgical Visual Treatment Objectives as Compared With Conventional Visual Treatment Objectives. *J Oral Maxillofac Surg.* 2005 Jan;63(5):609–17.
4. Deva M, Sesham VM. Visual Treatment Objective: A Review. *Indian J Dent Adv.* 2018;10(3):136–46.
5. Olivetti EC, Nicotera S, Marcolin F, Vezzetti E, Sotong JPA, Zavattoni E, Ramieri G. 3D Soft-Tissue Prediction Methodologies for Orthognathic Surgery—A Literature Review. *Appl Sci.* 2019 Jan;9(21):4550.
6. Swennen GRJ, Schutyser F, Barth EL, Groeve P De, Mey A De. A New Method of 3-D Cephalometry Part I: The Anatomic Cartesian 3-D Reference System. *J Craniofac Surg.* 2006;17(2):12.
7. Moss JP, Grindrod SR, Linney AD, Arridge SR, James D. A computer system for the interactive planning and prediction of maxillofacial surgery. *Am J Orthod Dentofac Orthop.* 1988;94(6):469–75.
8. Hussain S, Azeem M, Hamid WU, Rasool F. Relationship between positive clinical VTO and post-treatment soft tissue profile following phase I growth modification therapy. *Orthod J Nepal.* 2018;8(2):45–9.
9. Elshebiny T, Morcos S, Mohammad A, Quereshy F, Valiathan M. Accuracy of Three-Dimensional Soft Tissue Prediction in Orthognathic Cases Using Dolphin Three-Dimensional Software: *J Craniofac Surg.* 2019 Jan;30(2):525–8.
10. de Lira A de LS, de Moura WL, Artese F, Bittencourt MAV, Nojima LI. Surgical prediction of skeletal and soft tissue changes in treatment of Class II. *J Cranio-Maxillofacial Surg.* 2013 Jan;41(3):198–203.
11. Peterman RJ, Jiang S, Johe R, Mukherjee PM. Accuracy of Dolphin visual treatment objective (VTO) prediction software on class III patients treated with maxillary advancement and mandibular setback. *Prog Orthod.* 2016 Jan;17(1):19.
12. Jacobson R, Sarver DM. The predictability of maxillary repositioning in LeFort I orthognathic surgery. *Am J Orthod Dentofac Orthop.* 2002 Jan;122(2):142–54.
13. Akhoundi MSA, Shirani G, Arshad M, Heidar H, Sodagar A. Comparison of an Imaging Software and Manual Prediction of Soft Tissue Changes after Orthognathic Surgery. *J Dent.* 9(3):11.
14. Pektas ZÖ, Kircelli BH, Cilasun Ü, Uckan S. The accuracy of computer-assisted surgical planning in soft tissue prediction following orthognathic surgery. *Int J Med Robot Comput Assist Surg.* 2007 Jan;3(1):64–71.
15. Lu CH, Ko MS, Ellen Wen-Ching

DDS, Huang CS. The accuracy of video imaging prediction in soft tissue outcome after bimaxillary orthognathic surgery. *J Oral Maxillofac Surg.* 2003 Jan;61(3):333–42.

16. Zhang X, Mei L, Yan X, Wei J, Li Y, Li H, Li Z, Zheng W, Li Y. Accuracy of computer-aided prediction in soft tissue changes after orthodontic treatment. *Am J Orthod Dentofac Orthop.* 2019 Jan;156(6):823–31.

17. Loh S, Heng JK, Ward-Booth P, Winchester L, McDonald F. A radiographic analysis of computer prediction in conjunction with orthognathic surgery. *Int J Oral Maxillofac Surg.* 2001 Jan;30(4):259–63.

18. Syliangco ST, Sameshima GT, Kaminishi RM, Sinclair PM. Predicting soft tissue changes in mandibular advancement surgery: a comparison of two video imaging systems. *Angle Orthod.* 1997;67(5):337–46.

19. Kaipatur NR, Flores-Mir C. Accuracy of computer programs in predicting orthognathic surgery soft tissue response. *J Oral Maxillofac Surg.* 2009;67(4):751–9.

20. Sinclair PM, Kilpelainen P, Phillips C, White Jr RP, Rogers L, Sarver DM. The accuracy of video imaging in orthognathic surgery. *Am J Orthod Dentofac Orthop.* 1995;107(2):177–85.

21. Kazandjian S, Sameshima GT, Champlin T, Sinclair PM. Accuracy of video imaging for predicting the soft tissue profile after mandibular set-back surgery. *Am J Orthod Dentofac Orthop.* 1999;115(4):382–9.

22. Nadjmi N, Tehranchi A, Azami N, Saedi B, Mollemans W. Comparison of soft-tissue profiles in Le Fort I osteotomy patients with Dolphin and Maxilim softwares. *Am J Orthod Dentofac Orthop.* 2013 Jan;144(5):654–62.

23. Xia J, Ip HHS, Samman N, Wong HTF, Gateno J, Wang D, Yeung RWK, Kot CSB, Tideman H. Three-dimensional virtual-reality surgical planning and soft-tissue prediction for orthognathic surgery. *IEEE Trans Inf Technol Biomed.* 2001 Jan;5(2):97–107.

24. Csaszar GR, Brüker-Csaszar B, Niederdellmann H. Prediction of soft tissue profiles in orthodontic surgery with the Dentofacial Planner. *Int J Adult Orthodon Orthognath Surg.* 1999;14(4):285–90.

25. Konstantos KA, O'Reilly MT, Close J. The validity of the prediction of soft tissue profile changes after LeFort I osteotomy using the dentofacial planner (computer software). *Am J Orthod Dentofac Orthop.* 1994 Jan;105(3):241–9.