

EVALUATION OF SURGERY-FIRST ORTHOGNATHIC APPROACH IN CORRECTION OF DENTOFACIAL SKELETAL DEFORMITIES (A LONGITUDINAL OBSERVATIONAL STUDY)

Shady Aly Hassan¹, Gamal Aly Swaify², Ahmed SeragEldin Mohamed Habib³, Mohamed
Mamdouh Koraitim⁴, Sherief Hussein Abdel-Haffiez⁵

Abstract

Background: Ortho-First orthognathic surgery protocol was the widely accepted for treatment of skeletal deformities however the long duration of the whole treatment, worsening of the appearance by the orthodontic preparation that precede the surgery and the skeletal stability all were still a point of discussion. The purpose of this research was to appraise the surgery-first orthognathic approach in management of dentofacial skeletal deformities in both postsurgical skeletal stability outcomes and the whole treatment plan duration.

Materials and Methods: The study operated on twelve adult patients with class III skeletal deformities with or without skeletal asymmetry that meeting our inclusion criteria, the patients were evaluated clinically and radiologically with time regimen of 3 months postoperatively and 3 months after debonding. Evaluation was performed by panoramic and lateral Cephalometric radiological examinations and study casts to assess the treatment consequence.

Results: The whole treatment plan period ranged from 6 to 16 months (average, 10.58 months). The average age of the patients was 21.78 ± 2.94 years. The statistical analysis showed that changes in skeletal cephalometric landmarks were significant in comparison between the presurgical and postsurgical as well as the post orthodontic treatment cephalometrics and no significant difference between the immediate postoperative cephalometric analysis and post-debonding cephalometric one which indicates favorable skeletal stability along the postsurgical orthodontic treatment.

Conclusions: Surgery first orthognathic approach serves as a reliable option for management of dentofacial deformities. It has demonstrated to produce good effects and enhanced acceptance with its direct and quick bone correction.

Keywords: Surgery-first approach, orthognathic surgery, orthodontic treatment, dentofacial deformities, skeletal class III.

-
1. Assistant Lecturer Oral and Maxillofacial Surgery, Oral and Maxillofacial Surgery Department, Faculty of Dentistry, Suez University
 2. Professor of Maxillofacial and Plastic Surgery, Cranio-Maxillofacial and Plastic Surgery Department, Faculty of Dentistry, Alexandria University
 3. Lecturer of Maxillofacial and Plastic Surgery, Cranio-Maxillofacial and Plastic Surgery Department, Faculty of Dentistry, Alexandria University
 4. Lecturer of Orthodontics, Orthodontic Department, Faculty of Dentistry, Alexandria University
- * Corresponding Author: Shady Aly Hassan, Assistant Lecturer Oral and Maxillofacial Surgery, Department of Oral and Maxillofacial Surgery, Faculty of Dentistry, Suez University, Egypt. Email: shady.hassan@den.suezuni.edu.eg , P.O. Box:432221, Suez, Egypt Scopus ID: 57202021432
ORCID ID: 0009-0002-1443-2157

INTRODUCTION

The correction of dentofacial deformities (DFDs) and malocclusions has always had a threefold goal of achieving functional efficiency, structural balance, and aesthetics [1].

Patients who have significant malocclusion or dentofacial deformity (DFD) suffer compromised physical health, masticatory dysfunction, upper airway resistance, sleep disorders, poor dental hygiene, and perhaps dysfunctional temporomandibular joint (TMJ) [2].

In spite of that, nowadays among many populations, the aesthetic feature of DFDs with its associated psychosocial influence is more valuable than the related physical complications [3].

Dentofacial skeletal deformities and severe skeletal malocclusion are generally corrected by one of three treatment options : early interceptive treatment of the deformity and growth modification ,orthodontic camouflage within patients suffering mild to moderate deformities and they refusing surgical intervention in form of dental compensation, or orthognathic surgery that generally based on a combined approach including orthodontic and surgical operation of facial skeleton for basal bone repositioning with the aim of adjusting malocclusion helping in attaining functional efficiency, structural balance and esthetics [4].

Conventionally, the orthodontic management of malocclusion with superseding skeletal discrepancies requires orthognathic surgery preceded by orthodontic preparation. Orthognathic surgery, such as the Le Fort I osteotomy of the maxilla, multiple segmental

osteotomy, genioplasty, and mandibular bilateral sagittal split osteotomy, involves surgical handling to improve the facial anatomy, esthetics, and function [5, 6].

The conventional concept of surgical-orthodontic treatment, which consisted of preoperative orthodontic treatment of dental alignment, incisor decompensation, and arch coordination followed by orthognathic surgery with surgical stent and semi-rigid fixation for correction of the skeletal discrepancy and finally a postoperative orthodontic management phase for settling of the occlusion, has been recognized [5, 7].

By repositioning teeth in a normal relationship to their basal bone during the dental decompensation procedure, the presurgical orthodontic treatment aims to show the full amount of skeletal abnormalities. However, due to mastication function and power as well as natural dental compensation, which occurs in the opposite way to iatrogenic decompensation, complete decompensation may not be achievable [8, 9].

Post-surgical orthodontic treatment seem like to be more valuable as The surgical procedures alone may produce an apparently satisfactory "centric occlusion," but they are incapable to produce the ideal dynamic functional occlusion, which can only be accomplished by the precise orthodontic tooth movement and cusp positioning that is only possible with post-surgical orthodontic management [10].

However, the conventional ortho-surgery approach is the most commonly used approach , it has several disadvantages present such as lengthier period of presurgical orthodontic treatment preparation that lasts for 15 to 24

months involving progressive deterioration of facial esthetics and dental function, and causing temporary deteriorating of facial appearance and masticatory functions, and if a patient refuses surgery after all the preparations have been made, the results can be disastrous, especially in class III dentofacial deformities, also, the conventional approach to orthognathic surgery requires a relatively constant period of postoperative orthodontics that elongates the whole treatment time [11-16].

Regarding the previously mentioned drawbacks of conventional approach used; a different methodology, the surgery-first approach, proceeds with the orthognathic surgery in the beginning without presurgical orthodontic preparation, and most of the orthodontic treatment is performed after surgical correction in which eliminating the presurgical orthodontic treatment will aids in reducing the whole treatment plan [17, 18].

The purpose of this work was to assess the surgery-first orthognathic approach in the management of dentofacial skeletal deformities, primarily was to evaluate the functional (occlusion) outcomes in the SFOA and secondary was to evaluate the whole treatment period in dentofacial skeletal deformities correction while using the SFOA. Thus, the null hypothesis is that the Surgery-First Orthognathic Approach (SFOA) will has no significant difference in correcting dentofacial skeletal deformities.

MATERIALS AND METHODS

Sample size estimation

Sample size was estimated assuming 5% alpha error and 80% study power. Lo et al. reported that with the surgery-first approach for correcting skeletal deformity, 12% of patients had occlusal contact on one segment (unstable occlusion) compared to 88% with more stable occlusion. Using McNemar test, sample size was calculated to be 11 patients increased to 12 patients to make up for loss to follow up based on Rosner's method calculated by MedCalc Statistical Software version 16.4.3 [19, 20].

Study setting

Eligible participants were admitted and operated in the Maxillofacial and Plastic Surgery Department, Faculty of Dentistry, Alexandria University, Egypt.

Eligibility criteria [21, 22]

Inclusion criteria

- **Patients aged from 18 to 30 years.**
- **Patients suffered moderate to severe skeletal class III malocclusion with or without skeletal asymmetry with mild to moderate crowding in the anterior teeth (2-5 mm), flat to average curve of spee (2-4mm).**

Exclusion criteria

- **Patients with missing teeth or prothesis.**
- **Patients suffered compromised general health that contraindicated to general anesthesia.**
- **Patients suffered diseases affecting bone metabolism.**
- **Patient who stated a previously orthodontic treatment.**
- **Patients with multiple impacted teeth.**

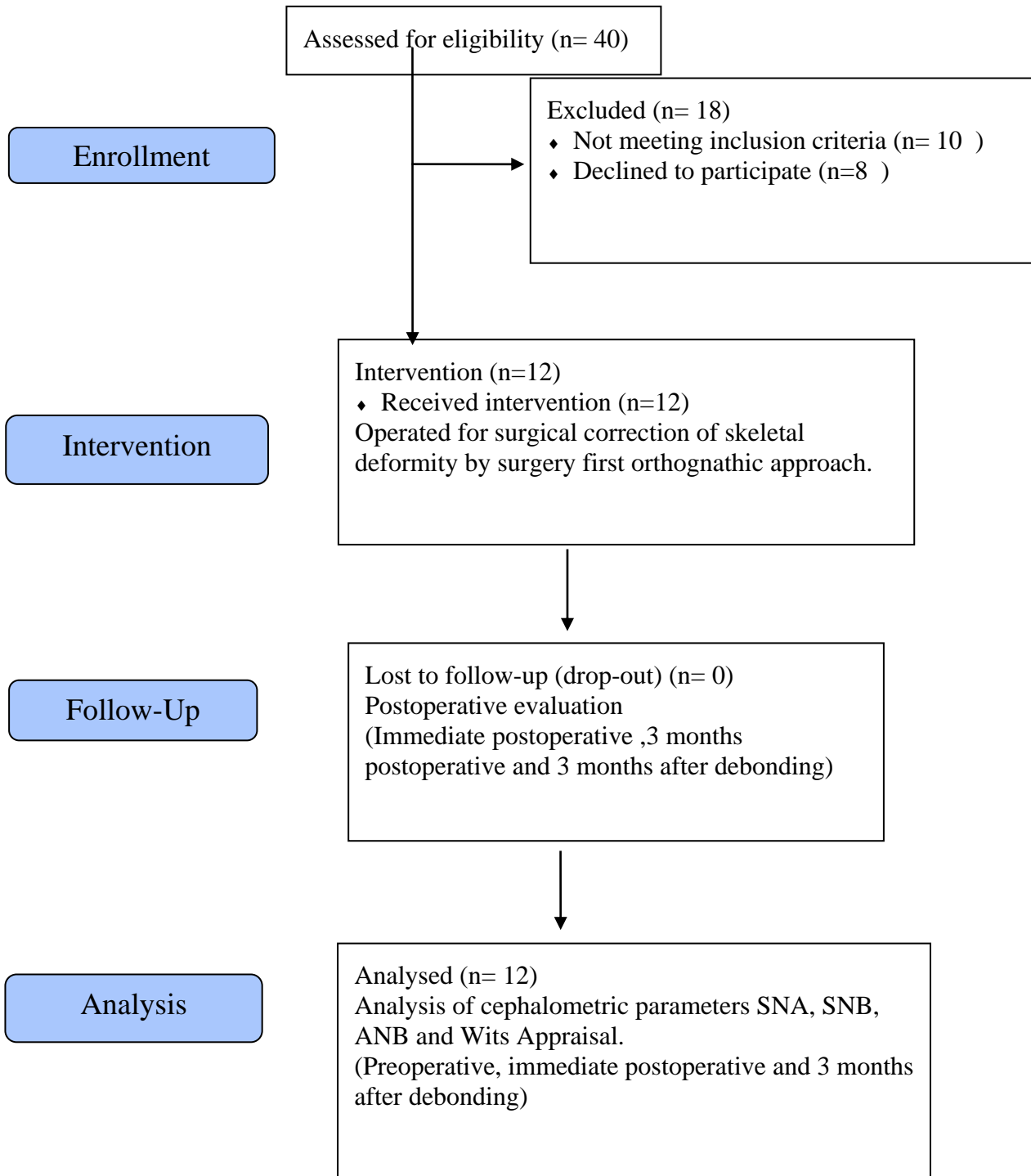


Fig (1): Research consort flow chart.

Preoperative records (T0)

Routine orthodontic records including:

- Radiographs: panoramic and lateral cephalometric x-rays and cephalometric analysis recording.
- Dental casts.
- Intraoral and extraoral photos.
- Records obtained at T0, T1, T2.

Preoperative planning and preparation

- Each case was evaluated using the clinical examination and available records to determine the movements required for correction of the skeletal deformities.
- Working dental casts were used for mock surgery and splints fabrication as needed (one case utilized digitally fabricated splints using digital casts obtained from intraoral scanning).
- The upper and lower dentitions were bonded and banded 24 – 48 hours preoperative but no arch wires were placed. The orthodontic arch wires were placed intraoperative at the end of the surgery under general anaesthesia by the orthodontist in chief.

Operative Procedures

- All aseptic technique measures for the patient and the surgical team were performed.
- All surgical interventions were done through intraoral approaches.

- Surgical interventions in bimaxillary surgeries were done by the sequence of maxilla first orthognathic surgery.
- Maxillary surgery:
 - The mainstay maxillary osteotomy used during the study was Le Fort I osteotomy and fixed with four L-shaped mini-plates with four screws.
- Mandibular surgery:
 - Mandibular osteotomies were done in the form of standard bilateral sagittal split osteotomy (BSSO) technique according to Hunsuck and Epker and fixation was done using straight miniplates and screws placed to follow Champy's ideal osteosynthesis line [23, 24].
 - All condyle bearing segments were positioned free hand without positioning devices, using straight miniplate and monocortical screws.
 - Orthognathic surgery procedures were individualized between three different variations according to treatment planning as the follow:
 - Mandibular setback in single jaw correction surgery.
 - Maxillary advancement with or without posterior impaction with mandibular setback in bimaxillary correction surgery.
 - Unequal mandibular setback in case of skeletal asymmetry.

Follow-up and Data analysis

- **Immediate Postoperative (T1)**
 - a) **Regular records were obtained for documentation and analysis.**
 - **Panoramic x-ray to ensure that the condyles are fully seated inside the condylar fossae.**
 - **Lateral cephalometric x-rays were done for measurements the skeletal changes after surgical interventions (SNA, SNB, ANB and wits appraisals).**
 - **Dental casts for evaluation of the postoperative occlusal relationship and midline assessment.**
 - b) **In one patient a posteroanterior skull view x-ray was done for doubt of condylar neck fracture during mandibular splitting, and there is no condylar fracture were noted.**
- **Three-months post-debonding follow-up (T2)**
 - a) **Regular records were obtained for documentation and analysis.**
 - **Panoramic x-ray to evaluate the bony osteotomies healing and any complications encountered.**

- **Lateral cephalometric x-rays were done for skeletal stability evaluation (SNA, SNB, ANB and wits appraisals).**
- **Dental casts for evaluation of the final orthodontic outcomes.**
- b) **Subjective clinical assessment of nerve numbness and final soft tissue changes.**

Occlusion

- **Was checked clinically by inspection and documentation was done by obtaining intraoral photos and study models in the intercuspal position to assess the occlusal relationship including canine and molar relations and midline centralization for the postoperative orthodontic treatment planning.**

RESULTS

Between June 2021 and March 2023, a longitudinal observational study was conducted on a total number of twelve adult patients (five males and seven females (**Fig. 2**) with mean age 21.78 ± 2.94 years (Table 1).

Table 1: Demographic data of the study participants

Variables		
Age (Years): Mean \pm SD		21.78 \pm 2.94
Gender: n (%)	Males	5 (41.7%)
	Females	7 (58.3%)
		N=12

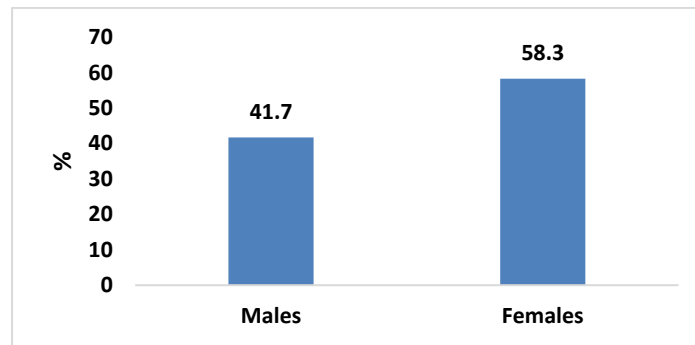


Fig (2): Gender distribution.

Nine patients were class III skeletal deformity, and three patients were Class III skeletal deformity associated with facial asymmetry.

Seven patients were planned for bimaxillary orthognathic surgery while five patients operated in form of single jaw surgery in form of mandibular setback surgery, eleven of the patients were planned with conventionally fabricated wafers and only one patient planned with a digitally designed wafer.

The hospital stay ranged from one day to eight days in the postoperative period, with a mean period of about 3.16 days. The whole treatment duration ranged from 6 to 16 months with a mean period of 10.58 months with the short hospital stay period were noticed with single jaw surgical intervention.

In our study, Seven LeFort I osteotomy were done; three of it were by using micro motor reciprocal saw and the remaining four using piezoelectric cutting saw, while in BSSO a total 28 osteotomies were done; eleven were done utilizing the piezoelectric cutting saw and thirteen were by the fissure bur on micro motor device.

Intermaxillary fixation for skeletal segments positioning in their new positions before semirigid fixation was done by means of

elastics in four patients and by IMF screws and wires in eight patients.

Intraoperative complications were inadequately fabricated intermediated wafer in one patient causing maxillary rotation during fixation which was managed by freely fixation of the maxilla without the wafer, bad split in the one side of sagittal mandibular osteotomy out of all 24 sagittal split osteotomies, which was managed by wire fixation intraoperatively at time of mandibular fixation.

Postoperative anterior openbite was present in four patients immediately postoperative which was managed by class III elastics traction force that solves the situation nicely with no further needed interventions.

In the only patient planned for two pieces maxilla to overcome the intermaxillary width discrepancy a palatal fistula occurred with fluid regurgitation from the nose that healed spontaneously with no surgical intervention, all the clinical data of all patients were summarized in (Table 2). All cephalometric data were statically analysed and collected. (Table 3) and (Fig.3- Fig.5).

A case scenario for bimaxillary surgery is presented in (Fig.6- Fig.21)

Table 2: Summary of pre, intraoperative and postoperative clinical findings

Patient No.	Gender	Age	Deformity	Problem list	Surgery	Hospital stay/Day	Complications
1	F	19	Class III	<ul style="list-style-type: none"> • Skeletal class III due to prognathic mandible. • High angle case. 	Single jaw surgery in form of Mandibular setback	3	Postoperative Numbness
2	F	18	Class III	<ul style="list-style-type: none"> • Skeletal class III due to prognathic mandible and retrognathic maxilla. • High angle case. 	Bimaxillary surgery in form of maxillary advancement and mandibular setback	3	<ul style="list-style-type: none"> • Postoperative Numbness • Postoperative Anterior openbite.
3	F	20	Class III	<ul style="list-style-type: none"> • Class III Skeletal base. • High Angle of the mandible. 	Bimaxillary surgery in form of maxillary advancement, posterior impaction and mandibular setback	8	<ul style="list-style-type: none"> • Postoperative Numbness • Postoperative Anterior openbite.
4	F	18	Class III	<ul style="list-style-type: none"> • Skeletal class III due to prognathic mandible. • High angle case. 	Bimaxillary surgery in form of maxillary advancement and mandibular setback	4	<ul style="list-style-type: none"> • Postoperative Numbness • Postoperative Anterior openbite
5	M	26	Class III	<ul style="list-style-type: none"> • Skeletal Class III due to maxillary deficiency. • Facial Asymmetry. 	Bimaxillary surgery in form of maxillary advancement and asymmetric mandibular setback	2	Postoperative Numbness
6	F	18	Class III	<ul style="list-style-type: none"> • Skeletal class III due to prognathic mandible. • Mild crowding in lower anterior teeth. • Concave profile. 	Single jaw surgery in form of Mandibular setback	2	Postoperative Numbness
7	M	26	Class III	<ul style="list-style-type: none"> • Skeletal class III due to prognathic mandible. • High angle case. 	Single jaw surgery in form of Mandibular setback	1	Postoperative Numbness
8	M	19	Class III	<ul style="list-style-type: none"> • Class III skeletal relation with retruded maxilla and prognathic mandible • increased anterior facial height. 	Bimaxillary surgery in form of maxillary advancement and mandibular setback	3	<ul style="list-style-type: none"> • Postoperative Numbness • Postoperative Anterior openbite
9	M	21	Class III	<ul style="list-style-type: none"> • Class III skeletal base. • High angle case. • Skeletal maxillary transverse discrepancy. 	Bimaxillary surgery in form of maxillary advancement two pieces maxilla and mandibular setback	4	<ul style="list-style-type: none"> • Postoperative Numbness • Palatal fistula. • Loss of upper two centrals
10	M	20	Class III	<ul style="list-style-type: none"> • Skeletal Class III base. • Facial Asymmetry. 	Bimaxillary surgery in form of maxillary advancement and mandibular setback	5	<ul style="list-style-type: none"> • Postoperative Numbness • Intraoperative and postoperative bleeding.
11	F	22	Class III	<ul style="list-style-type: none"> • Skeletal class III due to prognathic mandible. 	Single jaw surgery in form of Mandibular setback	1	Postoperative Numbness
12	F	23	Class II	<ul style="list-style-type: none"> • Skeletal class III due to prognathic mandible. • Facial Asymmetry. 	Single jaw surgery in form of Mandibular setback	2	Postoperative Numbness

Table 3: Comparison of skeletal variables at different time points

	T0		T1		T2		P value	Pairwise comparison		
	Mean ± SD	Median (IQR)	Mean ± SD	Median (IQR)	Mean ± SD	Median (IQR)		T0-T1	T1-T2	T0-T2
SNA (degrees)	81.73 ± 3.78	83.39 (5.93)	83.02 ± 4.52	82.95 (5.03)	82.40 ± 4.50	82.79 (4.89)	0.386	-	-	-
SNB (degrees)	86.13 ± 3.02	86.60 (2.03)	81.64 ± 4.22	82.97 (7.74)	81.35 ± 3.53	82.68 (2.87)	<0.0001*	0.001*	1.00	0.001*
ANB (degrees)	-4.40 ± 2.81	-3.10 (2.38)	1.38 ± 2.48	0.18 (3.21)	1.04 ± 2.62	-0.26 (3.67)	<0.0001*	<0.0001*	0.264	0.023*
Wits (mm)	-11.12 ± 3.42	-10.00 (3.27)	-2.29 ± 3.25	-3.23 (5.59)	-3.50 ± 2.70	-4.00 (4.88)	<0.0001*	<0.0001*	0.602	0.012*

*Statistically significant difference at p value ≤ 0.05

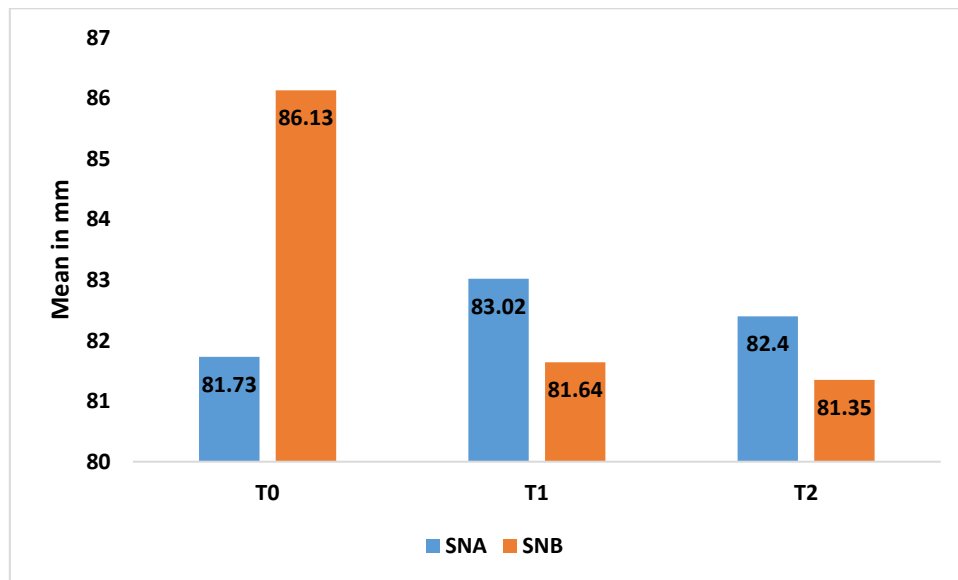


Fig (3): SNA and SNB measurement comparisons (Degrees).

T0: preoperative. **T1:** Immediate postoperative. **T2:** Three months postdebonding.

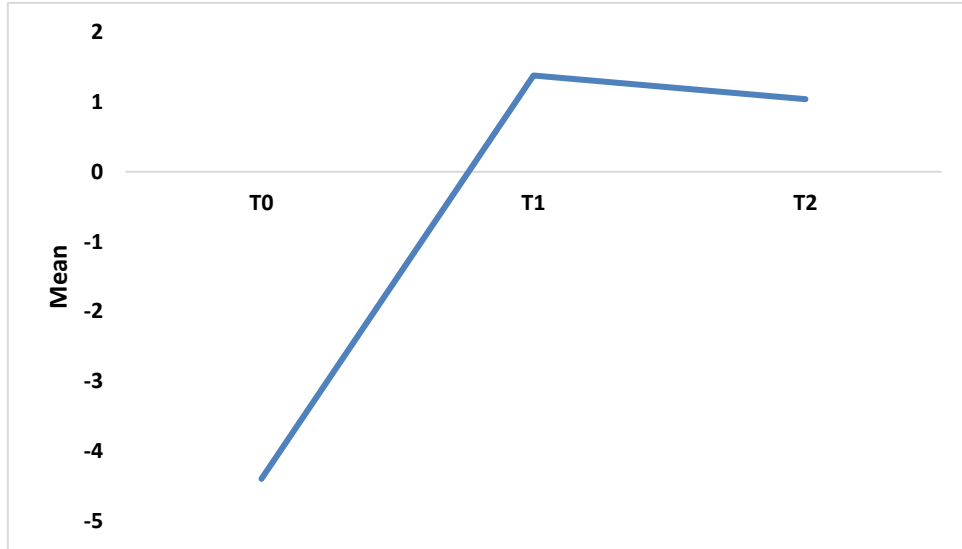


Fig (4): ANB measurement comparisons (Degrees).

T0: preoperative. **T1:** Immediate postoperative. **T2:** Three months postdebonding.

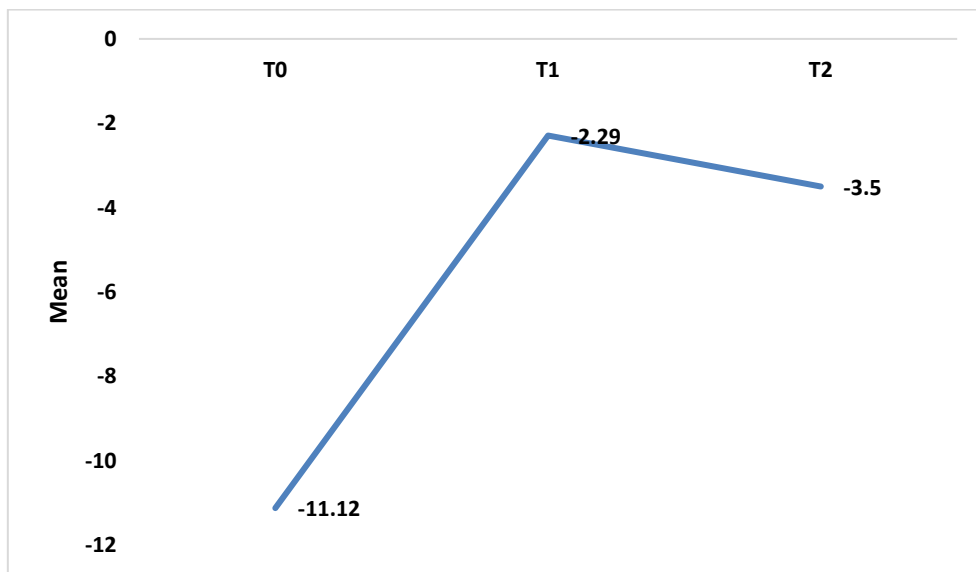


Fig (5): Wits Appraisal (mm).

T0: preoperative. **T1:** Immediate postoperative. **T2:** Three months postdebonding.

Patients

Case scenario for bimaxillary surgery (Figs 6-21)

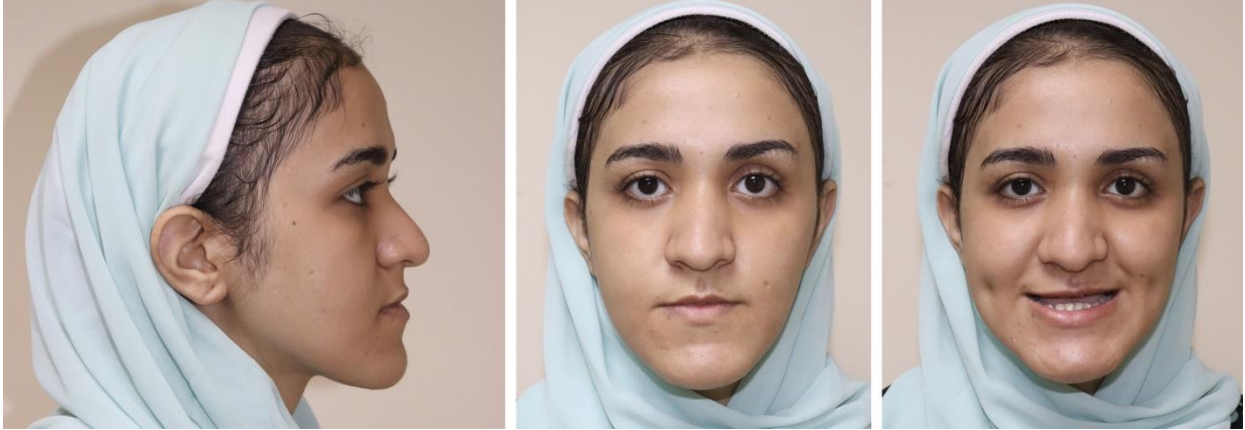

Fig (6): Preoperative extraoral photos.

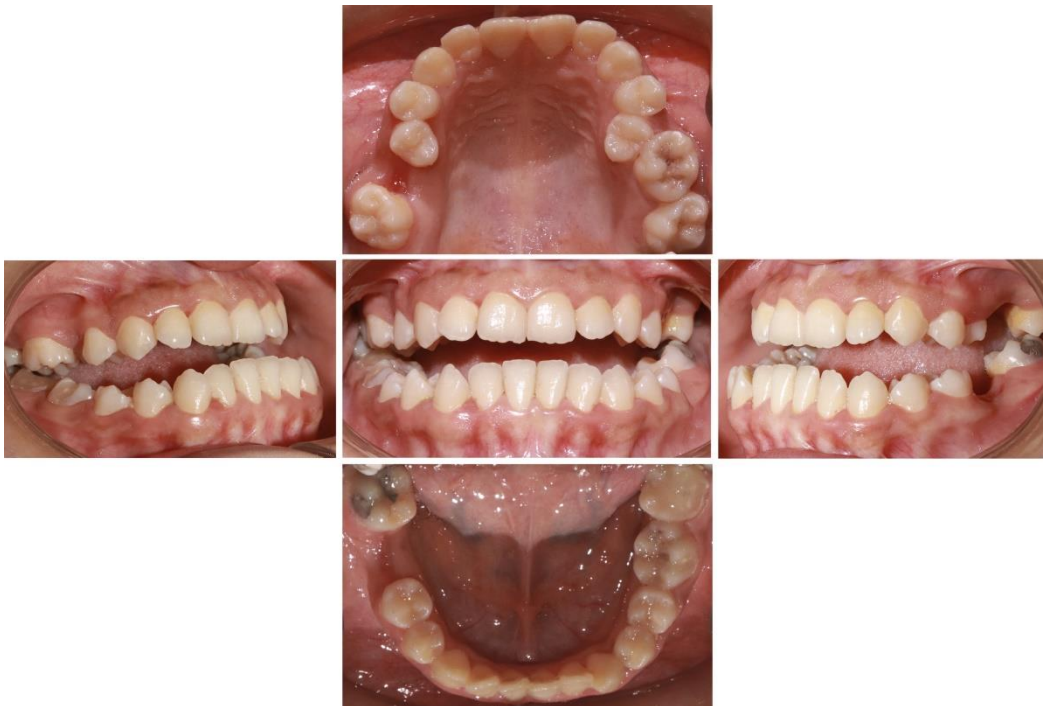

Fig (7): Preoperative Intraoral photos.

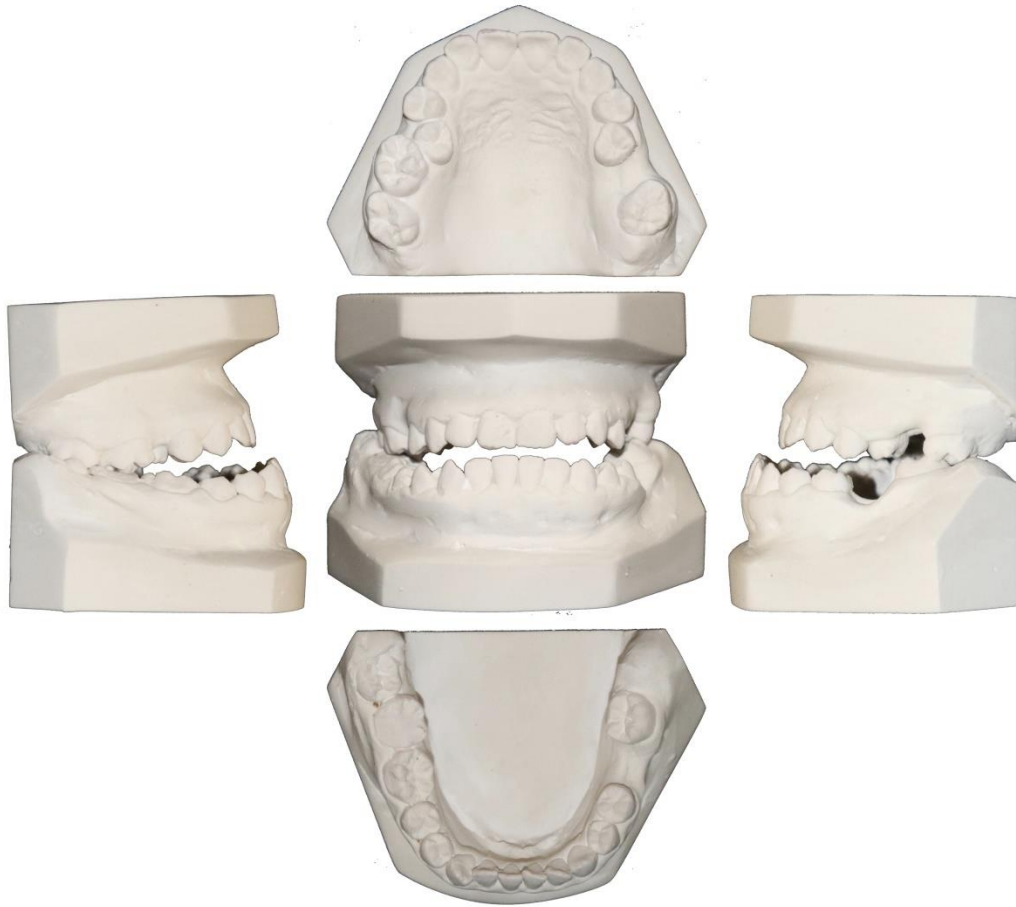

Fig (8): Preoperative cast photos.

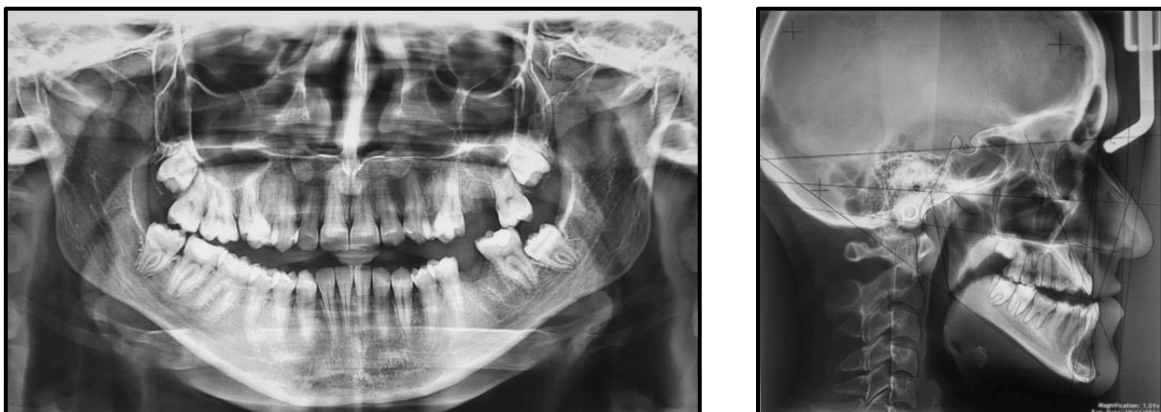
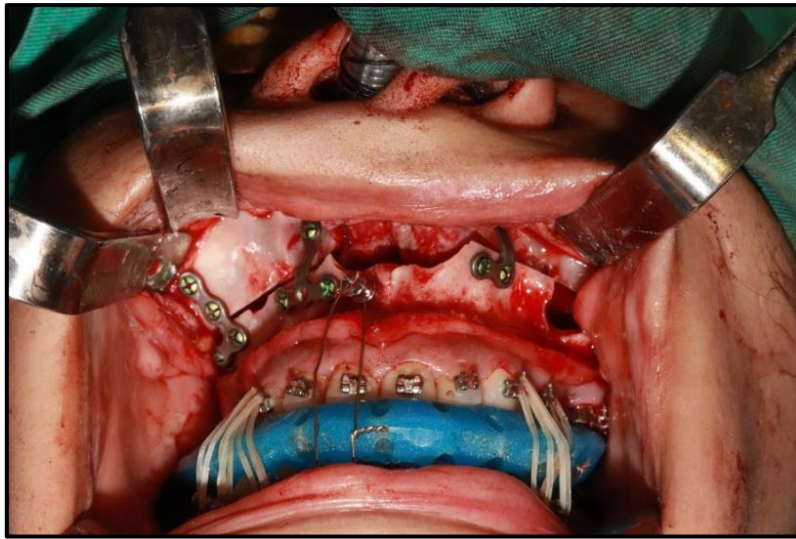
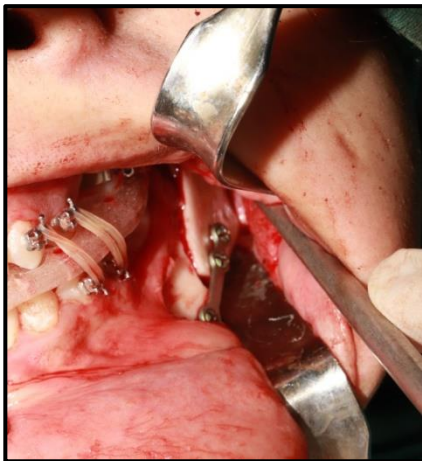


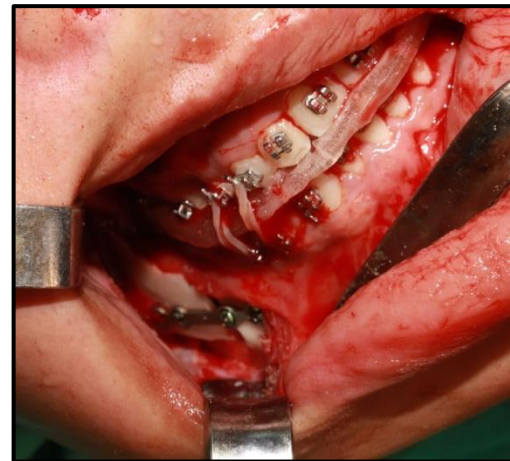Fig (9): Preoperative Panorama and lateral cephalometric x-rays.



A



B



C

Fig (10): Intra-operative steps.

A. maxilla fixation using intermediate wafer.

B&C. Mandible fixation using final wafer.

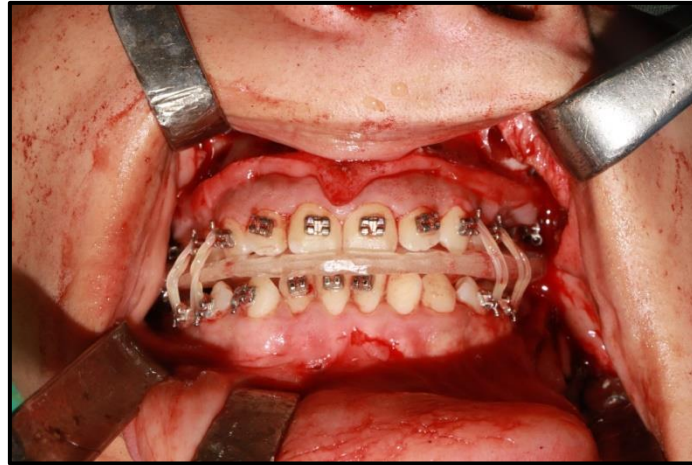


Fig (11): Final Intraoperative intraoral photo.

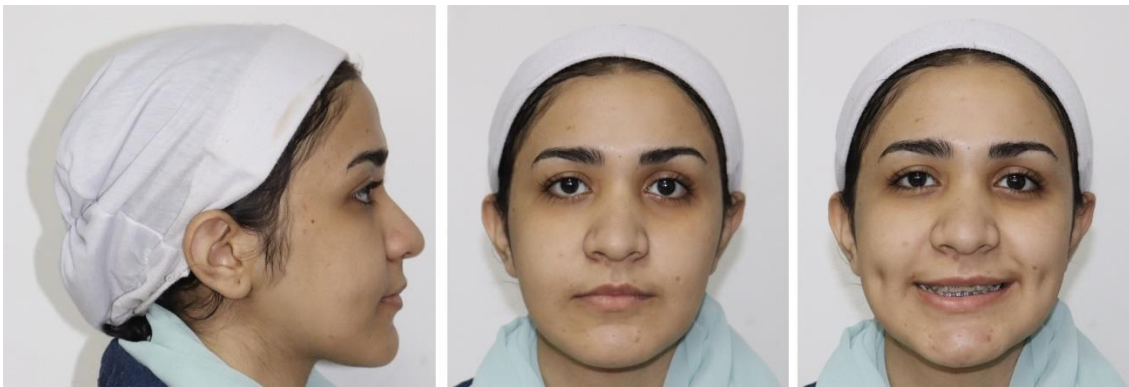

Fig (12): Immediate Postoperative extraoral photos.

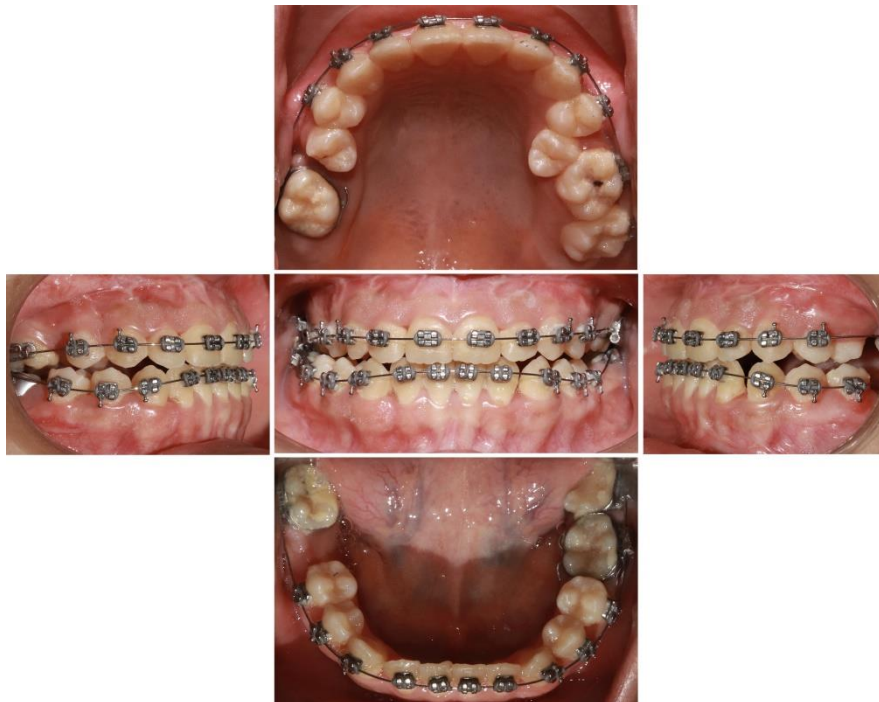

Fig (13): Immediate Postoperative intraoral photos.

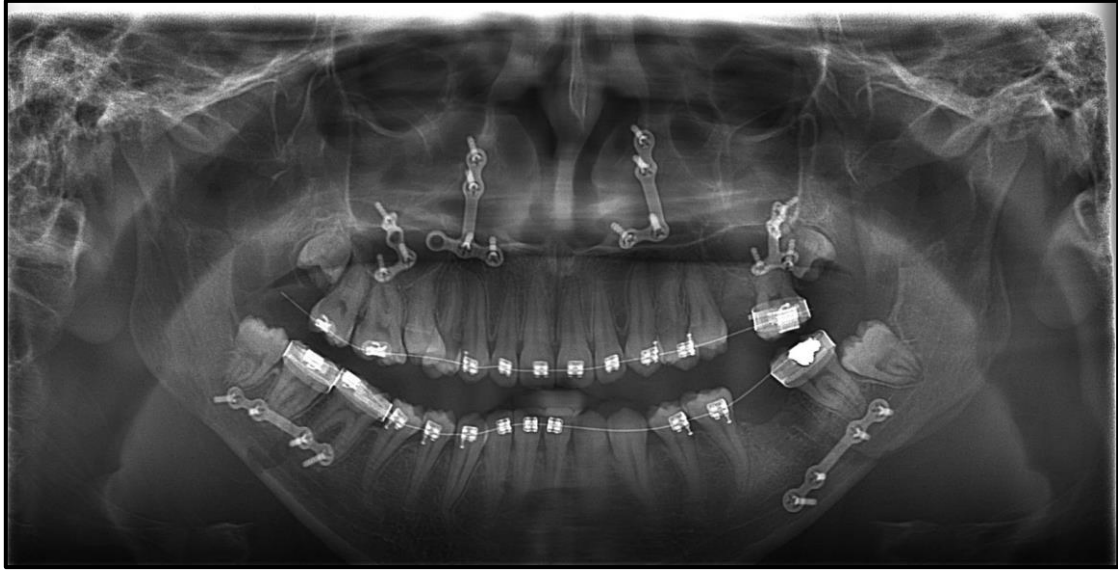
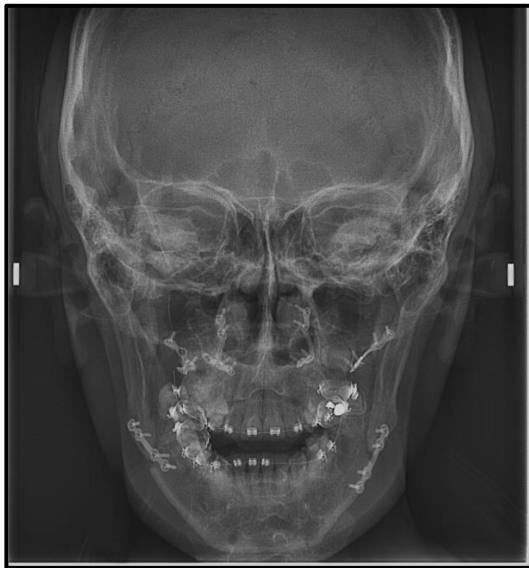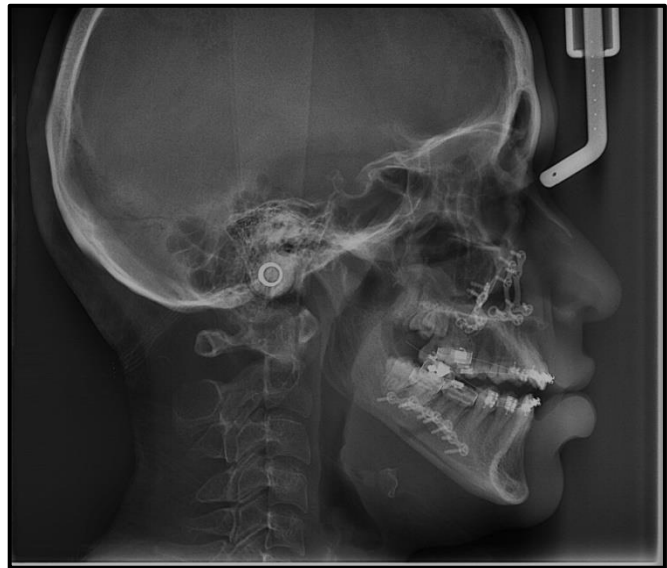


Fig (14): Immediate Postoperative panorama.

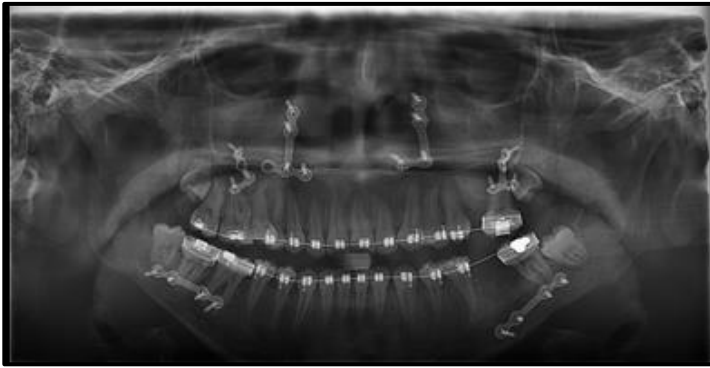

A

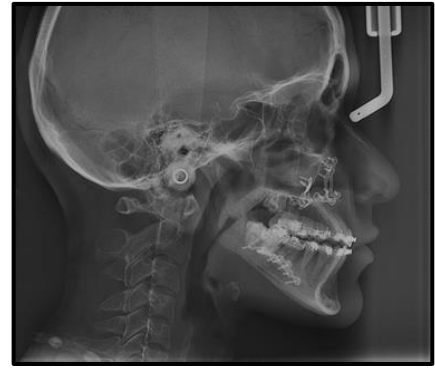

B

Fig (15): Immediate Postoperative X-rays. A. PA view B. Lateral cephalometric.

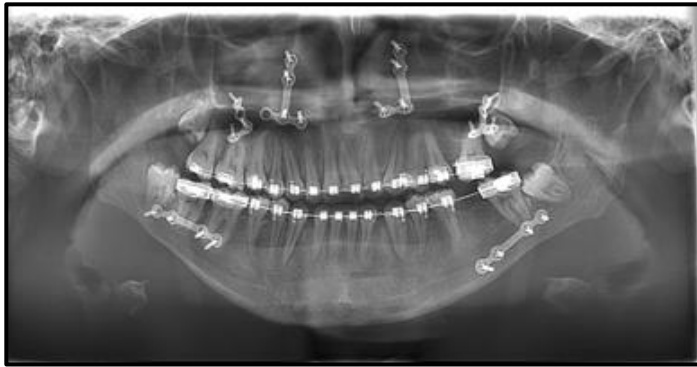

A

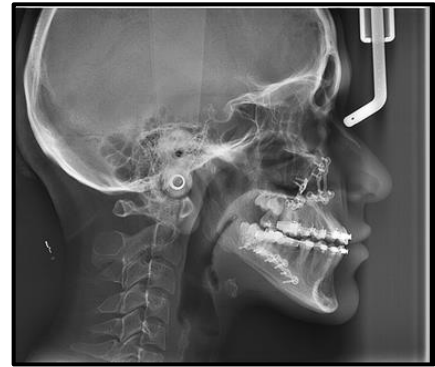


B

Fig (16): Three months Postoperative x-rays. A. Panorama B. lateral cephalometric.



A



B

Fig (17): Six months Postoperative x-rays. A. Panorama B. lateral cephalometric.

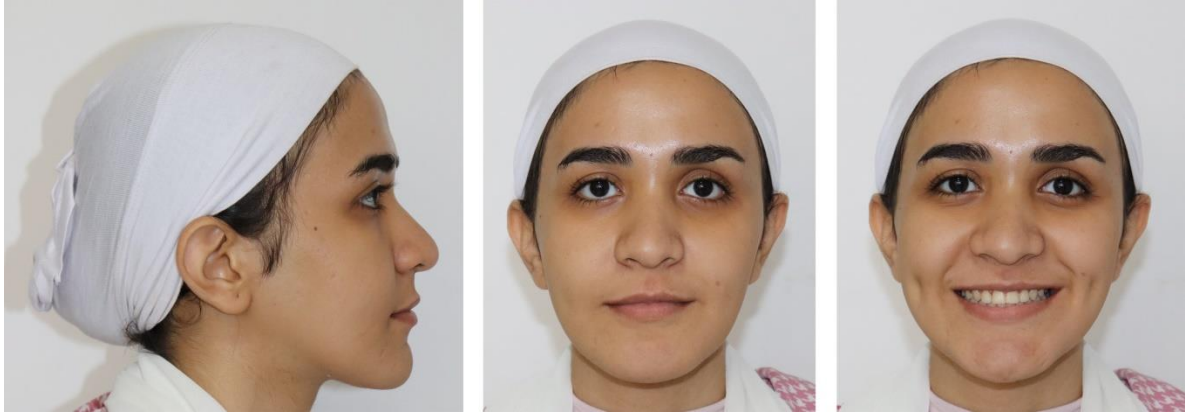

Fig (18): Immediate post-debonding extraoral photos.

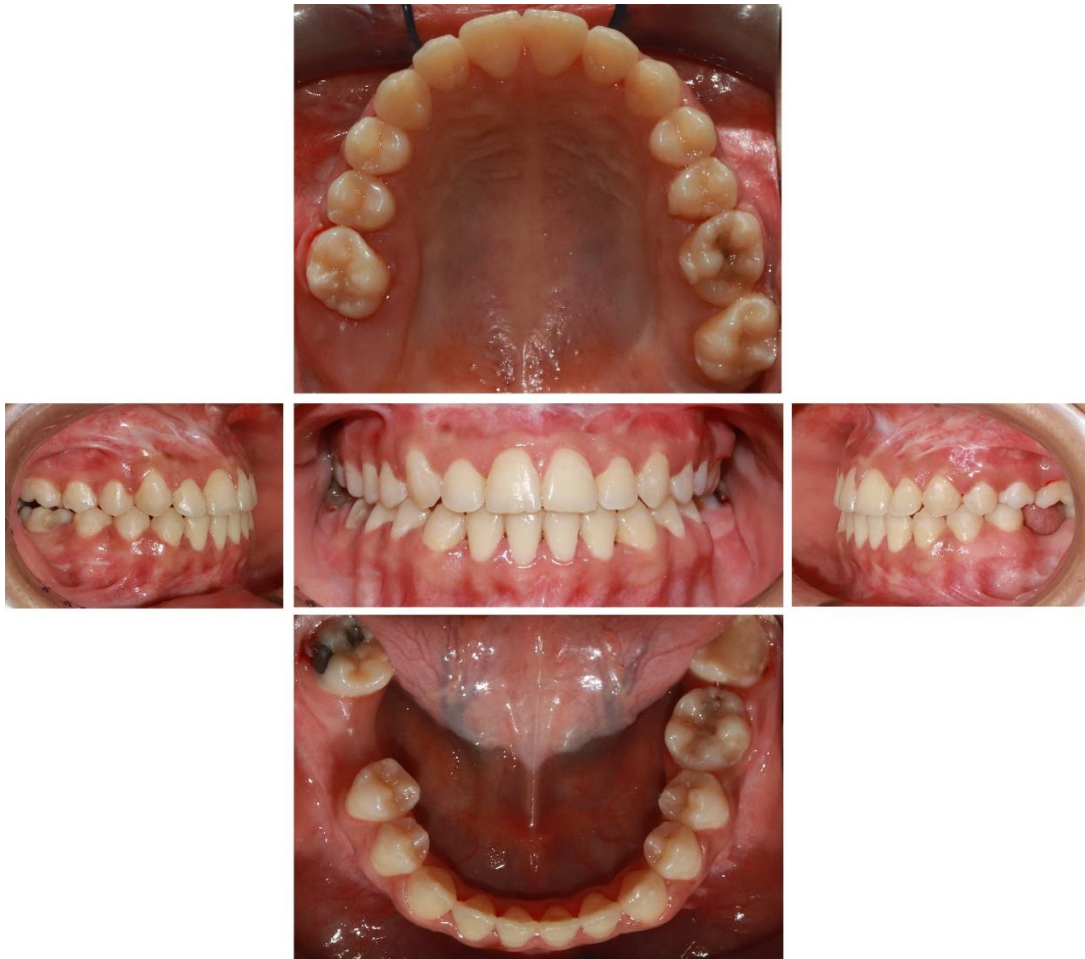

Fig (19): Immediate post-debonding intraoral photos.

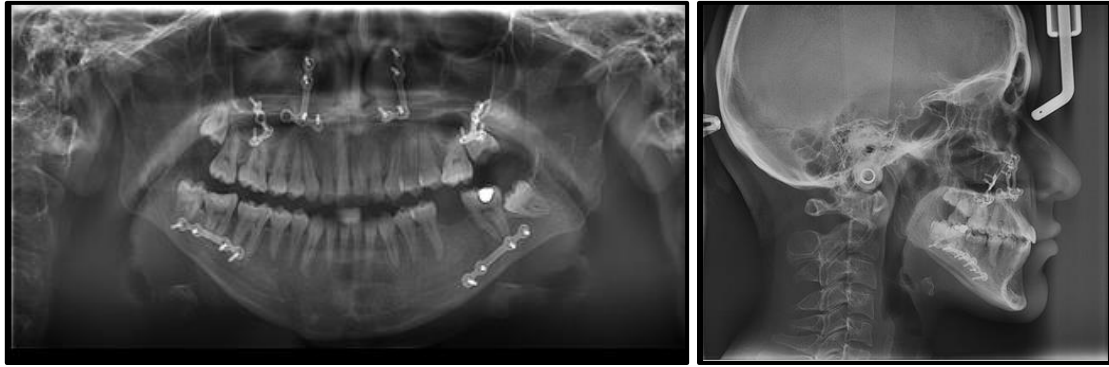
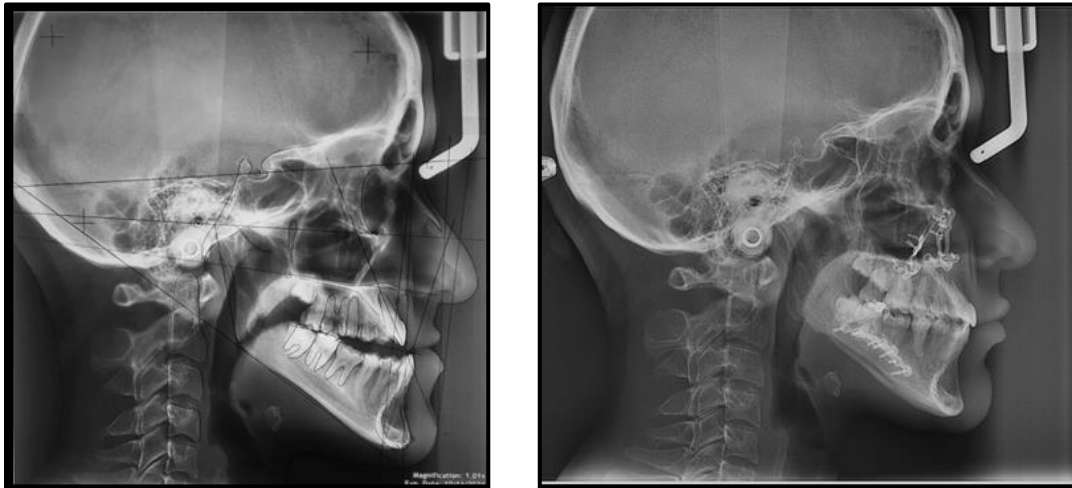


Fig (20): Immediate post-debonding x-rays.



A

B

Fig (21): Comparison between A. Preoperative and B. Immediate post-debonding lateral cephalometric.

DISCUSSION

Recently, the concerns with the quality of life and patient's esthetics are essential issues regarding the cosmetic surgeries that give the SFOA the privilege in different DFDs correction.

Regarding the orthodontics brackets bonding time it differs in conventional orthognathic surgery from SFOA in that there is no orthodontic tooth movements is needed before surgery, so the timing of orthodontic bonding and means of intraoperative IMF gaining was a point of controversy. Chung C Yu and Villegas [18] in their work orthodontic bonding was done one week before orthognathic surgery, **Nagasaka et al. (2009)[17]** and **E Liou et al.[22]** both stated that all the teeth were banded and bonded just before surgery while Orthodontic arch wires are placed one week postoperatively for the alignment, in another management **Hernandez at.al.(2011)[16]** bonded the orthodontics brackets within the period of ten to fourteen days postoperatively. In the present study all orthodontic bonding was done 24-48 hours preoperative like the work of **Nagasaka et al. (2009)[17]** and **E Liou et al.[22]** our point of view that is more comfortable for both the patients and the orthodontist as well as there is no surgical edema or pain which add difficulty in management in case of placing the brackets postoperatively, while the difference with their work is the placement of arch wire timing, in all patients of our study the arch wires were placed at the end of the surgical procedures under general anesthesia to start the activation of tooth movements from the day zero.

Borges et al.(2021)[25] and **Park et al.(2013)[26]** used skeletal anchorage screws for gaining IMF during osteotomies fixation, in the present study we used the means of IMF elastics using the bonded orthodontic brackets in the first four patients while the remaining eight patients the IMF screws were the means for IMF stabilization, the advantage of IMF screws is the more secured occlusion during miniplates fixation that reducing the time needed to check the occlusion repeatedly during the operation.

In our series eleven of the patients were planned with conventionally fabricated wafer and only one patient planned with a digitally designed wafer, the patient who subjected to digital planning suffered from horizontal discrepancy combined with anteroposterior one between the upper and lower jaw that required management using maxillary advancement in two-pieces maxilla, **Chin et al. (2017)[27]** in their comparative prospective study conducted on 10 patients fabricated two surgical splints digitally The first splint would guide the repositioning of segmented maxilla, where the second splint determined the final position of lower jaw. Their results showed that the virtual surgical plans were successfully transferred by the assistance of CAD/CAM fabricated surgical splint. **Lin and co-workers (2015)[28]** concluded that virtual orthognathic planning yields aesthetically favorable results, a higher level of patient satisfaction, accurate translation of the treatment plan with hypothesis that virtual planning making the operation itself easier and safer.

Pagotto and coworkers (2017)[29] in their systematic review and meta-analysis to compare piezosurgery with traditional osteotomy in orthognathic surgery stated that no variations in operative time were discovered for bimaxillary osteotomies were performed, although patients who had ultrasonic bone cutting experienced less intraoperative blood loss and postoperative neurosensory problems than those who underwent the traditional osteotomy method.

In the present study results were coincident with this systematic review, and there is no significant difference in the postoperative edema in both methods; while it should be stressed that the design of bony osteotomy especially in BSSO is highly better while using the piezosurgery with almost no bone loss at the osteotomy site which entails a more accurate in the measurements needed for correction of the jaw deformity.

Olate and colleagues (2018)[30] presented a retrospective study was conducted between 2005 and 2014 including Four hundred forty-five patients to analyze the presence of complications related to orthognathic surgery, the most relevant intraoperative complications encountered during their study were Orthodontic appliances problem, Bad split, Bleeding, Dental problem/ apicectomy, Soft tissue lesions; while postoperative complications were relapse, neurosensory deficits, infection or sinusitis, soft tissue problems and wound or suture problem.

These outcomes are in line with our present work , the patient who planned for two pieces maxilla surgery unfortunately lost his upper

two central teeth in the early postoperative period with our explanation was in two points, First It was due to soft tissue problem as a small band of attached gingiva was left attached to the alveolar bone due to low placed incision, Second was as SFOA didn't include any tooth preparation before surgery there was no sufficient bone for segmental maxillary osteotomy between the two centrals that affects the bone coverage at the proximal surfaces.

In the current study there were seven patients were planned for bimaxillary orthognathic surgery while five patients operated in form of single jaw surgery, all the anteroposterior discrepancies were all ideally corrected in all the sample with stable skeletal results our findings is totally matching with **Cao and coworkers (2009)[31]** who conducted a prospective study on thirty-six Chinese Class III patients with long face problems To describe the surgical procedure in correcting Class III patients with long face problems and to evaluate the lateral cephalometric changes resulting from surgical-orthodontic treatment.

In our study, the whole treatment duration ranged from 6 to 16 months with a mean period of 10.58 months which considered a great achievement in dentofacial deformity management; two of our patients who subjected for bimaxillary surgery correction finished their whole treatment in a period of 9 months, with a stable skeletal results with no any relapse detected, this occurred due to three factors, first of all the patients compliance was superior and the concept of "face-first" which offered by SFOA encourage the patients to continue their orthodontic treatment despite

the conventional approach in which the orthodontic preparation worsen the facial appearance [14]. However, this advantage may be a double ended weapon in some reluctant patients who delayed in the orthodontic visits after achieving a better facial appearance. Second important factor in reduction of the whole treatment plan is the Accelerated tooth movement phenomenon because the bone turnover rate increases due to neovascularization after bone osteotomies and bone healing process [32]. The accelerated tooth movement phenomena last for a period of four months postoperatively and by apply the arch wire at the end of the surgery we get all the benefit of this phenomenon by the first day to establish which for sure aids in the reduction of the treatment plan duration [22]. Third main factor in shortening the treatment period is that there is a synergistic effect between the orthodontic force and the newly generated adaptation force from the lip and tongue after correcting the skeletal difference. During postoperative orthodontic treatment, the tongue moves in the direction of tooth movement [33].

Yang et al.(2017)[34] compared the stability, effectiveness, and results between the anticipated benefit of conventional surgery in a systematic review and meta-analysis of ten retrospective studies, finding that the anticipated benefit was more effective in relation to the overall duration of treatment and had comparable stability and surgical results to conventional surgery. These results are corroborated by our demonstration of a shorter overall treatment time with aesthetic improvement without obstacles during the subsequent orthodontic treatment, leaving the

patient satisfied and lowering the likelihood that they will give up on treatment due to the worsening of their facial profile and occlusion, which is evident when the orthodontic is done prior to surgery.

Skeletal stability of all of our patients included in this study was optimum with no evidence of any relapse occurred in comparing the immediate postoperative lateral cephalometric and the after 3 months of debonding one, this skeletal stability is obtained by good preoperative planning for the planned postoperative occlusion, our results is explained and similar by the outcome of **Lo et al. (2019)[19]** who conducted a study on Forty-two adult patients with a skeletal class III deformity corrected by Le Fort I osteotomy and bilateral sagittal split osteotomy with a surgery-first approach exactly similar to our protocol, with the question of the skeletal stability after bimaxillary surgery using a surgery-first approach for skeletal class III deformity is related to the surgical occlusal contact or surgical change.

Lo et al. (2019)[19] evaluated The relationship between skeletal stability and surgical occlusal contact or surgical change, with a conclusion of no relationship was found between maxillary or mandibular stability and surgical occlusal contact. However, a significant relationship was found between maxillary and mandibular stability and the amount and rotation of surgical change. The results suggest that in the surgical-orthodontic correction of skeletal class III deformity with a surgery-first approach, the post-surgical skeletal stability is

not related to the surgical occlusal contact but is related to the surgical change.

However, a strong correlation between the quantity and rotation of surgical alteration and maxillary and mandibular stability was discovered. The findings indicate that skeletal class III abnormality can be corrected surgically and orthodontically. With a surgery-first strategy, the post-operative skeletal stability is related to the surgical change rather than the surgical occlusal contact [19].

This finding of skeletal stability is also documented in a research done by **Hwang et al. (2020)[35]** that conducted a prospective comparative study evaluating the skeletal stability of two-jaw surgery via surgery-first approach with conventional two-jaw surgery in facial asymmetry patients with a conclusion of when traditional double jaw surgery was compared with surgery-first double jaw surgery, similar outcomes in the postoperative skeletal stability were seen. Additionally, a shorter typical treatment time was noted.

These findings are highly coincided with our results as presented in the Pairwise comparison between follow up time points regarding skeletal measurements there is a significant difference between the presurgical and postsurgical skeletal measurements (T0 and T1), while there is no significant difference between the postsurgical and post bonding skeletal measurements (T1 and T2) which indicates a good skeletal stability obtained during the whole treatment duration.

Thus, the null hypothesis of this study was rejected, as the surgery-first orthognathic approach showed excellent bony structure

stability in skeletal deformity correction and a shorter whole treatment plan was present in all the patients included the sample of the study.

CONCLUSION

Within the scope of the results of this research, Surgery first orthognathic approach is highly reliable for multiple skeletal deformities correction, as it has direct and rapid bony modification, it has proven to show satisfactory results and elevated acceptance with excellent skeletal stability and time saving approach. Overcoming the main drawbacks of conventional orthognathic surgery concerning the long duration of the whole treatment period due to presurgical teeth preparation phase and worsening the facial appearance which may be disappointing to many patients during this phase.

Further studies regarding SFOA are needed for another variety of skeletal deformities to be managed by this approach such as segmented maxillary surgeries, the cases in which extraction of the premolars is required and anterior openbite patients.

REFERENCES

1. Reyneke J. Essentials of orthognathic surgery. Quintessence Publishing, Carol Stream, Ill, USA; 2003.
2. Vadgaonkar V, Gangurde P, Deshmukh V, Shah A. Orthodontic and surgical perspectives in management of a severe skeletal open bite. Case Rep Dent. 2014;2014:bcr2013200069.
3. Liu Z, McGrath C, Hägg U. The impact of malocclusion/orthodontic treatment need on

the quality of life: a systematic review. *Angle Orthod.* 2009;79(3):585-91.

4. Jose Cherackal G, Thomas E, Prathap A. Combined orthodontic and surgical approach in the correction of a class III skeletal malocclusion with mandibular prognathism and vertical maxillary excess using bimaxillary osteotomy. *Case Rep Dent.* 2013;2013:797846.

5. Sabri R. Orthodontic objectives in orthognathic surgery: state of the art today. *World J Orthod.* 2006;7(2).

6. Patel PK, Novia MV. The surgical tools: the LeFort I, bilateral sagittal split osteotomy of the mandible, and the osseous genioplasty. *Clin Plast Surg.* 2007;34(3):447-75.

7. Proffit WR, Turvey TA, Phillips C. The hierarchy of stability and predictability in orthognathic surgery with rigid fixation: an update and extension. *Head Face Med.* 2007;3(1):1-11.

8. Farronato G, Maspero C, Giannini L, Farronato D. Occlusal splint guides for presurgical orthodontic treatment. *J Clin Orthod.* 2008;42(9):508-12.

9. Di Palma E, Gasparini G, Pelo S, Tartaglia GM, Sforza C. Activities of masticatory muscles in patients before orthognathic surgery. *J Craniofac Surg.* 2010;21(3):724-6.

10. Lee R. The benefits of post-surgical orthodontic treatment. *Br J Orthod.* 1994;21(3):265-74.

11. O'Brien K, Wright J, Conboy F, Appelbe P, Bearn D, Caldwell S, et al.

Prospective, multi-center study of the effectiveness of orthodontic/orthognathic surgery care in the United Kingdom. *Am J Orthod Dentofacial Orthop.* 2009;135(6):709-14.

12. Larson BE. Orthodontic preparation for orthognathic surgery. *Oral Maxillofac Surg Clin.* 2014;26(4):441-58.

13. Sun B, Tang J, Xiao P, Ding Y. Presurgical orthodontic decompensation alters alveolar bone condition around mandibular incisors in adults with skeletal Class III malocclusion. *Int J Clin Exp Med.* 2015;8(8):12866.

14. Luther F, Morris D, Hart C. Orthodontic preparation for orthognathic surgery: how long does it take and why? A retrospective study. *Br J Oral Maxillofac Surg.* 2003;41(6):401-6.

15. Diaz PM, Garcia RG, Gias LN, Aguirre-Jaime A, Pérez JS, de la Plata MM, et al. Time used for orthodontic surgical treatment of dentofacial deformities in white patients. *J Oral Maxillofac Surg.* 2010;68(1):88-92.

16. Hernández-Alfaro F, Guijarro-Martínez R, Molina-Coral A, Badía-Escriche C. "Surgery first" in bimaxillary orthognathic surgery. *J Oral Maxillofac Surg.* 2011;69(6):e201-e7.

17. Nagasaka H, Sugawara J, Kawamura H, Nanda R. "Surgery first" skeletal Class III correction using the Skeletal Anchorage System. *J Clin Orthod.* 2009;43(2):97-105.

18. Villegas C, Uribe F, Sugawara J, Nanda R. Expedited correction of significant

dentofacial asymmetry using a “surgery first” approach. *J Clin Orthod.* 2010;44(2):97-103.

19. Lo S, Chen Y-A, Yao C-F, Liao Y-F, Chen Y-R. Is skeletal stability after bimaxillary surgery for skeletal class III deformity related to surgical occlusal contact? *Int J Oral Maxillofac Surg.* 2019;48(10):1329-36.

20. Rosner B. Fundamentals of biostatistics. 8th ed. Boston, Massachusetts: Cengage Learning; 2015.

21. Fish LC, Epker BN, Sullivan CR. Orthognathic surgery: the correction of dentofacial deformities. *J Oral Maxillofac Surg.* 1993;51(1):28-41.

22. Liou EJ, Chen PH, Wang YC, Yu CC, Huang CS, Chen YR. Surgery-first accelerated orthognathic surgery: orthodontic guidelines and setup for model surgery. *J Oral Maxillofac Surg.* 2011;69(3):771-80.

23. Hunsuck EE. A modified intraoral sagittal splitting technic for correction of mandibular prognathism. *J Oral Surg.* 1968;26:250-3.

24. Epker BN. Modifications in the sagittal osteotomy of the mandible. *J Oral Surg.* 1977;35:157-9.

25. Borges TM, Sol I, de Castro Rodrigues CM, Peres Lima FGG, Silva CJ, Furtado LM. Surgery First Approach in Orthognathic Surgery - Considerations and Clinical Case Report. *Ann Maxillofac Surg.* 2021;11(2):349-51.

26. Park KR, Kim SY, Park HS, Jung YS. Surgery-first approach on patients with temporomandibular joint disease by intraoral

vertical ramus osteotomy. *Oral Surg Oral Med Oral Pathol Oral Radiol.* 2013;116(6):e429-36.

27. Chin SJ, Wilde F, Neuhaus M, Schramm A, Gellrich NC, Rana M. Accuracy of virtual surgical planning of orthognathic surgery with aid of CAD/CAM fabricated surgical splint-A novel 3D analyzing algorithm. *J Craniomaxillofac Surg.* 2017;45(12):1962-70.

28. Lin HH, Chang HW, Lo LJ. Development of customized positioning guides using computer-aided design and manufacturing technology for orthognathic surgery. *Int J Comput Assist Radiol Surg.* 2015;10(12):2021-33.

29. Pagotto LEC, de Santana Santos T, de Vasconcellos SJA, Santos JS, Martins-Filho PRS. Piezoelectric versus conventional techniques for orthognathic surgery: Systematic review and meta-analysis. *J Craniomaxillofac Surg.* 2017;45(10):1607-13.

30. Olate S, Sigua E, Asprino L, de Moraes M. Complications in Orthognathic Surgery. *J Craniofac Surg.* 2018;29(2):e158-e61.

31. Cao Y, Zhou Y, Li Z. Surgical-orthodontic treatment of Class III patients with long face problems: a retrospective study. *J Oral Maxillofac Surg.* 2009;67(5):1032-8.

32. Huang H, Williams RC, Kyrkanides S. Accelerated orthodontic tooth movement: molecular mechanisms. *Am J Orthod Dentofacial Orthop.* 2014;146(5):620-32.

33. Baek S-H, Ahn H-W, Kwon Y-H, Choi J-Y. Surgery-first approach in skeletal class III malocclusion treated with 2-jaw surgery: evaluation of surgical movement and

postoperative orthodontic treatment. *J Craniofac Surg.* 2010;21(2):332-8.

34. Yang L, Xiao Y-d, Liang Y-j, Wang X, Li J-y, Liao G-q. Does the surgery-first approach produce better outcomes in orthognathic surgery? A systematic review and

meta-analysis. *J Oral Maxillofac Surg.* 2017;75(11):2422-9.

35. Hwang DS, Seo JS, Choi HS. Skeletal stability after 2-jaw surgery via surgery-first approach in facial asymmetry patients using CBCT. *Maxillofac Plast Reconstr Surg.* 2020;42(1):1-8.