



## Evaluation of Immediate Versus Delayed Implant Insertion with Flapless Piezotome Ridge Splitting for Rehabilitation of Patients with Narrow Alveolar Ridge

Ahmed Gamal A. Kasim<sup>\*1</sup>, Ashraf Abdelfattah<sup>1</sup>, Hosam El-Dein M. Ali<sup>1</sup>, Mohamed Mahgob Al-Ashmawy<sup>1</sup>, Abdel Aziz Baiomy Abdullah<sup>1</sup>, Zein Abdou Shatat<sup>2</sup> Mohamed Ashraf Abdel Fattah<sup>3</sup>

Codex : 15/2024/04

Aadj@azhar.edu.eg

### KEYWORDS

*Immediate implant,  
delayed implant,  
flapless ridge splitting ,  
narrow alveolar ridge*

### ABSTRACT

**Aim:** The aim of this study was to evaluate the immediate implant placement versus delayed implant placement 3 months later of the splitting of thin alveolar bone sites using flapless crest splitting technique. **Subjects and Methods:** This study was designed as a prospective clinical trial of 35 implants over 8 patients with 16 alveolar splitting sites. Eight sites were splitted and immediately implanted and submitted to group I, the another eight sites were splitted and implanted after 3 months they were submitted to group II, After alveolar ridge splitting both groups were grafted via xenografts and covered with collagen membranes for guided bone regeneration (GTR). For both groups we clinically assessed insertion torque, Implant stability quotient (ISQ) and radiographically horizontal bone gain and bone density at 3 intervals postoperatively, 3 and 6 months. **Results:** The mean ISQ and insertion torque  $\pm$  SD in group II was higher than group I. Group I showed a higher increase in bone gain than group II. **Conclusion:** Immediate implantation after piezotome ridge splitting can be a useful procedure in ridges which have low bone quality and a thin cortex. Delayed implantation after piezotome ridge splitting is recommended when the initial stability of the implants is predicted to be poor. Both techniques using piezotome alveolar ridge splitting are effective in avoiding adjacent nerve injury.

### INTRODUCTION

Narrow and atrophic dentoalveolar ridge (which is  $\leq 4$ mm thickness) is a serious challenge for the successful placement of dental implants<sup>1-5</sup>. Resorption of alveolar bone occurs consequent to tooth loss, as a result of physiologic healing<sup>6-7</sup>. Ridge healing patterns following tooth removal result in more rapid bone resorption on the buccal than on the lingual/palatal aspects of the ridge. Between 40-60% of labial bone is lost during the first 3 years and this lost continues at an annual rate of 0.25-0.5% thereafter<sup>8-10</sup>. The pattern of resorption often results in a residual knife edge and a palatally or lingually shifted ridge apex, with

1. Department of Oral and Maxillo-facial Surgery, Faculty of Dental Medicine, Boys, Assiut, Al-Azhar University
2. Department of Oral and Maxillo-facial Radiology, Faculty of Dentistry, Assiut University, Assiut, Egypt.
3. Department of Oral and Maxillo-facial Surgery-Ahram Canadian University.

\* Corresponding Author e-mail: dragaq1986@gmail.com.

frail and thin labial cortex<sup>11</sup>. The estimated structural loss is about 60% of pre-extraction alveolar ridge width<sup>12</sup>. As minimum thickness of 1–1.5 mm of bone should remain on both buccal and lingual/palatal aspects of the dental implants to ensure a successful treatment outcome<sup>1-5</sup>. Several techniques, such as guided bone regeneration, bone block grafting, horizontal dentoalveolar ridge distraction and ridge splitting may be applicable for bone expansion<sup>13</sup>. Nowadays, the increased tendency to receive the minimal invasive treatments has made the use of novel medical and dental techniques inevitable<sup>14,15</sup>. Piezoelectric ridge-splitting procedure provides a quicker method in which an atrophic ridge can be predictably expanded and grafted, and it eliminates the need for a second donor surgical site for harvesting autogenously bone<sup>1-4</sup>.

Subsequent to dentoalveolar ridge expansion, most surgeons prefer immediate dental implant placement for preservation of the gained bone thickness expansion and for time saving issues<sup>16-18</sup>, unfortunately Scarano<sup>19</sup> et al reported many complications of immediate implant placement after ridge splitting. Also Ziad and Angelo Troedhan<sup>20</sup> et. al. reported (That delayed ridge splitting allowed a predictable and safer increase in crestal bone width without compromise of the vascular supply of the bone flap and with no necrosis after implant placement and during bone healing comparable to the single stage flapless piezotome crest split<sup>20</sup>).

Eid<sup>21</sup> et al. demonstrated a favorable outcome of the staged ridge splitting and expansion approach in the rehabilitation of atrophic narrow edentulous posterior mandiblar area. All this previous studies of Scarano<sup>19</sup> et al, Ziad and Angelo Troedhan<sup>20</sup> et. al. and Eid<sup>21</sup> et al. , that favors delayed implant placement after ridge splitting procedure encouraged us to perform a study comparing implant placement immediately after piezoelectric dentoalveolar ridge splitting versus three months delayed implantation after splitting procedure.

## PATIENTS AND METHODS

This study was designed as a prospective randomized clinical trial of 35 implants over 8 patients with 16 alveolar splitting sites. Eight sites were splitted and immediately implanted and submitted to group I, the another eight sites were splitted and implanted after 3 months; they were submitted to group II.

**Ethics statement:** this study followed all methods of declarations of Helsinki for research involving human subjects and was reviewed and approved by the institutional reviewer bared of Al-Azhar university, school of Dentistry (Assiut branch).informed written consent was obtained from all patients included in the study.

### Surgical phase:

#### *Patient's preparation*

Before surgery, patients were asked to gargle with chlorhexidine 0.2% mouthwash (Oralden®) for about 1 minute, this was followed by circumoral scrubbing by gauze soaked in Povidone-Iodine solution 10% (Betadine®) and draped with sterile surgical drapes.

#### *Anesthesia:*

Local anesthesia was administered using 4% Articaine / adrenaline 1:100,000 1. 8ml Artinibsa cartilage.

**Incision and Flap design:** A bard parker blade No 15 was used to create a full thickness crestal mesio-distal incisional bocklet flap was made to expose crestal alveolar ridge of proposed splitting and implant sites, a conservative envelope flap elevation extending slightly beyond the alveolar crest to reduce flap morbidity and allow primary wound closure. In few cases additional small mesial and distal vertical releasing flaps were performed for more elucidation of the alveolar ridge crest fig (12B).



The Flapless Piezotome crest splitting (FPCS) technique:

A custom surgical guide fixed on the alveolar ridge (Fig 1 C) which fabricated according to the patient own CBCT fig (1 A). Demarcations of implant sites were performed with the initial drill till the full length of final implant. Removing of the surgical guide. A vertical mesiodistal mucoperiosteal incision and dissection only of the very top of the narrow alveolar crest (booklet flap; Fig 1 B), followed by a vertical mesiodistal osteotomy with crest split tip no. 1 (CS1) for the piezotome (Acteon; Fig 1D) to a depth lesser than the final implant by 2mm length. An initial horizontal distraction was performed using the CS2 tip for the piezotome Next, 90° buccal relief osteotomies were placed at the distal and mesial end of the mesiodistal vertical osteotomy line to prevent accidental fractures of the buccal bone segment during horizontal distraction using the CS3 tip from inside to outside the osteotomy. Horizontal distraction was then implemented using the CS4, CS5, and CS6 tips for the piezotome to reach a distraction gap width of 4 to 5 mm (Fig. 1 E).

#### **Group (I) FPCS with simultaneous implant placement:**

Splitting sites supplemented by simultaneous implant placement into their ridges. This was by drilling to the full length of the implant by the sequenced drills of Neobiotech system and implants placed. Guided bone regeneration (GBR) had been performed after implants placement, by crest site augmentation with xenograft (One Graft® cortico-cancellous graft, Germany). Implant stability had measured using OSSTEL and smart pegs (Fig 1 J,k). Covering the splitted crest and xenograft and implants with resorbable membrane (Hypro-sorb®, Germany). CBCT examinations were performed (pre-operatively, 3months and 6 months) postoperatively for comparing crest width and bone density in all this periods between group I and group II.

#### **Group (II) FPCS with 3 months delayed implant placement:**

We performed the same steps of CBCT examination of group I for all patients of group II. CBCT of the case in fig (1F). The same procedures of disinfection scrubbing, anesthesia and sequenced crest splitting as group I cases for cases of group II (fig.1 B, D and E). The difference in procedures between group I and group II started after completing splitting and GBR. We delayed implantation after 3 months (healing of bone splitting period). Guided bone regeneration (GBR) had been performed simultaneously after splitting by crest site augmentation with xenograft (One Graft® cortico-cancellous graft, Germany). Covering the splitted crest and xenograft with resorbable membrane (Hypro-sorb®, Germany). After 3 months, CBCT examination was performed (fig.1F). We measured alveolar crest width and length for determination of the appropriate implants. Incision had been made. Via assistance of a second CBCT taken at 3month a surgical guide was manufactured (fig.1H). Sequenced drilling of Neobiotech implant system and implants placement had been performed (fig.1H and I). We measured Initial stability by OSSTEL device (fig.1 J and K).

#### **Follow up and data collection**

##### ***I. Clinical parameters***

###### ***1. Implant stability quotient (ISQ):***

All implants were evaluated for primary stability once after implant insertion with an Osstell® a magnetic resonance device, which used resonance frequency analysis for determining implant stability post implantation and after 3months and another measurement after six months at second surgical phase.

##### ***II. Radiographic parameters***

###### ***1. Measuring of horizontal bone gain & loss:***

The reference-plane for horizontal bone gain measurement was determined by the bone-level

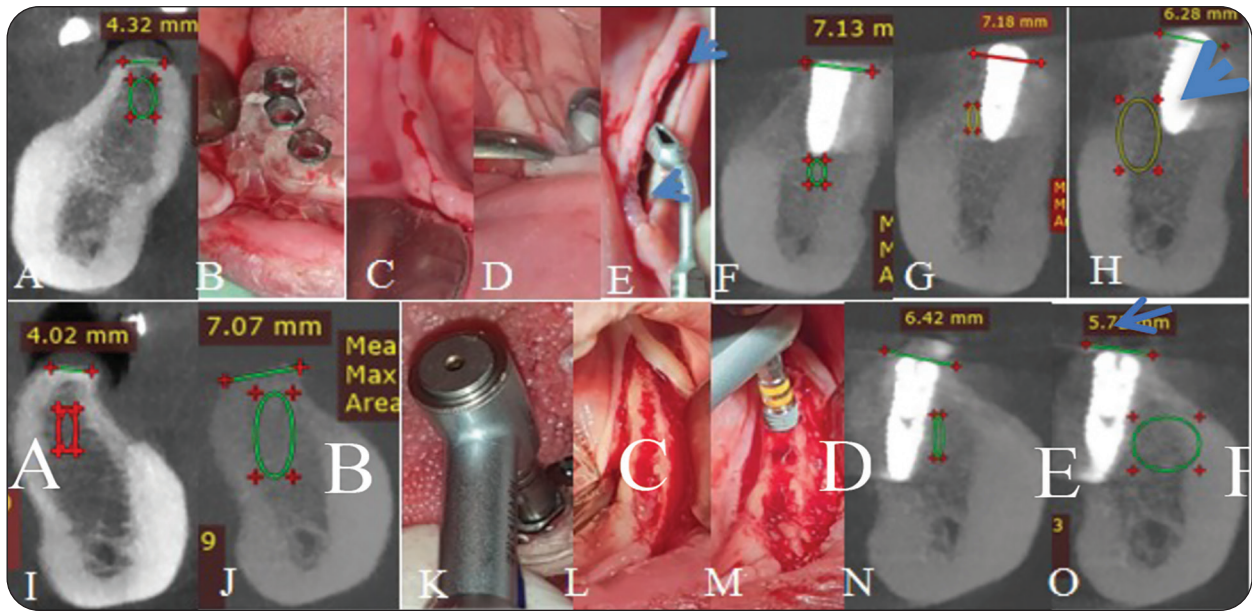


Fig. (1) Surgical procedures: A: pre-op. CBCT, B: Surgical guide. C: flapless incision, D: 1st Crest splitting via CS1 tip, E: final crest splitting tip CS.6. F: group I postop. CBCT, G: 3 months postoperative CBCT, H: 6 month post op. CBCT, For group II. I: Pre-op. CBCT. J: 3m post splitting. K: Implant position demarcation via custom made surg. Guide, L: alveolar bone clinical shape 3 months post splitting, M: implant insertion 3m post splitting. N: 3m post-splitting post-implantation CBCT, O: 6 month post-splitting CBCT.

crestal plane of inserted implants in cross sectional view of CBCT. From this reference-plane both buccal and lingual bone level of each implant was measured in millimeters on the day of implant placement (immediate) and on follow-up visits at postoperative, 3 and 6 months

## 2. Measuring of bone density:

By using of RDIANT DICOM VIEWER (software), change in bone density around implant was calculated in gray scale units. The positions of measurement sites were located at the top, middle and apical part of implant on buccal, lingual, mesial and distal sides.

## Statistical analysis:

Data were fed to computer and analyzed using IBM SPSS software package version 26.0. (Armonk, NY: IBM Corp).

## RESULTS

### 1. ISQ reading

Regarding Initial ISQ there was statistically significant difference between groups ( $p < 0.001^*$ ).

**Table (1)** Comparison between two studied groups according to ISQ mean reading.

	Group I	Group II	t. test	Pvalue
Initial	41.62 ±2.26	65.00 ±1, 69	23.40	<0.001*
At 3 months	69.00 ±4.00	70.88 ±4.70	0.85	0.40
At 6 months	73.88 ±5.22	76.12 ±5.05	0.87	0.39
Increase nom Initial				
At 3 months	27138 ±2.77	5.88 + 3.27	14.17	<0.001*
At 6 months	32.26 ±4.68	11.12 +	10.07	<0.001*

Data was expressed using Mean ± SD.

t: Student t-test



Group II showed statistically significant higher ISQ reading than group I. After 3 months, there was statistically non-significant difference between groups ( $p < 0.40$ ).

However the increase ISQ from initial was statically significant ( $p < 0.001^*$ ) group I ISQ reading was with higher increasing rate than group II. After 6 months, there was statistically non-significant difference between groups ( $p = 0.39$ ), however the increase ISQ from initial was statically significant ( $p < 0.001^*$ ). group I ISQ reading was with higher increasing rate than group II.

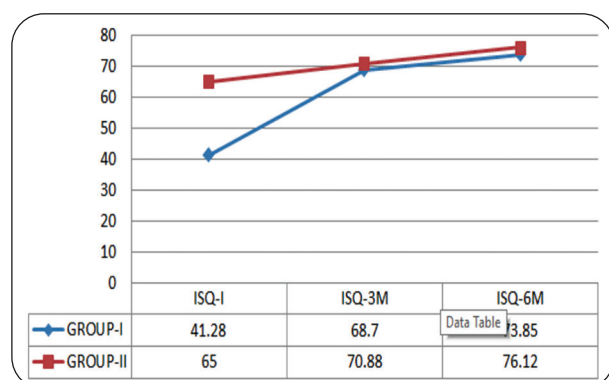


Fig. (2) Comparison between mean ISQ reading in different periods in each group.

## II. Radiographic parameters:

### 1. Measuring of horizontal bone gain & loss:

Regarding Initial, Postoperative, after 3 months there was statistically significant difference between groups ( $p = 0.041, 0.034$  respectively). After 6 months there was statistically non-significant difference between groups ( $p = 0.20$ ). Regarding Increase from Initial, there was statistically a significant difference. Group I showed higher

Increase from Initial than Group II, Postoperative and after 3 months were having statically significant differences ( $p = 0.048^*, 0.033^*$ ).

### 2. Measuring of bone density:

Regarding Initial, After 3 months and After 6 months there was statistically non-significant

difference between groups ( $p = 0.27, (p = 0.16)$  and ( $p = 0.82$ ). Group I showed higher density than group II.

**Table (2)** Comparison between two studied groups according to horizontal bone gain in CBCT.

	Group I	Group II	t. test	P value
Initial	4.04±0.13	4.01±0.14	0.434	0.67
Postoperative	7.47±0.95	6.45±0.85	2.249	0.041*
After 3 months	7.03±1.04	6.01±0.62	2.37	0.034*
After 6 months	6.47 ± 1.03	6.00±0.47	1.36	0.20
Increase from Initial				
Postoperative	3.43±0.96	2.44±0.87	2.16	0.048*
After 3 months	2.99±1.02	2.00±0.53	2.44	0.033*
After 6 months	2.43±1.02	1.99±0.38	1.32	0.219

Data was expressed using Mean SD. t: Student-t-test

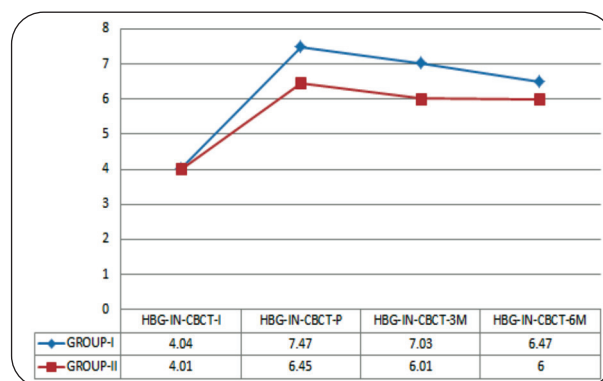


Fig. (3) Comparison between different periods in each group according to Horizontal bone gain in CBCT reading

**Table (3)** Comparison between two studied groups according to density.

	Group I	Group II	t. test	P value
Initial	667.2±274.8	543.1±115.8	1.18	0.27
Postoperative	7969±231	647.8±161.3	1.50	0.16
After 3 months	845.8±233	688.5±150	1.61	0.13
After 6 months	860.3±233.9	727.1±144.3	0.24	0.82
Increase from Initial				
Postoperative	129.7±68.4	104.7±99.6	0.59	0.57
After 3 months	178.6 ± 72.9	145.4±98.3	0.77	0.45
After 6 months	193.1±73.4	184±96.4	0.21	0.83

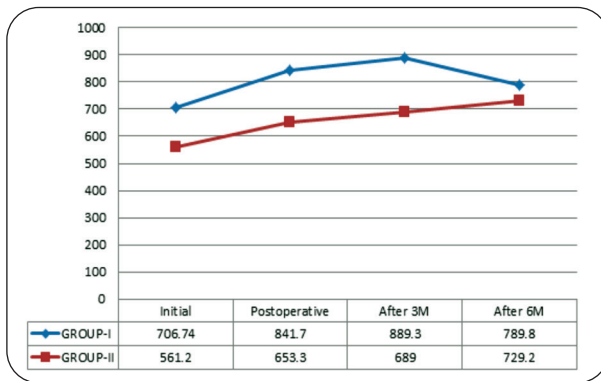


Fig. (4) Comparison between different periods in each group according to Bone densities reading.

## DISCUSSION

In our present study we had evaluated immediate implantation after alveolar ridge piezotome splitting and expansion versus 3 month delayed implantation after piezotome alveolar ridge splitting.

In our current study, ridge splitting was accompanied with immediate implant placement which originally was reported by **Summers**<sup>22</sup> that gave an advantage of the fact that bone was viscoelastic, compressed and can be manipulated. **Simion et al.**<sup>23</sup> had been agreed this technique which gave the same survival rate as two-steps split ridge expansion and shorten total treatment time to eliminate second surgical procedure morbidity<sup>24</sup>. **Sohn D S et al.**<sup>18</sup> had been worried of that there was a higher risk of malfracture of osteotomized bone segments, especially in mandible with a lack of initial stability for implants, and a compromised implant placement in buccolingual and apico-coronal directions.

In our present study, immediate implantation after splitting (group I) showed a statistically significant difference at ISQ reading than 3 month delayed implantation after ridge splitting (group II) at initial intra operative phase ( $p < 0.001$ ), after 3 and 6 months, there was statistically non-significant difference between groups ( $p = .40$  and  $.39$  respectively), where delayed implantation (group

II) showed a statistically a significant higher in ISQ reading than immediate ridge splitting group. Delayed implantation (group II) group was shown to enhance implant primary stability, due to implant insertion in already healed mineralized vital bone increasing bone-to-implant contact (BIC) upon implant placement in group II<sup>25</sup>. However in group I we inserted implant catching only apical few millimeters circumferentially and the last coronal part of fixture only touched buccal and lingual plates and newly inserted bone graft which healed together after that<sup>26-28, 29</sup>.

In our present study, according to insertion torque parameter there was statistically significant difference between two groups ( $p < 0.001^*$ ). Group I (Immediate implantation after piezotome ridge splitting) had showed statistically significant lower insertion torque than group II (3 month delayed implantation after piezotome ridge splitting). This was in agreement with **Blus C et. al.**<sup>30</sup>, **Sethi A et. al.**<sup>31</sup>, **Enislidis G et. al.**<sup>32</sup> and **Chauhan H et. al.**<sup>33</sup> who had compared immediate with late implantation after alveolar ridge splitting, and reported that late implantation had got higher insertion and removal torque, increased primary and secondary stability, higher bone-to-implant contact (BIC) and higher bone volume around implants, this favorable outcome was possible because of increasing bone-to-implant contact (BIC) upon implant placement in group II, However in group I we inserted implant catching only apical few millimeters circumferentially and the last coronal part of fixture only touched buccal and lingual plates and newly inserted bone graft which healed together after that.

In Comparison between two studied groups according to horizontal bone gain at CBCT there was a higher increase in ridge splitting group I than group II regarding postoperative and three months reading there were statically significant difference ( $p = 0.041$  and  $p = .34$ ). While at six months post operatively there was no significant difference between two groups regarding bone gain at CBCT ( $p = 0.20$ ). This results was in agreement with **Sohn D S et. al.**<sup>18</sup>



in 2010 and Chauhan H et. al.<sup>33</sup> in 2020 who had compared ridge splitting techniques with immediate and delayed implant placement and particulate bone graft they had got  $3.5 \pm 1.5$  mm gain in bone width.

In Comparison between two studied groups regarding bone density, we had observed that there was statistically non- significant difference between groups at initial reading ( $p=0.27$ ), postoperative ( $p=0.16$ ), 3 months ( $p=0.13$ ) and 6 months ( $p=0.82$ ). This finding was in agreement with ABDELSAMEAA et. al.<sup>34</sup> who perform a study at 2021 for evaluation of delayed Split Expansion technique for horizontal augmentation of narrow mandibular alveolar ridge for implant placement without Guided Bone Regeneration.

This result may be explained due to high bone to implant contact in group II and elasticity of cancellous bone, while in ridge splitting group I implant gained its primary stability from apical 2mm and the remaining part was surrounded by grafted bone mixed with growth factors and dynamic process that involved bone tissue modeling and remodeling .This was in agreement with Botticelli D et. al.<sup>35</sup> and Berglundh et al<sup>36</sup>.

## CONCLUSION

1. Results both groups had suggested that immediate and late implantation after piezotome ridge splitting were a successful methods for narrow alveolar bone expansion.
2. Late implantation after piezotome ridge splitting was demonstrated to be able to increase ridge width with more successful implant primary stability and bone density around dental implants without bone sacrificially. Especially in cases that have a prediction of buccal or lingual plate fracture delayed implantation is more preferred in this case.
3. Immediate implantation after piezotome ridge splitting can be a useful procedure in ridges which have low bone quality and a thin cortex.
4. Delayed implantation after piezotome ridge splitting can be used more safely and predictably in patients with high bone quality and a thick cortex and narrower ridges to avoid complete fracture of the buccal segments.
5. Delayed implantation after piezotome ridge splitting is recommended when the initial stability of the implants is predicted to be poor.
6. Both techniques using piezotome alveolar ridge splitting are effective in avoiding adjacent nerve injury.

## REFERENCES

1. Kelly A, Flanagan D. Ridge expansion and immediate placement with piezosurgery and screw expanders in atrophic maxillary sites: two case reports. *J Oral Implantol* 2013;39:85-90.
2. Moro A, Gasparini G, Foresta E, et al. Alveolar Ridge Split Technique Using Piezosurgery with Specially Designed Tips. *Biomed Res Int*;2017:4530378.
3. Pavlikova G, Foltan R, Horka M, Hanzelka T, Borunska H, Sedy J. Piezosurgery in oral and maxillofacial surgery. *Int J Oral Maxillofac Surg*2010;40:451-457.
4. Pereira CC, Gealh WC, Meorin-Nogueira L, Garcia-Junior IR, Okamoto R. Piezosurgery applied to implant dentistry: clinical and biological aspects. *J Oral Implantol*2014;40 Spec No:401-408.
5. Stricker A, Stubinger S, Voss P, Duttenhoefer F, Fleiner J. The bone splitting stabilisation technique--a modified approach to prevent bone resorption of the buccal wall. *Oral Health Dent Manag*2014;13:870-876.
6. Loeb I, Cuvelliez F, Putz M. [Resorption of the alveolar ridge following tooth extraction and the placement of immediate prostheses]. *Acta Stomatol Belg* 1985;82:111-115.
7. Pietrokovski J, Massler M. Alveolar ridge resorption following tooth extraction. *J Prosthet Dent* 1967;17:21-27.
8. Mecall RA, Rosenfeld AL. Influence of residual ridge resorption patterns on implant fixture placement and tooth position. 1. *Int J Periodontics Restorative Dent* 1991;11:8-23.
9. Mecall RA, Rosenfeld AL. Presurgical determination of prosthesis type and design. *Int J Periodontics Restorative Dent* 1992;12:32-51.

10. Mecal RA, Rosenfeld AL. Influence of residual ridge resorption patterns on fixture placement and tooth position, Part III: Presurgical assessment of ridge augmentation requirements. *Int J Periodontics Restorative Dent* 1996;16:322-337.
11. Schropp L, Kostopoulos L, Wenzel A. Bone healing following immediate versus delayed placement of titanium implants into extraction sockets: a prospective clinical study. *Int J Oral Maxillofac Implants* 2003;18:189-199.
12. Shahakbari R, Eshghpour M, Mianbandi V, et al. The Comparison of Utilizing Piezotome and Surgical Disc in Ridge Splitting of Atrophic Edentulous Maxillary Ridge. *J Maxillofac Oral Surg* 2020;19:374-379.
13. Bassetti MA, Bassetti RG, Bosshardt DD. The alveolar ridge splitting/expansion technique: a systematic review. *Clin Oral Implants Res* 2015;27:310-324.
14. Zakhary IE, El-Mekkawi HA, Elsantny ME. Alveolar ridge augmentation for implant fixation: status review. *Oral Surg Oral Med Oral Pathol Oral Radiol* 2013;114:S179-189.
15. Gonza ´lez-Garcı ´a R, Monje F, Moreno C. Alveolar split osteotomy for the treatment of the severe narrow ridge maxillary atrophy: a modified technique. *Int J Oral Maxillofac Surg* 2011;40(1):57-64
16. Demetriades N, Park JI, Laskarides C. Alternative bone expansion technique for implant placement in atrophic edentulous maxilla and mandible. *J Oral Implantol* 2010; 37(4):463-471
17. Sohn D-S, Lee H-J, Heo J-U, Moon J-W, Park I-S, Romanos GE. Immediate and delayed lateral ridge expansion technique in the atrophic posterior mandibular ridge. *J Oral Maxillofac Surg* 2010; 68(9):2283-2290
18. Scarano A, Piattelli A, Murmura G, Iezzi G, Assenza B, Mancino C. Delayed expansion of the atrophic mandible by ultrasonic surgery: a clinical and histological case series. *Int J Oral Maxillofac Implants*. 2015; 30: 144-9
19. Mahmoud, Z. T., Wainwright, M., & Troedhan, A. Flapless Piezotome Crest Split Achieves Comparable Outcomes to Autologous Onlay Grafts With Significant Less Patient Morbidity and Complications — A Randomized Clinical Study. *Journal of Oral Maxillofacial Surgery* 2020; 1-12. <https://doi.org/10.1016/j.joms.2020.06.008>
20. Eid, A., Noureldin, M., & Elsheikh, S. Evaluation of Bone Width Change Using a Two-Stage Ridge Splitting Approach in Narrow Posterior Mandibular Ridge (Clinical Trial). *Alexandria Dental Journal* 2022;0(0), 0-0. <https://doi.org/10.21608/adjalexu.2020.45441.1112>.
21. Summers RB. A new concept in maxillary implant surgery: the osteotome technique. *Compendium*. 1994;15(2):152, 4-6, 8 passim; quiz 62.
22. Simion M, Baldoni M, Zaffe D. Jawbone enlargement using immediate implant placement associated with a split-crest technique and guided tissue regeneration. *Int J Periodontics Restorative Dent*. 1992;12(6):462-73.
23. Mounir M, Beheiri G, El-Beialy W. Assessment of marginal bone loss using full thickness versus partial thickness flaps for alveolar ridge splitting and immediate implant placement in the anterior maxilla. *Int J Oral Maxillofac Surg*. 2014;43(11):1373-80.
24. Buser D, Ingimarsson S, Dula K, Lussi A, Hirt HP, Belser UC. Long-term stability of osseointegrated implants in augmented bone: a 5-year prospective study in partially edentulous patients. *Int J Periodontics Restorative Dent*. 2002;22(2):109-17.
25. Mistry G, Shetty O, Shetty S, Singh R. Measuring implant stability: A review of different methods. *Journal of Dental Implants*. 2014;4(2):165-9.
26. Atsumi M, Park S-H, Wang H-L. Methods used to assess implant stability: Current status. *The International journal of oral & maxillofacial implants*. 2007;22:743-54.
27. Alsaadi G, Quirynen M, Michiels K, Jacobs R, van Steenberghe D. A biomechanical assessment of the relation between the oral implant stability at insertion and subjective bone quality assessment. *J Clin Periodontol*. 2007;34(4):359-66.
28. Park KJ, Kwon JY, Kim SK, Heo SJ, Koak JY, Lee JH, et al. The relationship between implant stability quotient values and implant insertion variables: a clinical study. *J Oral Rehabil*. 2012;39(2):151-9.
29. Blus C, Szmukler-Moncler S, Vozza I, Rispoli L, Polastri C. Split-crest and immediate implant placement with ultrasonic bone surgery (piezosurgery): 3-year follow-up of 180 treated implant sites. *Quintessence Int*. 2010;41(6):463-9.
30. Sethi A, Kaus T: Maxillary ridge expansion with simultaneous implant placement: 5-Year results of an ongoing clinical study. *Int J Oral Maxillofac Implants*. 2000; 15:491.
31. Enislidis G, Wittwer G, Ewers R: Preliminary report on a staged ridge splitting technique for implant placement in the mandible: A technical note. *Int J Oral Maxillofac Implants*. 2006; 21:445.





32. Chauhan H, Lakshmi S, Aurora JK, Potlia I, Komal A, and Purohit N. Comparison between immediate vs. delayed lateral expansion technique to augment narrow alveolar ridges for placement of implants-A pilot study. *J Oral Biol Craniofac Res.* 2020;10(2):78-82.
33. ABDELSAMEEA, Sally; YOUSEF, Eman; MANSOUR, Noha. Evaluation of Delayed Split Expansion Technique for Horizontal Augmentation of Narrow Mandibular Alveolar Ridge for Implant Placement without Guided Bone Regeneration. *Egyptian Dental Journal*, 2021, 67.4: 2983-2994.
34. Botticelli D, Berglundh T, Lindhe J. Hard-tissue alterations following immediate implant placement in extraction sites. *Journal of Clinical Periodontology.* 2004;31(10):820-8.
35. Berglundh T, Abrahamsson I, Lang NP, Lindhe J. De novo alveolar bone formation adjacent to endosseous implants. *Clin Oral Implants Res.* 2003;14(3):251- 62.



## تقييم الغرسة الفورية مقابل المتأخرة مع شق حافة البيزوتوم الخالية من الدهون لإعادة تأهيل المرضى الذين يعانون من حافة سنخية ضيقة

احمد جمال قاسم\*1، اشرف عبدالفتاح محمود1، حسام الدين محمد على1، عبدالعزيز بيومي عبدالله1، محمد محجوب العشماوى1، زين الدين عبده شتات2، محمد اشرف عبدالفتاح3

1. قسم جراحة الفم والوجه والفكين، كلية طب الأسنان، جامعة الأزهرينين، أسيوط، مصر.
2. قسم اشعة الوجه والفكين، كلية طب الأسنان، جامعة أسيوط، مصر.
3. قسم جراحة الفم والوجه والفكين، كلية طب الأسنان، جامعة الأهرام الكندية، 6 أكتوبر، مصر.

\* البريد الإلكتروني: DRAGAQ1986@GMAIL.COM

### الملخص :

**الهدف:** كان الهدف من هذه الدراسة هو تقييم وضع الزرع الفوري مقابل وضع الزرع المتأخر بعد 3 أشهر من تقسيم مواقع العظام السنخية الرقيقة باستخدام تقنية تقسيم العرف بدون رفر.

**المواد والاساليب:** تم تصميم هذه الدراسة كتحريية سريرية مستقبلية لـ 35 عملية زرع على 8 مرضى لديهم 16 موقع تقسيم سنخي. تم تقسيم ثمانية مواقع وزرعها على الفور وتقديمها إلى المجموعة الأولى. وتم تقسيم المواقع الثمانية الأخرى وزرعها بعد 3 أشهر وتم تقديمها إلى المجموعة الثانية. وبعد انشقاق الحافة السنخية، تم تطعيم المجموعتين عن طريق طعم أجنبي وتغطيتها بأغشية الكولاجين لتجديد البونر الموجه. (جي تي آر). بالنسبة لكلا المجموعتين، قمنا بتقييم عزم دوران الغرسة. وحاصل ثبات الغرسة (ISQ) وكسب العظام الأفقي شعاعيًا وكثافة العظام على 3 فترات بعد العمل الجراحي. 3 و 6 أشهر.

**النتائج:** كان متوسط ISQ وعزم دوران الغرسة  $\pm$  SD في المجموعة الثانية أعلى من المجموعة الثانية. المجموعة الأولى أظهرت زيادة أعلى في اكتساب العظام مقارنة بالمجموعة الثانية.

**الخلاصة:** يمكن أن يكون الزرع الفوري بعد تقسيم نتوء البيزوتوم إجراءً مفيدًا في التلال ذات الجودة العظمية المنخفضة والقشرة الرقيقة. يوصى بتأخير عملية الزرع بعد انقسام سلسلة بيزوتومي عندما يكون من المتوقع أن يكون الاستقرار الأولي للزرعات ضعيفًا. كلتا التقنيتين اللتين تستخدمان تقسيم الحافة السنخية الانضغاطية فعالة في تجنب إصابة العصب الجوار.

**الكلمات المفتاحية :** زرع فوري، زرع متأخر، انقسام الحافة غير المسطحة، الحافة السنخية الضيقة