

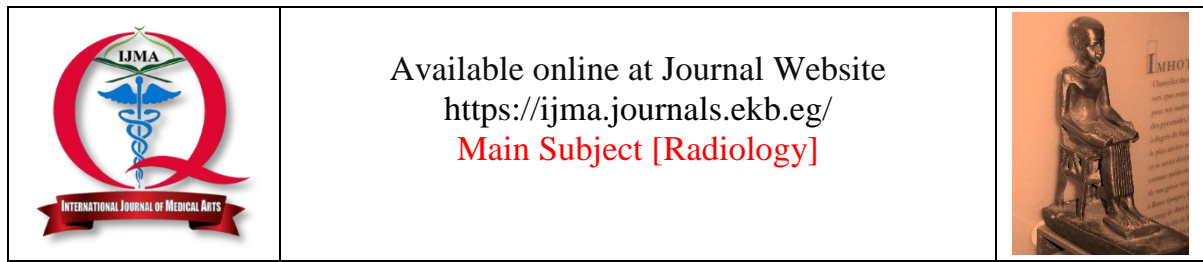
IJMA



INTERNATIONAL JOURNAL OF MEDICAL ARTS

VOLUME 6, ISSUE 5, MAY 2024

P- ISSN: 2636-4174
E- ISSN: 2682-3780



Available online at Journal Website
<https://ijma.journals.ekb.eg/>
 Main Subject [Radiology]



Original Article

Optimizing Cholesteatoma Assessment: Utilizing of Diffusion-Weighted Magnetic Resonance Imaging and Computed Tomography Imaging for Diagnostic Precision and Surgical Excellence

Yousef Mohamed Abd El-Aziz Ismail Hamroush ^{*1}, Ahmed Mohammed Fekry El-Deek ¹, Mohamed Hussein Abdelazim ², Mohamed Ashraf Abd El-Moneim Ali ¹

¹ Department of Radiodiagnosis, Damietta Faculty of Medicine, Al-Azhar University, Damietta, Egypt

² Department of Otorhinolaryngology, Damietta Faculty of Medicine, Al-Azhar University, Damietta, Egypt

ABSTRACT

Article information

Received: 29-03-2024

Accepted: 05-05-2024

DOI:
10.21608/IJMA.2024.280332.1951.

*Corresponding author

Email: josefazoz6@gmail.com

Citation: Hamroush YMAI, El-Deek AMF, Abdelazim MH, Ali MAA. Optimizing Cholesteatoma Assessment: Utilizing of Diffusion-Weighted Magnetic Resonance Imaging and Computed Tomography Imaging for Diagnostic Precision and Surgical Excellence. IJMA 2024 May; 6 [5]: 4410-4414. doi: 10.21608/IJMA.2024.280332.1951.

Background: Cholesteatoma is a sac-like growth inside the temporal bone that can cause bone disintegration and intracranial problems. CT is the preferred imaging method for diagnosis, but MRI is needed for better soft tissue resolution. Recurrent Cholesteatoma may require a second surgery for diagnosis. DW-MRI is a useful tool for studying Cholesteatoma.

Aim of the work: The current study evaluated the diagnostic performance of diffusion weighted magnetic resonance imaging [DW-MRI] and computed tomography [CT] in Cholesteatoma and the usefulness of DW-MRI in identifying residual or early recurrence from post-operative alterations.

Patients and Methods: A study was conducted at Al-Azhar University Hospital to assess patients with suspected Cholesteatoma. The study included 30 patients, both males and females, ranging in age from 15 to 60 years. Exclusion criteria included contraindications to MRI or CT examinations and recent middle ear surgery. The assessment of patients included a clinical examination and review of previous radiological examinations. CT imaging was performed using a multi-detector CT scanner, while 2-DW-MRI imaging was conducted using a 1.5 Tesla magnetic resonance scanner. Additional sequences were added to aid in anatomical localization.

Results: This study found that DWI MRI had 84.6% sensitivity and 100% specificity, while CT had 52% sensitivity and 60% specificity. The accuracy values of DWI MRI and CT were 86.66% and 53.33%, respectively.

Conclusion: Both DWI and CT can diagnose Cholesteatoma, however DWI MRI has a higher diagnostic rate than CT. Using both together delivers better results, accurate diagnosis, and better surgical guidance.

Keywords: Cholesteatoma; Middle Ear; Magnetic Resonance Imaging; Diffusion Weighted; Computed Tomography.



This is an open-access article registered under the Creative Commons, ShareAlike 4.0 International license [CC BY-SA 4.0] [<https://creativecommons.org/licenses/by-sa/4.0/legalcode>].

INTRODUCTION

A cholesteatoma is characterized by the development of a sac bordered by squamous epithelium that develops inside pneumatized portions of the temporal bone and includes collections of keratin debris. It might have been present from birth or developed later [congenital or acquired] of all cholesteatoma, only 2% are of the congenital form [1].

Early identification and detection are critical for effective treatment. This is related to the tumor's expansile growth capacity, as well as its erosive and destructive properties. This ultimately leads to the disintegration of the surrounding bones. As the illness progresses, it may cause facial nerve and inner ear injuries, as well as intracranial problems [such as meningitis and brain abscess]. These intracranial problems are accountable for the probable mortality linked with the illness [2].

The clinical aspects determine the diagnosis. Otoscopy and otomicroscopy are the foundations of diagnosis in conjunction with radiological results. The preferred imaging approach is computed tomography [CT] [3]. CT with spatial resolution allows for visualization of the tympanic cavity's bony components and walls. The CT results are extremely specific for the disorder and lead to an accurate diagnosis, particularly in cases of acquired cholesteatoma. However, the nature of soft tissues [e.g., inflammatory, granulation or scar tissue, cholesteatoma] could not be recognized due to the inferior tissue resolution of CT compared to MRI [4].

An imaging modality with a higher discrimination power of soft tissues, other than CT [for example MRI] is required to yield a higher diagnostic value for acquired cholesteatomas situated in atypical locations, cholesteatomas without clear bone erosions, and congenital cholesteatomas, where bone references are lost [5].

In tympanoplasties, there is no imaging technique that enables the diagnosis of recurrent cholesteatomas. It is evident mainly in closed tympanoplasties due to preservation of the posterior wall of the external ear canal. Thus, there is a need for a second surgery “second-look” for their diagnosis. This “second-look” is recommended to be done on a regular basis [6 mo. and 1 year] after closed tympanoplasty [6].

Diffusion weight imaging [DWI] is a specific type of MRI. Its mechanism is based on the detection of water molecule diffusion within tissues.

This can be measured using the "Apparent Diffusion Co-efficient [ADC]". Restricted diffusion is reflected by a low ADC value, and vice versa. Cholesteatoma induces diffusion limitation and is identified as a hyper intense focus on the DW sequence. DW-MRI is a useful imaging modality in the study of Cholesteatoma [7, 8].

The aim of this study is to evaluate diagnostic performance of DW-MRI along with CT in patients with cholesteatoma and importance of DWI in delineating residual or early recurrence of cholesteatoma from post-operative changes.

PATIENTS AND METHODS

We conducted this study between May 2023 and April 2024. The Department of Radio diagnosis at Al-Azhar University Hospital [New Damietta] completed it. It included 30 patients [18 males and 12 females]. Their ages ranged between 15 and 60 years. Clinical suspicion of Cholesteatoma exists in these patients.

Inclusion criteria included patients had a suspicion of Cholesteatoma, either a new one or a recurring one, and had symptoms like persistent or recurring discharge from the ear and gradual loss of hearing. The otoscopic examination revealed either a marginal tympanic membrane perforation or an attic retraction pocket, without any preference for age or gender.

Exclusion criteria included any contraindications to the use of MRI [e.g., metallic prosthesis, artificial pacemakers, or claustrophobic] or CT examination [e.g., pregnant females] and patients with recent middle ear surgery less than 6 months.

Ethical considerations: Our institution's local research and ethics committee reviewed and approved the study protocol number DFM-IRB00012367-23-11-002, approval date 25-11-2023. We obtained informed consent from all participants before including them in the study.

Methods: All patients were assessed clinically. The referred clinician achieved this assessment by inquiring about the patient's history, conducting a clinical examination, and reviewing the previous radiological examination. Additionally, we submitted all patients to the following:

1. CT Imaging: We completed an axial volume scan [section thickness of 0.67 mm, an increment of 0.67 mm, 120 Kv] with coronal and sagittal reformations [0.67 mm] parallel and perpendicular

to the lateral semi-circular canal on a 160-row multi-detector CT scanner [TOSHIBA Aquilion Prime].

2. DW-MRI Imaging: We performed 2-DW-MRI imaging on a 1.5 Tesla magnetic resonance scanner [Philips Acheiva, Netherlands], using surface coils with a small field of view and thin sections with a slice thickness of 2.3 mm. Coronal T2W and axial T1W sequences are added to aid in anatomical localization.

RESULTS

This study included thirty subjects. Their ages ranged from 15 to 60 years [mean age: 38 years]. They were 18 males [40%] and 12 females [60%]. The condition was represented more in the second and third decades and more in males.

Of all the included subjects, 21 [70%] had undergone primary mastoid surgery. However, 9 [30%] had a negative past history of surgery.

In addition, 19 subjects were symptomatized on the right side [63.33%], 9 on the left side [30%], and 2 had bilateral symptoms [6.66%]. All subjects had painless otorrhea. However, 20 [66.66%] had variable degrees of hearing loss, and 6 cases [20%] complained of tinnitus [clinical presentations are depicted in Table 1].

According to lesion localizations, 19 were at epitympanum, 7 at mesotympanum, and 4 were at hypo tympanum. According to distribution according to ossicular bone erosions, 22 [73.3%] showed areas of DWI restriction within the middle ear, indicating primary or recurrent cholesteatoma, while 8 [26.66%] didn't show significant middle ear DWI restriction. In addition, 15 cases showed areas of iso-dense opacities in the middle ear on the CT study; two cases of them [13.33%] didn't show significant DWI restriction, while the other 15 cases didn't show significant CT opacities; nine cases of them [60%] showed middle ear DWI restriction.

All 22 cases that showed evidence of primary or recurrent Cholesteatoma on DWI MRI images underwent primary or second-look mastoid surgery, while all cases [100%] showed intraoperative and/or histopathological evidence of cholesteatoma.

Of the eight subjects who were negative for the condition on DWIs, 4 [50.0%] were submitted to primary or second-look mastoid surgery. They showed small Cholesteatoma [< 4 mm] [not visualized by DWIs]. The other 4 [50%] showed only granulation and/or inflammatory tissue with no evidence of Cholesteatoma. The above results indicate that MRI DWI is more sensitive and specific than CT studies in the diagnosis of middle ear Cholesteatoma [Tables 2 and 3].

Table [1]: Distribution of patient clinical presentations

Clinical presentation	Frequency	Percent
Otorrhea	30	100%
Hearing loss	20	66.66%
Tinnitus	6	20 %
Right sided symptoms	19	63.33%
Left sided symptoms	9	30%
Both sides symptoms	2	6.66%

Table [2]: correlation of CT & DWI finding intraoperatively

Diagnostic value	Imaging Modality	
	MRI DWI	CT
Sensitivity	84.6%	52 %
Specificity	100 %	60 %
Accuracy	86.66%	53.33%
Positive predictive value	100 %	86.66%
Negative predictive value	50%	20%

Table [3]: Diagnostic values of MRI DWI & CT in detection of cholesteatoma according to our study

Imaging Modality	True Positive	False Positive	Ture Negative	False Negative	Total
DWI MRI	22	-	4	4	30
CT	13	2	3	12	30

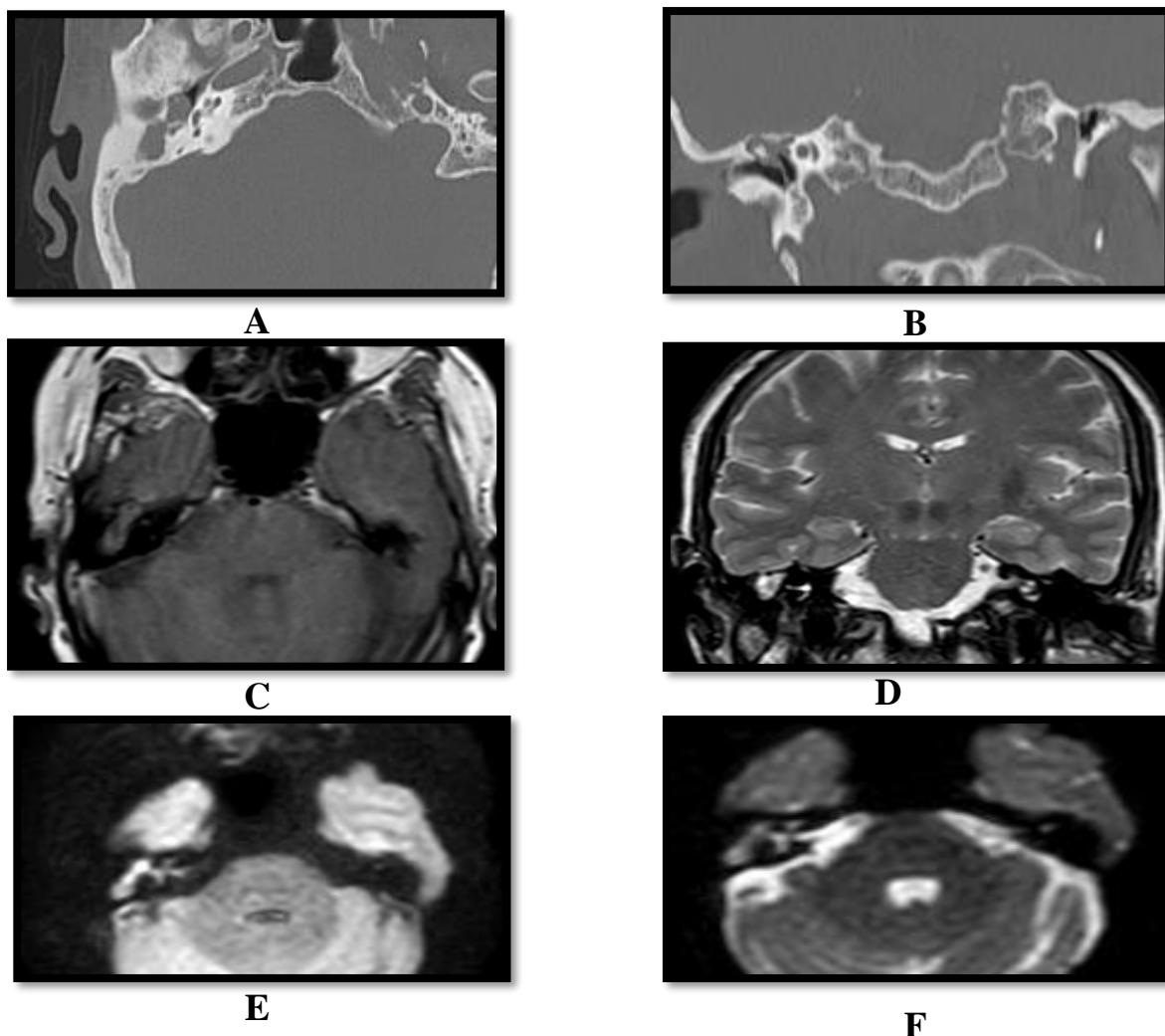


Figure [1]: A 51-year-old female, complaining of right painless otorrhea. CT and MRI were requested. [A], [B]: axial & coronal CT petrous bone: showing soft tissue density almost obliterating the right middle ear cavity, with opacification of right mastoid air cells, with no evidence of ossicle erosions or intracranial extension, tegmentum tympani is intact. [C]: Axial T1 WI: showing iso intense soft tissue signal occupying the right middle ear cavity. [D]: coronal T2 WI: the lesion eliciting high SI. [E]: DWI: the lesion shows high SI which representing restricted diffusion. [F]: ADC map: the lesion eliciting hpo SI.

DISCUSSION

The current study evaluated the diagnostic value of DWI-MRI along with CT in patients with cholesteatoma and the significance of DWI in distinguishing residual or early recurrence of Cholesteatoma from post-operative changes. We compared the results with intra-operative data from mastoid surgeries, follow-up data, and obtained histopathological data.

According to our study, DWI had a sensitivity of 84.6% in diagnosing cholesteatoma. This percentage is considerably better than previous studies such as **Nash et al.** [9], who reported a sensitivity of 63.6%. However, our reported sensitivity was lower than other studies [88%, 89.3%, and 100.0%] [10-12]. The studies by **Xun et al.** [10] and **Laske et al.** [11] included a large sample of patients, and the study by **Osman et al.** [12] included only subjects with recurrent conditions. This could

explain the heterogeneity of sensitivities. The specificity of DWI in detecting cholesteatoma was 100%, which is better than most studies [90% for **Osman et al.** [12] and 93% for **Xun et al.** [10]].

In the current study, the smallest size of cholesteatoma detected was 4.5 mm. This is slightly better than **van der Toom et al.** [8], **Sun et al.** [13] and **Cavaliere et al.** [14]. In those studies, the smallest size was 5 mm. However; the smallest detected size in the current work is larger than **Sheng et al.** [15] who can detect size [2 mm]. They used readout-segmented echo-planar imaging [RESOLVE] and the TGSE BLADE technique, a new technique that has markedly improved the image signal-to-noise ratio [SNR] and decreased image distortion.

In the current work, we could say that using DWI is a beneficial method in the evaluation of Cholesteatoma [either primary or recurrent]. It had excellent specificity, which reduced the need

for “second-look” surgery for many subjects. It also had an accepted sensitivity and the smallest detectable size when compared to other studies, as described previously. In addition, the CT assessment had a sensitivity of 52%, which is better than **Osman et al.** [12], who reported a value of 47.6%, and less than **Xun et al.** [10], who reported a value of 68%. The first author reported values for recurrent conditions, while the second author included a larger sample of subjects [80 patients].

On the other side, our CT study's specificity is about 60%, which is better than **Cavaliere et al.** [14] who reported a value of 50% and less than **Xun et al.** [10], and **Foti et al.** [16], who reported values of 78% and 87.5%, respectively.

The study has several limitations including a relatively small sample size of the studied population, multiple cases presenting months or years after initial symptoms possibly leading to increased lesion size and a falsely elevated study sensitivity, unassessed evaluation of contrast-enhanced T1-weighted imaging, and primarily relying on intraoperative findings without histopathological confirmation in most cases.

Conclusion: Both DWI and CT have good levels for diagnosis of cholesteatoma, Although DWI MRI has a high level of diagnosis more than CT, using both of them in correlation to each other gives a more a good results, accurate diagnosis and more excellent guidance for better surgical outcome. Recommendations for future studies include conducting research on a larger sample size and reducing the time interval between the initial or recurrent presentation and the MRI assessment.

Financial and Conflict of Interest: Nil

REFERENCES

1. Medany MM, Sabra RM, Hakim EK, Elshafei AMM, Sadawy AMI. Reliability of Diffusion Weighted MRI for the Diagnosis of Residual and Recurrent Cholesteatoma. *Egypt J Hospital Med* 2018; 72[10]: 5403-5408. doi: 10.21608/ejhm.2018.11297
2. ELNaeem A, Modather M, Gad SF, Abd Elwhab A, Ahmed A. Detection of Cholesteatoma using Diffusion Magnetic Resonance Imaging. *Egypt J Ear Nose Throat Allied Sci.* 2022;23[23]:1-7. doi: 10.21608/ejentas.2022.132526.1501
3. Castle JT. Cholesteatoma Pearls: Practical Points and Update. *Head Neck Pathol.* 2018 Sep;12[3]:419-429. doi: 10.1007/s12105-018-0915-5.
4. Hall A, Lingam RK, Singh A. The Problematic Middle Ear and Cholesteatoma. *Head and Neck Imaging: A Multi-Disciplinary Team Approach.* 2021:319-27.
5. Ali GG, El-Dieb LR, Ibrahim EA, Kamal S. Role of Diffusion-Weighted Propeller Magnetic Resonance Imaging in Cholesteatoma Diagnosis. *Med J Cairo Univ.* 2019; 87[June]:2477-84. doi: 10.21608/MJCU.2019.54856.
6. Kuo CL, Shiao AS, Yung M, Sakagami M, Sudhoff H, Wang CH, Hsu CH, Lien CF. Updates and knowledge gaps in cholesteatoma research. *Biomed Res Int.* 2015; 2015:854024. doi: 10.1155/2015/854024.
7. Henninger B, Kremser C. Diffusion weighted imaging for the detection and evaluation of cholesteatoma. *World J Radiol.* 2017 May 28;9[5]:217-222. doi: 10.4329/wjr.v9.i5.217.
8. van Dinther JJS, Coopman R, Vercruyssen JP, Somers T, Zarowski A, Vanspauwen R, et al. The Bony Obliteration Tympanoplasty in Pediatric Cholesteatoma: Long-term Hearing Results. *Otol Neurotol.* 2018 Jul;39[6]:715-723. doi: 10.1097/MAO.0000000000001846.
9. Nash R, Lingam RK, Chandrasekharan D, Singh A. Does non-echo-planar diffusion-weighted magnetic resonance imaging have a role in assisting the clinical diagnosis of cholesteatoma in selected cases? *J Laryngol Otol.* 2018; 132[3]:207-213. doi: 10.1017/S0022215118000087.
10. Xun M, Liu X, Sha Y, Zhang X, Liu JP. The diagnostic utility of diffusion-weighted magnetic resonance imaging and high-resolution computed tomography for cholesteatoma: A meta-analysis. *Laryngoscope Investig Otolaryngol.* 2023 Apr 5;8[3]:627-635. doi: 10.1002/lio2.1032.
11. Laske RD, Roth TN, Baráth K, Schuknecht B, Huber AM, Rösli C. The Role of Non-Echoplanar Diffusion-Weighted Magnetic Resonance Imaging in Diagnosis of Primary Cholesteatoma and Cholesteatoma Recidivism as an Adjunct to Clinical Evaluation. *Ann Otol Rhinol Laryngol.* 2018 Dec;127[12]:919-925. doi: 10.1177/0003489418800833.
12. Osman NM, Rahman AA, Ali MT. The accuracy and sensitivity of diffusion-weighted magnetic resonance imaging with Apparent Diffusion Coefficients in diagnosis of recurrent cholesteatoma. *Eur J Radiol Open.* 2017 Mar 23;4:27-39. doi: 10.1016/j.ejro.2017.03.001.
13. Sun WH, Fan JK, Huang TC. The Efficacy of DW and T1-W MRI Combined with CT in the Preoperative Evaluation of Cholesteatoma. *J Pers Med.* 2022 Aug 21;12[8]:1349. doi: 10.3390/jpm12081349.
14. Cavaliere M, Di Lullo AM, Cantone E, Scala G, Elefante A, Russo C, et al. Cholesteatoma vs granulation tissue: a differential diagnosis by DWI-MRI apparent diffusion coefficient. *Eur Arch Otorhinolaryngol.* 2018 Sep;275 [9]:2237-2243. doi: 10.1007/s00405-018-5082-5.
15. Sheng Y, Hong R, Sha Y, Zhang Z, Zhou K, Fu C. Performance of TGSE BLADE DWI compared with RESOLVE DWI in the diagnosis of cholesteatoma. *BMC Med Imaging.* 2020 Apr 19;20[1]:40. doi: 10.1186/s12880-020-00438-7.
16. Foti G, Beltramello A, Minerva G, Catania M, Guerriero M, Albanese S, Carbognin G. Identification of residual-recurrent cholesteatoma in operated ears: diagnostic accuracy of dual-energy CT and MRI. *Radiol Med.* 2019 Jun; 124[6]:478-486. doi: 10.1007/s11547-019-00997-y.

IJMA



INTERNATIONAL JOURNAL OF MEDICAL ARTS

VOLUME 6, ISSUE 5, MAY 2024

P- ISSN: 2636-4174
E- ISSN: 2682-3780