

Efficiency of Platelet-Rich Plasma in Repairing Tympanic Membrane Perforation

Ahmed M. Abdelaziz^{1*}, Nagy M. Eskander², Yasser T. Madian²,
Yehia M. Ashry²

¹Department of Otorhinolaryngology, Military Production Hospital.

²Department of Otorhinolaryngology, Faculty of Medicine-Suez Canal University

Abstract

Background: Myringoplasty is the definite treatment of tympanic membrane perforation. **Aim:** This study aimed to assess the success rate in repairing tympanic membrane perforation of Platelet platelet-rich plasma myringoplasty method. **Patients and Methods:** In our study, we have 27 TM perforations in 24 patients (where 3 patients had bilateral perforation) with small and medium-sized tympanic membrane perforations. We excluded subtotal or marginal perforation. In our study, Myringoplasty involves the repair of tympanic membrane perforation with a Platelet-rich plasma graft. Platelet-rich plasma graft was used as an overlay graft through the EAC under local anesthesia to act as a support for the Tympanic membrane to grow on both sides of the Platelet-rich plasma graft and enhance the success rate through its growth factors. **Results:** Graft uptake and complete closure of tympanic membrane were observed in 87.5% of cases (85.2% in relation to a number of perforations), Small-sized TM perforation documented 93.3% success rate (14 perforations of 15), while medium-sized TM perforation documented 75% success rate (9 perforations of 12). Platelet-rich plasma graft provides a better audiological result, hearing gain by >10 dB was achieved in 87.5% of patients. **Conclusion:** Platelet-rich plasma is a highly successful auto graft for closure of small tympanic perforations, fairly successful in medium-sized perforation, and provides unlimited graft material for residual perforations after failure fascia graft.

Keywords: PRP, Myringoplasty, Tympanic membrane perforation

Introduction

The tympanic membrane is an important structure of the middle ear representing mainly the lateral wall of the middle ear cavity. It has a great impact on the mechanics of hearing relative to sound transmission and compliance. Its specific histological nature, the exceptional migration ability of its epithelial layer not encountered in other epidermis, and its immunological competency, could transform the eardrum from a protector and a defender of the

middle ear to an invader⁽¹⁾. Myringoplasty is considered the most effective and reliable method of repairing tympanic membrane perforations. It has been used with various surgical techniques, and with numerous grafting materials to reconstruct the TM, including skin, fascia, cartilage, vein, fat, perichondrium, and dura mater. Temporalis fascia is considered by most surgeons to be the material of choice for myringoplasty⁽²⁾. Many different materials have previously been used to treat tympanic membrane perforations, including

*Corresponding Author: dr.a7medsallam.sur@gmail.com

hyaluronan, heparin, epidermal growth factor, fibroblast growth factor, platelet-derived growth factor, and transforming growth factor⁽³⁾. Platelets play an important role in hemostasis and wound healing. Alpha granules within platelets contain several growth factors and transforming growth factors.^{1,3,5,6} Platelets play an important role in hemostasis and wound healing. Platelet-rich plasma is defined as a small volume of plasma having a platelet concentration above baseline levels. A mixture of platelet-rich plasma and calcium results in the degranulation of alpha granules and the release of growth factors, forming a gel structure⁽⁴⁾. Erkilet et al. ⁽⁵⁾ reported the contribution of platelet-rich plasma to tympanic membrane healing in 44 rats following bilateral tympanic membrane perforation. Platelet-rich plasma was applied to the right side, while the left side was used as a control. In a group of 20 rats, daily otomicroscopic assessment demonstrated a significant difference in healing time for the right side compared with the left (10.2 ± 2.1 days 13.0 ± 2.9 days; mean difference 2.8 days). The other 24 rats were divided into 4 groups of 6 rats and sacrificed on days 3, 7, 14, and 28, and then histopathological examination of the tympanic membranes was performed. No significant differences in healing were found for any time point⁽⁵⁾. This research aimed to assess the success rate in repairing tympanic membrane perforation of Platelet platelet-rich plasma myringoplasty method.

Patients and Methods

This prospective study was conducted on 24 patients 11 male and 13 female that have small and medium-sized Tympanic membrane perforation. Perforation must be dry with apparently healthy middle ear mucosa, in Suez Canal University Hospital, in

Otorhinolaryngology Department. The study protocol was approved by the local ethical committee of the Faculty of Medicine, Suez Canal University, Egypt. in the period from August 2019 to October 2020. All patients gave their written informed consent to participate, the objectives of our study were to evaluate the success rate of the platelet-rich plasma usage as a graft material in combination with surgical refreshing of the perforation margins for the repair of chronic tympanic membrane perforations small and medium sizes. The medical and surgical records were reviewed prospectively, and the patients were followed up for one year.

Inclusion criteria

Patients with small and medium-sized tympanic membrane perforations according to Saliba's subdivision (TM was divided pre-operatively into four quadrants, and perforations involving more than two quadrants were excluded)⁽⁷⁾ were selected according to the following criteria. Age above 18 years old, Perforation persists more than 3 months. Perforation must be dry with apparently healthy middle ear mucosa (red, moist, and glistening). Air bone gap (ABG) is less than 30 dB. Size of perforation ranges from small to medium sized.

Exclusion criteria

Patients suffering from any of the following conditions were excluded from the study, Active ear discharge. Marginal and attic perforations. Large, subtotal, and total perforations. Those with suspected ossicular pathology have more than 30 dB air-bone gap. Eustachian tube dysfunction. Extensive TM sclerosis reaching the perforation margins. Patients with granulations and polyps in the external or middle ear. Patients with major illnesses like malignancy, liver cell failure, uncontrolled diabetes mellitus, and severe anemia. Revision

ear surgery. Patients below 18 years old. Patients refusing to give consent.

Pre-operative tests

History and ENT examination

Preoperative investigations: Audiologic assessment, Endoscopic examination. Preoperative laboratory tests including CBC, fasting and postprandial blood sugar, coagulation profile, and HIV serology will be done to look for any contraindications to PRP use like anemia, coagulopathies, and uncontrolled diabetes mellitus.

Surgical procedure:

The patients were fully informed about the procedure and written consent was provided given the general principle of the operation, postoperative care, and operative risks which include complications of local anesthesia, facial paralysis, recurrence of perforation, worse hearing, vertigo, and the possibility of the need for further surgeries.

Methods

Persistent TM perforation ranged from small-sized if its surface area is less than a quarter of the TM surface to medium-sized if its surface area is more than a quarter of the TM surface and less than half of the TM surface. Sterilization, Anesthesia, and Preparing platelet-rich plasma. The patient was positioned supine with the affected ear turned upwards; the margin of each perforation was freshened by a sharp needle. Autologous PRP membrane was cut to a size approximately about 1.5 times the size of the perforation, then placed through the external auditory canal over the perforation as a single overlay layer, then a meatal pack of soft paraffin-impregnated gauze was placed for 1 week for supporting the PRP membrane. All patients were discharged immediately after the procedure and advised to avoid self-removal of the pack, forceful coughing,

sneezing, straining, or blowing of the nose, and keeping the ear dry. Follow-up visits at the outpatient clinic were scheduled, the pack was removed after 1 week, and patients were followed for 3 months. All patients were subjected to an endoscopic examination with the same technique using 2.7mm o endoscope attached to the scope camera and recording system, PTA at the same audiological center, and ABG measurement. The hearing gain was calculated as the difference between pre-and post-treatment ABG means.

Statistical Analysis

Statistical analysis was performed using the Statistical Package for the Social Sciences (SPSS) statistical program version 24. Fisher exact test was used to identify the possible association between the categorical variables. Man Whitney U test was used to identify the possible association between the numerical variables. A receiver operating characteristic (ROC), or simply ROC curve, is a graphical plot that illustrates the performance of a binary classifier system as its discrimination threshold is varied. Results were considered statistically significant at a P-value less than 0.05.

Ethical consideration

The participants gave informed written consent to participate in the study. The protocol was approved by the local ethical committee. Privacy and confidentiality of the obtained data was ensured for all participants. Laboratory results were given to all tested members. All results were used for research purposes only. The results of this research could be used in the future by any researcher in the same field to do further studies for the benefit of patients. All data was saved, and only the researcher had access to it. No stored samples were shipped out of the country. The subjects

had the right to withdraw samples at any time.

Results

The present study included a total of 24 patients with chronic tympanic membrane perforations fulfilling the inclusion criteria. The mean age of patients in the present

study was 46.25 ± 15.82 years and the maximum patients belonged to range from 25 to 72 years. About 54.2% of patients in the present study were females. 54.2% of the studied cases had lesions on the right side and 45.8% had on the left side. 55.6% of the lesions among the studied cases were small size and 44.4% were medium (Figure 1).

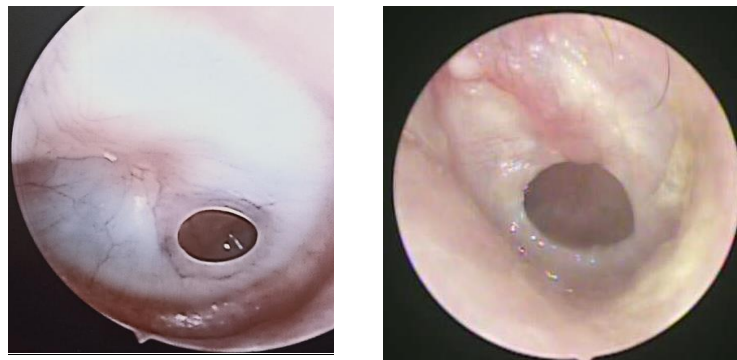


Figure 1: Sizes of TM perforations
(A): small-sized TM perforation (B): medium-sized TM perforation.

All the patients underwent surgical repair of the tympanic membrane by closure of perforation using platelet-rich plasma graft (Figs. 2, 3). Graft uptake and complete healing of the tympanic membrane without any residual of the perforation during the follow-up period (3 months) was the aim of this study, which was achieved in 87.5% of cases, graft failure was observed in 12.5% of cases (fig4, table 1), among these cases 2 cases showed post procedure middle ear infection and discharge. Complete closure among the studied cases ranged from 3 to 9 weeks with a mean of 5.44 weeks (Figure 5, Table 1). Comparing pre- and post-treatment mean ABG revealed that the mean ABG significantly decreased after treatment by PRP in all successful cases (Table 1,7). The present study documented that there was no statistically significant difference between successful.

cases and failed cases in age, sex, or side of lesion but there was an increase in the frequency of medium-size lesions among failed cases compared to succeed and there was a statistically significant increase in complication among failed cases as in Table 1. The table shows that the age of the studied cases ranged from 25 to 72 years with a mean of 46.25 years. Regarding sex distribution 54.2% were female. Table 1 shows that 54.2% of the studied cases had lesions on the right side and 45.8% had on the left side. One case had 2 perforations on the same side also 2 cases had bilateral lesions which made the total number of lesions 27. Table 1 shows that 55.6% of the lesions among the studied cases were small size and 44.4% were medium. Table 1 shows that the duration of complete closure among the studied cases ranged from 3 to 9 weeks with a mean of 5.44 weeks.

Table 1: Description of the studied cases	
Variable	(n=24)
Age: (year)	
Mean \pm SD	46.25 \pm 15.82
Range	25 - 72
Gender n (%)	
Male	11 45.8
Female	13 54.2
Side of lesion n (%)	
Rt	13 54.2
Lt	11 45.8
Size of lesion n (%)	
Small	15 55.6
Medium	12 44.4
Duration of complete closure (week)	
Mean \pm SD	5.44 \pm 1.42
Range	3 - 9
Complication n (%)	
No	21 87.5
Yes	3 12.5
Graft failure	3 12.5
Infection	2 8.3
Hearing gain:	
<10 db hearing gain (failed)	3 12.5
\geq 10 db hearing gain (succeed)	21 87.5
Outcome:	
Graft Failed	4 14.8
Graft Succeed	23 85.2

SD: Standard deviation

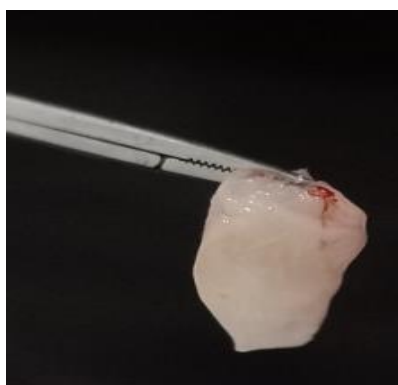


Figure 2: Final PRF membrane formed as graft material for the procedure.

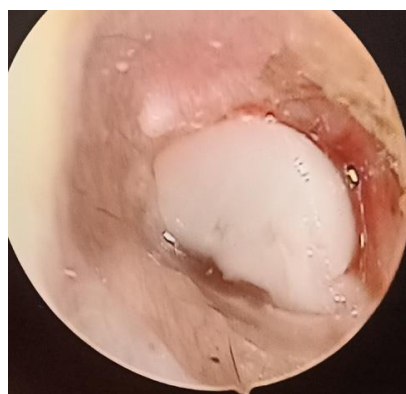

Figure 3: PRP graft placed over the perforation

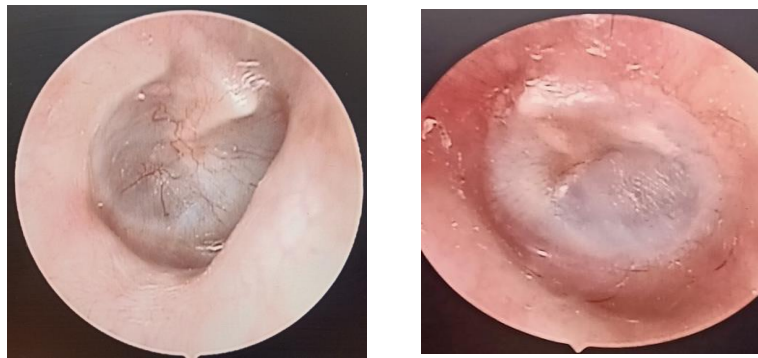


Figure 4: (A): complete closure of small-sized TM perforation, (B): complete closure of medium-sized TM perforations

Table 1 shows that 87.5% of the studied cases had no complication while 3 cases (12.5%) had. One case had failure of graft only while 2 cases had both infection and failure of the graft. Among cases that had graft failure, one case had 2 lesions. Table 1 shows that 87.5% of the studied cases had hearing gain equal to or more than 10 db (succeed). Also, in 85.2% of the lesions, the graft operation succeeds. Table 2 shows that there was a statistically significant decrease in ABG among the studied cases postoperative compared to pre. The mean

decrease was 10.86 db. Table 3 shows that there was an increase in the frequency of failure among medium lesions compared to small lesions. Table 4 shows that there was no statistically significant difference between successful cases and failed cases in age or sex. Table 4 shows that there was no statistically significant difference between successful cases and failed cases in ABG or the side of the lesion. Table 4 shows that there was a statistically significant increase in complication among failed cases compared to succeeded.

Variable	Pre (n=24)	Post (n=24)	Paired W	P	Hearing gain (n=24)
ABG: (db)					
Mean±SD	23.45±5.78	12.95±3.69	4.34	<0.001**	11.86 ± 3.24
Range	18 - 27	11 - 22			7 - 15

SD: Standard deviation, Paired W: Paired Wilcoxon test, **: highly significant ($P < 0.01$)

Variable	Small (n=15 [^])		Medium (n=12 [^])		χ^2	P
	N	%	N	%		
Outcome:						
Graft Failed	1	6.7	3	25	3.48	0.04*
Graft Succeed	14	93.3	9	75		

SD: Standard deviation, Paired W: Paired Wilcoxon test, **: highly significant ($P < 0.01$), χ^2 : Chi square test [^]: Number of lesions*: Significant ($P < 0.05$)

Discussion

In the present study, Myringoplasty involves the repair of tympanic membrane

perforation with an autologous graft material as they are less invasive, cheaper, and readily obtained⁽⁶⁾. Platelet-rich plasma had been described and used for repair and

regeneration of different tissues by Choukroun et al. (8) who first introduced its clinical application in oral, maxillofacial, and implant surgery. Platelet-rich plasma is a biological product created by condensing platelets in vitro and activating the alpha granules to stimulate the secretion of growth factors. Since it is prepared from autologous blood, platelet-rich plasma is cheaper than growth factors and carries no risk of infection transmission(9). Of course, it also acts as a support for the Tympanic membrane to grow on both sides of the PRP graft. Platelet-rich plasma has been used with a success rate and minimal

complications in cases of traumatic and acute Perforations(10). The present study included 24 patients with 27 TM perforations (One case had 2 perforations on the same side also 2 cases had bilateral lesions which made the total number of lesions 27), 11 males and 13 females with a mean age of 46.25 ± 15.82 years. Patients belonged to 25 to 72 years of age. According to Saliba's subdivision, 55.6% of the patients have a small tympanic membrane perforation (15 perforation) and 44.4% have a medium size tympanic membrane perforation (12 perforation)(7).

Table 4: Comparison between successful and failed cases

Variable	Failed (n=3)	Succeed (n=21)	t	P
Age (years)				
Mean \pm SD	47.4 \pm 16.16	40.5 \pm 14.62	0.76	0.46
Range	25 - 72	25 - 57		NS
ABG (db) before				
Mean \pm SD	24.2 \pm 4.45	20.6 \pm 3.19	1.75	0.09
Range	21 - 27	18 - 25		NS
Sex (n, %)				
Male	2 (66.7)	9 (42.9)	0.60	0.44
Female	1 (33.3)	12 (57.1)		NS
Side (n, %)				
Right	2 (66.7)	11 (52.4)	0.22	0.64
Left	1 (33.3)	10 (47.6)		NS
Complication (n, %)				
No	0 (0)	21 (100)	24	<0.001**
Yes	3 (100)	0 (0)		

SD: Standard deviation, t: independent t test, χ^2 : Chi square test, NS: Non-significant (P.0.05), **: Highly significant (P<0.001)

However, in this study we tried to assess the role of PRP graft in the closure of small and medium-sized chronic tympanic membrane perforations. Graft uptake and complete closure of tympanic membrane was observed in 87.5% OF cases (85.2% in relation to number of perforations), while failure of closure occurred in 12.5% of cases (14.6% in relation to number of perforations), The present study documented statistically significant association of outcome

with the size of the perforation, Small sized TM perforation documented 93.3% success rate (14 perforation of 15), while medium-sized TM perforation documented 75% success rate (9 perforations of 12). Platelet-rich plasma graft was used in the present study as an overlay graft through the external auditory canal after local anesthesia to close the perforations, Shukla et al. (11) in their comparative study compared the outcomes of the technique of placement of

PRF membrane for the closure of perforation i.e. overlay/underlay + overlay or combined. All patients underwent surgery under an operating microscope. In the case of small perforation, he used only the overlay technique as in our study but in the cases of medium perforation he used an underlay + overlay combination technique They documented that outcomes were significantly better in cases in whom overlay and underlay technique was used, with Successful closure was observed in 85.4% of cases but In our study, Successful closure was observed in 87.5% of cases and all cases operated using zero angle otoscope. Kumar⁽¹²⁾ reported relatively higher success rate of 92% as compared to present study (87.5%) The observed difference could be due to the difference in cause of perforations i.e. in reference study PRF was conducted for traumatic perforations whereas in present study, PRP was used for the chronic perforations. El-Anwar et al.⁽¹³⁾ reported a Successful repair in 84% of patients having a small tympanic membrane perforation using double layers of PRP one medial to the perforation and the other lateral to it, which is better in the present study also our study included both small and medium sized TM perforations using a single layer of PRP lateral to the perforation. In the current study, post-treatment mean ABG significantly improved in all patients (from 23.45 ± 5.78 to 12.95 ± 3.69 dB), We found that the mean \pm SD of hearing gain significantly improved by (11.86 ± 3.24 dB). This goes in line with Gür et al.⁽⁶⁾ who reported that the improvement in the mean air bone gap was 14.1 dB in group 1 where PRF was used. The results show that the use of PRF provides a better audiological result. Our results showed that the use of PRP graft provides better audiological results, and hearing gain by >10 dB was achieved in 87.5% of patients This differs from results obtained by

Hosam et al.⁽¹⁴⁾ who reported that hearing gain (≥ 10 dB) was achieved in 80% of patients in group A (PRF used). Mohamed Shindy et al.⁽¹⁵⁾ In his study of acute traumatic tympanic membrane perforation showed that complete healing was achieved in grade I (small-sized) by 100%, in grade II (medium-sized) by 90.9% which is higher than our results, but our study conducted on patients having small and medium-sized chronic TM perforations. Ahmed et al.⁽¹⁴⁾ used PRP with fat myringoplasty in 20 patients with small to medium-sized tympanic membrane perforations, 100% success rate was obtained in small perforations and 79.3% in medium-sized perforations which is better than our results but we depend on RRP graft as the main graft in the closure of the TM perforations as a less invasive procedure. Failure rates in the present study were significantly observed in patients having medium-sized TM perforations (3 perforations among the 4 failed cases) among these failed cases post-procedure active ear discharge was observed in 2 cases these cases showed upper respiratory tract infection, active ear discharge affecting the process of healing of the perforation, so the infection could be considered a main cause of failure. Failed cases showed a promising response to our procedure by minimizing the size of perforation which encouraged us to try the same procedure on these cases after the period of follow up giving us a successful closure in 2 of these cases. The advantages of platelet-rich fibrin include its easy preparation; as platelet-rich fibrin is autologous, the chances of immunogenic reaction, disease transmission, and graft failure are minimal. As PRF can be prepared any number of times so there is virtually unlimited graft material available for repeat surgeries and even in the surgeries which failed after the usage of temporalis fascia.

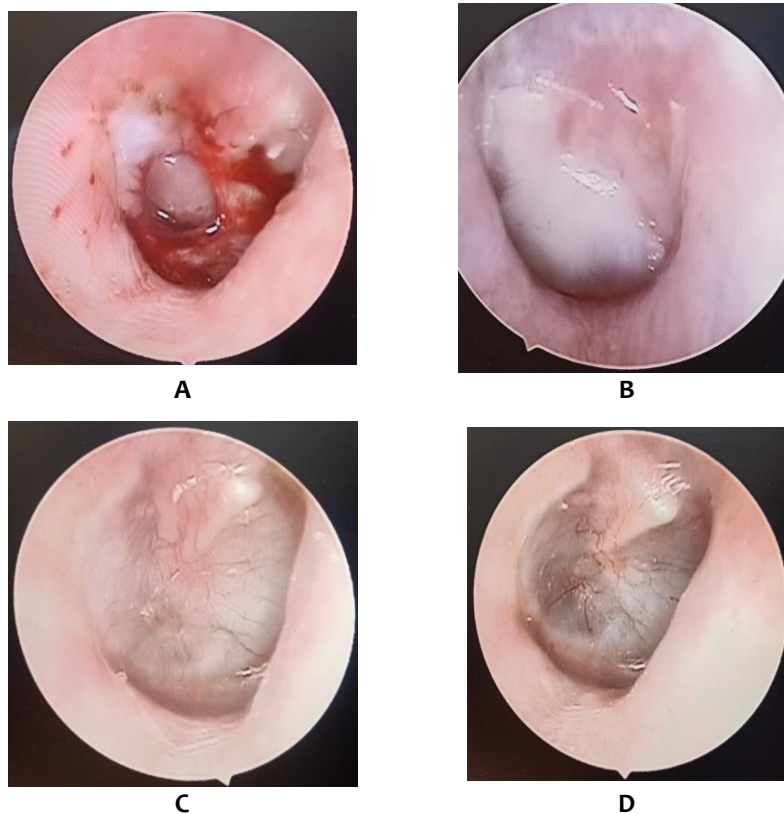


Figure (5): Stages of complete closure of TM perforation during follow up, (A): TM perforation after refreshment, (B): PRP graft adherent to TM perforation after one week, (C): TM perforation after 4 weeks, (D): TM perforation after 6 weeks showing complete healing.

It is inexpensive and can be used as an OPD procedure⁽¹⁶⁾. PRF myringoplasty doesn't require any incision and therefore patient morbidity is minimal. It can be taken as the first procedure for the closure of tympanic membrane perforation before any more invasive tympanoplasty procedure is attempted. Growth factors released by PRF acts for extended duration i.e. up to 7 days or more. Also, slow polymerization and remodeling of the fibrin matrix within PRF effectively sustains growth factors and other critical cells and thus aids in healing⁽¹⁷⁾. Garin et al. ⁽¹⁸⁾ also observed good safety of platelet-rich fibrin without any adverse effect in middle ear packing.

Conclusion

PRP is a highly successful auto graft for closure of small tympanic perforations, fairly

successful in medium-sized perforation, and provides unlimited graft material for residual perforations after the failure of fascia graft. According to our results, PRP should be included in myringoplasty procedures indicated for TMP secondary to chronic suppurative otitis media (CSOM).

Study limitations.

The methodological limitations of this study included its small sample size and lack of a control group.

References

1. Merchant SN, Rosowski JJ. Conductive hearing loss caused by third-window lesions of the inner ear. *Otol Neurotol.* 2008 Apr;29(3):282–9.
2. Zaman A, Omar S. Myringoplasty using temporalis fascia and its clinical

- outcome. *Int J Otorhinolaryngol Head Neck Surg*. 2019;5(6):1539.
3. Güneri EA, Tekin S, Yilmaz O, et al. The Effects of Hyaluronic Acid, Epidermal Growth Factor, and Mitomycin in an Experimental Model of Acute Traumatic Tympanic Membrane Perforation. *Otol Neurotol* . 2003;24(3):371–6.
 4. Zhang ZG, Huang QH, Zheng YQ, et al. Three Autologous Substitutes for Myringoplasty. *Otol Neurotol*. 2011;32(8):1234–8.
 5. Erkilet E, Koyuncu M, Atmaca S, et al. Platelet-rich plasma improves healing of tympanic membrane perforations: an experimental study. *J Laryngol Otol*. 2008;123(5):482–7.
 6. Gür ÖE, Ensari N, Öztürk MT, et al. Use of a platelet-rich fibrin membrane to repair traumatic tympanic membrane perforations: a comparative study. *Acta Otolaryngol* . 2016;136(10):1017–23.
 7. Saliba I. Hyaluronic acid fat graft myringoplasty: how we do it. *Clin Otolaryngol* . 2008 Dec;33(6):610–4.
 8. Simonpieri A, Choukroun J, Girard MO, et al. Implantation immédiate post-extractionnelle (IPE): l'intérêt du PRF®. *Implantodontie* . 2004;13(3):177–89.
 9. Grageda E. Platelet-Rich Plasma and Bone Graft Materials: A Review and a Standardized Research Protocol. *Implant Dent*. 2004;13(4):301–9.
 10. Huang J, Teh BM, Zhou C, et al. Tympanic membrane regeneration using platelet-rich fibrin: a systematic review and meta-analysis. *Eur Arch Oto-Rhino-Laryngology* . 2021.
 11. Shukla A, Kaurav YS, Vatsyayan R. Novel Use of Platelet Rich Fibrin Membrane in Transcanal Myringoplasty: A Prospective Study. *Indian J Otolaryngol Head Neck Surg* . 2020/05/08. 2020 Sep;72(3):355–62.
 12. Kumar RD. Application of Platelet Rich Fibrin Matrix to Repair Traumatic Tympanic Membrane Perforations: A Pilot Study. *Indian J Otolaryngol Head Neck Surg* . 2017/12/02. 2019 Nov;71(Suppl 2):1126–34.
 13. El-Anwar MW, Elnashar I, Foad YA. Platelet-Rich Plasma Myringoplasty: A New Office Procedure for the Repair of Small Tympanic Membrane Perforations. *Ear, Nose Throat J* . 2017;96(8):312–26.
 14. Hosam M, Shaker M, Aboulwafa A. Effect of topical use of platelet-rich fibrin in repairing central tympanic membrane perforation using the endoscopic inlay butterfly cartilage myringoplasty technique. *Egypt J Otolaryngol* . 2017;33(3):557–63.
 15. Shindy M, El-Shimi O, Belal M, et al. Use of Platelet Rich Fibrin in Acute Traumatic Tympanic Membrane Perforation Compared With the Conservative Treatment. *Benha Med J* . 2020;0(0):0.
 16. Sharma D, Mohindroo S, Azad RK. Efficacy of platelet-rich fibrin in myringoplasty. *Int J Otorhinolaryngol Head Neck Surg*. 2018;4(3):677.
 17. Karimi K, Rockwell H. The Benefits of Platelet-Rich Fibrin. *Facial Plast Surg Clin North Am*. 2019;27(3):331–40.
 18. Ezzedine K, Le Thuaut A, Jouary T, et al. Latent class analysis of a series of 717 patients with vitiligo allows the identification of two clinical subtypes. *Pigment Cell Melanoma Res* . 2013;27(1):134–9.