

Original Paper, PET/CT.

Value of ^{18}F -FDG PET/CT Compared to Conventional Imaging in Changing Management of Patients with Differentiated Thyroid Cancer before Radioactive Iodine Ablation.

Elantably, I¹. Ibrahim, D². Mounir, H³. Abdelgaid, S¹.

¹Nuclear medicine Unit, National Cancer Institute. ²Department of Radiology, Kasr Alainy Hospital, Cairo University. ³Clinical Oncology and Nuclear Medicine Department, Zagazig University, Egypt.

ABSTRACT:

Objectives: this retrospective study investigated the value of ^{18}F -FDG PET/CT compared to conventional imaging in change the management of patients with differentiated thyroid cancer before radioactive iodine ablation.

Material & Methods: patients with pathologically proven differentiated thyroid carcinoma (DTC) who underwent baseline whole body ^{18}F -FDG PET/CT before RAI-131 therapy were included. Findings of PET/CT along with results of conventional imaging studies (neck U/S and CT chest) were collected. The correlations and associations between results of PET/CT and conventional imaging studies were assessed. **Results:** The study included 124 patients (92 female and 32 male).

The ^{18}F -FDG PET/CT was positive in 65 sites in 38 patients with predominance at the loco regional area (thyroid bed in 22 & cervical lymph nodes in 15 patients) and distant sites in 28 patients. FDG PETCT was able to detect more loco regional disease compared to US. Using Kappa test, Neck U/S and F- ^{18}F FDG PET/CT in loco-regional assessment showed only fair agreement with a statistical significance (P value of 0.001 & 0.012 respectively) in detecting regional nodal deposits & operative bed lesions. ^{18}F -FDG PET/CT with CT chest results showed fair to moderate degree of agreement (P value < 0.001). ^{18}F -FDG PET/CT results changed the management of 26 patients (21%).

Conclusion: The initial ^{18}F -FDG PET/CT before RAI-131 ablation may change staging and management in some DTC patients

compared to other imaging modalities and help in planning for a proper dose of radioiodine therapy.

Key Words: ^{18}F -FDG PET/CT & DTC.

Corresponding Author: Abdelgaid, S.

E-mail: rwan2004@gmail.com.

Submission Date: 09/11/2022.

Accepted Date: 21/11/2022.

INTRODUCTION:

Thyroid cancer is considered the most common endocrine malignancy & the fifth most common cancer in women ⁽¹⁾.

Thyroid cancer in NCI represents about 1.97% of malignant neoplasm and about 74.7% of endocrine malignancy, with female to male ratio 2.6:1 & means age 51 years. Differentiated thyroid cancer includes: papillary thyroid cancer (PTC), follicular thyroid cancer (FTC) and Hurtle cell type. PTC is considered the most common subtype and has the best prognosis with 5-year survival of 98.1% ⁽²⁾.

Thyroid surgery (total or near-total thyroidectomy) followed by iodine-131 (I-131) ablation is the most effective therapeutic strategy for differentiated thyroid carcinoma (DTC) ⁽³⁾. Utilization of I-131 is not only important for primary tumors but also for lymph nodes (LNs) & distant

metastases ^(4, 5). But treatment strategies should be more cautiously tailored ⁽⁶⁾.

^{18}F -FDG PET/CT is recommended in high-risk patients with elevated serum thyroglobulin and negative I-131 imaging, for detection of disease recurrence ^(7, 8, 9). According to *Loboulleux et al.*, ^{18}F -FDG PET/CT is more beneficial than post empiric I-131 WBS for the diagnosis of recurrence/metastases in patients with increased blood thyroglobulin and no evidence of disease on diagnostic I-131 whole body scan (WBS) ⁽¹⁰⁾.

Over the last years, many studies have revealed high sensitivity (80-90%) of ^{18}F -FDG PET/CT in discovering local or distant disease recurrences in patients with increased thyroglobulin levels and negative I-131WBS ^(11, 12, 13, 14).

Further indications for PET/CT in changing the management of patients with differentiated thyroid carcinoma remain controversial for example some studies have indicated the value of ^{18}F -FDG-PET/CT in altering the treatment strategy for DTC, either postoperatively before I-131 ablation, as in studies by *Maamoun et al.* ⁽¹⁵⁾ and *Rosenbaum-Krumme et al.* ⁽¹⁶⁾, or through the follow-up with positive I-131 WBS, as indicated by *Piccardo et al.* ⁽¹⁷⁾ and *Abdelhamed et al* in their studies ⁽¹⁸⁾.

Ultrasonography (U/S) is currently regarded as a key diagnostic tool for the identification of thyroid cancer with metastatic LNs. According to *Mulla and Schulte*, the sensitivity and specificity of ultrasound in the identification of cervical LN malignant deposits are 63% and 93%, respectively ⁽¹⁹⁾.

However, U/S has drawbacks in the evaluation of the operative thyroid bed and for the diagnosis of nodal metastases which are located in a deep region of the trachea and surrounding structures ⁽²⁰⁾. Moreover, according to *Stokkel et al.*, distant metastases will be missed in DTC patients with recurrences if ultrasonography is the only imaging technique used ⁽²¹⁾.

This study aimed to evaluate the utility of the ^{18}F -FDG PET/CT compared to conventional imaging studies in altering the management of patients with differentiated thyroid cancer before radioactive iodine ablation.

PATIENTS AND METHODS:

This work was conducted retrospectively in National Cancer Institute, Cairo University between March 2018 and February 2021. A number of patients were referred to the NCI nuclear medicine department from Zagazig university hospital. The study included 124 patients with pathologically proven DTC post thyroidectomy with or without lymphadenectomy and who underwent staging whole body ^{18}F -FDG PET/CT before RAI-131 ablation/therapy. The results of pathological data, postoperative neck U/S and diagnostic CT chest were also collected from medical records. The patients with prior iodine treatment to FDG PET/CT & those with undifferentiated thyroid cancers or double malignancy were excluded. The diagnostic values of neck U/S, CT chest and ^{18}F -FDG PET/CT were analyzed, based on relevant histo-pathologic results or follow up.

PET/CT imaging protocol: All patients fasted for four to six hours before the injection of ^{18}F -FDG to ensure that Blood glucose levels did not exceed 150 mg/dL. The ^{18}F -FDG dose range was 190 - 375 MBq depending on body weight. Scanning started 60 min after tracer injection in 3D mode from the vertex to mid-thigh and included 6–8 bed positions (120s per bed position). The CT was acquired using the following parameters: 120kV, 140 mA, PITCH: 1.375, slice thickness: 3.75 mm. Both PET and CT scans were performed on patients under normal tidal breathing. The images were reconstructed from the raw emission data collected by iterative reconstruction with CT-derived attenuation correction using the ordered subsets expectation-maximization algorithm. Images were interpreted by two nuclear medicine physicians.

Image interpretation:

[A] Qualitative assessment:

An abnormal focus of ^{18}F -FDG uptake is visually identified according to site and number of lesions including thyroid bed, regional lymph nodes, and metastatic sites, and compared with the normal liver activity.

[B] Quantitative assessment:

The ^{18}F -FDG uptake intensity within a specific lesion is calculated by drawing a

volumetric region of interest (ROI) over the lesion to estimate SUVmax which measure the Concentration of activity in ROI (mCi/ml)/injected dose (mCi)/body weight (g).

Statistical analysis:

Statistical package SPSS (Statistical Package for the Social Sciences) version 25 was used for coding and entering the data. Quantitative data were represented using mean, standard deviation, median, minimum and maximum. While categorical data were expressed in the form of frequency and percentage. Non-parametric *Kruskal-Wallis and Mann-Whitney* tests were used for the comparisons between quantitative variables, the Student t-test when normally distributed numerical variables was used for comparing categorical data, Chi-square (χ^2) test was performed. An exact test was used when the expected frequency was less than 5. McNemar test was used to compare ^{18}F -FDG PET/CT performance with neck U/S and CT chest. Kappa test was used to assess for agreement between PET/CT, neck U/S and CT chest. Logistic regression analysis was used for determining independent variables associated with PET/CT outcome. P-values less than 0.05 were considered statistically significant.

RESULTS:

Patient characteristics:

This retrospective study included 124 patients with differentiated cancer thyroid who were referred to NCI for RAI ablation, initial ¹⁸F-FDG PET/CT was conducted pre-ablation, 92 (74%) were females and 32 (26%) were males.

Their age was ranging from 13 to 83 years old with a mean age of 42 years (± 15). Papillary cancer was the dominant histologic subtype in 103 patients representing 83.1%. While follicular type and Hurthle cell cancer were seen in 10 patients and 11 patients respectively. Lymphatic invasion occurred in 26.6%, vascular invasion in 12% & extra-thyroidal extension in 22.3% of patients. Cervical lymph node metastases found in 32% of patients.

Concerning the TNM staging and ATA risk stratification, 50% of patients were of T1-2 N0M0 and most of patients (96.8%) were classified as low and intermediate risk

(55.6% and 40.3% respectively).

Association between F-18 FDG PET/CT avidity and clinico-pathological features:

The studied group was divided according to the F-18 FDG PET/CT results into patients with F-18 FDG PET/CT positive and negative findings.

Significant positive PET/CT findings (P value = 0.039) were seen in Hurthle cell subtype in 63.6% of them (**Figure 1**). Other pathological features like tumor size, multimodality, extra-thyroidal invasion, lymph node involvement showed no statistically significant difference in between the PET positive and negative group of patients.

Intermediate and high-risk patients represent the major bulk of positive PET patients with P -value <0.004. Also, they found to have a relative risk of 2.8% chance of getting positive PET/CT findings more than the low-risk patients with CI of (1.211-6.555).

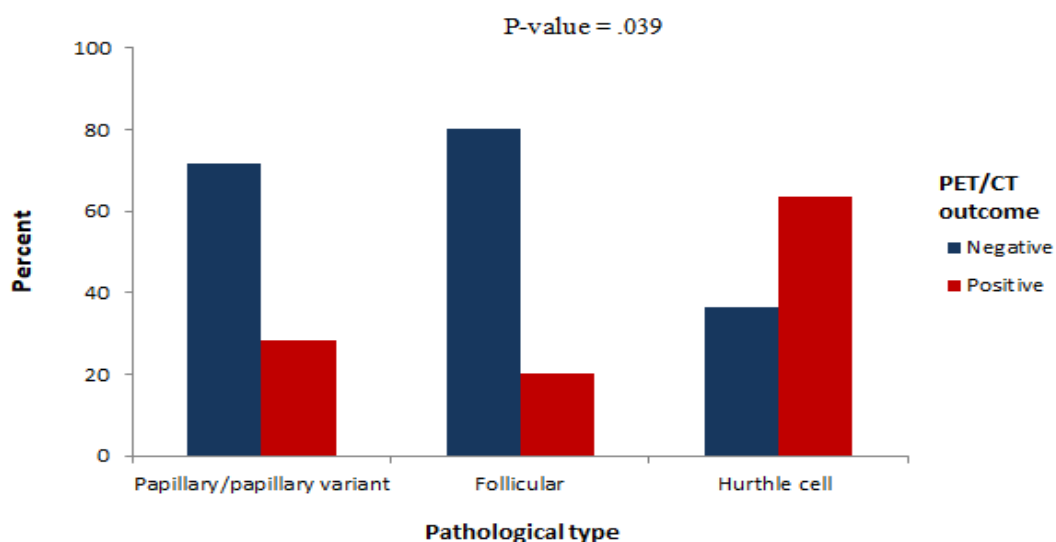


Figure (1): the different pathological type's percentage using ^{18}F -FDG PET/CT positive and negative patients.

Loco-regional and distant ^{18}F -FDG PET/CT locations in the PET/CT positive group of patients:

^{18}F -FDG-PET/CT was positive in 38 patients (30.6%) & negative in 86 patients (69.4%). FDG positive sites were seen in the thyroid bed (n = 22), cervical lymph nodes (n = 15),

and distant sites in twenty-eight patients (20.1%) located at: lungs (n = 14), mediastinal nodes (n = 8) and skeleton (n = 6) as seen in *Table (1)*. In the studied 124 patients, FDG reported sensitivity of 92.5%, specificity 94.4%, PPV 87.8%, and NPV 98.8 %.

Table (1): Loco-regional and distant FDG PET/CT locations in the positive group of patients:

| PET/CT positive patients per lesion location | No of patients | % From the 38 patients |
|--|----------------|------------------------|
| Operative bed residual disease | 22 | 17.7% |
| Cervical nodal deposits | 15 | 12.1% |
| Pulmonary metastases | 14 | 11.2% |
| Mediastinal nodal deposits | 8 | 6.4% |
| Skeletal metastases | 6 | 4.8% |

¹⁸F-FDG PET/CT versus conventional radiological modalities in detection of different lesions:

At thyroid bed: 99 patients had disease free thyroid bed using neck US. Whereas, 14 patients of them showed positive ¹⁸F-FDG PET/CT for residual tumor at thyroid bed & histo-pathologically confirmed in 12 patients. In the studied 117 patients who did ultrasound, sensitivity for the neck US in detecting operative bed disease was 33.3%, the specificity was 88.5%, the PPV was 38.9%, and the NPV was 85.9%.

For Cervical lymph node metastases:

Although neck U/S showed suspicious cervical LNs in 27 patients, PET/CT was positive in only 11 of them. Among the 99 patients who had no cervical nodal lesions by neck U/S only 2 were positive by PET/CT with statistical significance of P value 0.001.

For mediastinal nodal lesions: 113 patients reported negative for abnormal mediastinal

LNs by CT chest, 5 of them had F18-FDG avid LNs with three patients showed progressive disease in their consequent follow up CT chest. In 118 patients who underwent CT chest, CT sensitivity, specificity, PPV & NPV for mediastinal nodal deposits were 37.5 %, 98.2%, 60% and 95.6% respectively.

Regarding pulmonary metastases: 102 patients were considered as negative for significant finding in chest CT, while 4 of them were positive by ¹⁸F-FDG PET/CT. During follow up, two patients of them eventually considered as false positive and TG level remained undetectable. One showed an increase in nodules size in chest in follow up CT (true positive) and one patient lost follow up.

Chest CT examination was positive for suspicious pulmonary nodules (with size range 3-7 mm) in 16 patients, whereas only 10 patients out of them revealed positive ¹⁸F-FDG PET/CT (*Table 2*).

Table (2): ¹⁸F-FDG PET/CT versus other conventional radiological modalities in detection of different lesions.

| Conventional radiological tools (Neck US or Chest CT) | | F-18 FDG PET/CT | |
|--|------------------|-----------------|----------|
| | | Positive | Negative |
| *Neck US thyroid bed | Positive (n=18) | 7 | 11 |
| | Negative (n=99) | 14 | 85 |
| *Neck US cervical LN | Positive (n=27) | 11 | 16 |
| | Negative (n=90) | 2 | 88 |
| **Chest CT mediastinal LN | Positive (n=5) | 3 | 2 |
| | Negative (n=113) | 5 | 108 |
| Chest CT** Pulmonary lesion | Positive (n=16) | 10 | 6 |
| | Negative (n=102) | 4 | 98 |

*Neck US was not done in 7 patients.

** chest CT was not done in 6 patients.

Kappa test was used for neck U/S and ¹⁸F-FDG PET/CT loco-regional findings to assess their degree of agreement, there was only a fair agreement between them with a statistical significance displaying a P value of 0.001 & 0.012 respectively in cervical lymph node metastases & operative bed residual disease. While The degree of agreement of ¹⁸F-FDG PET/CT with CT chest results using the Kappa, test showed fair to moderate degree of agreement and was statistically significant (P value < 0.001).

Change of patients' management guided by FDG PET/CT results:

TNM classification was changed depending

on initial ¹⁸F-FDG PET/CT results in 26/124 patients with a subsequent management change as in establishing the need for re-surgery in 12 patients with operable residual loco-regional disease, increase the radioiodine doses in 8 patients with metastatic disease, radiotherapy referral in 3 patients with bone metastases, and trial for tyrosine kinase-inhibiting drugs in 3 patients who had advanced metastatic disease by FDG PET with negative post therapy iodine scan. So, change in management occurred in 26 out of 124 patients who accounted for 21% of the studied group (*Figures 2-3*).

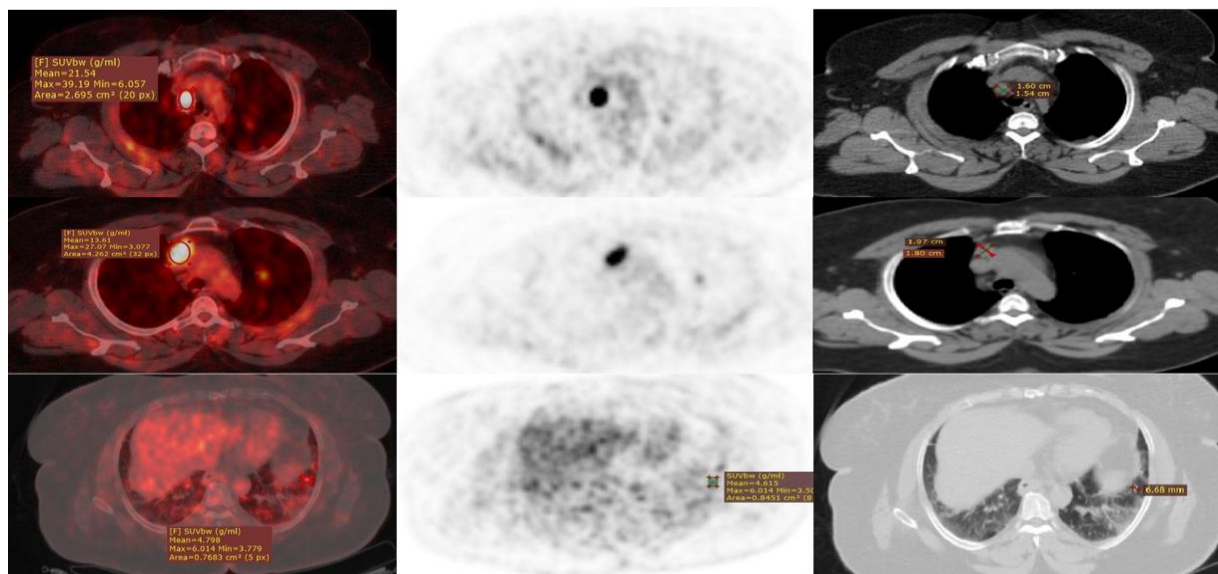


Figure (2): 51 year–old female patient with papillary thyroid carcinoma underwent total thyroidectomy and referred for RAI ablation dose. Fused PET/CT (A), PET (B) and CT(C) trans axial images reveal ^{18}F FDG avid mediastinal right pre-caval, right pre-tracheal LNs and left lower lung lobe nodule. Complementary chest CT was free. PET/CT detected more lesions so influenced the treatment strategy.

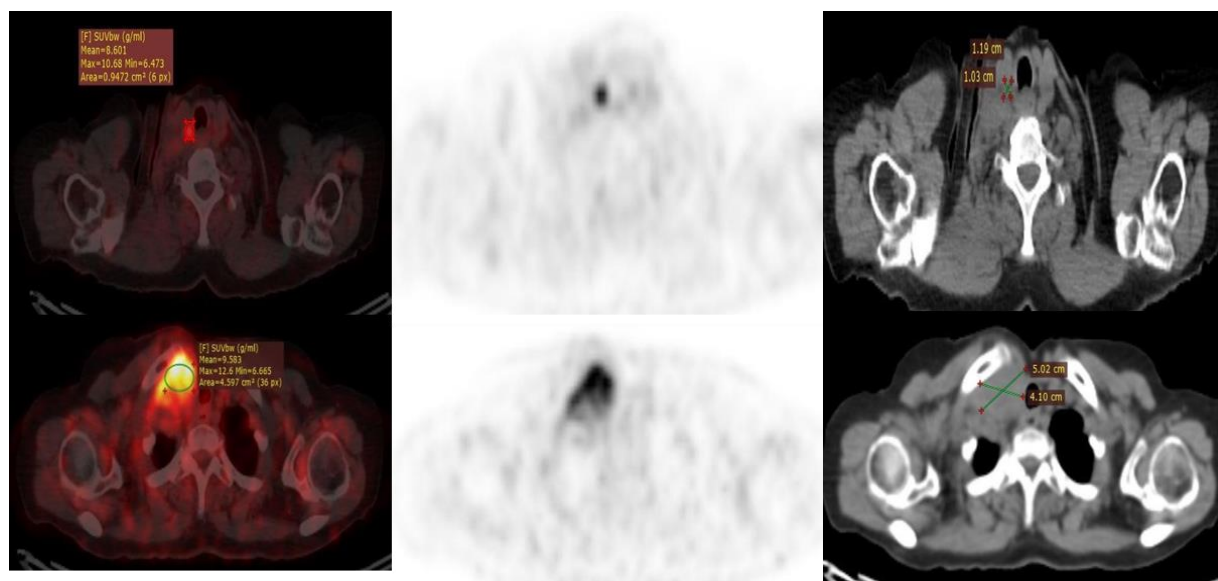


Figure (3): 78-year-old female patient presented with papillary thyroid carcinoma with cervical LNs. total thyroidectomy with nodal dissection was performed. She was referred for RAI ablation dose. Fused PET/CT (A), PET (B) and CT C Tran axial images reveal ^{18}F FDG avid right para-tracheal soft tissue nodule and large retro-clavicular mass. Neck US was free. Complementary chest CT shows right lower neck mass encroaching upon the clavicle. So, PET/CT detected more lesions that influenced the treatment strategy.

DISCUSSION:

Thyroid carcinoma is considered the most common endocrine cancer, represents about 1% of cancers ⁽¹⁾. Good prognosis is common among thyroid cancer patients; however, persistent, metastatic or recurrent disease may be seen among some patients therefore, an accurate diagnostic assessment is crucial to identify additional therapeutic options to improve outcome and survival ^(2, 22).

Ultrasound is basically used in differentiated thyroid cancer and has additive value in the management of thyroid cancer patients, it is simple, rapid and non-invasive and easy, the newly developed high-frequency linear array transducers and computer-enhanced imaging capabilities, can guide the FNAC biopsy from suspicious local lesions or LNs ^(23, 24). However, it is operator dependent and can miss the molecular functioning status of the lesion which may lead to inappropriate patient treatment, so ¹⁸F-FDG PET/CT may help in such situation.

The advantage of diagnostic CT over ¹⁸F-FDG PET/CT is the detection of smaller lesions that may be beyond the resolution of the ¹⁸F-FDG PET/CT, however CT as a morphological diagnostic tool has limitations so the application of functional imaging may

be valuable ^(23, 24). ¹⁸F-FDG PET/CT offers a functional imaging tool that is helpful in characterizing neoplastic lesions.

In AJCC cancer staging guidelines, the application of ¹⁸F-FDG PET/CT is not a standard in the initial evaluation of DTC patients ⁽²⁵⁾.

¹⁸F-FDG PET/CT contribution in discovering residual tumor or metastases early before I-131 ablation is still in need to be evaluated ⁽²⁶⁾.

According to our results, early staging ¹⁸F-FDG PET/CT scan in some DTC patients especially of aggressive variants and intermediate to high risk group, detected residual or metastatic disease which overlooked or indeterminate by conventional imaging studies and led to modification of treatment plan in 26/124 (21%) of patients.

In the current study, on the evaluation of thyroid operative bed, ¹⁸F-FDG PET/CT had good performance with higher sensitivity, specificity, PPV & NPV compared to US as FDG PET detected lesions in 14 patients while the neck US failed to discover them, this may be attributed to postoperative anatomy distortion. Also, 11 patients had false positive results by neck U/S with no positive uptake on ¹⁸F-FDG.

In the present work, in the context of cervical LN evaluation, neck U/S missed metastatic cervical LNs in two patients that were detected by ^{18}F -FDG PET/CT.

In a prospective study by *Martin et al.*, ultrasound has poor diagnostic accuracy when performed before FDG PET (pre-US) versus when guided by FDG PET findings (post-US). Pre-US reported sensitivity and specificity of 52% and 53%, respectively, while post-US reported sensitivity and specificity of 85% and 94% ($P < 0.05$), and 15 out of 51 patients (30%) had their therapy changed ⁽²⁷⁾.

In a single-center study including 423 patients, 16 out of 90 recurrent lesions were missed in US, but FDG-PET-CT correctly identified those ⁽²⁸⁾, which is analogous to our findings. Similarly, in a study of 34 patients with 30 tumor lesions in the neck, US detected 18 (including three that were FDG-negative), CECT identified 14, and FDG-PET identified 27 lesions ⁽¹⁰⁾.

Concerning the detection of pulmonary metastases, ^{18}F -FDG PET/CT showed F-18 FDG avid pulmonary nodules in four patients with possible benign nature on diagnostic CT. During follow up, two patients of them were confirmed to be

benign lesions (false positive) by diagnostic CT & undetectable serum thyroglobulin and only one patient showed increase in nodule size (true positive). Whereas, 6 out of 16 patients with suspicious pulmonary nodules by CT, didn't show any ^{18}F -FDG uptake which may be related to the small size of those lesions that were beyond the resolution of ^{18}F -FDG PET/CT.

Regarding the assessment of mediastinal LNs, ^{18}F -FDG PET/CT succeed in detection of mediastinal LNs in 5 out of 113 patients which were not suspicious in chest CT. This may be explained that ^{18}F -FDG PET/CT can detect malignant lymph nodes despite their normal size in diagnostic CT.

Our findings suggested that ^{18}F -FDG PET should be performed on all patients with Hurthle cell thyroid cancer as part of their initial postoperative staging as the majority of Hurthle cell variant in our study demonstrated significant positive findings in FDG PET/CT, which is comparable to study by *Daniel et al.*, who found that ^{18}F -FDG PET has excellent diagnostic accuracy in Hurthle cell thyroid cancer patients, surpassing CT and radio-iodine scan, and predicting patient outcome ⁽²⁹⁾.

Trivino et al.,⁽³⁰⁾ in a study of 81 patients to investigate the value of ¹⁸F-FDG PET/CT in high/intermediate risk patients; reported a sensitivity of 92.5%, specificity of 90.2%, PPV of 90.2%, and NPV of 92.5% which are comparable to our results, as majority of positive patients were of intermediate & high risk group with F18-FDG PET/CT in detecting residual disease showed sensitivity of 92.5%, specificity 94.4%, PPV 87.8%, and NPV 98.8 %.

In the current study, the ¹⁸F-FDG PET/CT findings led to a change in the initial staging based on the TNM classification with a subsequent change in management in 26 of patients in whom 12 patients underwent re-surgery for loco regional disease and

CONCLUSION:

¹⁸F-FDG in comparison to stand-alone conventional radiological imaging modalities, PET/CT performed prior to RAI treatment may identify additional loco-regional and metastatic tumor lesions in some DTC patients, particularly those with indeterminate or normal radiological findings while elevated baseline serum

increased radioiodine doses in other 8 patients.

Similar to our study results, Lee et al, analyzed retrospectively 286 patients with intermediate/ high-risk thyroid cancer, where ¹⁸F-FDG PET/CT discovered new lesions in 39 out of 286 patients (14 %) in comparison with the post-therapy I-131 scan and the therapy has changed in 30 patients (10 %) ⁽³¹⁾.

Gianlorenzo et al., on their work also came to the conclusion that early F-18 FDG PET/CT is advised for initial staging and therapy planning in DTC since it allows for the appropriate surgical approach and eliminates additional unnecessary studies ⁽³²⁾.

thyroglobulin, intermediate to high risk group and patients with invasive Hurthle cell carcinoma. This could change the treatment plan and dose of radioactive iodine therapy.

Study limitations: small sample size, retrospective study & different histopathological types are included in this study.

REFERENCES:

1. **Surveillance Research Program NCI.** Fast stats: an interactive tool for access to SEER cancer statistics. Available at: <https://seer.cancer.gov/faststats>; 2018.
2. **Institute NC. SEER cancer stat facts: thyroid cancer.** Available at: <https://seer.cancer.gov/statfacts/html/thyro.html>; 2018.
3. **Giannoula E, Iakovou I, Verburg FA.** Long term quality of life in differentiated thyroid cancer patients after thyroidectomy and high doses of ¹³¹I with or without suppressive treatment. *Hell J. Nucl. Med.* 21 (1):69-73; 2018.
4. **Ronga G, Toteda M, D'Apollo R, et al.** Lymph node metastases from differentiated thyroid carcinoma: does radioiodine still play a role? *Clin. Ter.* 163:377-381; 2012.
5. **Choudhury PS and Gupta M.** Differentiated thyroid cancer Theranostics: radioiodine and beyond. *Br. J. Radiol.* 91 (1091): 20180136; 2018.
6. **Haugen BR, Alexander EK, Bible KC, et al.** 2015 American Thyroid association management guidelines for adult patients with thyroid nodules and differentiated thyroid cancer: the American Thyroid Association guidelines task force on thyroid nodules and differentiated thyroid cancer. *Thyroid* 26:1-133, 2016.
7. **Miller ME, Chen Q, Elashof D, et al.** Positron emission tomography and positron emission tomography-CT evaluation for recurrent papillary thyroid carcinoma: meta-analysis and literature review. *Head Neck* 33 (4):562-565; 2011.
8. **Makeief M, Burcia V, Raingeard I, et al.** Positron emission tomography-computed tomography evaluation for recurrent differentiated thyroid carcinoma. *Eur. Ann. Otorhinolaryngol Head Neck Dis* 129 (5):251-256; 2012.
9. **Feine U, Lietzenmayer R, Hanke JP, et al.** Fluorine-¹⁸FDG and iodine-131-iodide uptake in thyroid cancer. *JNM.* 37 (9): 1468-1472; 1996.
10. **Leboulleux S, El Bez I, Borget I, et al.** Post radioiodine treatment whole-body scan in the era of 18-fluorodeoxyglucose positron emission tomography for differentiated thyroid carcinoma with elevated serum thyroglobulin levels. *Thyroid* 22 (8):832-838; 2012.
11. **Dietlein M, Scheidhauer K, Voth E, et al.** Fluorine-18 fluoro-deoxyglucose positron emission tomography and iodine-131 whole-body scintigraphy in the follow-up of differentiated thyroid cancer. *Eur. J. Nucl. Med.* 24 (11):1342-134; 1997.

12. **Dionigi G, Fama' F, Pignata SA, et al.**. Usefulness of PET-CT scan in recurrent thyroid cancer. *World J Otorhinolaryngol Head Neck Surg.* 6 (3):182–187; 2020.
13. **Kolodziej M, Saracyn M, Lubas A, et al.**. Evaluation of the usefulness of positron emission tomography with [¹⁸F] fluorodeoxyglucose performed to detect non-radioiodine avid recurrence and/or metastasis of differentiated thyroid cancer: a preliminary study. *Nucl. Med. Rev.* 24 (2):63-69; 2021.
14. **Almeida LS, Araújo ML, Santos AO, et al.**. Head-to-head comparison of F-18 FDG PET/CT in radioiodine refractory thyroid cancer patients with elevated versus suppressed TSH levels a pilot study. *Heliyon* 6 (3):e03450; 2020.
15. **Maamoun N, Moustafa H, Zaher A, et al.**. Value of initial ¹⁸FDGPET/CT in change of management of patients with differentiated thyroid cancer as compared to post ablative whole body iodine scan. *Egypt J. Nucl. Med.* 21(2):34-49; 2020.
16. **Rosenbaum-Krumme SJ, Görges R, Bockisch A, et al.**. ¹⁸F-FDG PET/CT changes therapy management in high-risk DTC after first radi - oiodine therapy. *Eur. J. Nucl. Med. Mol. Imaging* 39:1373-1380; 2012.
17. **Piccardo A, Foppiani L, Morbelli S, et al.**. Could ¹⁸FDG-PET/CT change the therapeutic management of stage IV thyroid cancer with positive 131-I whole body scan? *Q. J. Nucl. Med. Mol. Imaging* 55 (1):57-65; 2011.
18. **Abdelhamed, HM, Mohammed, AE, Fattahalla, MS. et al.**. Additive value of 18FDG-PET/CT to positive 131I whole body scan in recurrent differentiated thyroid cancer patients with potential influence on treatment strategy: single Egyptian center experience. *Egypt J. Radiol. Nucl. Med;* 2022.
19. **Mulla M and Schulte KM:** The accuracy of ultrasonography in the preoperative diagnosis of cervical lymph node (LN) metastasis in patients with papillary thyroid carcinoma: A meta-analysis. *Eur. J. Radiol.* 81:1965; author reply 1966; 2012.
20. **Nascimento C, Borget I, Al Ghuzlan A, et al.**. Postoperative fluorine-18-fluorodeoxyglucose positron emission tomography/computed tomography: an important imaging modality in patients with aggressive histology of differentiated thyroid cancer. *Thyroid*; 25 (4):437-444;. 2015.

21. **Stokkel MP, Duchateau CS, Dragoiescu C.** The value of FDG-PET in the follow-up of differentiated thyroid cancer: a review of the literature. *Q. J. Nucl. Med. Mol. Imaging*; 50 (1):78-87; 2010.
22. **Seib CD, Sosa JA.** Evolving Understanding of the Epidemiology of Thyroid Cancer. *Endocrinol Metab. Clin. North. Am*; 48 (1):23-35; 2019.
23. **23. Chung JK, So Y, Lee JS, et al.** Value of FDG PET in papillary thyroid carcinoma with negative 131-I whole-body scan. *J. Nucl. Med.* 40 (6):986-992; 1999.
24. **24. John I. Lew and Carmen C. Solorzano.** *The Oncologist.* 15(3): 253–258; 2010.
25. **Amin MB, Greene FL, Edge SB, et al.,** The Eighth Edition AJCC Can- cer Staging Manual: Continuing to build a bridge from a popula- tion-based to a more "personalized" approach to cancer stag- ing. *CA Cancer J. Clin.* 67 (2):93-99; 2017.
26. **Francis GL, Waguespack SG, Bauer AJ, et al.,** Management Guide- lines for Children with Thyroid Nodules and Differentiated Thyroid Cancer. *Thyroid.* 25 (7):716-759; 2015.
27. **Martin M.B, Kråkenes J, Brauckhoff K, et al.,** Post-PET ultrasound improves specificity of 18F-FDG-PET for recurrent differentiated thyroid cancer while maintaining sensitivity. *Acta Radiologica* Volume 56, Issue 11, November, Pages 1350 -1360; 2015.
28. **Seo JH, Lee SW, Ahn B-C.** Recurrence detection in differentiated thyroid cancer patients with elevated serum level of anti-thyroglobulin antibody: special emphasis on using ¹⁸F-FDG PET/CT. *Clin Endocrinol (Oxf)*; 72: 558–563. Crossref. PubMed; 2010.
29. **Daniel A.P, Schöder H, Gönen M, et al.** Diagnostic accuracy and prognostic value of ¹⁸F-FDG PET in Hürthle cell thyroid cancer patients. *J. Nucl. Med.* 2006 Aug; 47 (8):1260-6; 2006.
30. **Triviño Ibáñez EM, Muros MA, Torres Vela E, et al.,** The role of early ¹⁸F-FDG PET/CT in therapeutic management and carcinoma. *Endocrine*; 51(3):490-498; 2016.
31. **J.W. Lee, S.M. Lee, D.H. Lee, Y.J. Kim,** Clinical utility of ¹⁸F-FDG PET/CT concurrent with 131I therapy in intermediate-to-high-risk patients with differentiated thyroid cancer: dual-center experi- ence with 286 patients. *J. Nucl. Med.* 54 (8), 1230-1236; 2013.
32. **Gianlorenzo D, Fausto F, Salvatore A P, et al.** *World Journal of Otorhinolaryngology - Head and Neck Surgery*, Volume 6, Issue 3, September, Pages 182-187; 2020.