

**Original Article, PET/CT.**

## **The Added Value of FDG PET/CT in Assessment of Pleural Metastases in Breast Cancer Patients.**

Elkholy. E<sup>1</sup>, Aly A. M. <sup>1</sup>, Kandeel A <sup>2</sup>, Badr A. S<sup>1</sup>

<sup>1</sup> Department of Nuclear Medicine and Radiation Oncology, National Cancer Institute (NCI),

<sup>2</sup> Nuclear Medicine Unit, Faculty of Medicine Center, Cairo University, Egypt.

### **ABSTRACT:**

**Background:** The purpose of this study was to investigate the viability of using 18 F FDG positron emission computed tomography (PET/CT) to detect breast cancer pleural metastases and how this information relates to patient survival and outcome. **Methods:** 537 patients with pathologically confirmed breast cancer who had received PET/CT scanning at various phases of the disease were included in a retrospective research. 115 patients exhibited a variety of pleural lesions, which were subsequently verified or excluded by cytological analysis, a follow-up PET/CT scan, or other traditional radiology. The prognosis and OS were then correlated with these findings. **Results:** The average age of the 115 patients is 53±12. 99 patients (86.1%) had additional distant sites of metastases. Analyses of various types of pleural involvement revealed that 40% had

effusion, 33.3% had nodular thickening, 22% had diffuse thickening, and 4.7% had a combination of these patterns. PET/CT had a 93% accuracy rate for detecting pleural metastases linked to breast cancer, with sensitivity and specificity of 92.5% and 94.1%, respectively. Pleural metastases were negatively correlated with overall survival and prognosis ( $p<0.001$ ), and their association with additional distant metastases made the situation much worse ( $p<0.001$ ).

**Conclusions:** The combined presence of large and FDG avid pleural lesions can be a sensitive marker to suspect pleural metastases. While reporting a worrisome pleural lesion, PET/CT qualitative and quantitative assessment is helpful as it can influence and help map out the therapeutic approach to enhance the overall prognosis and survival.

**Keywords:** prognosis, survival, pleural, metastatic, 18F-FDG PET/CT, breast cancer.

---

**Corresponding author:** Esraa Elkholy.

**E-mail:** [esraa.roshdy@yahoo.com](mailto:esraa.roshdy@yahoo.com)

## INTRODUCTION:

Globally, breast cancer is the most prevalent malignant illness affecting women <sup>[1]</sup>. The advancements made in breast cancer early detection, which have enhanced survival. However, since the liver, bone, and lung are the most prevalent metastatic sites for breast cancer, some patients will recur as a result of distant metastases. Actually, lung or bone metastases affect about 60% of people with metastatic breast cancer at some point in their lives <sup>[2]</sup>. For most patients with breast cancer, metastatic illness is the primary cause of mortality. Even with more advanced tactics aimed at the original tumor, systemic therapies for metastases are not as successful; <sup>[3]</sup> The main course of treatment for non-metastasizing breast cancers is primary tumor surgical resection; however, for locally advanced disease and

distant metastases, additional treatment modalities (chemotherapy, hormone therapy, or radiation therapy) are required. <sup>[4,5]</sup> Breast cancer pleural metastases typically manifest as pleural thickening or nodularity and are often linked to malignant pleural effusion. <sup>[6,7]</sup> It's critical to comprehend the potential risks associated with utilizing PET/CT while diagnosing pleural illness in order to avoid misdiagnosis. Increased FDG avidity can be a sign of infectious pulmonary processes such pneumonia and pleuritic, which manifest as pleural thickening. Consequently, getting a clinical history and any previous imaging data that points to an infection is crucial. <sup>[8]</sup> The purpose of this retrospective study is to evaluate how well PET/CT can diagnose pleural metastases in patients with breast cancer <sup>[9]</sup>.

## PATIENTS and METHODS:

**Study population and illness state:** 537 adult patients with pathologically confirmed breast cancer were included in this retrospective analysis. Between January 2020 and December 2023, all of them were referred to the National Cancer Institute's (NCI) Nuclear Medicine unit for first pre-therapy and/or follow-up assessment. Clinical data, such as age, sex, detailed pathology, imaging modality

findings, response to treatment, and analytical survival statistics, were taken out of the medical records. Adult patients with a diagnosis of breast cancer or pathologically established breast adenocarcinoma are eligible for inclusion. Benign breast lesions and breast pathologies other than cancer, such as lymphomas and sarcomas, are excluded factors. History of a second primary cancer,

and lastly, insufficient information. Techniques for diagnosis 18-F FDG PET/CT imaging. Patient preparation includes fasting for four to six hours before the study, refraining from strenuous physical activity for twenty-four hours beforehand, and ensuring that the blood glucose level is no higher than 180 mg/dl before the F18 FDG is administered. A dosage of about 0.14 mCi/kg body weight of 18-F FDG was administered. Image collection was accomplished using a GE Medical System, USA, Discovery PET-CT scanner. 45 to 60 minutes after the injection of tracer, scanning began. The patients were first assessed while lying down with their arms raised. A CT scan was performed using the following parameters: 140 kV, 80

#### **Quantitative assessment:**

The maximum standardized uptake value (SUV max) is recorded after a spherical volume of interest (VOI) covering the regions of interest (pleural lesions/metastases) is put on the fused images for semi-quantitative analysis. Criteria for interpretation: Initial and follow-up evaluations were carried out. A subset of patients exhibiting FDG avidity in their mass lesions or worrisome pleural effusions were referred for cytological evaluation and maintained under surveillance. Follow up: If there was an

mA, PITCH: 1.375, slice thickness: 3.75 mm, and the scan was performed from the cranial vault down to the mid-thighs. No CT contrast material was used. Patients underwent both PET and CT scans while their tidal breathing was normal. Following that, PET acquisition (6–8 bed positions; acquisition time, 2 min/bed position) was carried out. Using the ordered subsets expectation maximization approach, the image was iteratively reconstructed from the raw emission data acquired, using CT-derived attenuation correction. Data Analysis: PET/CT scans were examined using the GE multi-planar review station from the manufacturer, which allows two skilled nuclear medicine doctors to analyze the CT, PET, and fused PET/CT images.

increase in the size of the prior lesions, an increase in activity, or the emergence of new active lesions, it was recorded as evidence of progression in the follow-up PET/CT or other radiologic modality. The 115 patients who had pleural effusions or suspected pleural lesions found by PET/CT were categorized as follow-up for the analysis.

1. Aspiration cytology was used to confirm that the true positive patients had metastatic cells, or follow-up PET/CT or CT imaging was used to demonstrate the

actual progression of the pleural lesions, whether they were nodular or diffuse pleural thickening. 2. Cytological findings also validated true negative patients whose PETCT data initially revealed minimal or non-significant FDG uptake favoring an inflammatory origin rather than a malignant pleural lesion. 3. Two patients were identified as false positives because their pleural effusion had a high SUV max value and they produced inflammatory exudate during cytological aspiration, which may have been caused by an underlying infection. 4. Finally, false negative patients with pleural lesions that had low SUV max values and/or mill metric CT sizes. These patients later reported clinically that they had a persistent pleural

#### **Statistical methods:**

The Statistical Package for Social Sciences (SPSS) version 27 was used for data management and analysis. The averages and standard deviations, as well as the applicable medians and/or ranges, were used to summarize the numerical data. Numbers and percentages were used to summarize the categorical data. The percentages and figures were used to estimate the frequency. Mathematical data were examined for normalcy using the Shapiro-Wilk and **Kolmogrov-Smirnov**

effusion that needed aspiration cytology and eventually showed metastatic deposits from the breast. Alternatively, follow-up PET/CT or CT imaging revealed that the mill metric pleural thickening size had progressed into significant, concerning lesions with high FDG avidity. Next, the disease condition was classified as either stable, regression, or progression. Patients were classified as dead if they were not followed up with or if they were declared deceased by calling the family contact listed on the NCI system. Overall survival: The survival rate was calculated using an estimated time frame from the start of treatment to the patient's death or last follow-up appointment.

tests. When comparing the independent groups with regard to categorical data, chi square or Fisher's tests were utilized. The student's t-test was used to compare two sets of regularly distributed numerical data, whereas the Mann-Whitney test was used to compare non-normally distributed numerical variables. Spearman's correlation coefficients, which range from -1 to +1, were computed to assess the degree of relationship between the non-normally distributed measures. The Kaplan

and Meier method was employed to estimate the overall survival. From the date of diagnosis to the date of death or the last follow-up, the overall survival was computed. The log-rank test was used to evaluate differences between the survival curves. A 2x2 table was used to calculate

## RESULTS:

This study included 537 breast cancer females that were recruited from Nuclear Medicine Unit, National Cancer Institute, Cairo University. The features of research participants are displayed in Table (1). The mean age of females with breast cancer was  $53 \pm 12$  years. The majority of lesions located in the upper outer quadrant (63.9%). Around 78% of patients performed local surgery (78.2%). The majority of breast cancer patients' pathology were invasive duct carcinoma (78.2%), followed by invasive lobular carcinoma (14.9%). Concerning hormonal receptor status, the majority of cases were estrogen and progesterone receptor positive

the PET CT's sensitivity, specificity, positive predictive value, negative predictive value, and overall accuracy in comparison to the gold standard approach (cytology and/or follow-up). Every test had two tails, and a probability (p-value) of less than 0.05 is regarded as significant.

(67.6% & 66.7%) respectively, while only 233 (43.4%) were HER2Neu positive. Three hundred and eighteen (59.2%) cases developed distant metastases. These characteristics are illustrated on Table (1). Out of the entire patient population as shown in Table (2), the great percentages of metastatic lesions were nodal metastasis, followed by bone, pulmonary, pleural, liver, and lastly peritoneal metastases respectively with percentages of around 41.2%, 29.4%, 25.7%, 21.4% & 16.2% respectively, and lastly 2.4% only had peritoneal metastases; and unfortunately some patients suffered from multiple metastatic lesions at the same time.

**Table (1): Characteristics of the study participants.**

<b>Clinico-pathological characteristics</b>	<b>Number</b>	<b>Percentage (%)</b>
<b>Age: &lt;50 Year</b>	229	42.6
<b>≥50 Year</b>	308	57.4
<b>Site:</b>		
▪ <b>LIQ</b>	96	17.9
▪ <b>LOQ</b>	48	8.9
▪ <b>UIQ</b>	50	9.3
▪ <b>UOQ</b>	343	63.9
<b>Local surgery:</b>		
▪ <b>Yes (n=420)</b>	420	78.2
○ <b>MRM</b>	312	74.3
○ <b>CBS</b>	108	25.7
▪ <b>No</b>	117	21.8
<b>Pathology:</b>		
▪ <b>IDC</b>	420	78.2
▪ <b>ILC</b>	80	14.9
▪ <b>Others</b>	37	6.9
<b>Hormonal receptors:</b>		
▪ <b>ER</b>		
○ <b>Positive</b>	363	67.6
○ <b>Negative</b>	174	32.4
▪ <b>PR</b>		
○ <b>Positive</b>	358	66.7
○ <b>Negative</b>	179	33.3
▪ <b>Her2neu</b>		
○ <b>Positive</b>	233	43.3
○ <b>Negative</b>	237	44.1
○ <b>Equivocal</b>	67	12.5
<b>Distant metastases:</b>		
▪ <b>Yes</b>	318	59.2
▪ <b>No</b>	219	40.8
<b>Pleural lesions:</b>	115	21.4

**Table (2): Prevalence of single and multiple organ metastases in patients' population (n=318)**

	(n=537)	(%)
<b>Non metastatic patients</b>	<b>219</b>	<b>40.8</b>
<b>Metastatic patients</b>	<b>318</b>	<b>59.2</b>
• <b>Single organ metastases</b>	<b>139</b>	<b>43.7</b>
Nodal	50	35.9
Bone	30	21.6
Pulmonary	31	22.3
Pleural	8	5.8
Liver	11	7.9
Peritoneal	1	0.7
Others	8	5.8
• <b>Multiple organ metastases</b>	<b>179</b>	<b>56.3</b>
<b>Total</b>	<b>318</b>	<b>100%</b>

**Pleural metastases analysis:** In our study group 115 (21.4%) of patients had pleural lesions. Analyzing the pleural lesions a shown in Table (3),

**Table (3): Analysis of pleural lesions with its associations (n=177):**

<b>Pathological pleural pattern</b>	<b>Number</b>	<b>Percentage (%)</b>
<b>Effusion</b>	71	40.1
<b>Diffuse pleural thickening</b>	39	22
<b>Nodular pleural thickening</b>	59	33.3
<b>Mixed nodular and diffuse thickening</b>	4	2.3
<b>Lymphangitis carcinomatosis</b>	4	2.3
<b>Total number of lesions</b>	177	100%

we found 177 lesions, in which 71 patients presented with pleural effusion (40.1%), 39

(22%) were diffuse pleural thickening, and 59 (33.3%) were nodular pleural lesions.

and 4.7% had a combination of these patterns. The presence of effusion was either as a standalone finding in 21 (11.8%) or it was associated mostly with the presence of nodular pleural lesions in 32 (18.1%) Diffuse pleural thickening were presented in 20 (11.3%), and even some rare 4 (2.3%) cases showed the presence of these 3 patterns simultaneously. 99 (86.1%) patients out of the total 115 patients with suspected metastatic pleural lesions were

suffered from other distant metastases. By the quantitative CT assessment, the median size of these lesions was 2 cm ranging from (0.3cm-16.4cm). PET/CT quantitative assessment median value for SUV max was 6 ranging from (1.5-28.6) (Figure 1). There was a fair degree of positive correlation between CT size of the lesion and PET/CT SUV max ( $r:0.47$ , P value  $<0.001$ ). Aiming to find a relation between SUV max and different risk factors, As shown in table (4),

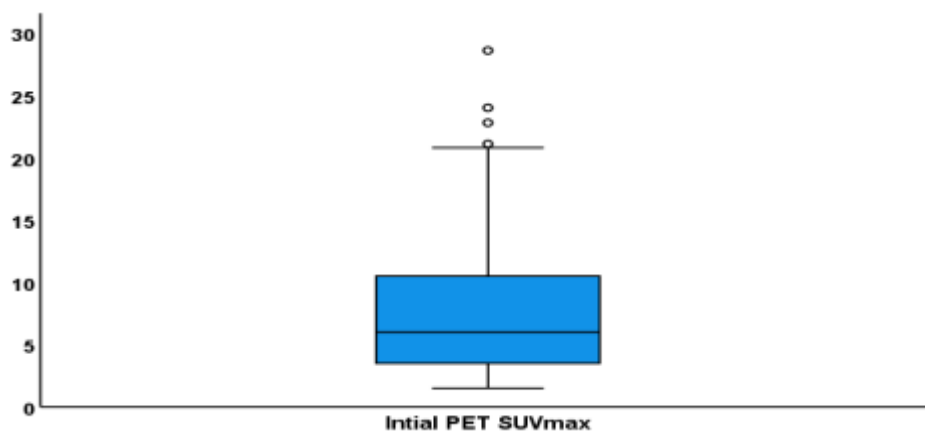


Figure (1): Box plot representing PET/CT SUV max for pleural lesions.



Table (4): SUV max in relation to different factors in Patients with pleural lesion:

	PET SUV max	
	Median (range)	P value
<b>Age:</b> <50 Year	7.7 (2.1-24)	<b>0.046</b>
≥50 Year	4.7 (1.5-28.6)	
<b>Side:</b> Left	6 (1.7-28.6)	0.194
Right	4.8 (1.5-20.6)	
Bilateral	9.6 (3.2-18.3)	
<b>Site:</b> LIQ	4.1 (1.6-20.8)	0.256
LOQ	3.5 (3.5-3.5)	
UIQ	11.3 (1.5-24)	
UOQ	6.2 (1.9-28.6)	
<b>Pathology:</b> IDC	6 (1.5-28.6)	0.858
ILC	4.7 (2-20.8)	
Others	7 (3.5-13.4)	
<b>Hormonal receptors:</b>		
▪ ER Positive	4.8 (1.5-28.6)	0.034
▪ ER Negative	8.6 (1.6-22.8)	
▪ PR Positive	4.7 (1.5-28.6)	0.058
▪ PR Negative	9.7 (1.6-24)	
▪ Her2neu Positive	6.7 (1.6-20.8)	0.890
▪ Her2neu Negative	5.5 (1.5-28.6)	
▪ Her2neu Equivocal	4.7 (2.7-22.8)	

SUV max was significantly higher in patients younger than 50 years compared to older females (p value 0.046), also SUV

max was significantly higher among females with ER negative compared to patients with ER positive (p value 0.034).

Meanwhile, there was no statistically significant difference in level of SUV max in relation to the rest of the other risk possible factors in our data (side, site of lesion, local surgery, pathology, PR, HER2Neu). The reference in our study design to assess the outcome was the availability of cytology from the pleural lesions in some patients and/or follow up by PET/CT or other conventional radiological studies available in our institution such as CT, MRI, and/or sono-mammography. Out of the 115 initially assumed pleural lesions (proven by PET/CT). 75 (64.9%) were true positive, 32 (28.1%) true negative patients, 2 (1.8%) false positive patients, and lastly 6 (%5.3) false negative patients. PET/CT proved to has favorable sensitivity reaching 92.5%, specificity reaching 94.1%, positive predictive value reaching 97.4%, negative

predictive value reaching 84.2%, and an overall accuracy reaching 93%. From the patients who initially had pleural lesions (n=115) follow up data by PET/CT was available for only 10 patients, 9 of them showed marked disease progression while only 1 of them showed a mild regressive course. In current study patients with pleural lesions had a far worse course than the non-pleural patients evident by the progression of 62.6% of the patients in comparison with the progression of non-pleural positive patients showing progression in only 28.7%, the regressive course between these 2 groups with pleural positive patients showing a minor regression of 10.4% only versus the non-pleural patients' regressive course of 25.6%. (Table 5)

**Table (5): Overall prognosis of pleural positive patients in comparison with non-pleural patients:**

Overall prognosis	Pleural positive patients (n=115 (%))	Non pleural patients (n=422 (%))	P value
<b>Progression</b>	72 (62.6%)	121 (28.7%)	<b>&lt; 0.00001</b>
<b>Regression</b>	12 (10.4%)	108 (25.6%)	
<b>Stationary</b>	31 (26.9%)	193 (45.7%)	

Table (6) illustrates that patients with nodular pleural thickening had significantly greater CT lesion size and PET/CT SUV

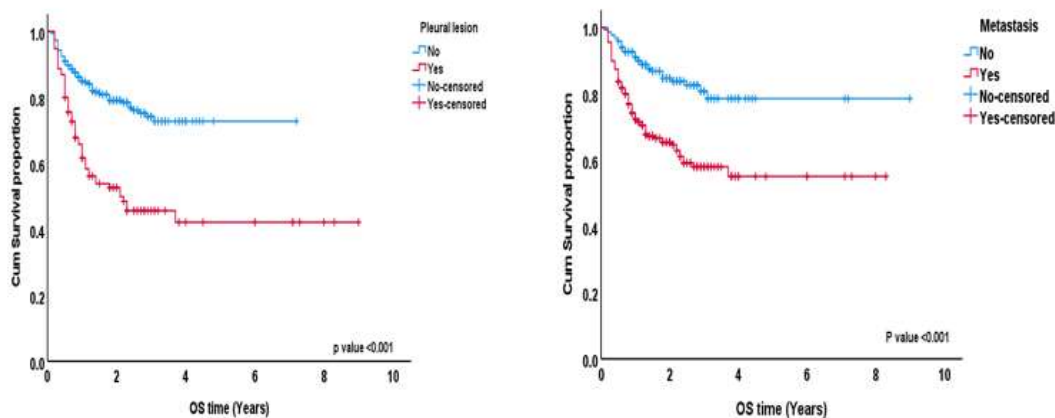
max when compared to diffuse pleural thickening (p values of 0.020 and <0.001, respectively). Regarding other variables,

nodular and diffuse pleural lesions do not differ statistically significantly.

**Survival analysis:**

The follow-up period ranged from 1 to 108 months, with a median of 17 months. Patients with metastatic disease have a much worse overall survival than other patients, as demonstrated in (Figure 2) (p value <0.001). Additionally, the overall

survival of patients with pleural lesions is significantly poorer than that of patients without pleural lesions (p value <0.001). (Scheme 5). In the meantime, there was no statistically significant variation in overall survival concerning (age, kind of pathology, ER, PR, HER2Neu, presence of axillary lymph node, side of primary, position of primary, performing surgery, and presence of active lesion).



**Figure (2): Kaplan and Meier curve representing overall survival in relation to presence of pleural lesions and presence of other metastasis.**

**Table (6): Nodular and diffuse pleural lesions in relation to different risk factors:**

	<b>Nodular n (%)*</b>	<b>Diffuse thickening n (%)*</b>	<b>P value</b>
<b>Age (Mean ±SD)</b>	54 ±12	55 ±12	0.536
<b>Age group</b>			0.263
▪ <50 Year	23 (69.7)	10 (30.3)	
▪ ≥50 Year	32 (56.1)	25 (43.9)	
<b>Site</b>			NA
▪ LOQ	0 (0)	1 (100)	
▪ UIQ	6 (60)	4 (40)	
▪ UOQ	39 (72.2)	15 (27.8)	
▪ LIQ	10 (40)	15 (60)	
<b>local surgery</b>			0.719
▪ No surgery	13 (59.1)	9 (40.9)	
▪ CBS	12 (54.5)	10 (45.5)	
▪ MRM	30 (65.2)	16 (34.8)	
<b>Pathology</b>			0.785
▪ IDC	41 (59.4)	28 (40.6)	
▪ ILC	10 (62.5)	6 (37.5)	
▪ Others	4 (80)	1 (20)	
<b>ER</b>			0.638
▪ Positive	37 (58.7)	26 (41.3)	
▪ Negative	18 (66.7)	9 (33.3)	
<b>PR</b>			0.167
▪ Yes	34 (55.7)	27 (44.3)	
▪ No	21 (72.4)	8 (27.6)	
<b>Her 2</b>			0.677
▪ Positive	23 (60.5)	15 (39.5)	
▪ Negative	27 (64.3)	15 (35.7)	
▪ Equivocal	5 (50)	5 (50)	
	<b>Median (range)</b>	<b>Median (range)</b>	
<b>CT size (cm)</b>	2.1 (0.3- 16.4)	1.2 (0.5-2.9)	<b>0.020</b>
<b>PET/CT SUV max</b>	9.1 (2.1-28.6)	3.6 (1.5-14.1)	<b>&lt;0.001</b>

## DISCUSSIONS:

For breast cancer patients, the best course of treatment and the assessment of their response to therapy depend heavily on the timely detection of distant metastases. It has been reported that FDG PET/CT functional imaging provides clinical relevance in a number of cancers. Breast cancer pleural metastases can develop during the course of the disease or at the time of diagnosis. The most frequent pleural malignancy is metastatic involvement, which is frequently linked to lymphoma, breast cancer, and original bronchogenic carcinoma <sup>[10]</sup>. According to the current retrospective analysis, nodal metastasis accounted for the largest percentage of metastatic lesions in our group, with lung, pleural, bone, liver, and other metastases following. Regretfully, the group of patients who experienced multiple metastatic lesions concurrently accounted for a larger number of metastatic patients—56.3%. This was consistent with findings by **Saricam et al.** that breast cancer typically spreads to the liver, lungs, and bones. Lung and bone metastases were seen in nearly 60% of patients with advanced breast cancer <sup>[11]</sup>. Based on an analysis of the current study sample, 115 patients (21.4%) reported nodular pleural thickening, diffuse thickening, or effusion as their pleural lesions. These lesions were either isolated or present in combinations with other patterns. Pleural effusion was the most often observed pattern in the majority of cases, followed by nodular pleural thickening and

diffuse pleural thickening. **Duysinx et al.** examined how 98 patients with pleural thickening and/or an exudative pleural effusion could be classified as having benign or malignant pleural illness using FDG PET/CT. The claim that PET/CT was more sensitive than CT alone in detecting pleural involvement was further supported by **Toaff et al.** <sup>[12]</sup>. FDG PET/CT demonstrated remarkable sensitivity of 92.5%, specificity of 94.1%, PPV of 96.4 %, NPV of 84.2 %, and overall accuracy of 93% in detecting and classifying the pleural lesions in our investigation. Using FDG PET/CT, which was validated by FNAC results, it was possible to appropriately diagnose 64.9% of the 115 patients with suspected pleural lesions as having metastatic nature and to rule out the possibility of malignancy in around 28.1% of the patients. Only two patients (1.8%) had false positive results, which were primarily brought on by effusion combined with high FDG avidity. False positive results only included 2 (1.8%) patients and were mainly caused by effusion accompanied by intense FDG avidity of SUV max above 4. On cytological assessment by FNAC it was later proved to be of inflammatory origin rather than of malignant metastases with a cytology revealing an exudative nature of the aspiration. False negative results were discovered in 6 (5.3%) patients and likely contributed to the small millimetric sizes of the pleural lesions with no significant FDG avidity or beyond PET

resolution. Other research showed that PET/CT may identify malignant pleural effusions with a wide range of sensitivity (75%–93%) and specificity (88%–96%). Depending on the original tumor, sample preparation, and cytologist experience, this significant variation could arise from a 60% mean sensitivity rate of pleural fluid cytology <sup>[13,14]</sup>. PET/CT showed a sensitivity of 81% and specificity of 74% in a review of 14 trials, including 407 patients. As a result, the use of PET/CT in the diagnosis of malignant effusion was not recommended <sup>[15]</sup>. PET/CT can be a trustworthy diagnostic technique, nevertheless, as evidenced by a different study by **Saricam et al.** that found that it had a 91.9% sensitivity and 91.3% specificity in identifying malignant pleural effusions <sup>[11]</sup>. Globally, a meta-analysis research examining PET/CT's ability to distinguish between benign and malignant pleural lesions revealed sensitivity and specificity ranges of 76% to 95% and 67% to 82%, respectively <sup>[16]</sup>. In addition, **Duysinx et al** assessed the efficacy of FDG-PET/CT in distinguishing between benign and malignant pleural illness in 98 patients with exudative pleural effusions and/or pleural thickening. The corresponding values for sensitivity, specificity, PPV, and NPV were 96.8%, 88.5%, 93.8%, and 93.9%. These values again demonstrated results that closely matched our own <sup>[9,17]</sup>. Additional results that elucidated the relationship between the existence of malignancy and the macroscopic appearance of the pleura during thoracoscopy were also published by **Saricam et al.** All nodular pleural lesions were found to be malignant, whereas

56.3% of patients with diffuse pleural thickening turned out to have cancer. Similarly, the nodular lesions' mean value of FDG uptake was considerably higher than the pleura's diffuse thickening <sup>[11]</sup>. It was consistent with our findings since patients with nodular pleural thickening had considerably higher PET/CT SUV max values than patients with diffuse pleural thickening, and there was a strong association between the lesion's CT size and SUV max. Comparing BPEs and MPEs, Zhang et al. discovered that MBEs had greater pleural SUV max, nodules, and increased pleural thickening. For the identification of MPE, PET/CT demonstrates sensitivity and specificity of 89%–100% and 67–94%, respectively <sup>[18]</sup>. Additionally, it was corroborated by **Budak et al.** that the MPE had higher rates of supra-diaphragmatic lymph node and pleural thickening than the BPE <sup>[19]</sup>. The patients in our study sample with pleural lesions had a far worse course than the non-pleural patients evident by the progression of 69.1% while progression of non-pleural positive patients was only 28.7%. **Simsek et al.** discovered that patients with single-site metastasis had a significantly better prognosis than patients with multiple metastatic sites. This finding aligns with the findings of our study, since most patients (56.3%) had multiple metastatic sites at initial presentation and had worse overall survival and prognosis overall <sup>[20]</sup>. Patients with metastatic disease have a much poorer overall survival than other patients, according to the data from our research population. Additionally, compared to patients

without pleural lesions, those with pleural lesions had a much poorer overall survival rate. In contrast, our study's findings showed no statistically significant variation in overall survival when compared to other risk factors, such as age. In the present study population, we found out that more than one third of cases with pleural affection had their breast cancer primary located in the LIQ (35.4%), which is theorized to be associated with the crossing of the lymphatic vessels in the retrosternal region that could be the cause of relatively higher incidence of development of pleural metastases with such cases. Similar to this, **Agalioti et al.** claimed that local proximity—as opposed to bloodstream—may allow breast cancer to spread to the pleura. According to **Pokieser et al.** pleural effusion was considerably greater in invasive ductal carcinomas localized in the inner quadrants as the initial site of metastasis. This finding may be linked to a higher incidence of internal mammary lymph node metastasis [21,22]. In this work, we examined the diagnostic precision of FDG PET/CT in determining the pathological character of pleural metastases and whether or not this has

### CONCLUSIONS:

FDG PET-CT has high sensitivity and specificity for the detection of the true pathology of metastatic pleural lesions. (Sensitivity of 92.5%, specificity of 94.1%, PPV of 97.4%, NPV of 84.2 %, and total accuracy of 93%). Median follow-up of the pleural metastatic cases (median OS was 17 months. OS rate at 1 years = 66% and they show

an impact on the prognosis of patients with pleural metastases, whether or not they are associated with other distant metastases. Comprehending these traits and their predictive significance in illnesses may facilitate tailored therapies for this patient population. One of the study's limitations is that, although a sizable portion of the patients with breast cancer were included, some individuals were left out due to death or lost follow-up. Second, the presence of inflammatory/infective process in some immuno-compromised patients receiving chemotherapy which may cause false positive results. Third the relative small number of patients with documented follow up by PETCT & those with regressive course of disease limited the statistical confidence for positive and negative predictive values. So, we recommend further studies with development of certain prospective validation models for the measurement of constant threshold to reach optimum SUV max cutoff, MTV, TLG, and other volumetric /metabolic evaluation. Finally follow up prospective study should be carried to validate the accuracy and specificity of our results.

a far worse prognosis in comparison with patients that did not have pleura lesions. PET/CT is helpful. In order to confirm or rule out the malignant character of lesions exhibiting a relatively high FDG uptake in the pleura or pleural effusion, patients with a diagnosis of a metastatic disease should have a more comprehensive evaluation.

REFERENCE:

1. **DeSantis, C.** Breast cancer statistics, 2013. *CA. Cancer J. Clin.*, 64(1): p. 52-62 **2014**.
2. **Gennari A, Conte P, Rosso R, et al.** Survival of metastatic breast carcinoma patients over a 20- year period: A retrospective analysis based on individual patient data from six consecutive studies. *Cancer.* Oct 15;104(8):1742-50 **2005**.
3. **DeSantis C, Siegel R, Bandi P, et al.** Breast cancer statistics,. 61: 409–18. *CA. Cancer J. Clin.* **2011**.
4. **Karagiannis GS, Goswami S, Jones JG, et al.** Signatures of breast cancer metastasis at a glance. *J. Cell. Sci.*;129(9):1751-8 **2016**.
5. **Jin L, Han B, Siegel E, et al.** Breast cancer lung metastasis: Molecular biology and therapeutic implications. *Cancer Biol. Therapy.*;19(10):858-68 **2018**.
6. **Hunter KW, Crawford NP, Alsarraj J. et al.** Mechanisms of metastasis. *Breast Cancer Res.*;10(1):2, **2008**.
7. **Sledge GW.** Curing metastatic breast cancer. *J. Onc. Prac.*;12(1):11-3 **2016**.
8. **Jyotsana N, Zhang Z, Himmel LE, et al.** Minimal dosing of leukocyte targeting TRAIL decreases triple-negative breast cancer metastasis following tumor resection. *Sci. Advan.*;5(7): eaaw4197, **2019**.
9. **Duysinx B, Nguyen D, Louis R, et al.** Evaluation of pleural disease with 18-fluorodeoxyglucose positron emission tomography imaging. *Chest.* **2004**; 125:489–493
10. **Jany B, and Welte T.** Pleural effusion in adults—etiology, diagnosis, and treatment. *Deutsches Ärzteblatt International.* May;116(21):377 **2019**.
11. **Saricam M.** F-18 FDG positron emission computed tomography in the diagnosis of pleural metastases from breast carcinoma. *International Surgery Journal.* Feb 26;7(3):764-9 **2020**.
12. **Toaff JS, Metser U, Gottfried M, et al.** Differentiation between malignant and benign pleural effusion in patients with extra-pleural primary malignancies: assessment with PET-CT-. *Investigative radiology.* Apr 1;40(4):204-9 **2005**.
13. **Fjaellegaard K, Petersen JK, Reuter S, et al.** PET-CT in suspected malignant pleural effusion. An updated systematic review and meta-analysis. *Lung Cancer.* Dec 1; 162:106-18 **2021**.
14. **Arnold DT, and Maskell N.** Imaging for malignant pleural effusions—still no routine role of positron emission tomography. *Journal of Thoracic Disease.* Apr;11(4):1079 **2019**.
15. **Hallifax RJ, Talwar A, Wrightson JM, et al.** State-of-the-art: Radiological investigation of pleural disease. *Resp. Med.*; 124:88-99 **2017**.
16. **Lococo F, Muoio B, Chiappetta M, et al.** Diagnostic performance of PET or PET/CT with different radiotracers in patients with suspicious lung cancer or pleural



- tumors according to published meta-analyses. *Contrast media & molecular imaging*. Apr 25;2020.
17. **Rohren EM, Turkington TG, Coleman RE. et al.** Clinical applications of PET in oncology. *Radiology*. May;231(2):305-32 **2004**.
  18. **Zhang W, Liu Z, Duan X, et al.** Differentiating malignant and benign pleural effusion in patients with lung cancer: an 18F-FDG PET/CT retrospectively study. *Frontiers in Oncology*.;13 **2023**.
  19. **Budak A, Yanarateş A, Budak E. et al.** The contribution of PET/CT to the differentiation of benign and malignant pleural effusion in patients with ovarian carcinoma. *Revista Española de Medicina Nuclear Imagen Molecular* (English Edition). Nov 1;42(6):353-8 **2023**.
  20. **Simsek FS, Yuksel D, Yaylali O, et al.** Can PET/CT be used more effectively in pleural effusion evaluation? *Japanese Journal of Radiology*. Dec;39(12):1186-94 **2021**.
  21. **Agalioti T, and Giannou AD, Stathopoulos GT.** Pleural involvement in lung cancer. *Journal of thoracic disease*. Jun;7(6):1021 **2015**.
  22. **Pokieser W, Cassik P, Fischer G, et al.** Malignant pleural and pericardial effusion in invasive breast cancer: impact of the site of the primary tumor. *Breast cancer research and treatment*. Jan; 83:139-42 **2004**.