



Effect of *Graviola (Annona muricata)* on Some Physiological Parameters and Fertility of Male Albino Rats Exposed to Oxidative Stress



Takea Shaker Ahmed¹, Raghad Tahseen Thanoon¹ and Khalid A. Hadi^{2*}

¹ Department of Basic Science, Collage of Dentistry, University of Tikrit, Tikrit, Iraq.

² Department of Physiology, Pharmacology and Biochemistry, Collage of Veterinary Medicine, University of Tikrit, Tikrit, Iraq.

Abstract

THE PRESENT study was designed to demonstrate the effect of *Graviola (Annona muricata)* on some physiological parameters and the reproductive efficiency of male rats exposed to oxidative stress. A total of 48 Wister albino rats were distributed among four groups, each group containing 12 rats, control group, A group was administered H₂O₂ at a concentration of 0.5% for 2 months), a group was given H₂O₂ with *Graviola* 100 mg/kg/day for 2 months) and a group was dosed with *Graviola* 100 mg/kg/day for 2 months). The results of this study showed a notable decrease in sperm count, the percentage of sperm viability, the antioxidant activity (AOA), the level of sex hormone (testosterone, follicular stimulating hormone and luteinizing hormone), glutathione concentration, Superoxide Dismutase enzyme activity, germinal epithelium height, and seminiferous tubules diameter in H₂O₂ group. Likewise, there were significant increase in MDA, percentage of sperm abnormalities and dead sperm, in the H₂O₂ group compared to the control group. Though, when H₂O₂ is given in combination with *Graviola*, there was a significant improvement. This combined treatment led to a significant increase in sperm count, sperm viability, sex hormone levels, glutathione concentration, SOD activity, antioxidant activity, height of germinal epithelium, and the seminiferous tubules diameters. At the same time, there is a significant decrease in MDA, the percentage of sperm abnormalities and dead spermatozoa. In conclusion, H₂O₂ treated with *Graviola* efficiently restores antioxidant parameters, sperm count, and sperm viability to normal values. This research proposes that *Graviola* provide good benefits in enhancing the reproductive performance of male rats.

Keywords: *Graviola (Annona muricata)*, physiological parameters, fertility, male albino rats, oxidative stress.

Introduction

It is widely recognized that the use of medicinal plants is the basis for health preservation. Chronic diseases such as diabetes, cardiovascular disease, cancer and infertility have reached endemic proportions, posing a major and urgent health concern for that reason, treatments of these diseases are of practical importance [1]. *Graviola (Annona muricata)* have been used as a medicinal for a long period. *Graviola* is a tropical tree of the (Annonaceae) family. Several studies have shown the therapeutic effects of *Graviola*, for instance anticancer [1,2], antimicrobial, antiviral agent, and anti-inflammatory properties. *Graviola* fruit contains antioxidants, phenols, acetogenins, and alkaloids. Therefore, it is used as an alternative treatment for diabetes, hypertension, tumors, and bacterial diseases. It is also used to treat infertility and increase fertility

because it contains antioxidants properties. Furthermore, it is less harmful compared to current commercial drugs [2]. *Graviola* extracts contain vitamins, carotenoids, pectinase, catalase and peroxidase these substances inhibit the growth of cancer cells and reduced glucosidase which decrease glucose absorption into blood post eating. Also decrease the processes of lipid peroxidation that results of oxidative stress exposed, so more research is required to explore their therapeutic properties [3].

Oxidative stress starts from an imbalance in generating and accumulating of free radical such as superoxide anion (O^{2•-}), hydrogen peroxide (H₂O₂) in cells. Furthermore, it depends on the capacity of the cell to remove these products [4]. Oxidative stress participates in many diseases, like heart diseases, inflammation, diabetes mellitus, tumors and other diseases such as Alzheimer's and infertility [5].

*Corresponding authors: Khalid A. Hadi E-mail: dr.physiologist@tu.edu.iq Tel.: +9647702315766

(Received 24/02/2024, accepted 13/06/2024)

DOI: 10.21608/EJVS.2024.272512.1874

©2025 National Information and Documentation Center (NIDOC)

Several studies indicating that H_2O_2 causes atrophy in animal testicles and that the exposure of rats to H_2O_2 in the prepubertal period causes damage to the developing testicles, which in turn is reflected in puberty on the normal functional processes in the testicle of animals [4]. Studies on the effect of Graviola (*Annona muricata*) on health in general might be available, but the studies that focused on the effects of Graviola on male rat fertility might be rare. Investigating this trait could provide valuable information on the potential effects of Graviola on male reproductive health and fertility. This study aimed to determine the effect of Graviola on some physiological parameters and the reproductive competence of male rats exposed to oxidative stress.

Experiment Design

Animals were placed in cages and were fed *ad libitum* with distilled water. They were left one-week for acclimatization before the beginning of the experiment. Albino rats *Rattus norvegicus* were divided into 4 groups, each containing (12) adult male rats their age was 100 days. The animals were administered daily for 60 days orally using Gastric gavage feeding.

Control Group: Received distilled water at dose of (1 ml/kg) for 60 days [4].

H_2O_2 Group: Received H_2O_2 3 ml/kg at a concentration of 0.5 % for 60 days [4].

Graviola with H_2O_2 Group: Received H_2O_2 (0.5%) followed by graviola extract (100mg/kg) for 60 days.

Graviola group: Administered graviola extract capsule (CiViMuna, USA) 100mg/kg for 60 days (given orally dissolved in distilled water [7]).

Preparation of histological sections for testes of male Rats

At the end of the experiment, rats were sacrificed under light ether anesthesia and the testes (right and left) were extracted and the epididymis were separated from the testes, the right testicle of each animal was kept in a neutral formalin buffer solution. The testicles passed in a series of ethyl alcohol rising concentration (70, 95, 100) % to remove water from them, then xylol for clarification, and then buried in paraffin in preparation for sectioning and dyed using hematoxylin and eosin dye H&E [8].

The diameters of the seminal tubules and the thickness of germinal epithelium were measured using the ocular micrometer, the average diameters of (30) tubules were calculated [8].

The sperm count was calculated after separating the right epididymis from the right testicle and collecting its semen content by squeezing the epididymis and the number of sperm was calculated using the hemocytometer. To calculate the percentage of live and dead sperm and the

percentages of sperm abnormalities, the content of the left epididymis was squeezed into a Petri dish containing 2ml of physiological salt solution at a temperature of (37 °C), then a drop of the solution was taken and placed on a clean and dry glass slide and stained with eosin and nigrosine dye, and the second part of the mixture was taken and putting on glass slides after drying in the incubator at a temperature of (37 °C) for 10 minutes and after the slide is completely dry examined with the oil lens, 100X after which the percentage of sperm abnormalities were calculated [9].

Blood samples

Blood samples were collected from rat by cutting the jugular vein in the neck, about 5 ml of blood was collected and placed in test tubes free of anticoagulant left for about 15 minutes in a water bath at 37 °C, and then the serum was obtained by centrifuged at 3000 rpm, and saved at (-20 °C) tubes until biochemical parameters and hormones are measured.

Measurement of FSH, LH and Testosterone

FSH, LH and Testosterone were assessed in serum of male rat quantitatively by Eliza- enzyme immunosorbent assay. Rat Kits provided by (Endocrinotech, ERKR 7014, Endocrinotech, ERKR 7014) using to determine FSH and LH respectively. Testosterone concentration were determined using rat kit supplied from (Biokits Technologies IncEU04).

Determination of Glutathione (GSH), superoxide dismutase (SOD) Malondialdehyde (MDA) AOA activity

GSH was determined using a colorimetric assay with Cayman's Kit from Cay. Chem. Company in USA. The photochemical nitroblue tetrazolium method was employed to assess the SOD [10]. This technique makes use of sodium cyanide, an inhibitor of the peroxidase enzyme. This is an indirect way of measuring SOD activity, where nitroblue tetrazolium reduction by $O^{\cdot-2}$ forms formazin.

MDA level was analyzed using rat malondialdehyde Eliza Kit (BioVision, US) colorimetric/fluorometric Detection Method.

The antioxidant activity AOA was measured by the modified method according of [11,12].

The principles of this method are Fe-EDTA complex reacts with OH by a Fenton type reaction, leading to the formation of OH radicals. These reactive oxygen species break down benzoate, resulting in the release of reactive compound such as thiobarbituric acid reactive substances. Spectrophotometric measurement of thiobarbituric acid color used to detect the AOA.

Statistical analysis

The data were statistically analyzed using one way analysis of variance. The Duncan multiple range test were used to determine differences between groups. The acceptable statistical discrimination level is determined to be $P \leq 0.05$, which means that any difference is statistically significant if the probability value (P) is less than 0.05. The parameters were performed using the statistical software SPSS.

Results

This study is designed to examine the effect of Graviola on reproductive performance in male rats, especially in relation to antioxidants, changes in semen, and the effect of male sex hormones under the influence of oxidative stress produced by hydrogen peroxide. Table (1) shown that exposure to H_2O_2 resulted in a significant decrease ($p \leq 0.05$) in the total sperm count and live sperm ratio, and in the diameter and thickness of the seminiferous tubules, with a significant increase ($p \leq 0.05$) in the percentage of dead sperm and deformed sperm compared to the control group and the Graviola group. From Table 2, a significant decrease ($p \leq 0.05$) in glutathione level, superoxide dismutase activity and total antioxidant activity (AOA) is shown, with a significant increase ($p \leq 0.05$) in the serum level of malondialdehyde of animals treated with H_2O_2 compared to the control group and the Graviola group. In the statistical analysis shown in Table 3, a significant decrease ($p \leq 0.05$) in testosterone level, follicle-stimulating hormone (FSH) and luteinizing hormone (LH) levels in the H_2O_2 group compared to the control group and a significant increase in male reproductive hormones ($p \leq 0.05$) in the Graviola group compared to the H_2O_2 group and the control group. The results of the experiment show that the animal dosing of Graviola with H_2O_2 showed an antioxidant effect, reducing the harmful effect of hydrogen peroxide and reducing damage to the male reproductive system, resulting in an improvement in the total number of sperm, live/dead sperm ratio, reduction of sperm malformations, improvement in the diameter and thickness of the semen tubules and sex hormones, as well as an increase in the level and overall activity of antioxidants. The experiment also showed that given Graviola alone had a positive effect in increasing reproductive efficiency. The histological examinations for testes of the control group were appeared in their normal structure, where the testicle was surrounded by a connective tissue, and the seminal tubules were surrounded by a basement membrane. The cavities of the tubules showed the presence of Sertoli cells and sperm cells of various phases. Sperm is also observed within the cavities of the seminal tubules between the supporting cells of Sertoli. This group showed no histological changes, and histological examination (Fig. 1) shows regular division of Spermatogonium with a clear presence of

leydig cells between the seminiferous tubules, and the lumen of the tubules containing sperm. In contrast, a slicing of the testicle of the H_2O_2 group showed severe pathological changes in the seminiferous tubules. These changes included degeneration of some sperm cells within the seminiferous tubules, necrosis and sloughing in some supporting cells and sperm precursors, with a small number of sperm inside the tubule. Edema was observed between the seminiferous tubules, and enlargement of some primary and secondary sperm cells (Fig. 2). In contrast, the examination of the segments of the testicle of the group treated with Graviola with H_2O_2 showed an improvement in the histographic figure, as it came slightly closer to the control group, as seen in Fig (3).

Discussion

In a healthy state, there is a balance between the production of free radicals and the body's ability to counteract them, and a dynamic balance occurs between them. Oxidative potential is shown when the production of free radicals in a cell exceeds the level of antioxidant capacity [4,13]. Free radicals are highly effective and unstable, interacting with fats, proteins and nucleic acids, leading to cell damage [14,15]. The current study shows that treating rats with H_2O_2 led to a significant decrease ($p \leq 0.05$) in the total sperm count and live sperm ratio. A significant decrease in the average diameter of the seminiferous tubules and the thickness of the epithelium of the seminiferous tubules was also observed. In contrast, the percentage of dead sperm and deformed sperm saw a significant increase ($p \leq 0.05$) when compared with the control group. These findings are consistent with a previous study by [16], where they reported a significant decrease in the total number of sperm and the number of Sertoli cells in mice after exposure to H_2O_2 . This decrease is due to the increased production of active oxygen varieties as a result of H_2O_2 administration, which breaks down the cells lining the seminiferous tubules (Sertoli cells), thus causing obstruction in sperm maturation [17]. In a study, Abdel Hady pointed out that the membrane surrounding sperm in males contains a rich composition of unsaturated fatty acids. These acids are shown to be highly sensitive to certain types of active oxygen, which leads to their damage via the lipid peroxidation process and thus contributes to a decrease in sperm motility. According to the results of the study, the loss of intracellular ATP is a contributing factor to this decline, resulting in the axial filament in the sperm breaking down and reducing its vitality. The author also notes the pertinence lipid peroxidation of sperm cell induced the mechanism of ROS, which leads to sperm damage and promote infertility [18]. our results revealed histological changes in the testes of rat treated with H_2O_2 , also noted severe changes in seminiferous tubules include necrosis of some

spermatids, degeneration with sloughing in some Sertoli cells, as well as oligospermia. These findings are agreed with previous studies performed by many researchers [19,20,21]. The results of this study showed a significant decrease in glutathione level and SOD, as well as a decrease in the efficacy of antioxidant activity in rat treated with H₂O₂. These results are agreed with other study by [22], where they demonstrated that the exposure to oxidative stress causes a significant decrease in glutathione level in liver, due to lack antioxidant enzymes such as glutathione peroxidase and catalase in mice liver. A previous study [23]. Other researchers also indicated that exposure to oxidative stress causes destructive oxidative effects, increasing lipid peroxidation in tissues, thus leading to depletion of the level of glutathione in tissues and numerous changes in the antioxidant regimen [21]. Treatment with H₂O₂ led to a significant increase in the level of malondialdehyde. These findings are consistent with research conducted by Raeeszadeh *et al.* [24], who noted that rat exposure to free radicals resulting from exposure to heavy metals led to an increase in lipid peroxidation and a deficiency in antioxidant enzymes. It is noted that cell membranes mainly contain trans fats, which are a prime target for active oxygen species. In addition, these free radicals are responsible for the breakdown of most of the cell membrane proteins, resulting in reduced antioxidant levels [19]. According to research by [25], oxidative stress on male adult rats resulted in a significant ($p \leq 0.05$) decrease in the concentration of testosterone, follicle-stimulating hormone (FSH), and luteinizing hormone (LH). These findings are consistent with the current study's findings, and the cause of the decrease is damage to testicular tissue, specifically in Leydig cells, which are responsible for both the stabilization of the pituitary gland's function and the production of testosterone hormone. However, the results of this study differ from those of [26]. Who suggested that the shorter exposure time to H₂O₂ oxidative stress or the mode of administration were to blame. However, the results of this investigation differ from those of [26]. He ascribed this discrepancy to either the shorter exposure period to oxidative stress using H₂O₂ or the manner in which the animals were administered [27]. Receiving Graviola and H₂O₂ resulted in a significant increase in glutathione level, average seminiferous tubule epithelium thickness and testosterone level with a significant decrease in malondialdehyde level compared to the H₂O₂ group [7]. It has been shown that giving Graviola to mice and rats increased the levels and strength of glutathione, catalase and superoxide dismutase; also, an increased concentration of GSH in serum can be attributed to the activity of these enzymes. As a powerful antioxidant, Graviola stops oxidative processes by eliminating free radicals and stopping the proliferation of lipid peroxidation [28]. By reducing

the body's consumption of glutathione, a non-enzymatic antioxidant found in the body and raising its level in the blood serum, Graviola helps prevent oxidative damage caused by highly active free radical molecules, including powerful oxidizing agents such as hydroxyl radical and superoxide negative in the blood and body fluids [29]. In addition, there is a marked decrease in the amount of MDA. This decrease can be attributed to the active ingredients and their concentrations in the extract of Graviola, which contains high levels of terpenoids and flavonoids. These substances serve as antioxidants by removing reactive oxygen species, which Diminished the oxidative stress [30,31]. This research demonstrated the importance of Graviola in decreasing free radicals that cause testes damage in rats administered H₂O₂. The results also showed increase in sperm count, the percentage sperm viability, sex hormones levels, and observed improvement in the histological sections of seminiferous tubules as well as an increase in antioxidants Activity (AOA). The abundant number of flavonoids, polyphenolic compounds, glycosides, and vitamin E may justify this increase. As a result of raising and triggering antioxidant levels and lowering oxidative stress [32,33,34]. The decrease in dead sperm percentage and sperm abnormalities was also noticed, and this may be lead to the potency of polyphenolic compounds and flavonoids, which inhibit the reactions of ROS and play to remove them, via the activity of antioxidant enzymes that inhibit the oxidation and peroxidation of lipids and inhibit malondialdehyde production [35,36]. The conclusion of this study is that Graviola (*Annona muricata*) has the ability to improve reproductive efficiency because it is a natural antioxidant.

Conclusion

H₂O₂ treated with Graviola efficiently restores antioxidant parameters, sperm count, and sperm viability to normal values. This research proposes that Graviola provide good benefits in enhancing the reproductive performance of male rats.

Acknowledgment: The researchers express their appreciation to everyone who participated to the completion of this work, and supporting of University of Tikrit.

Declaration Conflicted of interested: none.

Funding statement: Self-funding.

Ethical approval: Rats were handled in accordance with the College of Veterinary Medicine's Animal Ethics Committee recommendations. Approval for this study was obtained from the scientific board of the Department of Physiology, Biochemistry, and Pharmacology at the Faculty of Veterinary Medicine, University of Tikrit (protocol no.3/7/1215).

TABLE 1. Protective effect of Graviola on total sperm rate, percentage of live and dead sperm, sperm abnormalities, average diameters and thickness of seminiferous tubule epithelium in male adult rats administered H₂O₂.

Groups\ Variables	Total sperm count x 10 ⁶ mean± S.D	Viable sperm percentage % mean ± S.D	Dead sperm percentage % mean ± S.D	Sperm abnormalities% mean± S.D	Diameter of seminiferous tubules mean± S.D	Height of seminiferous tubules mean± S.D
Control Group	8.043± 0.094 ^a	78.893±0.052 ^b	21.107±0.047 ^b	9.731±0.038 ^c	299.688±0.055 ^a	81.666±0.034 ^b
H2O2 Group	4.005± 0.088 ^c	24.310±0.055 ^d	75.690±0.054 ^a	31.028±0.040 ^a	244.315±0.052 ^c	47.109±0.039 ^d
Graviola with H2O2 Group	7.231±0.057 ^b	73.143±0.044 ^c	26.857±0.039 ^b	11.511±0.031 ^b	275.465±0.029 ^b	76.222±0.076 ^c
Graviola Group	8.532±0.214 ^a	81.017±0.051 ^a	18.983±0.051 ^c	8.372±0.048 ^d	303.393±0.036 ^a	84.214±0.032 ^a

Vertically different letters mean a significant difference between the totals at a probability level ($p \leq 0.05$). Number of animals in each group = 12

TABLE 2. Protective effect of Graviola on average levels of MDA, GSH, SOD and measurement of AOA in adult male rats given with H₂O₂.

Variables\Groups	MDA(μMOL/L) mean± S.D	GSH(mg/dl) mean± S.D	SOD(U/L) mean± S.D	AOA (μMOL/L) mean± S.D
Control Group	1.543± 0.05 ^e	11.023±0.098 ^b	0.967±0.014 ^a	45.106±0.138 ^b
H ₂ O ₂ Group	4.125± 0.93 ^a	3.132±0.112 ^d	0.319±0.042 ^c	28.659±0.036 ^d
Graviola with H ₂ O ₂ Group	1.951±0.049 ^b	9.681±0.081 ^c	0.661±0.009 ^b	36.395±0.175 ^c
Graviola Group	1.003±0.024 ^c	13.497±0.103 ^a	0.998±0.036 ^a	45.875±0.032 ^a

Vertically different letters mean a significant difference between the totals at a probability level ($p \leq 0.05$). Number of animals in each group = 12

TABLE 3. Protective effect of Graviola on average level of testosterone, FSH and LH in adult male rats administered H₂O₂.

Groups \ Variables	Testosterone (ng/dl) mean± S.D	FSH (mIU/ml) mean± S.D	LH (mIU/ml) mean± S.D
Control Group	103.372±0.039 ^b	1.609±0.015 ^b	1.199±0.027 ^b
H ₂ O ₂ Group	45.178±0.032 ^d	1.011±0.023 ^d	0.891±0.020 ^c
Graviola with H ₂ O ₂ Group	117.701±0.021 ^c	1.171±0.011 ^c	1.194±0.019 ^b
Graviola Group	128.352±0.041 ^a	1.235±0.021 ^a	1.2019±0.017 ^a

Vertically different letters mean a significant difference between the total at a probability level ($p \leq 0.05$).

Number of animals in each group = 12

Similar letters: not significant

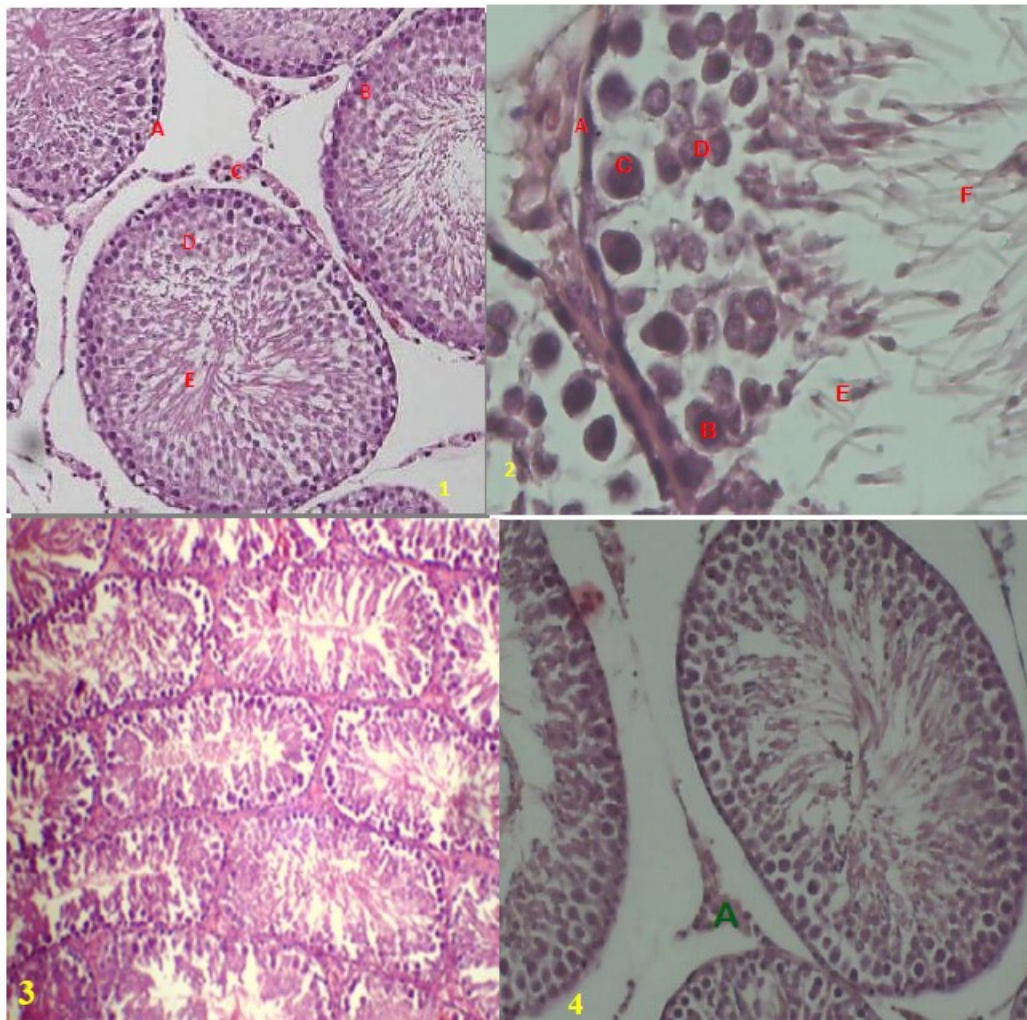


Fig.1-4. Fig.1 Histologic section of an adult rat testicle from the control group showing (A) spermatogonia (B) primary spermatocyte (D) secondary spermatocyte (E) spermatids. Fig. (2) histological section of the testicle of an adult rat from the H₂O₂ group shows degeneration of a number of sperm cells within the seminal tubules with thickening of the basement membrane (A) and primary spermatocyte hypertrophy(B), secondary spermatocyte hypertrophy, degeneration of spermatids (E). In Fig. (3) we observed an improvement in testicular tissue in adult rats treated with Graviola and H₂O₂. Fig. (4) A photograph of section of testes of rat treated with Graviola show normal distribution of various stage of spermatogenesis.

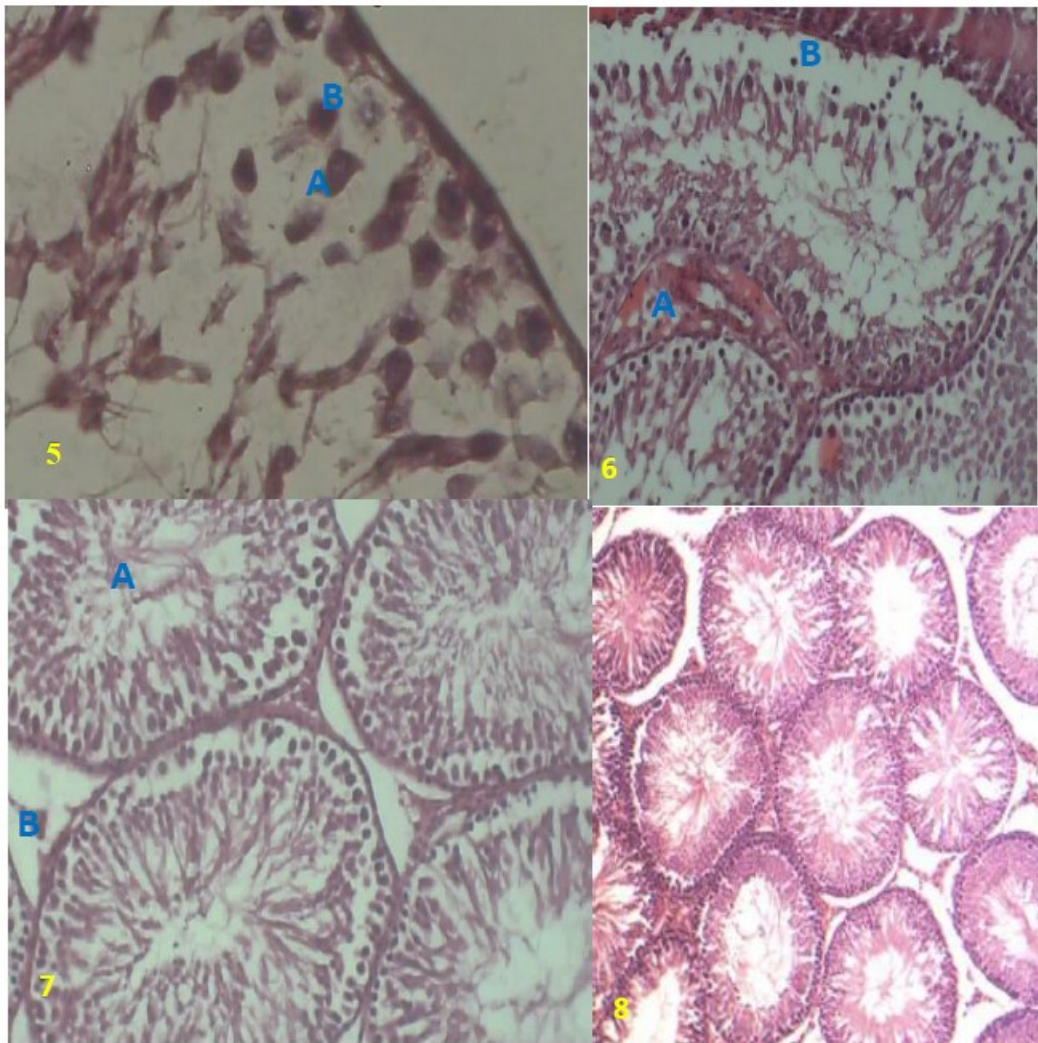


Fig. 5-8: Fig.5. High magnification photograph of an adult rat testicle from the H_2O_2 group showing (A) hypertrophy of sertoli cell (B) germinal cell necrosis Fig. (6) histological section of the testicle of an adult rat from the H_2O_2 group shows congested blood vessels with sloughing germinal epithelium from basement membrane Fig. (7) photograph of testes male rat treated with Graviola and H_2O_2 showing (A) several spermatid (B) leydig cell Fig. (8) A photograph of section of testes of rat treated with Graviola show normal seminiferous tubules with thin basement membrane with form resemble that of the control group.

References

1. Chang, F.R., Liaw, C.C., Chou, C.J., Chiu, H.F. and Wu, Y.C. New adjacent Bistetrahydrofuran Annonaceous acetogenins from *Annona muricata*. *Planta Med.*, **69**, 241-246(2003).
2. Zubaidi, S. N., Mohd Nani, H., Ahmad Kamal, M. S., Abdul Qayyum, T., Maarof, S., Afzan, A. and Mediani, A. *Annona muricata*: Comprehensive Review on the Ethnomedicinal, Phytochemistry, and Pharmacological Aspects Focusing on Antidiabetic Properties. *Life*, **13**(2), 353(2023).
3. Patil, H.V., Dhankani, M.A. and Dhankani, A.R. A Review on Marvel Fruit: *Annona muricata*. *Med. Sci.*, **21**(1),26(2023).
4. Ana, F. Vinha, C. and Costa, C. Oxidative stress, antioxidants and biomarkers: appreciation for analytical methods for health promotion. *Int. Aca. Res. J. Int. Med. Pub. Hlth.*, **4**(3), 47-55 (2023).
5. Bezerra, F. S., Lanzetti, M., Nesi, R. T., Nagato, A. C., Silva, C. P., Kennedy Feitosa, E., Melo, A. C., Cattani Cavalieri, I., Porto, L. C. and Valenca, S. S. Oxidative stress and inflammation in acute and chronic lung injuries. *Antioxidants*, **12**(3),548(2023).
6. Okagu, I. U., Ndefo, J. C., Chibuogwu, C. C., Aham, E. C., & Onoh, A. P. Modulation of Hydrogen Peroxide-Induced Oxidative Stress in Rats by Deep Root Herbal Mixture®—A Nigerian Branded Polyherbal Drug., (2020).
7. Alsenosy, A. W. A., El-Far, A. H., Sadek, K. M., Ibrahim, S. A., Atta, M. S., Sayed-Ahmed, A. and Mousa, S. A. Graviola (*Annona muricata*) attenuates

- behavioural alterations and testicular oxidative stress induced by streptozotocin in diabetic rats. *PLoS One*, **14**(9), 0222410(2019).
8. Salah, M. and Abdul-Hamid, M. Protective effect of orange and grapefruit peel extracts against testicular toxicity induced by sulfasalazine in male albino rats. *Egyptian Journal of Histology*, **37**(3), 429-441 (2014).
 9. Luaibi, N.M. and Qassim, H.A. Dose and time dependent effects of silver nanoparticles (AGNPS) on ovarian histology and serum levels of sex hormones in female rats. *Pak. J. Biotechnol.*, **14**(4), 663-672(2017).
 10. Cheng, Chien-wei, Liang-yü Chen, Chan-wei Chou and Ji-yuan Liang. Investigations of riboflavin photolysis via coloured light in the nitro blue tetrazolium assay for superoxide dismutase activity. *Journal of Photochemistry and Photobiology B: Biology*, **148**, 262-267 (2015).
 11. Lueridhe, J.M., Maitd, L. and Poyer, L. Superoxide dismutase and Fenton chemistry. *Biochem. J.*, **269**, 169-174 (1994).
 12. Yamazaki, Isao; Piette and Lawrence, H. ESR spin-trapping studies on the reaction of Fe²⁺ ions with H₂O₂-reactive species in oxygen toxicity in biology. *Journal of Biological Chemistry*, **265**(23), 13589-13594 (1990).
 13. Ait Tayeb, A.E.K., Poinsignon, V., Chappell, K., Bouligand, J., Becquemont, L. and Verstuyft, C. Major depressive disorder and oxidative stress: A review of peripheral and genetic biomarkers according to clinical characteristics and disease stages. *Antioxidants*, **12**, 942(2023).
 14. Akter, S., Khan, M.S., Smith, E.N. and Flashman, E. Measuring ROS and redox markers in plant cells. *RSC Chemical Biology*, **2**, 1384(2021).
 15. Arfin, S., Jha N. K., Jha S. K., Kesari, K. K., Ruokolainen, J., Roychoudhury, S., Rathi, B. and Kumar, D. Oxidative stress in cancer cell metabolism. *Antioxidants*, **10**(5), 642(2021).
 16. Hipler, U.C., Gornig, M., Hipler, B., Romer, W. and Schreiber, G. Stimulation and scavestrogen-induced inhibition of reactive oxygen species generated by rat sertoli cells. *Arch. Androl.*, **44**, 147-154(2000).
 17. Matuszewska, A., Nowak, B., Nizański, W., Eberhardt, M., Domrazek, K., Nikodem, A. and Szelaż, A. Long-term administration of abacavir and etravirine impairs semen quality and alters redox system and bone metabolism in growing male wistar rats. *Oxidative Medicine and Cellular Longevity*, **1**, 32(2021).
 18. Abdel Hady, A. A., Abd-Allah, E. E. E., Emam, N. M., El-Sagheer, A. E. S., Younes, A. M., Abdel Monsef, A. S. and Shawky, N. O. Protective Effects of Curcumin and Selenium on Testicular Toxicity Induced by Lead Acetate in Adult Male Albino Rats [Structural and Biochemical Study]. *International Journal of Medical Arts*, **5**(2), 3045-3053(2023).
 19. Solcan, C., Slencu, B. G., Trinca, L. C., Motrescu, I., Petrovici, A., & Solcan, G. Testicular Injuries due to Subacute Combined Exposure to Cadmium and Lead in Rats. *Farmacia*, **70**(4), 690-703(2022).
 20. Li, J., Ning, M., Zhang, Y., Liu, Q., Liu, K., Zhang, H. and Liu, Y. The potential for nanomaterial toxicity affecting the male reproductive system. Wiley Interdisciplinary Reviews: *Nanomedicine and Nanobiotechnology*, **14**(6), e1806(2022).
 21. El-fakharany, Y.M., Mohamed, E.M., Etewa, R.L. and Abdel Hamid, O.I. Selenium nanoparticles alleviate lead acetate-induced toxicological and morphological changes in rat testes through modulation of calmodulin-related genes expression. *Journal of Biochemical and Molecular Toxicology*, **36**(5), e23017(2022).
 22. Conde de la Rosa, L., Goicoechea, L., Torres, S., Garcia-Ruiz, C. and Fernandez-Checa, J. C. Role of oxidative stress in liver disorders. *Livers*, **2**(4), 283-314 (2022).
 23. Bai, H., Fang, C. W., Shi, Y., Zhai, S., Jiang, A., Li, Y. N. and Qin, X. J. Mitochondria-derived H₂O₂ triggers liver regeneration via FoxO3a signaling pathway after partial hepatectomy in mice. *Cell Death & Disease*, **14**(3), 216. (2023).
 24. Raeeszadeh, M., Karimfar, B., Amiri, A. A. and Akbari, A. Protective effect of nano-vitamin C on infertility due to oxidative stress induced by lead and arsenic in male rats. *Journal of Chemistry*, **2021**, 1-12(2021).
 25. Al-Damegh, M.A. Stress-induced changes in testosterone secretion in male rats: Role of oxidative stress and modulation by antioxidants. *Journal of Animal Sciences*, **4**(02), 70(2014).
 26. Meeker, J.D., Rossano, M.G., Bridget, P. and Padmanabhan, V. Environmental exposure to metals and male reproductive hormone: Circulating testosterone is inversely associated with blood molybdenum. *Fertil. Steril.*, **93**(1), 130-149(2010).
 27. Bumanlag, E., Scarlata, E. and O'Flaherty, C. Peroxiredoxin 6 peroxidase and Ca²⁺-independent phospholipase A2 activities are essential to support male-mouse fertility. *Antioxidants*, **11**(2), 226 (2022).
 28. Drishya, G., Nambiar, J., Shaji, S.K., Vanuopadath, M., Achuthan, A., Kumar, A., Alias, A., Sherif, A., Joseph, C. and Divya, P. RECK and TIMP-2 Mediate Inhibition of MMP-2 and MMP-9 by *Annona muricata*. *J. Biosci.*, **45**, 89(2020).
 29. Prasad, S. K., Pradeep, S., Shimavallu, C., Kollur, S. P., Syed, A., Marraiki, N. and Glossman-Mitnik, D. Evaluation of *Annona muricata* acetogenins as potential anti-SARS-CoV-2 agents through computational approaches. *Frontiers in Chemistry*, 1281(2021).
 30. Menon, S., Al-Eisa, R. A., Hamdi, H., Lawrence, L., Syamily, P. S., Sivaram, V. P. and Narayanankutty, A. Protective Effect of *Annona muricata* Linn Fruit Pulp Lyophilized Powder against Paracetamol-Induced Redox Imbalance and Hepatotoxicity in Rats. *Processes*, **11**(1), 276(2023).
 31. Anaya Esparza, L. M. and Montalvo-González, E. Bioactive compounds of soursop (*Annona muricata* L.) fruit. In Bioactive compounds in underutilized fruits and nuts. Cham: Springer International Publishing., pp. 175-189(2020).
 32. Jocelin Chan, W. J., Harnett, J. E., Meroni, A., McLachlan, A. J. and Harrahan, J. R. An evaluation of

- the quality of *Annona muricata* leaf products. *Journal of Pharmacy and Pharmacology*, **75**(10), 1357-1365(2023).
33. Silihe, K. K., Mbou, W. D., Ngo Pambe, J. C., Kenmogne, L. V., Maptouom, L. F., Kemegne Sipping, M. T. and Njamen, D. Comparative anticancer effects of *Annona muricata* Linn (Annonaceae) leaves and fruits on DMBA-induced breast cancer in female rats. *BMC Complementary Medicine and Therapies.*, **23**(1), 234(2023).
34. Eyeghre, O. A. Ezeokafor, E. N. Dike, C. C. and Oparaji, K. C. The Impact of *Annona Muricata* on Semen Quality and Antioxidants Levels in Alcohol-Induced Testicular Dysfunction in Male Wistar Rats. *International. Journal of Trend in Scientific Research and Development*, **7**(4), 789-800 (2023).
35. Roozbeh, N., Amirian, A., Abdi, F. and Haghdoost, S. A Systematic Review on use of Medicinal Plants for Male Infertility Treatment. *J. Farm Reprod. Heal.*, **15**(2), 74-81(2022).
36. Uno, U. U., Ogbe, H. O., Okolo, C. M., Ekaluo, U. B. and Akwa, B. U. Effect of soursop (*Annona muricata* L.) leaf extract on sperm toxicity induced by caffeine in albino rats. *The Pharmaceutical and Chemical Journal*, **4**(1), 82-87(2017).

تأثير الجرافيوولا على بعض المتغيرات الفسلجية وعلى خصوبة ذكور الجرذان البيضاء المعرضة للاجهاد التاكسدي

تقية شاكر احمد¹ ، رعد تحسين ذنون¹ ، خالد احمد هادي²

¹ فرع العلوم الاساسية- كلية طب الاسنان- جامعة تكريت-العراق.
² فرع الفسلجة والادوية والكيمياء الحياتية-كلية الطب البيطري- جامعة تكريت-العراق.

الملخص

تم تصميم هذه الدراسة لإثبات تأثير المستخلص المائي لفاكهة القشطة (*Annona muricata*) على بعض المعلمات الفسيولوجية والكفاءة التناسلية لذكور الفئران المعرضة للاجهاد التاكسدي. اذ تم توزيع الجرذان البالغ عددها 48 فأرا أبيض على أربع مجموعات ، كل مجموعة تحتوي على 12 فأرا ، مجموعة سيطرة، ومجموعة تم إعطاء بيروكسيد الهيدروجين بتركيز 5٪ لمدة شهرين) ، ومجموعة أعطيت بيروكسيد الهيدروجين مع فاكهة القشطة 100 ملغ / كغ / يوم لمدة شهرين) ومجموعة تم إعطاءها مستخلص مائي لفاكهة القشطة بتركيز 100 ملغ / كغ / يوم لمدة شهرين). تشير نتائج الدراسة إلى انخفاض ملحوظ في عدد الحيوانات المنوية ، ونسبة صلاحية الحيوانات المنوية ، ونشاط مضادات الأكسدة ، ومستوى هرمون الجنس ، وتركيز الجلوتاثيون ، ونشاط سوبر اوكسيد دسميونيز ، وارتفاع الظهارة الجرثومية ، وقطر الأنابيب المنوية. وبالمثل ، هناك زيادة كبيرة في المألوندايالديهيد ، ونسبة تشوهات الحيوانات المنوية والحيوانات المنوية الميتة ، في مجموعة بيروكسيد الهيدروجين مقارنة بمجموعة السيطرة رغم ذلك ، عندما تم إعطاء بيروكسيد الهيدروجين مع مستخلص فاكهة القشطة وبفاصل زمني نصف ساعة، لوحظ هناك تحسن كبير في الكفاءة التناسلية وفي مستوى مضادات الأكسدة وفعالية مضادات الأكسدة. اذ ادت المعاملة بفاكهة القشطة إلى زيادة كبيرة في عدد الحيوانات المنوية ، وصلاحية الحيوانات المنوية ، ومستويات هرمون الجنس ، وتركيز الجلوتاثيون ، ونشاط سوبر اوكسيد دسميونيز ، ونشاط مضادات الأكسدة ، وارتفاع الظهارة الجرثومية ، وقطر الأنابيب المنوية. وفي الوقت نفسه ، حصل انخفاض كبير في المألوندايالديهيد ، ونسبة تشوهات الحيوانات المنوية والحيوانات المنوية الميتة في الجرذان المعالجة بمستخلص فاكهة القشطة. نستنتج من خلال هذه الدراسة ان المعاملة بفاكهة القشطة تعمل على رفع مستوى مضادات الأكسدة وعدد الحيوانات المنوية وتحسين حيوية هذه الحيوانات المنوية لذلك فان فاكهة القشطة تساهم في تعزيز اداء الخصوبة في ذكور الجرذان.

الكلمات الدالة : الجرافيوولا، المتغيرات الفسلجية ، خصوبة الذكور، الجرذان البيضاء ، الاجهاد التاكسدي.