



## Evaluating Platelet-Rich Plasma (PRP) for Treatment of Osteoarthritis in Rabbits Involved Histomorphology, Radiology and Biochemical Assessments

Ibrahim Fawzy<sup>1</sup>, Farouk Abdelmohdy<sup>1</sup>, Ayman S. Atiba<sup>2</sup>, Foad Farrag<sup>3</sup>, Mustafa Shukry<sup>4</sup> and Mohamed Kassab<sup>1\*</sup>

<sup>1</sup> Department of Cytology and Histology, Faculty of Veterinary Medicine, Kafrelsheikh University, Kafrelsheikh, Egypt.

<sup>2</sup> Department of Surgery, Anesthesiology and Radiology, Faculty of Veterinary Medicine, Kafrelsheikh University, Kafrelsheikh, Egypt.

<sup>3</sup> Department of anatomy and Embryology, Faculty of Veterinary Medicine, Kafrelsheikh University, Kafrelsheikh, Egypt.

<sup>4</sup> Department of Physiology, Faculty of Veterinary Medicine, Kafrelsheikh University, Kafrelsheikh, Egypt.

### Abstract

**O**STEoarthritis (OA), the prevalent type of arthritis, arises from mechanical wear and inflammatory processes. Platelet-rich plasma (PRP), a derivative of blood enriched with activated platelets, offers a rich mixture of growth factors essential for the repair of cartilage. Twelve rabbits were classified into control negative, OA and treated groups. Induction of arthritis was done by Monoiodoacetate (MIA). Treatment is done with PRP. X-ray, histological study, immunohistochemical investigation, and biochemical measuring were done to investigate arthritis of femorotibial joints and its treatment with PRP. MIA-induced OA is characterized by affection on cartilage with fragmentation, apoptosis of chondrocytes, and loss of matrix. Synovitis is characterized by hyperplasia of lining cells, congestion, extravasation and leucocytic infiltration with increased ESR, CRP and IL-6. The PRP-treated group appeared to preserve the typical structure of both cartilage and synovium. in conclusion We confirm the impact of PRP in the treatment of OA by several scores, Mankin and Krestinsin scores. These scores indicate that PRP may be an efficient method for OA treatment.

**Keywords:** Osteoarthritis, PRP, Radiology, Histology, Immunohistochemistry.

### Introduction

Osteoarthritis (OA) is a joint degeneration condition marked by the breakdown of articular cartilage, causing pain and reduced mobility, mainly affecting the knees and hips [1]. Pathological alterations include the deterioration or inflammation of cartilage, subchondral bone, and synovium, along with the development of osteophytes [2]. OA frequently impacts the bone beneath and entails pathological modifications in the synovium, joint capsule, ligaments, and surrounding structures. [3].

Recently, the focus of research has shifted towards synovitis-induced cartilage degradation. Synovitis, whether due to trauma or rheumatic diseases, is characterized by an elevated count of inflammatory cells and an increase in cytokines they

produce, such as interleukin, tumor necrosis factor-alpha (TNF $\alpha$ ), IL-6, and IL-17. These cytokines are known to contribute to the breakdown of cartilage [1]. Traditional treatments for cartilage degradation or osteoarthritis (OA) typically involve intra-articular injections of lubricants or anesthetics, or the surgical option of arthroplasty [2].

Platelet-rich plasma (PRP) is a derivative of blood that offers a natural mix of self-derived growth factors, which enhance the proliferation, migration, and differentiation of stem cells [4]. Furthermore, PRP can mitigate cell death by lowering the expression levels of the Bcl-2-interacting mediator of cell death (BIM) gene and by inhibiting the process of apoptosis [5]. Numerous foundational, preclinical, and clinical studies, including case studies and trials, have demonstrated the effectiveness of platelet-rich

\*Corresponding author: Mustafa Shukry E-mail: mostafa.ataa@vet.kfs.edu.eg, Tel.: 01020705320

(Received 13/03/2024, accepted 18/06/2024)

DOI: 10.21608/EJVS.2024.276578.1909

©2025 National Information and Documentation Center (NIDOC)

plasma in treating musculoskeletal conditions such as osteoarthritis. PRP is extensively utilized to facilitate the healing of soft tissue injuries and has been shown to be effective in repairing damaged cartilage or preventing its further deterioration [6].

In our current study, we intend to develop a model of knee osteoarthritis and assess the impact of platelet-rich plasma (PRP) on treating this condition through X-ray, biochemical, and histopathological methods.

## **Material and Methods**

### *Ethical Approval*

The experiments received approval from the ethics committee at the Faculty of Veterinary Medicine, Kafrelsheikh University, Egypt, and an ethical issue number was issued. KFS-IACUC/75/2024

### *Animals grouping and Experimental design:*

Twelve Newzeland rabbits were used in this study. The animals were one year old and two to three kg in weight. The rabbits were grouped into three groups, four in each. Sterile MIA powder (MIA- Sigma Aldrich, Saint-Louis, Missouri, USA) was mixed into a sterile saline solution. Osteoarthritis was done by injection of Sodium Monoiodoacetate (MIA) intra-articular in knee joint 10 mg/kg.

### *Preparation of P-PRP*

As previously described, blood samples were collected for P-PRP preparation following Landesburg's method. Initially, rabbits were sedated with pentobarbital intravenous injections. Subsequently, 9 ml of blood was drawn from the central auricular artery using a 10 ml syringe, which contained 1 ml of 2.5% sodium citrate to prevent clotting. This blood was then subjected to centrifugation at 200 g for 10 minutes, resulting in separation into three layers: plasma, platelets, and red blood cells. Next, the plasma and platelets were further centrifuged under the same conditions, after which the majority of the supernatant plasma was removed. The plasma located above the buffy coat was then carefully extracted with a pipette. Following the removal of the supernatant platelet-poor plasma, the leftover plasma and sedimented platelets were thoroughly mixed to produce 1 mL of P-PRP. Of this, 0.6 mL was used for each intra-articular injection [7].

### *Radiological Evaluation*

Radiographic examinations were conducted using a GXR 52 S X-ray machine (DRGEM Co., Ltd., Seoul, Korea), with the X-ray beam settings at 40 KV, 25 MA, and 1.25 MAS. Two views, ventrodorsal and lateral, were captured for each examination. A single observer, blinded to the study,

assessed all digital images on a medical-grade monitor without any image enhancement, using Film Workstation 2.1.0 software (e., Film Medical Inc., Toronto, Canada). The radiographic criteria for mild osteoarthritis (OA) included signs of joint mineralization, slight subchondral bone remodeling, early periarticular new bone formation, or small, distinct bone fragments in the joint space. Moderate OA was indicated by more pronounced signs of these features. Marked OA was characterized by even more severe signs, presence of large bone fragments within the joint space, or moderate subluxation [8]

### *Histological Examination*

Eight weeks following the administration of monoiodoacetate, the rabbits were euthanized using a lethal dose of pentobarbital (120 mg/kg). Their joints were then preserved in 4% neutral buffered formalin for three days and decalcified using 10% Na<sub>2</sub>EDTA (Sigma-Aldrich) for thirty days. After decalcification, paraffin-embedded sections with a thickness of 5 µm were prepared for both toluidine blue and haematoxylin and eosin (H&E) staining procedures. The histological examination of the cartilage and synovium was conducted using Image J software (National Institutes of Health, Bethesda, MD, USA) and the findings were assessed according to Mankin's scoring system [9]

For the evaluation of the synovial membrane, a histological grading system was employed [10]. Mankin's scoring system evaluates osteoarthritic cartilage severity on a scale from 0 (normal) to 14 (severe OA), aggregating scores from structural integrity (0-6 points), matrix staining loss (0-4 points), cellular abnormalities (0-3 points), and tidemark integrity breaches (0-1 point). The synovial membrane is assessed through a separate scoring system focusing on inflammation and proliferation, each graded from 0 to 4. The final score is the average of these two grades. Inflammation levels range from 0 (none) to 4 (extensive inflammatory cell presence), while synovial proliferation is scored from 0 (none) to 4 (complete joint cavity occupation by proliferation). Three independent, trained evaluators, blinded to the study details, analyzed and scored the sections using these criteria.

### *Immunohistochemical Examination*

For Immunohistochemical staining, tissue sections were soaked in antigen retrieval solution (citrate buffer 10 mM citric acid, pH 6.0) for 16–18 hours at 60°C then incubated with 3% hydrogen peroxide for 10 minutes, and blocked with 1% sheep serum at room temperature for 1 hour to removal of non-specific reaction. Sections were incubated with anti-caspase 3 (Cell Signaling Technology), anti-TNF (ABclonal Technology) antibodies overnight at

4°C. For staining with secondary antibodies, horseradish peroxidase (HRP) labeled antibodies were used (1:400 in 1% bovine serum albumin [BSA] for 1 hour at 37°C). 3,3'-diaminobenzidine was used as a chromogen, and hematoxylin was used as a counterstain in immunohistochemistry [11].

#### *Biochemical Analysis*

##### *Interleukin 6 measurement*

IL-6 levels (pg/ml) were determined with ELISA kits available on the market (Quantikine, R&D Systems). The detection level for IL-6 was 0.7 pg/ml.

##### *C reactive protein measurement*

CRP levels in rabbit serum from osteoarthritis (OA), PRP-treated, and control negative groups were measured using ELISA kits as per the manufacturer's protocol (Demeditec, Germany). The kit included ready-to-use reagents such as MTP-International standard 5-vials, Chromogen Solution, Conjugate, and Stop solution, with the exception of washing solution and specimen diluents. A standard optical density (OD) curve was generated for each calibrator included in the kit, corresponding to the concentration values in mg/l. Samples with CRP levels > 3.0 mg/l were categorized as high risk.

##### *Erythrocytes Sedimentation Rate (ESR) Test*

Erythrocytes Sedimentation Rate (ESR) was measured using Westergren method [12]

##### *Data Analysis*

The data are displayed as mean  $\pm$  SEM. Statistical analyses were performed using GraphPad Prism 5 and 9 (GraphPad Software, San Diego, CA, USA). Results of blood parameters were statistically evaluated using one-way ANOVA followed by Duncan's multiple range tests with the SPSS programming tool (IBM SPSS 20®, IBM Corp., Armonk, NY, USA). All significance statements were based on  $p < 0.05$ .

## **Results**

The growth observation revealed lameness, swelling, hotness and redness around the femorotibial joints in OA group, while the control negative and PRP-treated groups were normal.

#### *Radiological finding*

The average joint was seen by x-ray in the control negative group. The monoiodoacetate-injected group (OA) revealed moderate osteoarthritis with narrowing of joint space and little osteophyte formation, attended by sclerosis and mild subchondral bone distortion. The treated group showed a slight joint space narrowing compared to the control negative group (Fig. 1&2).

#### *Histological finding*

The cartilage of the femorotibial joint was a hyaline type. The most superficial cells were elongated, and the chondrocytes were in lacunae in single or paired cells. A basophilic matrix separates the lacunae. The OA model showed fragments in the tibial cartilage only, but the femoral cartilage was intact, with cracks deep into the middle of the cartilage. The injured cartilage showed fragmentation, degeneration of the matrix and apoptosis of chondrocytes. The PRP-treated group repaired the cartilage with its matrix. The thickness of tibial cartilage was reduced in the OA group compared to the control negative and PRP-treated group.

The synovium in the control negative group appeared lined with simple squamous to cuboidal cells and covered fibro-elastic connective tissue stroma with many blood vessels and connective tissue cells. In the OA group, the synovium lining appeared mildly hyperplastic to two to three layers, with highly congested blood vessels and moderate leukocytic infiltration and extravasation of blood. The treated group showed mild congestion of blood vessels and mild thickness of synovial lining Fig (3).

The matrix stain with toluidine blue appeared to have a homogenous matrix distribution in the control negative and PRP-treated group, while the control positive OA group showed patches of dark and light staining in its matrix. The light staining lost its matrix Fig (4).

Mankin's and Kristensen's scoring for cartilage and synovium showed significant defects in the OA group compared to the control negative and PRP-treated group. There was no substantial change between the control negative and PRP-treated groups (Tables 1 & 2).

#### *Immunohistochemical finding.*

Both TNF $\alpha$  levels, indicating inflammation, and caspase3 levels, indicating apoptosis, were found to be lower in both control negative and PRP-treated groups compared to the osteoarthritis group, across chondrocytes in articular cartilage as well as in the synovial lining and stroma. No significant difference was observed between the control negative and PRP-treated groups, as illustrated in Fig. 5 and 6.

#### *Biochemical analysis*

The levels of ESR, CRP, and IL-6 were significantly higher in the group injected with MIA (OA group) compared to both the control negative and PRP-treated groups. Between the control negative and PRP-treated groups, there were no significant differences observed (Fig. 7).

## **Discussion**

Blood derivatives used for tissue repair have gained popularity in treating musculoskeletal injuries. Among these, PRP has been recognized for its potential in addressing orthopedic conditions [13]. Our method for producing PRP involves two centrifugation steps of 10 ml of blood at 200 g each, yielding one ml of PRP. This process aligns with the procedure described [14] To achieve a higher concentration of platelets, this approach was taken, but it resulted in greater changes to platelet shape and was more prone to slight mistakes in the preparation process than methods using single centrifugation. Various techniques, including single, double, or triple centrifugations, filtration, and plateletpheresis, have been employed by others, sometimes utilizing activating agents to aid the process [15]

In general, [16] Demonstrated the effectiveness of PRP in a rabbit model with collagenase-induced osteoarthritis (OA), intra-articular PRP injections facilitated cartilage healing across all levels of OA severity, showing a particularly noticeable impact in cases of moderate OA. Saito *et al.* [17] Employed a rabbit model of osteoarthritis (OA) created by resecting the anterior cruciate ligament, treating it with injections of gelatin hydrogel microspheres infused with PRP. These injections significantly halted the advancement of OA, as observed through both morphological and histological evaluations, although the use of PRP alone led to minimal regeneration. Characteristic signs of OA in X-ray examinations are noticeable osteophyte formation, reduction in joint space, and joint deformatio [18,19]. This study also found that groups with untreated arthritis exhibited imaging characteristics akin to those seen in osteoarthritis. X-ray analyses indicated that the groups receiving treatment had somewhat reduced levels of osteophyte development and joint deformity compared to the untreated group.

Our findings revealed the presence of cartilage fragmentation and chondrocyte apoptosis by H&E loss of extracellular matrix as observed by toluidine blue in the joint of the monoiodoacetate osteoarthritic group. After eight weeks of treatment, these changes were restored, and the number of chondrocytes increased in the treated group. These findings could be attributed to the high intensity of growth factors in the highly activated platelets of PRP [20]. On the synovium, we showed hyperplasia in synoviocytes lining the joint cavity, congestion of blood vessels, extravasation of blood and infiltration of leucocytes in the group's stroma, which retains its normal morphology in the treated group. The anti-osteoarthritic effect of PRP on the regeneration of cartilage damage may attributed to its reduction of

the local inflammation and stimulation of synovium, causing reduce of IL 1 $\beta$  [21]

Over the past several decades, the detrimental impact of inflammatory markers (ESR and CRP) and pro-inflammatory cytokines (IL-6) on cartilage in the pathophysiology of osteoarthritis has been clarified. IL-1b, produced locally by synovial cells and articular chondrocytes, has been found in elevated concentrations in the synovial fluids of patients with osteoarthritis [22] and demonstrated to induce the expression of catabolic molecules, leading to the subsequent breakdown of the cartilage matrix [23].

The immunohistochemical finding revealed expression of TNF $\alpha$  and caspase as markers for inflammation and apoptosis, respectively, in OA group than control negative and PRP-treated groups in both cartilage and synovium. These results would attribute to the direct effect of PRP on the synovium to lower NF-KB activity and inhibit the activity of COX4 and CXCR4, which are essential factors for inflammatory reaction. PRP can up-regulate HGF, IL4 and TNF $\alpha$ , while HGF and TNF $\alpha$  block NF-KB expression to inhibit inflammation [24].

## **Conclusion**

The current study confirms the impact of using PRP intra articular injection in the treatment of OA by several scores, Mankin and Krestinsin scores. These scores indicate that PRP may be an efficient method for OA treatment.

### *Conflict of interest statement:*

The authors have disclosed that they do not hold any conflicts of interest related to the publication of this article.

### *Funding statement*

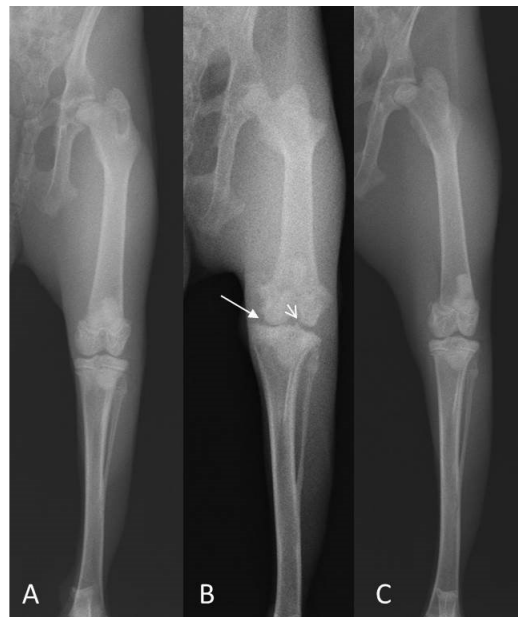
This research received no funding

### *Ethical Approval*

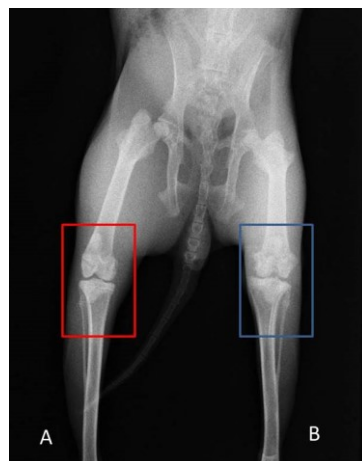
The experiments received approval from the ethics committee at the Faculty of Veterinary Medicine, Kafrelsheikh University, Egypt, and an ethical issue number was issued. KFS-IACUC/75/2024

### *Author`s contribution*

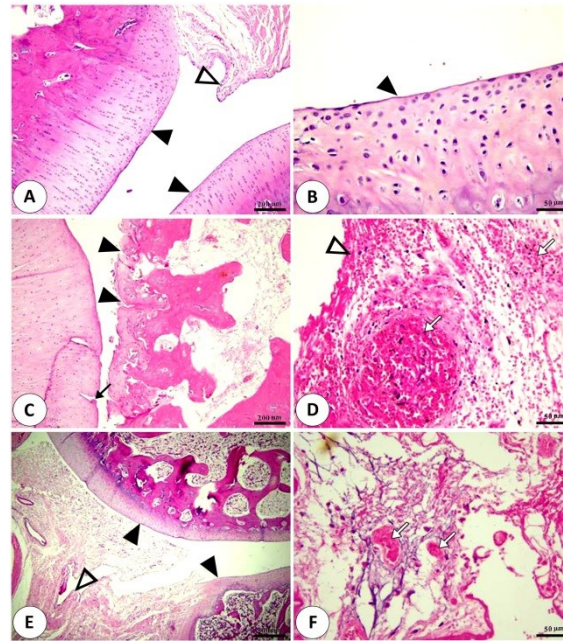
I.F.,F.A. designed the study plan, A.S.AT.,drafted the manuscript, F.F.,M.S.. helped in conducting the research work, conducting data analysis, and assisted in the writing of the manuscript, M.K. provided technical help in writing the manuscript, writing—review and editing. All authors have read and agreed to the published version of the manuscript.



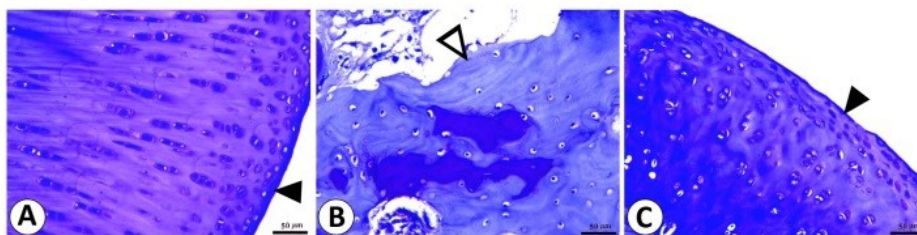
**Fig. 1. femorotibial joint arthritis model,** A. Normal femorotibial joint B. Marked osteoarthritis.



**Fig. 2. Day 30 post-injection** A. The control group was regular, B. Arthritis treated group showed mild osteoarthritis with minimal periarticular new bone formation (arrow) and regional joint space narrowing, C. Arthritis non-treated group showed moderate osteoarthritis. Mild subchondral bone sclerosis (long arrow), with new bone formation (short arrow).



**Fig. 3. Photomicrograph of H&E staining of femorotibial joint** showing normal structure of cartilage (black arrow heads) and synovium (white arrow head) in negative group (A&B). Cartilage and synovium of OA group (C&D) showing degeneration and fragmentation of tibial cartilage (black arrow head), cracks in femoral cartilage (black arrow), hyperplasia of synovial lining (white arrow head), sever congestion of synovial blood vessels and extravasation of blood (white arrow). Treated group (E&F) showing intact articular cartilages (black arrow head), slightly normal synovium (white arrow head) and mild congestion of blood vessels (white arrow).



**Fig.4. Photomicrograph of toluidine blue staining of femorotibial joint** showing homogenous staining (black arrow head) of cartilage matrix in control negative and treated groups (A and C) and heterogenous (white arrow head) staining (B).

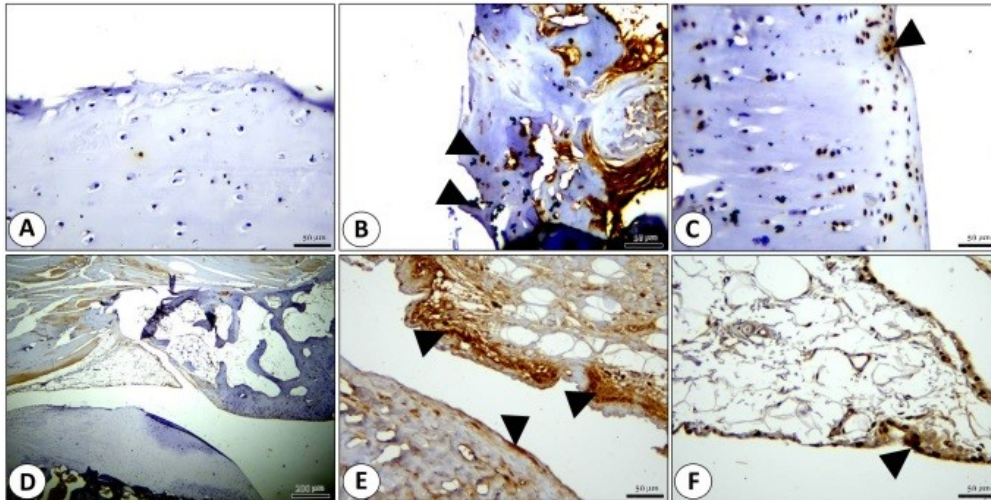
**TABLE 1. Mankin's scoring for grading of pathological lesion of articular cartilage**

	Negative group	OA group	PRP group
Structural abnormalities	0	5	2
Loss of staining	0	3	1
Cellular anomalies	0	3	1

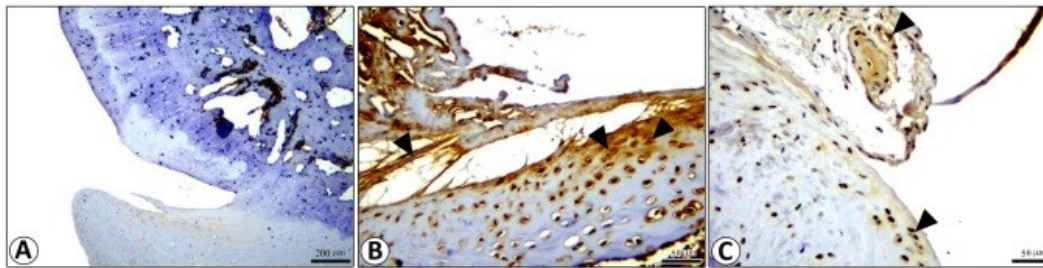
**TABLE 2. Krestensen's scoring for pathological lesion of synovium.**

	Negative group	OA group	PRP group
Inflammation	0	4	1
Synovial proliferation	0	4	1

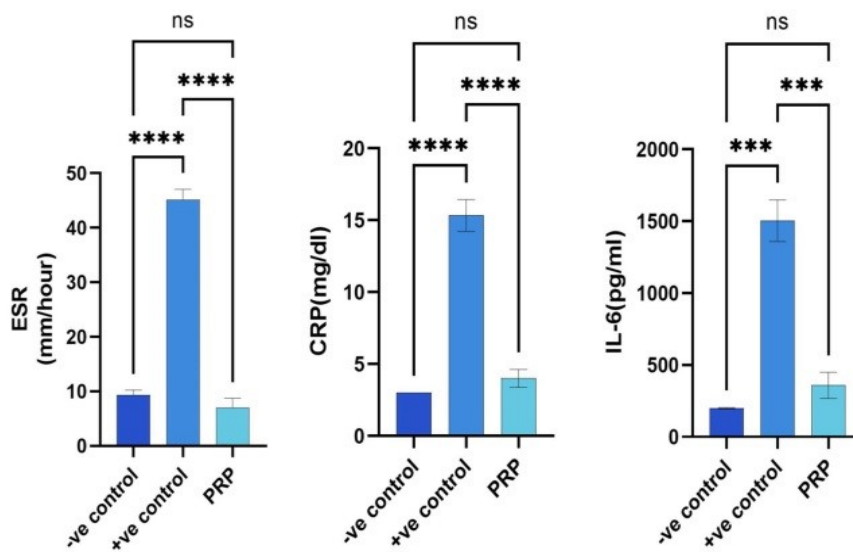




**Fig. 5. Photomicrograph of TNF $\alpha$  in femorotibial joint** showing no labelling in cartilage and synovium of negative group ( A &D) respectively, strong labelling (black arrow heads) in OA group in chondrocytes of the cartilage and synovium (B&E) , and weak labelling (black arrow heads) in cartilage and synovium in treated group (C&F).



**Fig. 6. Photomicrograph of caspase3 in femorotibial joint** showing no labelling in cartilage and synovium of negative group (A), strong labelling (black arrow heads) in chondrocytes and synovium of OA group(B) and weak labeling (black arrow heads) in treated group (C).



**Fig. 7. levels of ESR, CRP and IL-6 in control negative, OA and PRP treated groups.**

**References**

1. Kapoor, M., Martel-Pelletier, J., Lajeunesse, D., Pelletier, J.-P. and Fahmi, H. Role of proinflammatory cytokines in the pathophysiology of osteoarthritis. *Nature Reviews Rheumatology*, **7**, 33-42 (2011),
2. Liu, J., Song, W., Yuan, T., Xu, Z., Jia, W. and Zhang, C. A comparison between platelet-rich plasma (PRP) and hyaluronate acid on the healing of cartilage defects. *Plos one*, **9**, e97293(2014),
3. Piskin, D., Benjaminse, A., Dimitrakis, P. and Gokeler, A. Neurocognitive and neurophysiological functions related to ACL injury: a framework for neurocognitive approaches in rehabilitation and return-to-sports tests. *Sports Health* **14**, 549-555 (2022).
4. Zamani, M., Alizadeh-Tabari, S. and Zamani, V. Systematic review with meta-analysis: the prevalence of anxiety and depression in patients with irritable bowel syndrome. *Alimentary Pharmacology & Therapeutics*, **50**, 132-143(2019),
5. Hegazy, M.-E.F., Fukaya, M., Dawood, M., Yan, G., Klinger, A., Fleischer, E., Zagloul, A.W. and Efferth, T. Vitamin K 3 thio-derivative: a novel specific apoptotic inducer in the doxorubicin-sensitive and-resistant cancer cells. *Investigational New Drugs*, **38**, 650-661(2020).
6. Jaroń, A., Trybek, G. The pattern of mandibular third molar impaction and assessment of surgery difficulty: A retrospective study of radiographs in East Baltic population. *International Journal of Environmental Research and Public Health*. **18**, 6016. (2021)
7. Landesberg, R., Roy, M. and Glickman, R.S. Quantification of growth factor levels using a simplified method of platelet-rich plasma gel preparation. *Journal of Oral and Maxillofacial Surgery*, **58**, 297-300 (2000)
8. Arzi, B., Wisner, E.R., Huey, D.J., Kass, P.H., Hu, J. and Athanasiou, K.A. A proposed model of naturally occurring osteoarthritis in the domestic rabbit. *Lab Animal*, **41**(1), 20-25 (2012).
9. Mankin, H.J., Dorfman, H., Lippiello, L. and Zarins, A. Biochemical and metabolic abnormalities in articular cartilage from osteo-arthritic human hips: II. Correlation of morphology with biochemical and metabolic data. *JBJS.*, **53**, 523-537 (1971).
10. Kristensen, E., Bouillon, S., Dittmar, T. and Marchand, C. Organic carbon dynamics in mangrove ecosystems: a review. *Aquatic Botany*, **89**, 201-219 (2008).
11. Hammady, Maha. Application of Immunohistochemistry in Rat Models of Erosive Gastritis. *Egyptian Journal of Veterinary Sciences* **55**(4), 1021-1036 (2024)
12. Bain, A.R., Ainslie, P.N., Hoiland, R.L., Barak, O.F., Drvis, I., Stenbridge, M., MacLeod, D.M., McEneny, J., Stacey, B.S. and Tuailon, E. Competitive apnea and its effect on the human brain: focus on the redox regulation of blood-brain barrier permeability and neuronal-parenchymal integrity. *FASEB Journal*, **32**(4), 2305-2314 (2018)
13. Chevalier, X. Intraarticular treatments for osteoarthritis: new perspectives. *Current Drug Targets*, **11**, 546-560 (2010).
14. González, J.C., López, C. and Carmona, J.U. Implications of anticoagulants and gender on cell counts and growth factor concentration in platelet-rich plasma and platelet-rich gel supernatants from rabbits. *Veterinary and Comparative Orthopaedics and Traumatology*, **29**, 115-124 (2016).
15. Kwon, D.R., Park, G.Y. and Lee, S.-U. The effects of intra-articular platelet-rich plasma injection according to the severity of collagenase-induced knee osteoarthritis in a rabbit model. *Annals of Rehabilitation Medicine*, **36**, 458 (2012) .
16. Saito, M., Okamatsu-Ogura, Y., Matsushita, M., Watanabe, K., Yoneshiro, T., Nio-Kobayashi, J., Iwanaga, T., Miyagawa, M., Kameya, T. and Nakada, K. High incidence of metabolically active brown adipose tissue in healthy adult humans: effects of cold exposure and adiposity. *Diabetes*, **58**, 1526-1553 (2009)
17. Boulocher, C.B., Viguier, E.R., Cararo, R.D.R., Fau, D.J., Arnault, F., Collard, F., Maitre, P.A., Roualdes, O., Duclos, M.-E. and Vignon, E.P. Radiographic assessment of the femorotibial joint of the CCLT rabbit experimental model of osteoarthritis. *BMC Medical Imaging*, **10**, 1-10 (2010).
18. Singh, S. and Prasad, S.M. Growth, photosynthesis and oxidative responses of Solanum melongena L. seedlings to cadmium stress: mechanism of toxicity amelioration by kinetin. *Scientia Horticulturae*, **176**, 1-10 (2014).
19. Dohan Ehrenfest, D.M., de Peppo, G.M., Doglioli, P. and Sammartino, G. Slow release of growth factors and thrombospondin-1 in Choukroun's platelet-rich fibrin (PRF): a gold standard to achieve for all surgical platelet concentrates technologies. *Growth Factors*, **27**, 63-69 (2009).
20. Bendinelli, P., Matteucci, E., Dogliotti, G., Corsi, M.M., Banfi, G., Maroni, P. and Desiderio, M.A. Molecular basis of anti-inflammatory action of platelet-rich plasma on human chondrocytes: Mechanisms of NF- $\kappa$ B inhibition via HGF. *Journal of Cellular Physiology*, **225**, 757-766 (2010).



21. Wood, P., Bessel, M. and Fox, M. Long-period variables in the Magellanic Clouds-Supergiants, AGB stars, supernova precursors, planetary nebula precursors, and enrichment of the interstellar medium. *Astrophysical Journal, Part 1 (ISSN 0004-637X)*, **272**(1) 99-115 (1983).
22. Yang, J. H., Zhang, Y., Yin, W.-J., Gong, X., Yakobson, B.I. and Wei, S.-H. Two-dimensional SiS layers with promising electronic and optoelectronic properties: theoretical prediction. *Nano Letters*, **16**, 1110-1117 (2016).
23. Saklatvala, J. Tumour necrosis factor  $\alpha$  stimulates resorption and inhibits synthesis of proteoglycan in cartilage. *Nature*, **322**, 547-549 (1986).
24. Marmotti, A., Rossi, R., Castoldi, F., Roveda, E., Michielon, G. and Peretti, G.M. PRP and articular cartilage: a clinical update. *BioMed. Research International*, **2015**, 542502(2015)

### تقييم استخدام البلازما الغنية بالصفائح الدموية في علاج الالتهاب العظمي المفصلي في الارانب عن طريق الفحص النسيجي و الاشعة و الاختبارات الكيميائية

إبراهيم فوزي<sup>1</sup>، فاروق عبد المهدي<sup>1</sup>، أيمن السيد عتيبة<sup>2</sup>، فؤاد فرج<sup>3</sup>، مصطفى شكري<sup>4</sup> ومحمد كساب<sup>1\*</sup>

<sup>1</sup> قسم علم الخلايا والأنسجة - كلية الطب البيطري- جامعة كفر الشيخ- كفر الشيخ- مصر

<sup>2</sup> قسم الجراحة والتخدير والأشعة- كلية الطب البيطري- جامعة كفر الشيخ- كفر الشيخ- مصر

<sup>3</sup> قسم التشريخ وعلم الأجنة- كلية الطب البيطري- جامعة كفر الشيخ- كفر الشيخ- مصر.

<sup>4</sup> قسم وظائف الأعضاء- كلية الطب البيطري- جامعة كفر الشيخ- كفر الشيخ- مصر.

#### الملخص

يعتبر الالتهاب العظمي المفصلي النوع الأكثر شيوعاً من التهابات المفاصل والذي ينتج بسبب الاحتكاك الميكانيكي و الالتهابات. البلازما الغنية بالصفائح الدموية احد مشتقات الدم الغنية بالصفائح الدموية النشطة تتميز بوجود مزيج غني من عوامل النمو اللازمة لعملية اصلاح الغضاريف. أستخدم في هذه الدراسة عدد 12 أرنب تم تقسيمهم الي ثلاث مجموعات مجموعة حاكمة و مجموعة مصابة بالالتهاب العظمي المفصلي و المجموعة المصابة بالمعالجة ب البلازما الغنية بالصفائح. تم احداث الالتهاب العظمي المفصلي عن طريق حقن مادة الخلات احادية اليود Monoiodoacetate داخل المفصل ثم العلاج باستخدام البلازما الغنية بالصفائح. تم عمل فحص باستخدام تقنيات الاشعة السينية و فحص الانسجة و الاميونو هستو كيمستري و التحاليل الكيميائية لاستكشاف اصابة مفصل الركبة و تأني العلاج باستخدام البلازما الغنية بالصفائح. الالتهاب العظمي المفصلي المستحدث باستخدام مادة الخلات احادية اليود Monoiodoacetate يتميز بالتأثير علي الغضاريف المفصلي و تهشمها و موت الخلايا الغضروفية و فقدان المادة الخلوية للنسيج. يتميز التهاب الغشاء المفصلي بزيادة في عدد الخلايا المبطن للغشاء و احتقان الاوعية الدموية و الانصباب الدموي و تجمع لخلايا الدم البيضاء مع زيادة في معدل سرعة الترسيب و بروتين سي التفاعلي و الانترليوكين 1. المجموعة المعالجة باستخدام البلازما الغنية بالصفائح أظهرت الحفاظ علي الشكل الطبيعي لتركيب الغضاريف و الغشاء المفصلي. الخلاصة هو ان الدراسة اكدت علي التأثير الايجابي في استخدام البلازما الغنية بالصفائح الدموية في علاج الالتهاب العظمي المفصلي عن طريق قياسات Mankin and Krestinsin scores حيث اوضحت هذه القياسات مدي فاعلية البلازما الغنية بالصفائح الدموية في علاج الالتهاب العظمي.

**الكلمات الدالة:** التهاب المفاصل العظمي ، بلازما غنية بالصفائح، الأشعة، علم الأنسجة، المناعة النسيجية.