

Diagnostic Ability of Macular Ganglion Cell Asymmetry for Detection of Early Glaucoma

Mery G. Sabry^{a*}, Ali Mahmoud Ismail^a, Mohammed Hussein Elagouz^a, Ashraf Moustafa Mohammed^a

^aOphthalmology Department, Faculty of Medicine, Sohag University, Sohag, Egypt.

Abstract

Background: This work used spectral domain optical coherence tomography (SD-OCT) to assess the macular thickness asymmetry as a diagnostic marker of early glaucoma. Measurements of the thickness of the macula's superior and inferior quadrants as well as the overall thickness of macular ganglion cells will be used to do this.

Objectives: The main goal of the study was to use OCT to detect early occurrences of glaucoma in students at Sohag University who had normal or rising IOP.

Patients and Method: Case-control study patients and methodology There were 127 participants in this study, or 200 eyes total. 100 people in (Group 1) had early primary open angle glaucoma (cases) (100 eyes) with glaucomatous visual field abnormalities and/or signs of glaucomatous optic neuropathy (GON). With regard to (Group 2), there were 73 glaucoma-free, healthy controls (controls) with 100 eyes who were unharmed in their visual fields.

Results: There is a significant difference in age, total GCL, superior GCL, and inferior GCL between early glaucoma cases and normal cases (P value = 0.000). Early glaucoma cases also had lower levels of total GCL, superior GCL, and inferior GCL. Age and total GCL have a weakly negative connection ($r = -.158$, $P = 0.001$), which is weakly negative. In binary logistic regression, Inferior GCL (P value 0.001), Superior GCL (P value = 0.004), and Total GCL (P value = 0.03) are the three variables that affect glaucoma the most.

Conclusion: As a result, macular scans are a useful diagnostic tool for detecting early glaucoma. Age-related changes in the thickness of many retinal layers should also be taken into account when interpreting data on retinal layer and RNFL thickness in research examining the impact of disease on the retina.

Keywords: Macular thickness asymmetry; Spectral domain Optical Coherence Tomography (SD-OCT); Early glaucoma.

DOI: 10.21608/SVUIJM.2023.171037.1439

*Correspondence: meryelkomos89@yahoo.com

Received: 5 December, 2022.

Revised: 16 January, 2023.

Accepted: 29 January, 2023

Published: 25 June, 2024

Cite this article as: Mery G. Sabry, Ali Mahmoud Ismail, Mohammed Hussein Elagouz, Ashraf Moustafa Mohammed..(2024). Diagnostic Ability of Macular Ganglion Cell Asymmetry for Detection of Early Glaucoma. *SVU-International Journal of Medical Sciences*. Vol.7, Issue 2, pp: 241-249.

Copyright: © Sabry et al (2024) Immediate open access to its content on the principle that making research freely available to the public supports a greater global exchange of knowledge. Users have the right to Read, download, copy, distribute, print or share link to the full texts under a [Creative Commons BY-NC-SA 4.0 International License](https://creativecommons.org/licenses/by-nc-sa/4.0/)

Introduction

A progressive optic neuropathy called glaucoma is characterized by structural changes in the retina and optic nerve (selective loss of retinal ganglion cells (RGCs) and thinning of their axonal layer, known as the retinal nerve fibre layer (RNFL)), as well as functional visual field (VF) deficits that are typically found at the site of these structural changes (Felipe et al., 2012).

Several new technologies have been created to assess structural changes, one of which is optical coherence tomography (OCT), which provides the potential of providing high resolution cross-sectional images of retina in vivo (with axial resolution of 8- 10Mm2 and quantative measurement of retinal thickness) (Leung et al., 2009).

OCT has been widely used for assessment of glaucoma to detect Prepapillary retinal nerve fibre layer (p.RNFL), which is determined by acquiring a circular retinal scan around the optic nerve head and comparing the thickness of the retina to normal (Michelle et al., 2010),The head of the optic nerve by radial cross-sectional scans enable a consistent, objective evaluation of disc morphology with a reasonable level of discriminatory value. In practise, this function has a tendency to be less frequently employed than RNFL analysis (Mita et al., 2016) ,also it can detect Ganglion cell complex (GCC) analysis that can measures retinal thickness at the macular region . (Nakatani et al., 2011).

Patients and methods

Case-control study, There were two groups of 127 participants in this study, (200 eyes).

Group 1 consisted of 100 individuals who had early primary open angle glaucoma (cases) (100 eyes) with glaucomatous visual field abnormalities and/or signs of glaucomatous optic

neuropathy (GON). The presence of abnormal pattern standard deviation (PSD) outside of the 95% age-matched normal limits or a Glaucoma Hemifield Test (GHT) result outside of normal limits, as well as a cluster of three points with a probability of 5% or less in the pattern deviation map in at least one hemifield, including at least one point with a probability of 1% or a cluster of two points with a probability of 1%, were used to determine whether glaucomatous.

Group 2 consisted of 73 healthy, non-glaucomatous patients (controls) (100 eyes) who had no visual field impairment or other symptoms that would indicate the presence of the disease.

Some data(OCT & Visual fields) were gathered from Sohag Ophthalmology Investigative Center and some data from one of the private ophthalmology centers (Dar EL Youin) , all data were gathered between March 2019 and March 2020.

Each patient and control participant gave their written informed consent.

Before beginning, the study received approval from the Sohag Faculty of Medicine's medical research ethics council.

All participants were subjected to:

1. A thorough history is taken, including information on age, family history, the use of antiglaucoma medications and how long they have been used, the presence of diabetes, and the duration of hypertension.
2. A thorough ophthalmological examination that includes measuring visual acuity, refractive error, intraocular pressure (IOP), anterior segment examination by slit lamp biomicroscopy, and fundus examination with non-contact lenses.
3. Functional and structural assessment using the Humphrey field analyzer

745i standard automated perimetry (SAP) to determine the severity indices for glaucoma.

The glaucomatous VF defect was defined as:

- a. A pattern standard deviation (PSD) over 95% of normal limits as validated by at least two credible tests (false positive/negative rates of 15%, fixation losses of 15%), or a glaucoma hemifield test (GHT) that is outside of normal limits, or
 - b. A cluster of three points with a probability of less than 5% in the pattern deviation map, containing at least one point with a probability of less than 1%, or a cluster of two points with a probability of less than 1%.
4. Macular ganglion cell layer (GCL) thickness utilising an Optovue SD-OCT machine (3D-OCT, software version 2017,1,0,151 Optovue).

Statistical analysis

Statistical Package for the Social Sciences, version 26.0 for Windows,

was used to calculate all statistical analyses (SPSS, Inc, Chicago, Intl). Age, IOP, refractive status, VF indices, and GCIPL thickness differences between control (healthy eyes) and early glaucoma eyes were examined using a chi-squared test for categorical variables and an independent sample t-test for continuous variables. In my study, correlation analysis is also used. P value indicates the degree of significance. P value of 0.05 indicates a significant relationship, and 0.001 indicates a highly significant relationship. The correlation between age and the GCL parameters was evaluated using Pearson's correlation coefficients (r). The strength of correlation was defined as: r from 0-0.4 weak correlation, r from 0.4-0.7 moderate correlation, r from 0.7-1 strong correlation, r positive correlation (increase of one variable means increase of the other and vice versa), r negative correlation (increase of one variable means decrease of the other and vice versa).

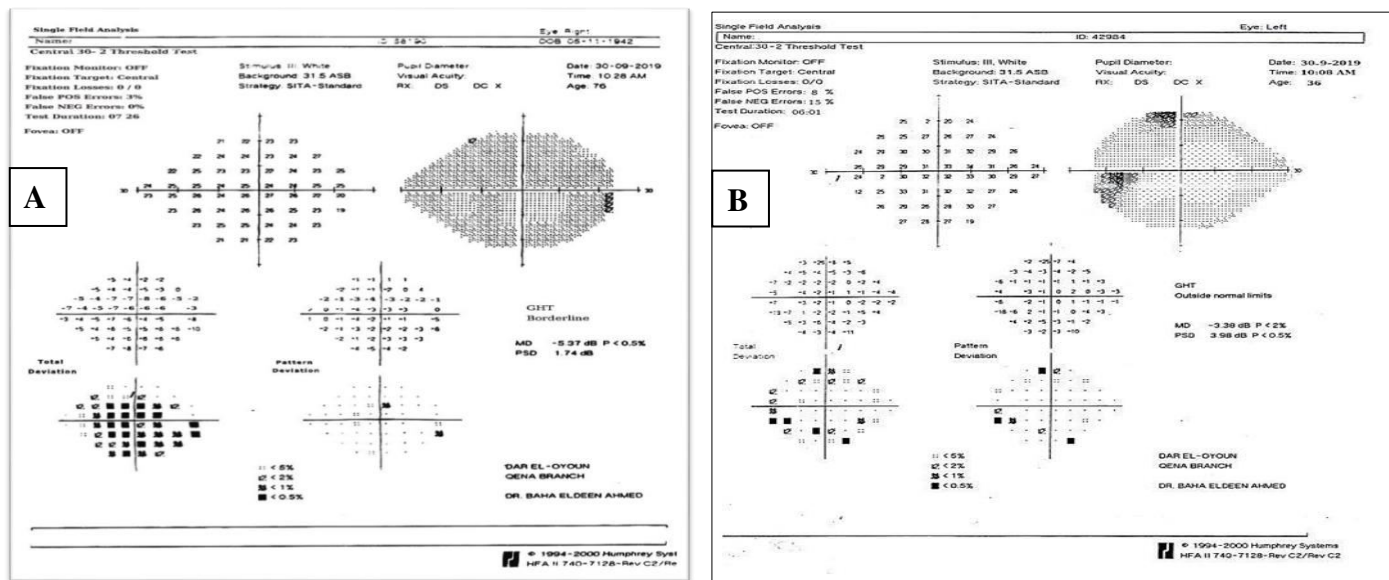


Fig.1.A,B Visual field with early glaucoma

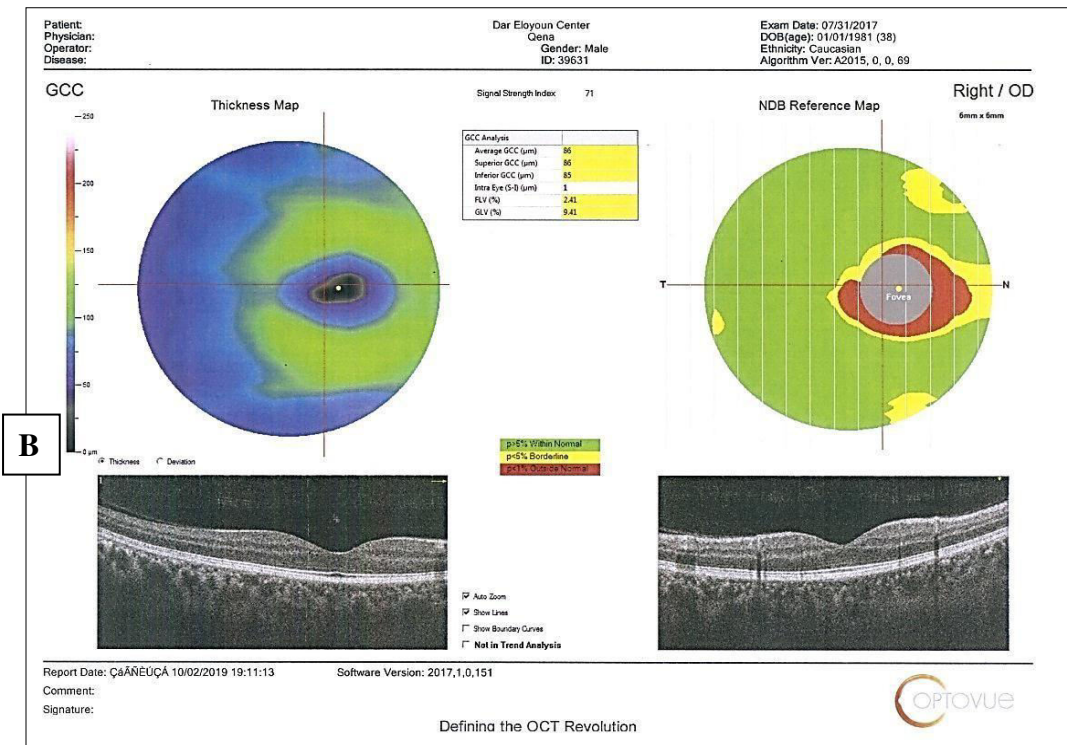
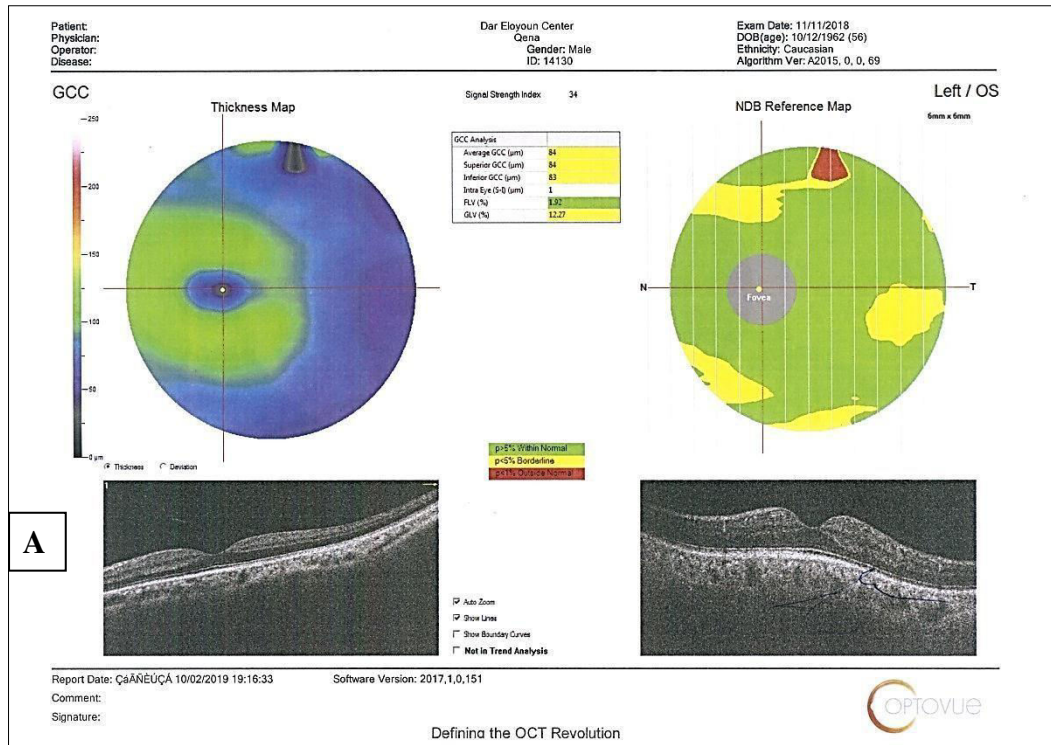


Fig.2.A,B Ganglion cell thickness map with early glaucoma

Results

Age, total GCL, superior GCL, and inferior GCL are all significantly different between the normal group

and the early glaucoma group, according to (Table.1), (P value = 0.000).

Table 1. The relationship between age and OCT parameters in the early glaucoma group and the normal group

Variable	Early Glaucoma (100 cases)	Normal (100 cases)	P value
Age	49.9 ± 14.7	38.9 ± 13.2	.000*
Total GCL	91.5 ± 6.1	99.4 ± 8.9	.000*
Superior GCL	90.5 ± 6.2	98.6 ± 9.6	.000*
Inferior GCL	92.3 ± 9.6	100.2 ± 8.4	.000*

Age and total GCL have a weakly negative association ($r = -.158$, $P = 0.02$), while age and superior

GCL have a weakly negative correlation ($r = -.223$, $P = 0.001$), according to (Table .2).

Table 2. The relationship between study group ages and the GCL parameters

Variables	Pearson correlation	P value
Age & Total GCL	-.158	0.02*
Age & Superior GCL	-.223	0.001*
Age & Inferior GCL	-.084	0.2

(Table.3) shows the results of binary logistic regression to determine the most and least effective factors. Inferior GCL had the highest correlation with

glaucoma (P value 0.001), followed by Superior GCL (P value = 0.004), and finally Total GCL (P value = 0.03).

Table.3. The results of a binary logistic regression analysis for the most predictable factor for glaucoma

Variables	Beta	P value
Total GCL	0.182	0.03
Superior GCL	0.178	0.004
Inferior GCL	0.175	0.000

Discussion

Glaucoma is a progressive optic neuropathy that causes structural changes in the optic nerve and retina (selective loss of retinal ganglion cells (RGCs) and thinning of their axonal layer, known as the retinal nerve fibre layer (RNFL)). These changes cause the optic nerve to appear normal in morphology and may alter the visual field (VF). Glaucoma may cause blindness if it is not identified and treated in its early stages.

It is understood that structural

damage, including the loss of retinal ganglion cells and their axons, occurs before functional damage, which appears as typical VF changes. (Wollstein et al.,2004)

This study uses spectral domain optical coherence tomography (SD-OCT) as a diagnostic indicator of early glaucoma with the goal of identifying the significance of ganglion cell layer thickness analysis in the diagnosis of early glaucoma and also to know the first parameter affected in early glaucoma. This was accomplished by

measuring the thickness of the macular superior and inferior quadrants as well as the total thickness of macular ganglion cells.

VF and OCT parameters (ONH, RNFL, and GCC) are used to diagnose glaucoma. This study found that the macula can be helpful in the identification of early glaucoma, which is in line with many other investigations, including those by Hiroshi Yamada et al. (Nouri et al., 2013) study, Mwanza JC, et al study. (Kanski et al., 2015) – In Hiroshi et al study, that were completed in 122 patients' 122 eyes, including 30 normal eyes, 30 preperimetric eyes, 31 early glaucoma eyes, and 31 advanced glaucoma eyes, revealed that glaucoma severity was correlated with a reduction in thickness parameters. (Nouri et al., 2013) In specifically for the ganglion cell layer, they produce Macular retinal layer thickness data, show promise as early indicators of glaucomatous retinal damage. (Nouri et al., 2013) Visual field abnormalities might not become noticeable until the loss of more than 40% of the optic nerve fibre layer (Benedict et al., 2019). Also, The loss of retinal ganglion cell axons is routinely diagnosed by the presence of thinning of the optic nerve neuroretinal rim, peripapillary retinal nerve fiber layer (RNFL), and/or inner layers of the macula, preceding perimetric visual field changes and eventual blindness so we regarded that macular thickness evaluation precede VF in diagnosis of early glaucoma, and this agreed with the study of Benedict C. Umezurike, et al. (Gurses et al., 2004).

The Benedict et al. study showed that the presence of thinning of the optic nerve neuroretinal rim, peripapillary RNFL, and inner layers of the macula is frequently used to detect the loss of retinal ganglion cell axons. These structural modifications

may come before perimetric visual field modifications. The ONH, circumpapillary (cp) RNFL, and macula with their separate layers are three anatomic sites in glaucoma where structural anomalies can be analysed by OCT (Gurses et al., 2004). This study demonstrated a relationship between aqueous buildup and elevated IOP that is caused by an imbalance between aqueous humour secretion and drainage. The ONH suffers from ischemia and hypoxia as a result of the pressure on the RGC, which causes death. This results in retinal ganglion cell death, loss of optic nerve fibres, and inhibition of anterograde and retrograde axonal transit, along with recognizable alterations in their appearance (Gurses et al., 2004) In this investigation, we found that RNFL scans are less reliable than macular scans (Vizzeri et al., 2009) This can be explained by the fact that accurate operator positioning of the scan circle is necessary for RNFL scanning, and any misalignment tends to result in changes in RNFL data. Macular scans, on the other hand, need internal fixation. (Michelle et al., 2010). Regression analysis was used in this study to show that in the early stages of glaucoma, the inferior quadrant of the macula (inferior GCC) is most affected, with a highly significant value ($p = 0.001$) compared to the superior quadrant (superior GCC) and the total macular thickness (total GCC) ($p = 0.004$ & $p = 0.03$, respectively). Study by Mafalda Mota et al (Nakatani et al., 2011) Similar findings were found by studies by Tomomi Higashide et al (Parikh et al., 2009) and Nakatani et al (Bowd et al., 2011). That was carried out in the study by Mafalda Mota et al. on 70 eyes of 54 glaucoma patients. SD-OCT was performed on all patients, and VF was evaluated using static

computerised perimetry. They sought to establish a correlation between superior vs. inferior macular thickness and the thinning of the superior and inferior temporal RNFL, based on the total macular thickness (TMT) determined by SD-OCT. (Nakatani et al., 2011) The study results confirm some studies which claim that cellular damage in glaucoma is more severe in inferior macula particularly in earlier stages of glaucoma.

In Nakatani et al study, one eye from 32 early glaucoma patients 32 normal participants underwent macular scans and peripapillary RNFL scans with SD-OCT 3 times on the same day. Correlation of OCT data with visual field defects was evaluated by linear regression analysis. (Bowd et al., 2011)

The study indicated that inferior inner macular volume had the best connection with mean deviation (P 0.001), and that macular parameters for the diagnosis of early glaucoma by SD-OCT exhibited good consistency and discriminating power comparable to peripapillary RNFL parameters. Both (Bowd et al., 2011) and this support the findings of this study.

But, other studies reported that inferior GCC parameters statistically significant lower (p=0.002) as in R Thomas et al study (Nazli et al., 2013)

In the early glaucoma group, only two parameters (the outer inferior average volume (p = 0.003) and the outer inferior average thickness (p = 0.002)) were statistically substantially lower than in the control group, according to a study by R Thomas et al (Nazli et al., 2013). They came to the conclusion that early glaucoma significantly differs from normals in terms of outer inferior macular thickness and volume characteristics. The limited utility of macular measures in the diagnosis of early glaucoma is shown by the

moderate sensitivity and specificity (Nazli et al., 2013). The number of patients included in the study (56 eyes with early glaucoma and 75 normal eyes in R Thomas vs. 100 eyes with early glaucoma and 100 normal eyes in this study), age, ethnicity, and the type of OCT instrument utilised in the study could all have contributed to this. According to Nazli Demirkaya et al study's findings, there is a substantial positive association between peripapillary RNFL thickness and pericentral GCL thickness (R = 0.553, P 0.001). It is possible that a thinner GCL would in fact result in a thinner RNFL because the RNFL is made up of GCL axons. Age was associated with a substantial reduction in mean peripapillary RNFL thickness (R = 0.332, P 0.001). (Nazli et al., 2013) .

When evaluating data on retinal layer and RNFL thickness in research concerned with the effects of disease on the retina, Nazli Demirkaya et al. concluded that changes in the thickness of numerous retinal layers occur with increasing age. It may also be possible to use the age-related changes in the retina as a quick and easy way to establish an objective measure for ageing generally or ageing caused by systemic disorders. (Nazli et al., 2013)

Conclusion

Our results suggest that macular scans is a good diagnostic ability for the detection of early glaucoma, these findings are very useful, especially in eyes with unusually small or large optic discs, tilted optic disc, peripapillary atrophy, or when optic disc scan cannot be captured.

So, we recommend performing VF test with both macular and p.RNFL scanning in all subjects suspected or known to have glaucoma for better and earlier diagnosis as they improve the sensitivity of glaucoma detection.

With early diagnosis and management we can decrease the incidence of irreversible glaucomatous damage.

Also we found changes in the thickness of several retinal layers occur with increasing age and this should be taken into consideration while interpreting retinal layer and RNFL thickness data in studies concerned with the effects of disease on the retina. The age-related changes of the retina may also be of use as a simple method to provide an objective parameter for aging in general, or aging in the course of systemic diseases.

References

- **Benedict CU, Moses OK, Okechukwu U. (2019).** Primary Open Angle Glaucoma: The Pathophysiology, Mechanisms, Future Diagnostic and Therapeutic Directions., *Ophthalmology Research: An International Journal*,10 (3): 1-17
- **Felipe A Medeiros, Linda M. Zangwill, Christopher Bowd, Kaweh Mansouri, Robert N. Weinreb et al. (2012).** The Structure and Function Relationship in Glaucoma.: *Investigative Ophthalmology & Visual Science* , 53: 6939-6946.
- **Gurses R, Teng C, Vessani R . (2004).** Macular and retinal nerve fiber layer thickness measurement reproducibility using optical coherence tomography (OCT-3). *Journal of Glaucoma*,13:238–244.
- **Leung CK, Yu M, Weinreb RN, Ye C.(2009).** Retinal nerve fiber layer imaging with spectral domain optical coherence tomography: a variability and diagnostic performance study. *Ophthalmology*, 119(4):731
- **Michelle L. Gabriele, Hiroshi Ishikawa, Joel S. Schuman, Richard A. Bilonick, Jongsick Kim, Larry Kagemann, et al. (2010).** Reproducibility of Spectral-Domain Optical Coherence Tomography Total Retinal Thickness Measurements in Mice, *Investigative Ophthalmology & Visual Science*, (51): 6519-6523.
- **Mita S, Sabyasachi B, Debabrata D.(2016).** Comparative analysis of macular and peripapillary retinal nerve fiber layer thickness in normal,glaucoma suspect and glaucomatus eyes by optical coherence tomography.*Nepal J ophthalmol*,8(16):110- 118.
- **Nakatani Y, Tomomi H, Shinji O. (2011).** Evaluation of macular thickness and peripapillary retinal nerve fiber layer thickness for detection of early glaucoma using spectral domain optical coherence tomography. *Journal of Glaucoma*, 20(4):252-259
- **Nazli D, Hille W, Sanne M. (2013):** Effect of Age on Individual Retinal Layer Thickness in Normal Eyes as Measured With Spectral-Domain Optical Coherence Tomograph. *Invest Ophthalmol Visual Science*, 54(7): :4934–4940
- **Nouri-Mahdavi K, Nowroozizadeh N, Nassiri N.(2013).**Macular ganglion cell/inner plexiform layer measurements by spectral domain optical coherence tomography for detection of early glaucoma and comparison to retinal nerve fiber layer measurements.*Am J Ophthalmol*, 156:1297-1307.
- **Parikh RS , Parikh SR, Thomas R.(2009).** Diagnostic capability of macular parameters of Stratus OCT 3 in detection of early glaucoma.*British journal of ophthalmology*, 94(2) :197-201.
- **Vizzeri G, Bowd C, Medeiros F.(2009).** Effect of signal strength and improper alignment on thevariability of stratus optical coherence tomography retinalnerve

fiber layer thickness measurements.
Am J Ophthalmol, 148: 249–255.

- **Wollstein G, Schuman JS, Price LL, Aydin A, Beaton SA, Stark PC, et al.(2004).**Optical coherence

tomography (OCT) macular and peripapillary retinal nerve fiber layer measurements and automated visual fields. .Am J Ophthalmol. 138(2):218-25.