

## Use of Lyophilized Growth Factors Foam in Chronic Ulcers

ADEL MABROUK, M.R.C.S.\*; HOSSAM M. FAHMY, M.D.\*\*; AMR MABROUK, M.D\*.;  
MAI RAAFAT HAMMAD, M.Sc.\* and MOHAMED SAMIR BADAWY, M.D.\*

*The Department of Plastic, Burn and Maxillofacial Surgery\* and Department of Laboratory & Transfusion Medicine\*,  
Faculty of Medicine, Ain Shams University*

### Abstract

**Background:** Treatment of chronic ulcers involves addressing the underlying cause and interventions to improve the process of healing such as autologous platelet-rich plasma. Platelet-rich plasma has been extensively studied for its potential in promoting healing of chronic ulcers as it contains a high concentration of growth factors such as platelet derived growth factor, epithelial growth factor and fibroblast growth factor. Advanced growth factor delivery systems have been developed to prolong the bio-activity of growth factors.

LGF have been developed by a patented method to overcome the discrepancies of conventional platelet rich plasma.

**Objective:** In this study, we present LGFoam as a topical agent containing Lyophilized growth factors, for use in chronic lower limb ulcers for the purpose of improving healing.

**Methodology:** Comparison of ulcer size between LGFoam topically applied to non-healing lower limb ulcers of various etiologies, as opposed to conventional dressing with a 30-day follow-up period.

**Conclusion:** Several advanced growth factors delivery systems have been developed for topical use. However, conflicting evidence exists for their efficacy, warranting further research.

In our study, there was a statistically significant decrease in ulcer size for the LGFoam group, encouraging future studies into its use in promoting wound healing in general, especially chronic non-healing ulcers as a problematic entity.

**Key Words:** Ulcer – Chronic wound – Growth factors – PRP.

**Ethical Committee:** The study was approved by the Ethical Committee of Ain Shams University in January 2019 (FMASU R 41/2019).

**Disclosure:** No conflict of interest.

**Funding:** This research received no specific grant from any funding agency in the public, commercial, or not-for-profit sectors.

### Introduction

A chronic ulcer is a non-healing wound persisting for a period of more than six weeks and show-

ing no tendency to heal after three months of appropriate treatment. It can develop due to trauma, chronic venous insufficiency, diabetes, or chronic ischemia. A common site for chronic ulcers is the lower limb, mostly on the legs, ankles, or feet [1].

Treatment of chronic ulcers includes addressing the underlying cause and local interventions to improve the process of healing such as autologous platelet-rich plasma (PRP) [1,2].

PRP has been extensively studied for its potentials in promoting the healing of chronic wounds such as ulcers, improving ulcer depth and healing rate, hence making it a promising and safe modality of treatment [2,3,4,5].

PRP contains a high concentration of growth factors, which play an essential role in wound healing [6].

Growth factors influence wound healing by several mechanisms. They have chemotactic properties that attract inflammatory cells and fibroblasts into wounds, they stimulate cellular proliferation, they stimulate angiogenesis, and they influence the synthesis of growth factors by neighboring cells [7].

Some of the most important growth factors that have been extensively studied are platelet-derived growth factor (PDGF), fibroblast growth factor (FGF), and vascular endothelial growth factor (VEGF) [7].

PDGF is released from platelets following tissue injury [8], and it serves to initiate inflammatory response by chemotaxis to attract neutrophils, macrophages, fibroblasts into the wound site [9]. It also up-regulates the production of other factors such as insulin growth factor-1 [10]. FGF are a family of factors produced by keratinocytes, fibroblasts, endothelial cells and mast cells [11,12]. They are responsible for granulation tissue formation, re-epithelialization, and remodeling of tissues [13]. They upregulate synthesis and deposition of several extracellular matrix components and increase the motility of keratinocytes [14]. The VEGF family promote angiogenesis through stimulating the migration of endothelial cells [15,16].

---

**Correspondence to:** Dr. Mai Raafat Hammad,  
E-Mail: mairaaafat1991@hotmail.co.uk

PRP can be applied topically or used as an intralesional injection [17]. To form a platelet gel that can be applied to the ulcer, an activator solution such as thrombin with calcium chloride can be added [17]. Advanced growth factor delivery systems have been developed to prolong the bio-activity of growth factors [18].

Lyophilized growth factors (LGF), prepared from equine platelets were used in a previous animal study and showed improvement of wound healing [19]. It is produced according to a patented method (Code number: WO2018091713).

In this study, we present LGFoam for use in chronic lower limb ulcers for the purpose of improving healing.

### Patients and Methods

*Sample size:* 20 patients (10 LGFoam group, 10 control group).

*Setting:* Department of Plastic, Burn and Maxillofacial Surgery, Ain Shams University, Cairo, Egypt. Between January 2019 to July 2022.

*Inclusion criteria:* Patients with chronic lower limb ulcers that had developed within a year of the study, of any etiology except malignant ulcers, size of ulcers ranging from 5-50 mm in diameter. Laboratory investigations (complete blood picture, serum albumin, liver enzymes and kidney function tests) were conducted for all patients and patients were only included if hemoglobin was above 10g/dl, serum albumin was above 10, and liver enzymes and kidney function tests were within normal ranges.

*Exclusion criteria:* Ulcers with active signs of infection such as redness, hotness and tenderness of surrounding skin or purulent discharge. Patients who had undergone any previous surgical intervention to the ulcer itself such as surgical debridement and active smokers (patient who had not ceased smoking at least one month before the study).

*Study period:* 1 January 2019 to 31 July 2022.

#### Intervention:

LGFoam (Fig. 1) is a white, porous, inelastic pad consisting of Human LGF suspended in a marine collagen and then lyophilized. LGF have been developed by a patented method to overcome the discrepancies of conventional platelet rich plasma (PRP) [19]. It is a new and refined form of PRP in which allogenic pathogen free platelets are used as a source of growth factors instead of autologous platelets. In vitro stimulation of platelets is done to free growth factors from their site of storage in the alpha granules, and thus avoiding the further use of thrombin or calcium chloride for platelets activation. The lyophilized growth factors also have the

advantage of possessing a lengthier shelf life (12-18 months) in comparison to autologous PRP (8 hours). The amount of growth factors in each vial is standardized to be equivalent to those coming from platelets within 20ml of whole blood, with a platelet count of 1 million per microliter. It is then subjected to UV/Riboflavin treatment to eliminate any pathogens.

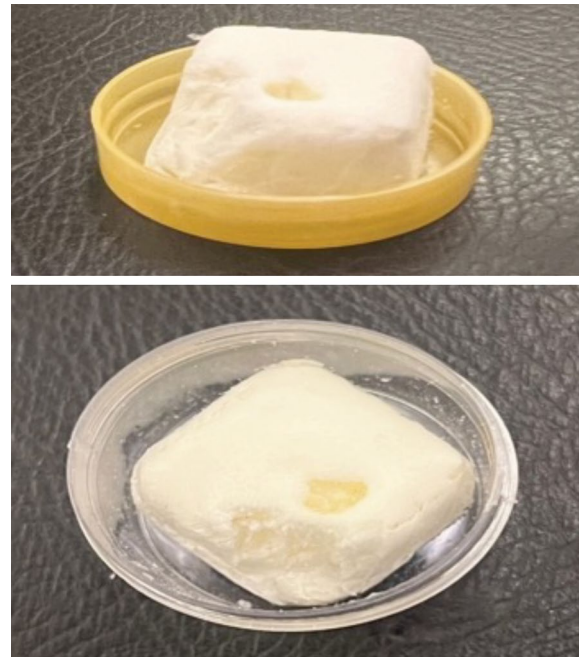


Fig. (1): LGFoam.

On topical application the foam transforms into a soft gel sheet on contact with wound exudate hence maintaining a moist wound environment which helps in epithelialization and granulation tissue formation. The foam is hydrophilic and biodegradable, thus the oozing of any drops of serous fluid, will lead to a breakdown in the proximal side of the foam. Eventually there is sustained release of the LGF incorporated within.

*Patients were divided into two groups:*

- 1- *LGFoam group:* Dressing was done by betadine, then washing with normal saline solution, then foam was applied before non-adherent gauze. Dressing was done every other day.
- 2- *Control group:* Conventional wet-to-dry dressing was done using betadine, washing with normal saline solution, then antibiotic ointment was placed before applying non-adherent gauze. Dressing was changed on a daily basis.

No oral antibiotics were administered during the study period. Only orally administered drugs used were medications patients used regularly such as antihypertensive drugs, oral hypoglycemic drugs, and beta-blockers, but no vasodilators.

No additional procedures were done except for dressings in both groups, i.e curettage. Non-compressive below the knee crepe bandages were used to seal the dressing in both groups and all patients were instructed to elevate their limbs when not ambulating.

Evaluation was done once every other day by the attending physician in the outpatient clinic for 30 days to compare ulcer size.

*Statistical analysis:*

Performed using computer software statistical package for the social science (SPSS, version 20; SPSS Inc., Chicago, Illinois, USA).

Quantitative (numerical) normally distributed variables were described as mean ± standard deviation (SD). Significance level was set at *p*-value of less than 0.05.

**Results**

Thirteen males and seven females were included in this study. Mean age for patients was 60.85±7.74 years (range 45-72). Patient characteristics, as well as size and etiology of ulcers are summarized in Table (1).

Table (2) demonstrates ulcer size in millimeter (mm) at the start of the trial and after 30 days. Over the 30 day follow-up period, there was a statistically significant reduction in ulcer size in the LGF group (*p*=0.001891), with a mean size of 30.9mm reduced to 7.7mm and a non-statistically significant reduction in the control group (*p*=0.695), with a mean size of 30.1mm reduced to 27mm.

Table (1): Patient Characteristics, ulcer size and ulcer etiology.

Variable	LGF group	Control group
Age (years)	59.8±9.4	61.9±5.9
<i>Sex:</i>		
Male	6	7
Female	3	4
Ulcer size (mm)	30.9±17.9	30.1±15.53
<i>Etiology:</i>		
Traumatic	2	0
Ischemic	3	2
Venous	2	2
Diabetic/ Neuropathic	2	4
Unspecified	1	2

Table (2): Ulcer size before intervention and after 30 days in both study groups.

Ulcer size (mm)	LGfoam group (n=10)	Control group (n=10)
Before	30.9±17.9	30.1±15.53
After 30 days	7.7±9.1	27±12.26

Figs. (2,3) show improvement in ulcer size in two cases from the LGfoam group.

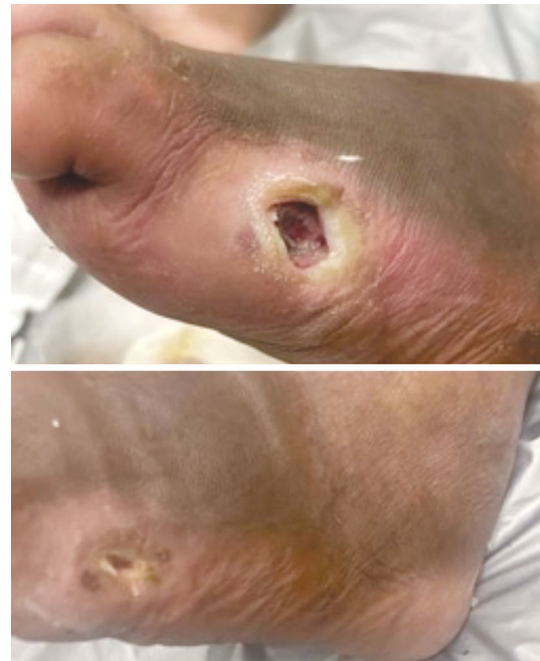


Fig. (2): A case of a 65-year-old male patient, with an ischemic ulcer over the lateral aspect of right foot before intervention (top), and at day 14 of using LGF (bottom).

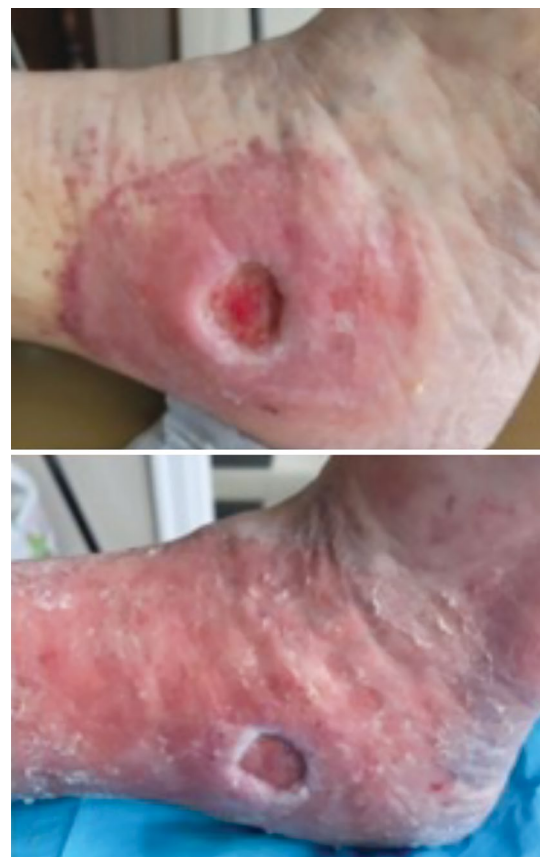

Fig. (3): A case of 57-year-old female patient, with an ischemic ulcer over the lateral aspect of right foot before intervention (top), and at day 5 of using LGF.

## Discussion

Management of chronic lower limb ulcers include some key options such as compression therapy using stockings and limb elevation [1,20,21], debridement by either surgical, mechanical, or enzymatic methods to remove dead tissues and hence promote healing [22], medications such as pentoxifylline and aspirin which improve circulation and reduce inflammation [23,24], vacuum-assisted closure which may help to promote healing despite limited evidence [25], surgery for cause such as arterial insufficiency or venous reflux [1], skin grafts [26], and autologous PRP containing growth factors [2-6,17].

Several advanced growth factors delivery systems have been developed for topical use [8] such as Regranex®, which is an FDA approved gel containing 0.01% becaplermin (recombinant human PDGF) used as an adjunct in the treatment of chronic diabetic foot ulcers [27,28], Fibrablast® spray (recombinant human FGF), first approved in Japan in 2017 but showed low in vivo stability [29,30], and Heberprot-P®, which contains recombinant human EGF, administered intralesionally 3 times per week [31,32]. However, conflicting evidence exists for efficacy of previously mentioned systems, warranting further research [18].

Different PRP preparation methods have been compared by Da Silva et al., regarding platelet concentrations, the capacity to preserve growth factor, and the ability of these preparations to produce better cellular metabolism showing that lyophilized PRP is a possible alternative to fresh PRP, with minor technical variability, large-scale production with increased shelf life that can be achieved using a single process of production [33].

An in-vitro study by Hariprasad et al. compared PRP, platelet-rich-fibrin, and lyophilized platelets using ELISA showing greater concentration of VEGF, FGF, and PDGF in the lyophilized preparation [34].

A study by Saputro et al., used allogenic lyophilized PRP in a full-thickness wound animal model, in which it significantly accelerated epithelialization and did not cause any local or general adverse reactions [35].

Yassin et al., used PRP wafers, manufactured using sodium carboxymethylcellulose, utilizing wound size measurements and histopathological analysis, to illustrate better results than lyophilized PRP powder [36].

Yeung et al., used a lyophilized PRP solution on deep second-degree burn injuries, which showed significant effectiveness on wound healing.

## Conclusion:

In this study, we present LGFoam for use as a topical agent in chronic lower limb ulcer with the aim of improving healing, demonstrated in this study by decrease in ulcer size.

Future research is encouraged with larger sample sizes and more homogenous study groups.

## References

- 1- Kahle B., Hermanns H.J. and Gallenkemper G.: Evidence-based treatment of chronic leg ulcers. *Dtsch Arztebl Int.*, Apr. 108 (14): 231-7, 2011. doi: 10.3238/arztebl.2011.0231.
- 2- Qu S., Hu Z., Zhang Y., Wang P., Li S., Huang S., Dong Y., Xu H., Rong Y, Zhu W., Tang B. and Zhu J.: Clinical Studies on Platelet-Rich Plasma Therapy for Chronic Cutaneous Ulcers: A Systematic Review and Meta-Analysis of Randomized Controlled Trials. *Adv Wound Care (New Rochelle)*, Feb. 11 (2): 56-69, 2022. doi: 10.1089/wound.2020.1186.
- 3- HUBER S.C., DE MORAES MARTINELLI B., QUINTERO M., DE PAULA L.Í.S., CATALDO J.L., DE LIMA MONTALVÃO S.A. and ANNICHINO-BIZZACCHI J.M.: A case series of platelet rich plasma in chronic venous ulcers. *Regen Ther.*, Apr. 5; 18: 51-58, 2021. doi: 10.1016/j.reth.2021.03.005.
- 4- Hesseler M.J. and Shyam N.: Platelet-rich plasma and its utility in medical dermatology: A systematic review. *J. Am. Acad. Dermatol.*, Sep. 81 (3): 834-846, 2019. doi: 10.1016/j.jaad.2019.04.037.
- 5- QU W., WANG Z., HUNT C., MORROW A.S., URTECHO M., AMIN M., SHAH S., HASAN B., ABD-RABU R., ASHMORE Z., KUBROVA E., PROKOP L.J. and MURAD M.H.: The Effectiveness and Safety of Platelet-Rich Plasma for Chronic Wounds: A Systematic Review and Meta-analysis. *Mayo. Clin. Proc.*, Sep. 96 (9): 2407-2417, 2021. doi: 10.1016/j.mayocp.2021.01.030.
- 6- PINTO J.M., PIZANI N.S., KANG H.C. and SILVA L.A.: Application of platelet-rich plasma in the treatment of chronic skin ulcer - case report. *An Bras Dermatol.*, Jul-Aug. 89 (4): 638-40, 2014. doi: 10.1590/abd1806-4841.20143004.
- 7- Greenhalgh D.G.: The role of growth factors in wound healing. *J. Trauma.*, Jul. 41 (1): 159-67, 1996. doi: 10.1097/00005373-199607000-00029.
- 8- UYSAL A.C., MIZUNO H., TOBITA M., et al.: The effect of adipose-derived stem cells on ischemia-reperfusion injury: immunohistochemical and ultrastructural evaluation. *Plast Reconstr. Surg.*, 124: 804-815, 2009.
- 9- Mardani M., Asadi-Samani M., Rezapour S., et al.: Evaluation of bred fish and seawater fish in terms of nutritional value, and heavy metals. *J. Chem. Pharm. Sci.*, 9: 1277-1283, 2016.
- 10- MARDANI M., MAHMOUD B., MORADMAND J.S., et al.: Comparison of the descurainia sophia and levostatin

- effect on the ldl cholesterol reduction, a clinical trial study. *J. Chem. Pharm. Sci.*, 9: 1329-1333, 2016.
- 11- Ghafarzadeh M. and Eatemadi A.: Clinical efficacy of liposome-encapsulated Aloe vera on melasma treatment during pregnancy. *J. Cosmet Laser Ther.*, 19: 181-187, 2017.
  - 12- Nie C., Yang D., Xu J., et al.: Locally administered Adipose-derived stem cells accelerate wound healing through differentiation and vasculogenesis. *Cell Transplant*, 20: 205-216, 2011.
  - 13- Jaferian S., Soleymaninejad M., Negahdari B., et al.: Stem cell, biomaterials and growth factors therapy for hepatocellular carcinoma. *Biomed Pharmacother.*, 88: 1046-1053, 2017.
  - 14- Lee S.H., Lee J.H. and Cho K.H.: Effects of human adipose-derived stem cells on cutaneous wound healing in nude mice. *Ann. Dermatol.*, 23: 150-155, 2011.
  - 15- Jaferian S., Soleymaninejad M. and Daraee H.: Verapamil (VER) enhances the cytotoxic effects of docetaxel and vinblastine combined therapy against non-small cell lung cancer cell lines. *Drug Res. (Stuttg)*, 68, 2017. DOI:<https://doi.org/10.1055/s-0043-117895>
  - 16- Huang S-P., Hsu C-C. and Chang S-C., et al.: Adipose-derived stem cells seeded on acellular dermal matrix grafts enhance wound healing in a murine model of a full-thickness defect. *Ann. Plast. Surg.*, 69: 656-662, 2012.
  - 17- Suthar M., Gupta S., Bukhari S. and Ponemone V.: Treatment of chronic non-healing ulcers using autologous platelet rich plasma: A case series. *J. Biomed Sci.*, Feb. 27; 24 (1): 16, 2017. doi: 10.1186/s12929-017-0324-1.
  - 18- Park J.W., Hwang SR. and Yoon I.S.: Advanced Growth Factor Delivery Systems in Wound Management and Skin Regeneration. *Molecules*, Jul. 27; 22 (8): 1259, 2017. doi: 10.3390/molecules22081259.
  - 19- Hassan M.H., Abd El-Rahman S.S., Amer M.S., Fahmy H.M. and Shamaa A.A.: Effect of lyophilized growth factors (LGF) derived from equine platelets on experimentally induced skin wound healing in mongrel dogs. *International Journal of Veterinary Science*, 10 (2): 75-82, 2021. <https://doi.org/10.47278/journal.ijvs/2020.012>.
  - 20- Dogra S. and Sarangal R.: Summary of recommendations for leg ulcers. *Indian Dermatol Online J.*, Jul. 5 (3): 400-7, 2014. doi: 10.4103/2229-5178.137829.
  - 21- Shi C., Dumville J.C., Cullum N., Connaughton E. and Norman G.: Compression bandages or stockings versus no compression for treating venous leg ulcers. *Cochrane Database Syst. Rev.*, Jul. 26; 7 (7): CD013397, 2021. doi: 10.1002/14651858.CD013397.pub2.
  - 22- Gethin G., Cowman S. and Kolbach D.N.: Debridement for venous leg ulcers. *Cochrane Database Syst Rev.*, Sep. 14; 2015 (9): CD008599, 2015. doi: 10.1002/14651858.CD008599.pub2.
  - 23- Jull A., Waters J. and Arroll B.: Pentoxifylline for treatment of venous leg ulcers: Aa systematic review. *Lancet*, May 4; 359 (9317): 1550-4, 2002. doi: 10.1016/S0140-6736(02)08513-6.
  - 24- Layton A.M., Ibbotson S.H., Davies J.A. and Goodfield M.J.: Randomised trial of oral aspirin for chronic venous leg ulcers. *Lancet*, Jul. 16; 344 (8916): 164-5, 1994.
  - 25- Ubbink D.T., Westerbos S.J., Evans D., Land L. and Vermeulen H.: Topical negative pressure for treating chronic wounds. *Cochrane Database Syst. Rev.*, Jul. 16; (3): CD001898, 2008. doi: 10.1002/14651858.CD001898.pub2.
  - 26- Jones J.E., Nelson E.A. and Al-Hity A.: Skin grafting for venous leg ulcers. *Cochrane Database Syst. Rev.*, Jan. 31; 2013 (1): CD001737, 2013. doi: 10.1002/14651858.CD001737.pub4.
  - 27- Schreml S., Szeimies R.M., Prantl L., Landthaler M. and Babilas P.: Wound healing in the 21<sup>st</sup> century. *J. Am. Acad. Dermatol.*, Nov. 63 (5): 866-81, 2010. doi: 10.1016/j.jaad.2009.10.048.
  - 28- Robson M.C., Steed D.L. and Franz M.G.: Wound healing: Biologic features and approaches to maximize healing trajectories. *Curr. Probl. Surg.*, Feb. 38 (2): 72-140, 2001. doi: 10.1067/msg.2001.111167.
  - 29- Barrientos S., Brem ., Stojadinovic O. and Tomic-Canic M.: Clinical application of growth factors and cytokines in wound healing. *Wound Repair Regen.*, Sep-Oct. ;22 (5): 569-78, 2014. doi: 10.1111/wrr.12205.
  - 30- Ito K., Ito S., Sekine M. and Abe M.: Reconstruction of the soft tissue of a deep diabetic foot wound with artificial dermis and recombinant basic fibroblast growth factor. *Plast. Reconstr. Surg.*, Feb. 115 (2): 567-72, 2005. doi: 10.1097/01.prs.0000149485.60638.30.
  - 31- Tiaka E.K., Papanas N., Manolakis A.C. and Georgiadis G.S.: Epidermal growth factor in the treatment of diabetic foot ulcers: An update. *Perspect Vasc. Surg. Endovasc. Ther.*, Mar. 24 (1): 37-44, 2012. doi: 10.1177/1531003512442093.
  - 32- Fernández-Montequín J.I., Betancourt B.Y., Leyva-Gonzalez G., Mola E.L., Galán-Naranjo K., Ramírez-Navas M., Bermúdez-Rojas S., Rosales F., García-Iglesias E., Berlanga-Acosta J., Silva-Rodríguez R., García-Siverio M. and Martínez L.H.: Intralesional administration of epidermal growth factor-based formulation (Heberprot-P) in chronic diabetic foot ulcer: Treatment up to complete wound closure. *Int. Wound J.*, Feb. 6 (1): 67-72, 2009. doi: 10.1111/j.1742-481X.2008.00561.x.
  - 33- Da Silva L.Q., Montalvão S.A.L., Justo-Junior A.D.S., Cunha Júnior J.L.R., Huber S.C., Oliveira C.C. and Anichino-Bizzacchi J.M.: Platelet-rich plasma lyophilization enables growth factor preservation and functionality when compared with fresh platelet-rich plasma. *Regen Med.*, Oct. 13 (7): 775-784, 2018. doi: 10.2217/rme-2018-0035.
  - 34- Hariprasad R., Suganya T.L., John S.S., Raj P.R., Kuriakose F. and Anoop V.N.: Assessment of Growth Factors with Three Different Platelet Preparations, Namely Platelet-Rich Fibrin, Platelet-Rich Plasma, and Lyophilized Platelet: An In vitro Study. *J. Pharm Bioallied Sci.*, Nov. 13 (Suppl 2): S1696-S1699, 2021. doi: 10.4103/jpbs.jpbs\_358\_21.

- 35- Saputro I.D., Ardan A.M., Yuniarti W.M. and Putra O.N.: The Wound Healing Effect of Allogeneic Freeze-Dried Platelet-Rich Plasma in a Full-Thickness Wound Animal Model. *Journal of Reports in Pharmaceutical Sciences*, 10 (1): p 71-76, Jan-Jun. 2021. | DOI: 10.4103/jrptps.JRPT-PS\_77\_19.
- 36- Yassin G.E., Dawoud M.H.S., Wasfi R., Maher A. and Fayez A.M.: Comparative lyophilized platelet-rich plasma wafer and powder for wound-healing enhancement: Formulation, in vitro and in vivo studies. *Drug Dev. Ind. Pharm.*, Aug. 45 (8): 1379-1387, 2019. doi: 10.1080/03639045.2019.1620269.
- 37- Yeung C.Y., Hsieh P.S., Wei L.G., Hsia L.C., Dai L.G., Fu K.Y. and Dai N.T.: Efficacy of Lyophilised Platelet-Rich Plasma Powder on Healing Rate in Patients with Deep Second Degree Burn Injury: A Prospective Double-Blind Randomized Clinical Trial. *Ann. Plast. Surg.*, Feb. 80 (2S Suppl 1): S66-S69, 2018. doi: 10.1097/SAP.0000000000001328.