

---

**Fungal Contaminants in Commercial Chicken Feeds and Effect of Feeding Aflatoxin B1 Contaminated Ration on Validity of Live Hitchner B1 Vaccine Immunogenicity**

Tarek M. Helal<sup>1\*</sup>, Eman E Abden<sup>2</sup>, Ahmed M Ammar<sup>3</sup>, Alaa A Hussein<sup>2</sup>, Mansour H. Abdel-Baky<sup>1</sup>, Samy M Shafi<sup>1</sup>

<sup>1</sup>Central Laboratory for Evaluation of Veterinary Biologics, Abbasia, Cairo, Egypt,

<sup>2</sup>Department of Bacteriology, Immunology and Mycology, Faculty of Veterinary Medicine, University of Sadat.,

<sup>3</sup>Department of Bacteriology, Immunology and Mycology, Faculty of Veterinary Medicine, Zagazig University

\* Corresponding Author: [Tarek\\_helal@yahoo.com](mailto:Tarek_helal@yahoo.com)

Submitted: 29 March 2019 Accepted: 29 May 2019

---

**ABSTRACT**

This study was designed to spot highlight on the incidence of fungal contaminants and Aflatoxins producing molds in 35 feed samples from 28 broiler and 7 egg-laying chicken flocks in Egyptian. Furthermore, the effects of feeding SPF-white Leghorn chicks on ration contaminated with 50 ppb Aflatoxin (AF) B1 on Newcastle Disease Virus (NDV)-Hemagglutination Inhibition (HI) antibody titers between the third and fourth weeks after vaccination with the live Hitchner B1 strain vaccine was investigated. The histopathological changes in liver, kidney, bursae of Fabricius and spleen was performed at two and five weeks of exposure to AFB1. The most identified moulds were *Aspergillus* (94%), *Penicillium* (37%) and *Fusarium* (17%). The aflatoxigenic *A. flavus* and *A. parasiticus* were isolated from (80%) and (9%) of feed samples, respectively. NDV-HI antibody titers were significantly ( $P < 0.05$ ) decreased in AFB1 exposed group of vaccinated chickens than non-exposed group. The geometric mean titers of 4.9 log<sub>2</sub> and 5.7 log<sub>2</sub> were produced by sera of chickens group fed on normal ration while 3.9 log<sub>2</sub> and 3.8 log<sub>2</sub> were recorded by sera of chickens group fed on AFB1 contaminated ration 21- and 28-days post vaccination, respectively. The results concluded that a significant ( $P < 0.05$ ) increase in mean scores of the histopathological lesions exhibited by livers, kidneys and spleens of AFB1 exposed chickens in comparison with the non-AFB1 exposed chickens while, non-significant ( $P > 0.05$ ) increase was detected for bursae of Fabricius respectively.

**Keywords:** *Aflatoxins, Chicken, Feed, Vaccination, Histopathology.*

---

**INTRODUCTION**

Mycotoxins are recognized as common secondary fungal metabolites contaminant in feedstuffs as produced by mold and constitute a serious worldwide problem with high economic impact (Pappas *et al.* 2016). annually about 25% of world's food stuffs are contaminated with Mycotoxins (CAST, 1989). Aflatoxins are metabolites of *Aspergillus* species which contaminated many of cereal grain foods

(Herzallah, 2013). Poultry feedstuffs are exposed to high concentration of aflatoxin causing huge economic losses (Hoerr, 2013). It causes a significant mortality, growth rates retardation, and decreased resistance to diseases (Gholami-Ahangaran and Zia-Jahromi, 2013; Gholami-Ahangaran *et al.*, 2016). Aflatoxins decrease immune resistance and suppress vaccine-induced immunity in birds (Diekman and Green,1992). Moreover, the main harmful

effects of Mycotoxin include immune depression, hepatotoxicity, nephrotoxicity, oncogenesis and genotoxicity (Shareef, 2010). Contamination of poultry feed affects with Aflatoxin produced influence on various animal health parameters such as alteration in gene expression, disturbance on liver enzymes, kidney damage, mortality and immunosuppression which may predisposing agent for infectious diseases (He *et al.*, 2013). Aflatoxin, particular AFB1 is called "the silent murderer" because its chronic consumption at levels below 20 ppb does not induce evident clinical symptoms; however, it reduces the absorption of food and causes immune suppression (AgroBioTek, 2009). Additionally, (Ursula Hofstetter, 2007) reported that mycotoxins have adverse effect on the immune system via several pathways including; depressed T cells or reduced complement or interferon activity, impaired macrophage function and suppression of antibody titers. Therefore, this study was designed to determine the occurrence of the toxigenic fungi in commercial feed samples collected from 35 commercial chicken flocks (28 broilers and 7 layers) in eight Egyptian Governorates during 2017, and the effect of feeding of chickens on ration contaminated with aflatoxin B1 on validity of immunogenicity test of live ND virus vaccine under the laboratory condition.

## **MATERIALS AND METHHODS**

The experiments and tests were carried out in Central Laboratory for Evaluation of Veterinary Biologics (CLEVB), Department of Poultry Disease, Animal Health Research Institute (AHRI) and Department of Bacteriology, Immunology and Mycology, Faculty of Veterinary Medicine, Sadat University.

### **1. Feed samples**

A total of 35 of feed samples of approximate 500 g each were collected during 2017 from 28 broiler chicken farms and 7-layer chicken farms located in eight Egyptian Governorates, and subjected to mycological examination for isolation and identification of fungal contaminants.

### **2. Specific Pathogen Free chicks (SPF)**

SPF-white Leghorn chicks were purchased from SPF-chickens farm, Koum Oshem, AL-Fayoum Governorate, Egypt, and used for conduction of immunogenicity test of live Hitchiner B1, ND virus vaccine.

### **3. Embryonated chicken eggs:**

Specific Pathogen Free-Embryonated Chicken Eggs (SPF-ECEs) were purchased from SPF-chickens farm, Koum Oshem, AL-Fayoum Governorate, Egypt for preparation of Newcastle Disease (ND) virus antigen, and titration of the virulent NDV strain.

### **4. Commercial chicken ration**

Commercial chicken ration purchased from SPF-chickens farm, Koum Oshem, AL-Fayoum Governorate, Egypt was used to feed the experimental chickens. To ensure validity of this ration, samples of ration were analyzed for aflatoxins, ochratoxins and zeralenone by AHRI. The ration was approved as a valid ration.

### **5. Vaccine**

A commercial batch of live Hitchner B1 vaccine of Newcastle disease virus that submitted to CLEVB were selected to examine its immunogenicity in SPF-chickens fed on normal ration and chickens fed on AFB1-contaminated ration.

### **6. Virus**

LaSota strain obtained from a valid commercial batch of live NDV vaccine was used for preparation of NDV-Hemagglutination antigen.

### **7. Aflatoxin B1**

A vial of 2 ml Aflatoxin B1 (5ng/microliter) in methanol (UN-No: 1230) purchased from Riedel-de Haen chemical company (Wunstorfer Str, Germany) was used to contaminate the chicken ration experimentally at level of 50 part per billion.

### **8. Serum samples**

Serum samples were collected from the experimental chickens and stored at  $-20^{\circ}\text{C}$  until subjected to Hemagglutination inhibition (HI) test for measuring of NDV-HI antibodies.

### **9. Organs specimens**

Specimens of livers, spleens, bursae of Fabricius, and kidneys were collected from

sacrificed (slaughtered) chickens and kept in 10 % formalized phosphate buffered saline until prepared and examined for histopathological lesions.

## 10. Mycological methods

-Isolation of fungi was done by plate dilution method according to (Jansen *et al.* 1960).

-The fungal culture identification was done according to (Conant *et al.* 1954) and (Moss and Mcquown, 1953) and for macro and micro morphological identification of all fungal isolates according to (Barnett and Hunter 1999).

-*Aspergillus*, *Penicillium*, *Hyphomycetes* and *Dematiaceous fungi* were identified and classified according to the key of (Raper and Fennel, 1965 and 1977), (Raper *et al.*, 1949), (Ellis 1971) and (Barron, 1972).

-Detection of toxigenic isolates of *A. flavus* was done by using standard procedures according to Saito, M., Machida, S. (1999)

## 11. Addition of aflatoxin B1 to the commercial ration

The daily requirement of aflatoxin B1-contaminated ration was prepared as follows: Each of 10 micro-liter of aflatoxin B1 solution was diluted in approximately 1000 micro-liter distilled water, and then dispensed on approximately 100-gram ration with thorough mixing, and approximately 900-gram ration was added and mixed well. The aflatoxin content was estimated by the (ROMER method 1975)

## 12. Experimental design

Seven day-old-SPF chicks were randomly divided into two groups (50 chicks /group), housed and maintained in separate cage battery in clean room. Group 1 (G1) was fed on the normal commercial ration until the end of experiment, and the second group (G2) was started to be fed on ration experimentally contaminated with aflatoxin B1 (50 ppb) and up to the end of experiment. At twenty one days old, 30 chickens from both G1 and G2 were vaccinated with live Hitchner B1, NDV vaccine via intra-ocular route of administration with the recommended one dose (not less than  $6 \log_{10} \text{EID}_{50}$  of the virus infectivity titer per bird), and the rest chickens (20 birds) of each group was left as a negative (unvaccinated) controls

G3 and G4.. Again the vaccinated groups were housed and maintained in separate chicken isolators, and unvaccinated group was housed and maintained in separate cage batteries in clean room. At the day of vaccination, and at days 21 and 28 after vaccination, not less than ten individual random blood samples for preparation of serum samples were collected from chickens of each group. Also at the day of vaccination (2 weeks of feeding on normal ration or contaminated ration) and at day 28 after vaccination (6 weeks of feeding on normal ration or contaminated ration), five birds were randomly chosen from each of G1 and G2, and sacrificed by slaughtering and tissue samples of liver, kidney, bursa of fabricius and spleen were collected from each bird and prepared for histopathological examination.

## 13. Virological Tests:

### 13.1. Preparation and titration of NDV, LaSota strain-Haemagglutinating (HA) antigen

Preparation and titration of NDV-HA antigen were conducted following the terristral manual of (OIE, 2016).

### 13.2. Hemagglutination Inhibition (HI) test

HI test was carried out to detect NDV-Hemagglutination Inhibiting (HI) antibodies in sera of vaccinated and unvaccinated chickens following the terristral manual of (OIE, 2016). Geometric mean NDV-HI antibody titer of each vaccinated chickens' group was calculated by the method of (Brugh 1978).

## 14. Histopathological Examination

Tissue samples from livers, kidneys, spleens, and bursae of Fabricius, were collected from sacrificed chickens and fixed in 10 % formalin in PBS; pH 7.2. To evaluate the histopathological changes, paraffin wax tissue sections from each specimen were prepared by microtome, and stained with hematoxylin and eosin following the method of (Bancroft, 1990), and the type and degree of histopathological changes in each sample were scored using four scales between 0 = no lesion (normal), 1 = mild, 2 = moderate, 3 = severe, and 4 = very severe. Lesion score of each type of histopathological change and mean lesions score for each organ of

each chickens group were calculated according to (Randall and Reece 1996).

### 15. Statistical analysis methods

Serological data generated by HI test and histopathological lesions scoring data were subjected to statistical analysis to evaluate the significance of the differences observed among and within the experimental groups. The method for assessment of statistically significant and un-significant was T-student test (Sedecor, 1971). Interference of feeding of chickens on AFB1 contaminated ration on mean NDV-HI antibody titers induced 3 and 4 weeks after vaccination, and distribution for various possible interference and corrective values (likelihood) were statistically calculated simply based on mean antibody titer exhibited by vaccinated chickens fed on normal ration (control group), ( Armitage, et al 2005).

## RESULTS

### Fungal contaminants in feed samples:

Moulds of genus *Aspergillus*, *Penicillium*, *Mucor*, *Fusarium*, *Rhizopus* and yeasts were isolated from 33, 13, 7, 6, 6, and 4 out of 35 feed samples, respectively as demonstrated in Table (1) while *Scopulariopsis*, *Alternaria*, *Cladosporidium*, *Cladospor* and *Absidia* were isolated at lower percent.

Table (2) demonstrates incidence of *Aspergillus* spp in the tested feed samples; *A. flavus*, *A. niger*, *A. fumigates*, *A. parasitticus*, *A. terreus*, and *A. candidus* were isolated from 28, 22, 8, 3, 2 and 1 out of 35 samples, respectively.

Table (3) revealed that 15 out of 28 *Aspergillus flavus* isolates were toxigenic, and 5, 6 and 4 of them were respectively of low, moderate and high mycotoxins productivity, while the 3 isolates of *Aspergillus parasitticus* were of highly toxigenic.

### NDV-HI antibody response in experimental chicken groups:

Table (4) demonstrates the NDV-HI antibody seroconversion by SPF-white Leghorn chickens 21 and 28 days after vaccination with the recommended field dose titer of the live

Hitchner vaccine via eye –drop route of administration, and 35 to 42 days after feeding on either normal ration or ration contaminated with 50 ppb of Aflatoxin B1; geometric mean titers of 4.9 log<sub>2</sub> and 5.7 log<sub>2</sub> were produced by sera of chickens group fed on normal ration 21 days and 28 days after vaccination respectively, and 3.9 log<sub>2</sub> and 3.8 log<sub>2</sub> were recorded by sera of chickens group fed on ration contaminated with 50 ppb of Aflatoxin B1 21 days and 28 days after vaccination respectively, while serum samples of unvaccinated chickens group given 100 % negative HI test (of titer not more than 3 log<sub>2</sub>). Based on mean NDV-HI antibody titers exhibited by 3 weeks and 4 weeks post-vaccination-serum samples of chickens group fed on normal ration and chickens group fed on AFB1 contaminated ration, possible interference and corrective values (likelihood) were statistically calculated. The obtained difference values between the third & fourth week post-vaccination serum samples mean NDV-HI antibody titers (4.9 log<sub>2</sub>& 5.7 log<sub>2</sub>) of chickens group fed on normal ration and mean antibody titers (3.9 log<sub>2</sub>& 3.8 log<sub>2</sub>) of chickens group fed on contaminated ration were 1.0 log<sub>2</sub> and 1.9 log<sub>2</sub>, and the corrective values in percentages for approximately extra 50 ppb of AFB1 in contaminated ration were 25.64 % and 50 %, and thus the possible (likelihood) corrective values for each approximately extra 5 ppb of AFB1 in contaminated ration were 2.56 % and 5.0 % (table 4).

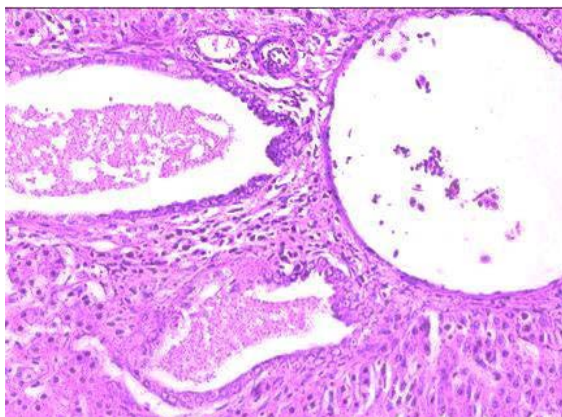
### Histopathological changes of AFB1in experimental chicken groups:

Histopathologically, chickens fed ration containing 50 ppb AFB1 for 5 weeks were showed severe hyperplasia of bile-duct lining epithelium with lumen secretion and moderate degenerative changes of hepatocytes in the liver samples (Figure1 and 2), severe hyper cellularity of G.T and moderate necrosis of renal tubules which replaced with lymphocytes in the kidney samples (Figure 3 and 4), moderate depletion of lymphoid follicles with hyperplasia of the epithelium lining in the bursa of fabricius sample (Figure5), and severe hemorrhages and

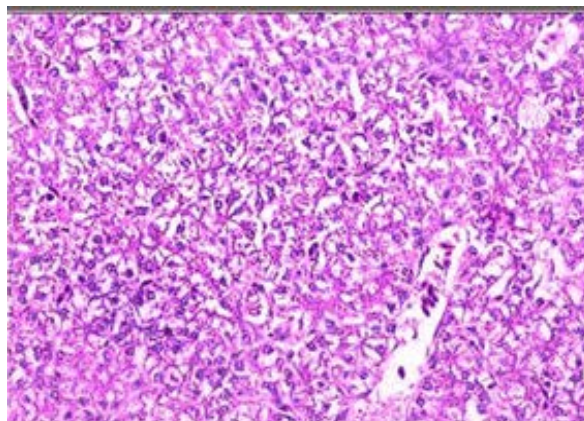
moderate depletion of lymphocytes in the spleen sample (Figure 6).

Mean scores of histopathological lesions in samples of (livers) and (kidneys) of the chickens group fed 2 weeks & 5 weeks on normal ration and chickens group fed 2 weeks & 5 weeks on ration contaminated with Aflatoxin B1 were

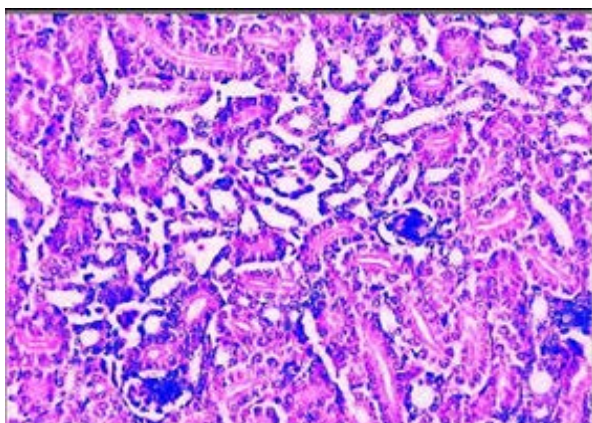
(0.33 & 0.83 and 1.33 & 2.33) and (0.16 & 0.66 and 1.50 & 2.50) respectively (table 5), and mean scores of histopathological lesions in samples of (bursae of fabricius) and (spleens) of the chickens group fed 2 weeks & 5 weeks on normal ration and chickens group fed 2 weeks & 5 weeks on ration contaminated with Aflatoxin B1 were (0.25 & 1.25 and 1.25 & 1.75) and (0.25 & 0.50 and 1.25 & 2.50) respectively (table 6).



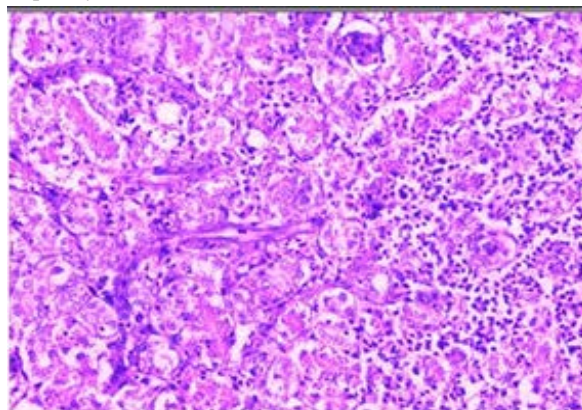
**Fig. (1)** Liver of chicken showing hyperplasia of bile ductules with secretion in lumen. (H&E X400)



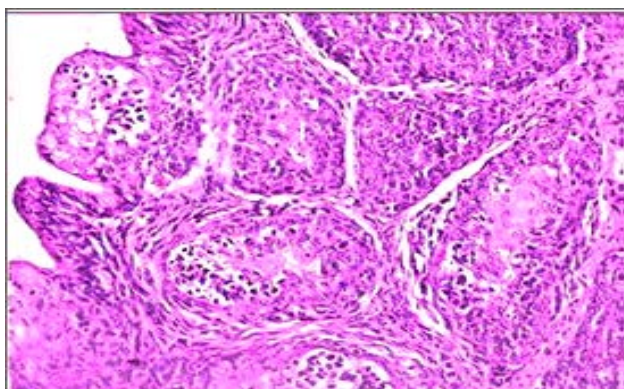
**Fig. (2)** Liver of chicken showing degeneration of hepatocytes. (H&E X200)



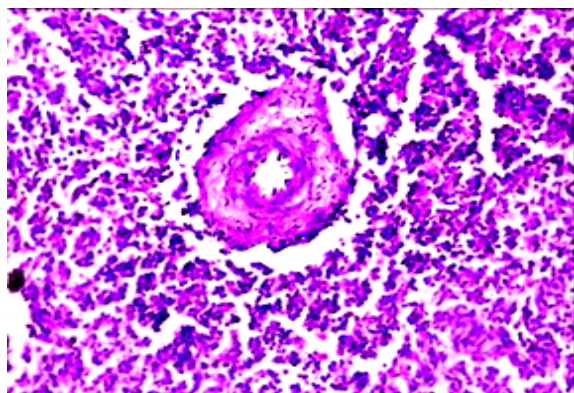
**Fig. (3)** Kidney of chicken showing intertubular edema, degenerative changes of renal tubules and hypercellularity of G.T. (H&E X100)



**Fig. (4)** Kidney of chicken showing necrosis of renal tubules which replaced with inflammatory cells mainly lymphocyte and intertubular C.T. proliferation. (H&E X400)



**Fig. (5)** Bursa of Fabricius of chicken showing hyperplasia of epithelia and depletion of lymphoid follicles. (H&E X400)



**Fig. (6)** Spleen of chicken showing depletion of lymphocytes, and haemorrhages and thickening of splenic

**Table (1)** Incidence of fungal contaminants in 35 feed samples collected during 2017 from commercial broiler and egg-laying chicken flocks located in 8 Egyptian Governorates.

Ration groups	No of Samples	<i>Aspergillus</i> Spp	<i>Fusarium</i> Spp.	<i>Penicillium</i> Spp.	<i>Mucor</i> Spp.	<i>Rhizopus</i> Spp.	<i>Cladosporium</i> Spp	<i>Alternaria</i> Spp	<i>Absidia</i> Spp	Yeast	<i>Scopulariopsis</i> Spp.	<i>Cladosporium</i> Spp
Broiler Ration	28	26	4	10	7	6	0	2	1	3	1	1
Laying Hen Ration	7	7	2	3	0	0	1	0	0	1	1	0
Total numbers	35	33	6	13	7	6	1	2	1	4	2	1
Percentages (%)		94	17	37	20	17	3	6	3	11	6	3

**Table (2)** Prevalence of *Aspergillus* spp in feed samples.

Ration groups	No of feed samples	<i>A. flavus</i>	<i>A. fumigates</i>	<i>A. niger</i>	<i>A. candidus</i>	<i>A. terreus</i>	<i>A. parasiticus</i>
Broiler Ration	28	22	6	18	1	2	3
Laying Hen Ration	7	6	2	4	0	0	0
Total numbers	35	28	8	22	1	2	3
Percentages (%)		80%	23%	63%	3%	6%	9%

**Table (3)** toxigenic strains of *Aspergillus flavus* and *Aspergillus parasiticus* isolated from culturing of 35 feed samples

Ration groups	<i>A. flavus</i>			<i>A. parasiticus</i>		
	+	++	+++	+	++	+++
Broiler ration	5	3	2	0	0	3
Laying hen ration	1	3	2	0	0	0
Total numbers	5	6	4	0	0	3

+ = Low toxigenic strain, ++ = Moderate toxigenic strain, and +++ = High toxigenic strain

**Table (4)** Effects of Aflatoxin B1 on NDV-HI antibody titers in sera of SPF white Leghorn chickens vaccinated with live Hitchner B1 vaccine

time of sampling	GMT of NDV-HI antibodies in sera of vaccinated chickens fed on normal ration	GMT of NDV-HI antibodies in sera of vaccinated chickens fed on ration contaminated with 50 ppb of AFB1
3 WPV	4.9 log <sub>2</sub>	3.9 log <sub>2</sub>
4 WPV	5.7 log <sub>2</sub>	3.8 log <sub>2</sub>

GMT = Geometric Mean Titer

WPV= Week Post-Vaccination

NB: Serum samples of unvaccinated chickens were exhibited 100 % negative NDV-HI antibody (of titer not more than 3 log<sub>2</sub>) along the times of sampling.

- difference values (d) = 1.0 log<sub>2</sub> and 1.9 log<sub>2</sub> {the third- & fourth-week post-vaccination serum samples mean NDV-HI antibody titers (4.9 log<sub>2</sub> & 5.7 log<sub>2</sub>) of chickens group fed on normal ration minus mean antibody titers of chickens group fed on contaminated ration (3.9 log<sub>2</sub> & 3.8 log<sub>2</sub>).
- Corrective values in percentages (c) for approximately extra 50 ppb of AFB1 in contaminated ration = 1.0 x 100/ 3.9 = 25.64 % and 1.9 x 100/ 3.8 = 50 %
- Possible (likelihood) corrective values in percentages (c) for each approximately extra 5 ppb of AFB1 in contaminated ration = 25.64/10 = 2.56 % and 50/ 10 = 5.0 %.

**Table (5)** Scores of histopathological lesions in livers and kidneys of chickens fed on rations experimentally contaminated with 50 ppb of aflatoxin B1 in comparison with chickens fed on normal ration.

Chicken groups	Liver							Kidney						
	Congestion of blood vessels and sinusoid	Thrombus formation	Perivascular infiltration of inflammatory cells	Hyperplasia of bile with lumen secretion	Focal necrosis	Degenerative changes of hepatocytes	Mean	Congestion of renal blood vessels	Focal aggregation of lymphocytes	Interlobular and perivascular hemorrhage	Degenerative changes of renal tubules	Hyper cellularity of G.T	Thickening of ureter	Mean
Chickens fed 2 weeks on normal ration	1	0	0	0	0	1	0.33	1	0	0	0	0	0	0.16
Chickens fed 5 weeks on normal ration	1	0	1	0	2	1	0.83	1	0	0	1	1	1	0.66
Chickens fed 2 weeks on ration contaminated with AFB1	1	0	1	2	2	2	1.33	1	1	2	2	2	1	1.50
Chickens fed 5 weeks on ration contaminated with AFB1	2	2	2	2	3	3	2.33	2	2	3	3	3	2	2.50

Scale of Histopathological lesion scores; 0 = normal, 1 = mild, 2 = moderate, 3 = severe and 4 = very severe

**Table (6)** Scores of histopathological lesions in Bursa of Fabricius and Splens of chickens fed on rations experimentally contaminated with 50 ppb of aflatoxin B1 in comparison with chickens fed on normal ration

Chicken groups	Bursa of fabricius					Spleen				
	Hyperplasia of epithal lining	Depletion of lymphocytes	Atrophy of lymphoid follicles	Hyperplasia of interfollicular C.T	Mean	Depletion of lymphocytes	Thickening of splenic artery	Haemorrhage	Thickening of splenic capsule	Mean
1.Chickens fed 2 weeks on normal ration	0	1	20	0	<b>0.25</b>	1	0	0	0	<b>0.25</b>
2.Chickens fed 5 weeks on normal ration	1	2	1	2	<b>1.50</b>	1	0	0	1	<b>0.50</b>
3.Chickens fed 2 weeks on ration contaminated with AFB1	1	2	1	1	<b>1.25</b>	1	2	1	1	<b>1.25</b>
4.Chickens fed 5 weeks on ration contaminated with AFB1	2	2	2	1	<b>1.75</b>	3	2	3	2	<b>2.50</b>

Scale of Histopathologicallesion scores; 0 = normal, 1 = mild, 2 = moderate, 3 = severe and 4 = very severe

## DISCUSSIONS

As a toxigenic fungi are widely spread naturally contaminating the cereal grains of chicken rations (maze and soya bean), a survey for the known toxigenic fungi was undertaken on a 35

feed samples randomly collected during 2017 from 28 commercial broiler and 7 laying chicken farms which located in 8 Egyptian governorates.

The obtained results revealed that (1), *Aspergillus* spp, *Penicillium* spp, and *Fusarium*

spp were approximately isolated from 94 %, 37 %, and 17 % of feed samples respectively, while approximately 3 % to 20 % of the feed samples were contaminated with *Mucor* spp, *Rhizopus* spp, *Scopulariopsis* spp, *Alternaria* spp, *Cladosporidium* spp, *Cladospor* spp and *Absidia* spp, (2) *Aspergillus flavus* and *Aspergillus parasiticus* were approximately isolated from 80 % and 9 % of feed samples respectively, while *Aspergillus niger*, *Aspergillus fumigatus*, *Aspergillus terreus*, and *Aspergillus candidus* were approximately isolated from 63 %, 23 %, 6 %, and 3 % of feed samples respectively, and (3) 15 toxigenic strains were identified out of 28 isolates of *Aspergillus flavus*; 5, 6 and 4 of them were respectively of low, moderate and high toxins productivity, and the 3 isolates of *Aspergillus parasiticus* were of highly toxigenic one.

Survey on incidence of mycotoxins producing fungal contamination in samples of corn and sunflower revealed that *Aspergillus*, *Penicillium* and *Fusarium* species were approximately represented 45 %, 42 % and 13 % of the total isolates respectively, and 64 % of *Aspergillus* spp isolates were toxigenic (Abdel-Malik *et al.*, 1993).

Overall incidence of Aflatoxin (AF) B1 in 410 poultry feed samples was approximately 44 % with average and maximum levels of 24 µg/Kg and 78 µg/Kg, (Anjum *et al.*, 2012). The tolerant levels of aflatoxin in animal feeds for many countries were in the range 5 – 50 µg/kg; (Hans and Van, 1999). Aflatoxin contamination in a poultry feed and feed ingredient was approximately occurred with quantities range between 10 ppb and > 100 ppb, (Donna M. *et al.*, 2017).

Because AFB1 is the most prevalent and potent mycotoxin that primarily produced by *Aspergillus flavus* as concluded from the present survey results, experiment on validity of immunogenicity test of live NDV vaccine of strain Hitchner B1 in SPF-white Leghorn chickens fed on ration contaminated with 50 ppb of AFB1 was conducted in comparison with those chickens fed on normal ration that containing less than 20 ppb aflatoxins and/or not

more than 10 ppb AFB1 according to the (Egyptian standards, 1990). The main objective of this experiment was to determine the impact of feeding of chickens on ration contaminated with 50 ppb of AFB1 for 2 weeks before vaccination and 3-4 weeks after vaccination with live Hitchner B1, NDV on validity of immunogenicity test.

The present experiment results of NDV-HI antibody seroconversion by SPF-white Leghorn chickens 21 and 28 days after vaccination with the recommended field dose titer of the live Hitchner B1 vaccine via eye-drop route, and fed on ration experimentally contaminated with 50 ppb of Aflatoxin B1 for 35 to 42 days in comparison with chickens those vaccinated with Hitchner B1 vaccine and fed on normal ration clearly addressed the immunosuppressive effect of AFB1; NDV-HI antibody geometric mean titers of 4.9 log<sub>2</sub> and 5.7 log<sub>2</sub> were exhibited by sera of chickens group fed on normal ration 21 days and 28 days after vaccination respectively, and 3.9 log<sub>2</sub> and 3.8 log<sub>2</sub> were recorded by sera of chickens group fed on ration contaminated with 50 ppb of Aflatoxin B1 21 and 28 days after vaccination respectively, while serum samples of unvaccinated chickens group given 100 % negative HI test (not more than 3 log<sub>2</sub>). There was a significant difference between NDV-HI antibody titers produced by sera of vaccinated chickens fed on AFB1 contaminated ration and vaccinated chickens those fed on normal ration (P<0.05). The vaccine is not immunogenic unless the vaccinated chickens have developed serum NDV-HI antibody titers between 4 log<sub>2</sub> and 6 log<sub>2</sub> (OIE Manual; 2016) or mean titer of at least 4 log<sub>2</sub>, (Egyptian standards; 2017), and the mean HI titer in unvaccinated control chickens sera is not more than 2.

Based on mean NDV-HI antibody titers exhibited by third and fourth weeks post-vaccination-serum samples of chickens group fed on normal ration and chickens group fed on AFB1 contaminated ration, the obtained interference, and corrective values in percentages for approximately extra 50 ppb of AFB1 in contaminated ration were 25.64 % and 50 %, and thus the simple corrective values of



the likelihoods (almost certainly how likely something is to happen) of the various possible interference for each approximately extra 5 ppb of AFB1 in contaminated ration were 2.56 % and 5.0 %. AFB1 dose (50 and 100 ppb)-dependent reduction in serum anti-NDV antibody titers of chickens was recorded after vaccination against ND.

Many scientific papers were successful to ascertain clinical toxicity and weak sero-response to the vaccination or vaccination failure against NDV, ILT, IBD, IB, FC and other vaccines in chickens and turkeys fed on ration contaminated with 200 ppb (Azzam and Gabal 1998), and (Ebrahimi and Shahsavandi (2008). Also, determination of serum titers of antibodies against live NDV vaccine is a method which recommended to be used to evaluate immunomodulating effects of living vaccines of IBDV and CAV in vivo, European Pharmacopoeia, (2010).

Significant decrease of antibody titers was recorded in young layer chicks vaccinated with commercial live vaccines against ND, IB and IBD following exposure to 200 ppb of aflatoxin in the feed, (Gabal and Azzam 1998).

The present experiment results of histopathological changes in the vitality related organs (liver and kidney) and immunity related organs (bursa of Fabricius and spleen) of chickens fed 2 weeks and 5 weeks on ration contaminated with Aflatoxin B1 in comparison with chickens those fed on uncontaminated ration showed a significant increase of mean histopathological lesion scores in samples of livers, kidneys and spleens 2 and 5 weeks after feeding on AFB1 contaminated ration ( $P < 0.05$ ). Mean scores of histopathological lesions in samples of (livers), (kidneys) and (spleens) of the chickens group fed 2 weeks & 5 weeks on normal ration and chickens group fed 2 weeks & 5 weeks on ration contaminated with Aflatoxin B1 were (0.33 & 0.83 and 1.33 & 2.33) and (0.16 & 0.66 and 1.50 & 2.50) and (0.25 & 0.50 and 1.25 & 2.50) respectively, and mean scores of histopathological lesions in samples of bursa of Fabricius of the chickens group fed 2 weeks & 5 weeks on uncontaminated ration and chickens

group fed 2 weeks & 5 weeks on ration contaminated with Aflatoxin B1 were (0.25 & 1.25) and (1.25 & 1.75) respectively.

-Of course, the chickens fed on contaminated ration were exhibited a visible body weights lower than the chickens group those fed on normal ration by the fifth weeks old (un-tabulated data). (Ghosh *et al.*, 1990).

## CONCLUSION:

Different toxigenic and non-toxigenic moulds were detected at various incidence percentages in majority of the tested commercial chicken feeds. Moreover, feeding of chickens on ration contaminated with approximately 50 ppb of AFB1 for 5 to 6 weeks adversely affect the validity of immunogenicity test of live Hitchner B1 vaccine through the significant reduction of the sero-response with significant induction of histopathological changes in livers, kidneys and spleen.

## REFERENCES

- Abdel-Mallek, A. Y., S. S. M. EL-Maraghy and H. A. Hasan. (1993). Mycotoxin producing potential of some *Aspergillus*, *penicillium* and *fusarium* isolates found on corn grains and sunflower seeds in Egypt. *Journal of Islamic Academy of Sciences*, 6: 189-192.
- Agro-Bio-Tek (2009). Las Micotoxinas en la Agroindustria – Aflatoxinas. Agro-Bio-Tek. Dominicana. <http://www.agrobiotek.com>
- Anjum M. A., Khan S. H., Sahota A. W. and Sardar R. (2012) Assessment of Aflatoxin B1 in commercial poultry feed and feed ingredients, *The Journal of Animal & Plant Sciences*, 22(2); Page: 268-272
- Armitage. P, Berry .G and Matthews .J.N.S (2005). *Statistical methods in medical research*, fourth edition, published by a blackwell science Ltd.
- Azzam, A.H and M.A. Gabal. (1998). Aflatoxin and immunity in layer hens. *Avian Pathology*, 27: 570-577.
- Bancroft JD, Stevens A. (1990). *Theory and practice of histological techniques*, 3rd

- edition. Edinburgh; New York: Churchill Livingstone.
- Barnett HL and Hunter BB. (1999). *Illustrated Genera of Imperfect Fungi*. The Amer. Phytopathol. Soc. St. Paul,
- Barron, G.(1972). *The genera of Hyphomycetes from soil*. Robert ekrieger Puf. Comp.
- Brugh, MA. Jr. (1978): A simple method for recording and analyzing serological data. *Avian Dis.*22: 362- 365.
- CAST.(Council for Agricultural Science and Technology).(1989)."Mycotoxins: Economics and Health Risks". Task Force Report No. 116. Ames, IA
- Conant, N. F.; Martin, D. S.; Smith, D. T.; Baker, R. D. and Callaway, J. L. (1954) *Manual of clinical mycology*, philadelphia, W. B. Saunders Company.
- Diekman, M.A., and M.L.Green (1992). Mycotoxins and reproduction in domestic livestock. *J Anim Sci.* May; 70(5):1615-27.
- Donna M. Morrison, David R. Ledoux , Lambert F. B. Chester and Coretta A. N. Samuels (2017) A Limited Survey of Aflatoxins in Poultry Feed and Feed Ingredients in Guyana. *Vet. Sci.*, 4, 60; doi:10.3390/vetsci4040060 www.mdpi.com/journal/vetsci
- Ebrahimi, M.M. and Shahsavandi S. (2008) Evaluation of antibody levels during simultaneous aflatoxicosis and vaccination against infectious laryngotracheitis in pullets. *Biologicals.* 36 (5):327-9.
- Egyptian standard regulations for evaluation of veterinary biologics (2017).Testing for immunogenicity of live Newcastle disease vaccines. Third edition, pages 118-120.
- Egyptian standards (1990). Maximum limits for mycotoxin in food. Egyptian Organization for Standardization and Quality Control, part (1) aflatoxin. ES 1875 1990.
- Ellis, M. B. (1971). *Dermatiaceous Hyphomycetes*. Commonwealth Mycological Institute, Kew, Survey, England.
- European Pharmacopoeia, (2010). The 7th edition of the European Pharmacopoeia was consists of a two-volume main edition. Strasbourg : Council Of Europe : European Directorate for the Quality of Medicines and Healthcare,
- Gabal MA and AH Azzam. (1998). Interaction of Aflatoxin in the feed and immunization against selected infectious diseases in poultry. II. Effect on One-day-old Layer Chicks Simultaneously Vaccinated against Newcastle Disease, Infectious Bronchitis and infectious Bursal Disease. *Avian Pathol.*; 27(3): 290–295.
- Gholami-Ahangaran M, Rangaz N, Azizi S.(2016) Evaluation turmeric (*Curcuma longa*) effect on biochemical and pathological parameters of liver and kidney in chicken aflatoxicosis. *Pharm Biol* ; 54(5): 780–7
- Gholami-Ahangaran M, Zia-Jahromi N. (2013) Nanosilver effects on growth parameters in experimental aflatoxicosis in broiler chickens. *Toxicol Ind Health*; 21: 121–5. Th ed. Ames: Wiley-Blackwell, 2013: 1271–87.
- Ghosh, J.D., J. Singh, S.K. Mahipal and R.C. Kulshreshtha, (1990). Effect of aflatoxin-contaminated feeds on egg production and broiler growth. *Indian J. Anim. Sci.*, 60:
- Hans P and Van E (1999). *Worldwide Regulations for Mycotoxins*. Third Joint FAO/WHO/UNEP International Conference on Mycotoxins, Tunis, Tunisia, 3-6 March, 1999, Page 7.
- He, B. J., K.Y. Zhang, D.W. Chen, X.M. Ding, G.D. Feng, X. AO. (2013). Effects of vitamin E and selenium yeast on growth performance and immune function in ducks fed maize naturally contaminated with aflatoxin. *livest. Sci.*, 152, pp. 200-207.
- Herzallah SM (2013). Aflatoxin B1 residues in eggs and flesh of laying hens fed aflatoxin B1 contaminated diet. *Am J Agric Biol Sci*; 8: 156–61.

- Hoerr FJ. Mycotoxins. In: Swayne DE, Glisson JR, McDougald LR, (2013) eds. Disease of poultry. 13th ed. Ames: Wiley-Blackwell: 1271–87.
- Jansen, L.: Curi, Bond, and Fribourge, H. (1960) Methods for studying soil micoflora-plant disease relationship. Minneapolis, Burgess Publishing Co.
- Moss, E.S. and Mcquown, A. L. (1953).Atlas of medical mycology 3rd Ed., Williams and Wilking Co., Baltimore.
- OIE terrestrial Manual (2016). Chapter.2.3.14. Newcastle Disease (infection with Newcastle disease virus)
- Pappas, A. C., E. Tsiplakou, D.I. Tsitsigiannis, M. Georgiadou, M.K. Iliadi, K. Sotirakoglou and G. Zervas (2016). The role of bentonite binders in single or concomitant mycotoxin contamination of chicken diets.Br Poult Sci. <http://dx.doi.org/10.1080/00071668.2016.1187712>.
- Randall CJ, Reece RR (1996) A Colour Atlas of Avian Histopathology Mosby-Wolfe, London.
- Raper, K. B, Thom, C. and Fennel. D. I. (1949) A manual of the penicillia The Williams and Wilkins Co.Reddy, D.V, R., Thirumala-Devi, K., Reddy, S.V., Waliyar, F., Mayo, M.A. Rama Devi, K., Ortiz, R. &Lenne, I.M (2002);
- Raper, K. B. and Fennel, D. T. (1977).The genus *Aspergillus* Robert E. Krieger Publishing Co., Inc. Box 542, Huntington, N. Y.
- Raper, K. B. and Fennel. D. T. (1965). The genus *Aspergillus* The Williams and Wilkins Co., Baltimore
- ROMER, R. T. (1975): Qualitaitve/quantitiatve analysis for detection and estimation of aflatoxin (Romer mini column method). J. Assoc. Off. Anal. Chem. 58, 500-506.
- Saito, M., Machida, S. (1999), A rapid identification method for aflatoxin producing strains of *A. flavus* and *A. parasiticus* by ammonia vapor. Myco science, 40(2): 205-208.
- Sendecor, G.W. (1971): Statistical methods, fourth Edition. Iowa State Univ. Pr
- Shareef A.M. (2010). Molds and mycotoxins in poultry feeds from frams of potential mycotoxycosis; Iraqi J. Vet. Sciences. 24:17-25.
- Ursula Hofstetter, 2007. The negative effects of various mycotoxins on the immune system of poultry. BIOMIN Newsletter, 5-46.