

Structure and Function of Periosteum with Special Reference to its Clinical Application

Review
Article

Hany K. K. Mostafa

Faculty of Medicine, Ain Shams University – Fakeeh College of Medical sciences FCMS.

ABSTRACT

This review summarizes the structure of periosteum in relation to clinical applications.. It shows the structure of periosteum as outer fibrous and inner osteogenic layers. Bone lining cells were used recently to describe inactive osteoblasts. The review also discussed the role of periostin protein, its higher concentration in periosteum than bone. Periostin is high early in fracture while decrease after stoppage of cellular differentiation so figure out the stem cell as the main source of periostin. Also in this review the structure of bone niche was described as formed of cellular part and non cellular part. Stem cell niche is very important to regulate stem cell division and direct differentiation to bone growth or bone healing and regeneration of damaged bone. This review also reported the blood supply of periosteum. Blood supply from periosteum is divided into four vascular systems. It sheds a light on morphology of osteoblasts and mechanism of mineralization. osteoblast has specific receptors in the cell membrane and contains a magic structure called matrix vesicle which plays the key role in bone mineralization. Moreover, the review discusses the role of periosteum in bone remodeling. Periosteal bone formation is described in different ages: fetal, childhood and adulthood. It also reported on osteoblastic activation of osteoclasts and its role in bone structure. The review explained the new term of bone remodeling unit which is formed of cutting cone and closing cone so confirm the importance of exercise for healthy bone formation. Factors affecting bone formation by periosteum were also categorized to hormonal, mechanical, environmental genetic and diseases. Healing of bone fracture is the most important one clinical application, but the review also contains many clinical applications related to the structure and function of periosteum.

Received: 28 November 2018, **Accepted:** 08 December 2018

Key Words: Ossification, osteoblast and remodeling, periosteum.

Corresponding Author: Hany K. KMostafa, MD, Faculty of Medicine, Ain Shams University – Fakeeh College of Medical sciences FCMS., **Tel.:** +20 27869972, **E-mail:** hanykamal66@yahoo.com

ISSN: 1110-0559, Vol. 42, No. 1

PERIOSTEUM

Introduction

Bones are one of specialized connective tissue that is formed of cells, collagen fibers and ground substance. It is enclosed by a periosteum except in joints.^[1]

General appearance:

The periosteum is formed of tan-white layer at the surface of al bones. The periosteum is firmly adherent to the bone in adults. In children, the periosteum is loosely close to the underlying bone. The periosteum is thicker than adult and mainly cellular in childhood. In contrast, it is thinner and fibrous in adults.^[2]

Microscopic structure:

The periosteum is formed of two layers: Outer fibrous layer and inner osteogenic layer. The inner layer presents adjacent to bone and contains smaller blood vessels and proliferative cells of bone (Fig.1). It is sometimes called cambial layer. Cambium means exchange and it is responsible for nutrition, growth and repair of bone in width.^[3]

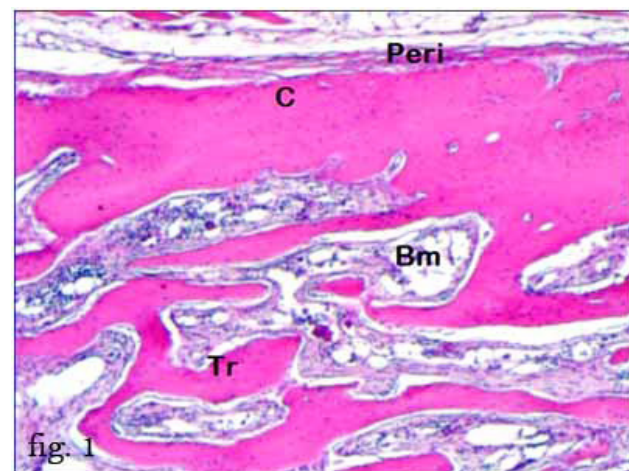

Fig. 1: shows the periosteum (peri) covering the outer cortical bone (C). Bone marrow spaces (BM) are present in between the trabeculae (Tr) of cancellous bone. H&E x2501

Inner osteogenic layer:

It is the inner most layer of the periosteum. It consists mainly of osteoblasts with some osteogenic progenitor cells arranged in the layer adjacent to the bone matrix core.

During intense synthesis of extracellular matrix, osteoblasts are rounded or cuboidal, with basophilic cytoplasm. While with the decrease of osteogenesis, osteoblasts become spindle in shape and their ribosomal content becomes fewer. There is another type of cells that are osteogenic progenitor cells which differentiate into osteoblasts. Osteogenic tissue contains few collagen and elastic fibers.^[4&5]

Bone-Lining Cells

In sites where remodeling is not occurring, the bone surface is covered by a layer of flat cells with attenuated cytoplasm and a few organelles around the nucleus. These cells are simply called bone lining cells. Bone-lining cells on external bone surfaces are called periosteal cells, and those lining internal bone surfaces are usually called endosteal cells. Gap junctions are present between the bone-lining cell processes. Bone-lining cells represent a population of cells that are derived from osteogenic progenitor cells (Figs. 2&3).^[6]

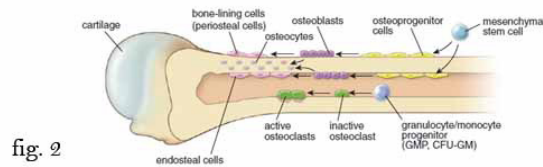


Fig. 2: bone lining cells on outer and inner surface of bone are called periosteal cells and endosteal cells.^[6]

Osteoblasts have many processes, these processes of bone-lining cells extend into the canalicular channels of the adjacent bone and communicate by means of gap junctions with osteocytic processes. As a matter of structure related to function, the main roles of these cells are: the maintenance and nutritional support of the osteocytes embedded in the underlying bone matrix and regulate the movement of calcium and phosphate into and out of the bone.^[6&7]

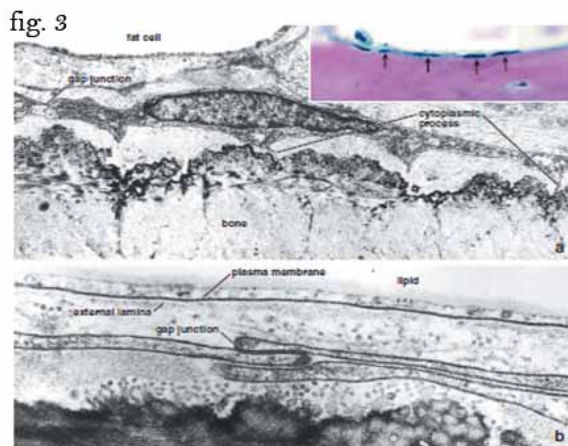


Fig. 3: showing the gap junctions between the cytoplasmic processes of bone lining cells.^[6]

Outer fibrous layer:

It is formed of fibroblasts and collagen fibers together

with ground substance (Figs. 2&3). It also has many blood capillaries surrounded by pericytes. Pericytes also act as stem cells for bone. Pericytes are slightly branched cells and enclose the capillary endothelial cells, with the ability to differentiate into numerous cell types, including osteoblasts. Pericytes play important role in periosteal bone formation due to their greater abundance in periosteum than in endosteal bone formation. Sympathetic nervous fibers are present in this layer.^[6]

In general, the collagen fibers of the periosteum are arranged parallel to the surface of the bone in the form of a capsule. Bundles of periosteal collagen fibers, called perforating fibers, penetrate the bone matrix, binding the periosteum to bone matrix. These fibers are called Sharpey's fibers. They represent the sites where ligaments and tendons attach to the bone. The direction of collagen fibers is determined by tension forces (Fig. 4). These fibers penetrate entire cortex at the sites exposed to high amount of tension forces.^[8&9]

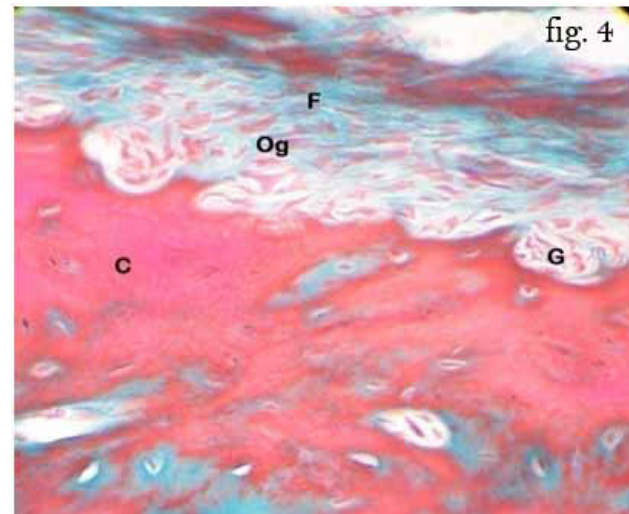


Fig.4: shows the periosteum from of outer fibrous layer (F) and inner osteogenic layer (Og) containing osteoprogenitor cells and osteoblasts. There are multiple subperiosteal grooves (G) lined with osteoprogenitor cells within the bone cortex (C). Masson trichrome X250.^[1]

Periostin protein:

Periostin protein is present in the higher amount in periosteum than in the bone is periostin.^[10] (Wu Z, 2017) It is synthesized by the stem cells which will differentiate to osteoblasts. All preosteoblasts secrete periostin in the extracellular matrix. The level of periostin is higher 4-folds during the early days after any fracture.^[11] The periostin protein level decreases with the stoppage of differentiation of preosteoblasts and formation of osteoblasts. In different words periostin is secreted by differentiated cells and once the osteoblasts fully formed its level in blood decrease.^[12]

Stem cell niche of bone:

Stem cells of periosteum are numerous. They include stromal cells, pericytes and osteogenic progenitor cells in periosteum.

The periosteum has highly regenerative capacity. These stem cells require stem cell niche to control their activity called stem cell niche of bone. It is formed of cellular part: stem cells, blood capillaries, fibroblast, and nerve fibers supplying periosteum. Non cellular part is formed of collagen fibers, glycoprotein molecules. This niche acts as microenvironment to provide anti-differentiation signals to keep the stem cells in undifferentiated state. When the regeneration and bone formation is required the stem cells leave their niche, starting division and differentiation. An interaction between stem cells and niche microenvironment occurs through cell junctions and cellular mediators.^[13]

Blood supply of periosteum

The arterial supply of any long bones starts from periosteum. Four vascular systems are detected.

1. Intrinsic periosteal system: the capillaries of periosteum within zone II.
2. Periosteocortical anastomoses: in relation to underlying cortical bone.
3. Periosteomuscular system in relation to muscles attached.
4. Periosteofacial system in relation to tendons, ligaments and fibrocartilage attached to bone. So this system is variable from bone to bone.^[14]

Osteoblast structure and function:

Osteoblasts have three main functions in bone. vital to bone tissue and are the cells responsible for the production, transport, and arrangement of most of the components of the organic matrix (osteoid),

They produce transport and arrange the matrix of bone (osteoid).

They start and control mineralization process.

They secrete certain factors to control themselves and the neighboring osteoclasts.

On histological bases osteoblasts secrete alkaline phosphatase, osteopontin, and osteocalcin. They also have membrane protein called receptor activator of nuclear kappa factor ligand (RANKL) (essential for osteoclastic activity), they have very important membrane receptors for insulin like growth factor and parathyroid hormone (PTH). They have no receptors for growth hormone. They have cytoplasmic receptor for active vitamin D. The functioning osteoblasts are 40µm size and have basophilic cytoplasm that is in contact with the bone.

Multiple cytoplasmic processes extend from the cells into and through the bone matrix, contacting adjacent osteoblasts and osteocytes via gap junctions.

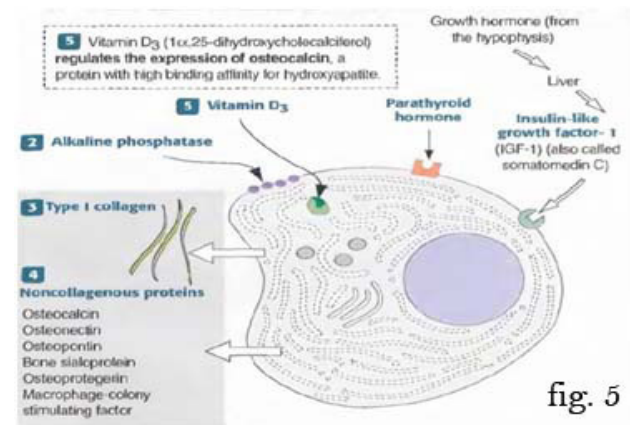


fig. 5

Fig. 5: shows the site, structure and function of osteoblasts.^[7]

The nucleus is eccentric and located toward the outer fibrous layer or zone II and often has a prominent nucleolus. It has a prominent perinuclear well-developed Golgi apparatus. The cells flatten and elongate as their synthetic activity diminishes and remain lining the resting bone surfaces (Fig. 5).^[7]

The role of matrix vesicles

Mineralization is defined as deposition of minerals mainly calcium and phosphate in certain tissue most commonly bone but other tissues could be also mineralized. The process is regulated by osteoblasts in bone.

- Osteoblasts secrete osteocalcin a protein with high binding of extracellular Ca^{+2} so it raises the concentration of this ion.
- The osteoblasts are stimulated by the high Ca^{+2} concentration to secrete alkaline phosphatase (ALP), which increases the local concentration of PO_4 ions. The high PO_4 concentration stimulates more Ca^{+2} concentration to rise.
- The high Ca^{+2} and PO_4 concentration stimulates the osteoblasts to release small (100nm) matrix vesicles into the bony matrix by exocytosis. The matrix vesicles have ALP and pyrophosphatase on their membrane as transmembrane. Both enzymes cleave PO_4 ions from other molecules of the matrix.
- The matrix vesicles that accumulate Ca^{+2} and cleave PO_4 ions cause the local isoelectric point to increase, which results in crystallization of $CaPO_4$ in the surrounding matrix vesicles.
- The $CaPO_4$ crystals initiate matrix mineralization by the formation and deposition of hydroxyapatite crystals $[Ca_{10}(PO_4)_6(OH)_2]$ in the matrix surrounding the osteoblasts.^[6&8]

Functions of periosteum:

Periosteal bone formation during endochondral bone formation in fetal life

Usually the bone is formed over another tissue. During fetal life the bone formed over either cartilage or mesenchyme. In the first case, that is called endochondral growth, bone is formed over model of cartilage. The cartilage is formed from mesenchyme and grows in width by appositional growth from perichondrium and in length by interstitial growth through chondrocytes. But at certain point the perichondrium stop forming chondrocytes instead it forms osteoblasts and osteocytes and so it is called now periosteum. The tissue formed under the periosteum is called bone collar. Meanwhile the chondrocytes of cartilage are enlarged and lead to thinning out of cartilage matrix. Chondrocytes start to calcify the matrix of cartilage by alkaline phosphatase enzyme. The periosteum adds more bony tissue to replace the calcified matrix of cartilage. Periosteum form bone as the previously mentioned through osteoblast secretion of bony matrix then osteoblast mineralize the tissue by matrix vesicle. The bone formed at this stage of life is characterized by being of high cellular content low matrix and mineral content better to call it immature bone Figure 6 (Fig. 6)^[6&15]

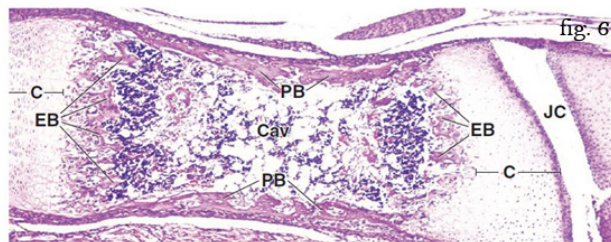


Fig. 6: it shows section of fetal bone with periosteum and periosteal bone (PB) surrounding cartilage (C) and medullary cavity (Cav). Endochondral bone spicules (EB) are formed at both ends of cartilage model.^[6]

Periosteal bone formation during childhood:

During childhood period, there are two types of growth in bone growth in width and growth in length. The growth in length performed through growth plate at diaphyseal – epiphyseal junction. The growth plate is a hyaline junction shows proliferation and hypertrophy of chondrocytes then matrix calcification and finally ossification by osteoblasts. The exact mechanism is beyond the scope of our review. Growth in width is accomplished through periosteum by adding bone osteons or Haversian system. The process is started from the inner layer of periosteum which is highly vascularized and contains many stem cells. The stem cells differentiate to osteoblasts that secrete and mineralize matrix of the future bone on both sides of blood vessels that extend longitudinally along the long bones. The bony ridges enlarge in size until they surround the blood vessels. When both ridges fuse together the blood vessels now are located within a canal lined by osteoblasts. Osteoblasts lining the canal continue to form bone along the canal. The newly

formed bone is added as layers called lamellae. The newly added layer separated from the old one by cement line which is formed of ground substance with high collagen. Cement line represents the outer (Fig.7).

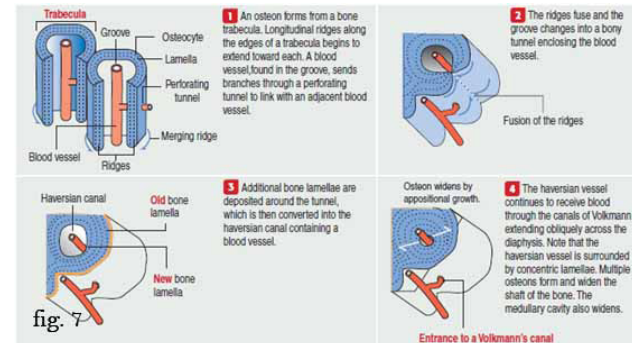


Fig. 7: shows conversion of bone trabeculae into Haversian system by periosteum in four phases.^[7]

By this mechanism the periosteum is able to add many osteons to the external matrix of bone. These osteons increase the width of long bone with subsequent endosteal bone resorption to keep the thickness of bone constant.^[7&16]

Periosteal bone formation in adulthood

Many researches confirm the periosteal bone formation during adulthood period but at slower rate than before. The mechanism of bone formation is similar to that described before start by periosteal ridges around blood vessels, then fuse together to form Haversian canal and finally the concentric lamellae are formed around the Haversian canal consequently.^[24] Other researches further added very important cause for periosteal bone ossification during adulthood that is the occurrence of endosteal bone resorption as very strong stimulus to periosteal bone growth to compensate the removed bony mass.^[17]

The role of osteoblasts indifferntiation and activation of Osteoclasts

Osteoclastogenesis is triggered by two specific molecules produced by the osteoblast:

1. Macrophage colony-stimulating factor(M-CSF) ligand.
2. Receptor Activator Nuclear Factor kappa B ligand(RANKL).

differentiation and activation of osteoclasts occurs in two steps:

The osteoclast precursors are derived from themonocyte-granulocyte progenitor cells through responds to M-CSFligand produced by osteoblast cells.

RANKL is a member of the tumor necrosis factor(TNF) superfamily. RANKL binds to RANKreceptor on the surface of the osteoclast precursors.RANKL-RANK binding stimulates RANK trimerizationand the recruitment of two transcription factors (cfos and nuclear factor Kappa

B). Both acts in the nucleus and activate genes so they triggering the differentiation of the osteoclast precursors to mature osteoclasts (Fig. 8).

Osteoblasts can also regulate and inhibit osteoclastic activity.⁷ Osteoblasts synthesize osteoprotegerin, a protein with high binding affinity for RANKL. Osteoprotegerin is a soluble protein that binds to RANKL and prevents RANK-RANKL interaction. By this mechanism, osteoprotegerin inhibits the osteoclastogenic process. Parathyroid hormone stimulates the expression of RANKL so the pool of RANKL increases relative to osteoprotegerin. Secretion of parathyroid hormone enhances RANK-RANKL binding and osteoclastogenesis, resulting in increased bone resorption. IL-1, TNF, TGF-β, vitamin D, and prostaglandin E2 also can regulate the RANK-RANKL binding and osteoprotegerin.¹⁸ So inflammation also could affect bone formation and resorption.^[19]

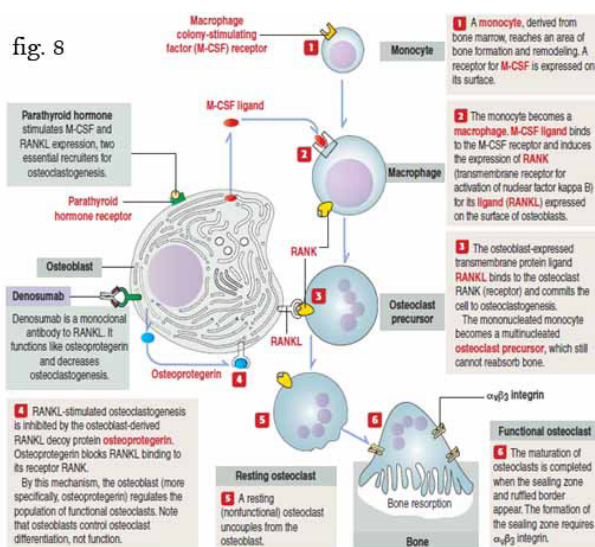


Fig. 8: Osteoblasts regulate osteoclastogenesis.^[7]

Functions of periosteum in bone remodeling:

There was a controversy about the periosteal bone resorption for a long time. The resorption of bone was only devoted to endosteum by osteoclasts of endosteum. To compensate this, bone growth occurs on periosteum. This was called bone modeling. Recently it is reported that bone growth in periosteum also occurs after a process of bone resorption through which osteoclasts erode the old damaged lamellae or microcracks. This resorption gradually gets rid of weak bone and paves the road for new lamellae formation suitable for mechanical force and tension. So exercise is a highly recommended not only for muscle but also for bone remodeling. The term internal bone remodeling is now much more accepted than bone modeling used before. Bone remodeling occurs through interaction between osteoblasts and osteoclasts. Bone remodeling unit is described as cylinder under the periosteum formed of cutting cone created by osteoclasts forming cylinder of 200 μm and closing cone formed by osteoblasts to replace the eroded bone from outside to inside until the cylinder totally

closed. The cylinder changed to Haversian system or newly formed osteon after full osteoblastic activity. As the closing cone is formed rapidly by osteoblasts to close the cutting cone of osteoclasts so on examination of many slides of bone we usually found the closing cone while the cutting cone is rarely observed. Close observation of the closing cone reveal the presence of blood capillaries surrounded by pericytes preosteoblasts and osteoblasts. Those cells act from outwards to inwards to fill the cutting cone.

According to bone remodeling unit mentioned, we could confirm the dynamicity of bone tissue and also the high adaptability of it through the turnover. (Fig. 9).^[6,7 & 8]

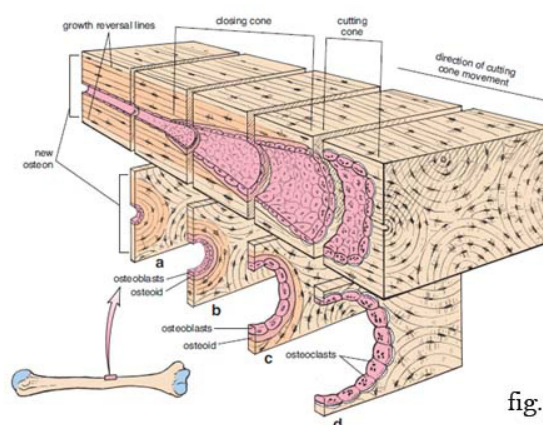


Fig. 9: shows the bone remodeling unit from closing cone toward the cutting cone (A, B C & D).^[6]

Factors affecting bone formation by periosteum:

Bone formation in childhood and adulthood periods is influenced periosteal bone ossification during aging (hormonal, nutritional, smoking, genetic, race, mechanical)^[1]

1. Hormonal regulation:

The role of sex hormones: both androgen in male and estrogen in female have key role in bone growth. Sex hormones stimulate proliferation and ossification within the epiphyseal plate of cartilage in long bones so they lead to closure of epiphyseal plate of cartilage. More specifically androgen stimulates periosteal bone growth. At puberty in males, the periosteum expands due to androgen action with little change in the endosteal bone deposition, so that bone width increases. Males have the bone thickness as females but the androgen effect on periosteum leads to thicker bone diameter than in females, so the bone breaking force is greater in males.^[20, 21&22]

Growth hormone and thyroid hormones: they act on epiphyseal plate of cartilage to maintain the persistence of it and ensure growth of bones in length. Growth and thyroid hormones have receptors on chondrocytes of epiphyseal plate of cartilage. They stimulate proliferation of chondrocytes so the elongations of long bones are ensured through both hormones. Dwarfism is the result of

deficiency of growth hormone and /or thyroid hormones. Moreover, the same hormone act upon osteogenic progenitor cells to differentiate into osteoblasts and start bone formation. Osteoblasts have no receptors for growth hormone but they do have for insulin like growth factor^[6&8].

The role of insulin-like growth factor 1 (IGF-1) in the regulation of periosteal apposition has long been postulated, especially in concert with growth hormone and sex steroids during puberty^[23].

Parathyroid hormone and calcitonin hormone act to regulate the Calcium content within the serum and consequently in bone matrix.

Parathyroid hormone, calcitonin and androgen could be used as drugs during bone fracture or to prevent bone fracture.^[24]

2. Mechanical force:

Muscular exercise and mechanical force stimulates periosteal bone ossification.^[25]

3. Genetic factors:

Certain genes are identified and defined as operators to bone formation.^[26]

4. Different environmental factors:

Nutrition could modulate periosteal bone formation. Some authors proved the inhibitory effect of nicotine one bone formation^[1,27&28].

5. Diseases and drugs:

Renal dysfunction, intake of steroids and vitamin D deficiency inhibit periosteal bone formation,^[29 & 30]

Clinical applications of periosteal bone deposition:

Bone fractures

Traumatic and nontraumatic fractures are some of the most common pathologic conditions affecting bone. Fractures are classified as complete or incomplete; closed (simple) when the overlying tissue is intact; compound when the fracture site communicates with the skin surface; comminuted when the bone is splintered; or displaced when the ends of the bone at the fracture site are not aligned. If the break occurs in bone already altered by a disease process, it is described as a pathologic fracture.

The bone is a good example of regenerative tissue through its ability to create new cells from stem cells already present, secrete bone matrix and finally mineralize the matrix by matrix vesicles.^[31&32]

The first response of fracture is haematogenous inflammatory response as usual to any insult. Inflammatory cells like neutrophils then macrophages reach the field and start to phagocytose and clear the area for the coming healing processes. Granulation tissue is formed that is composed of capillaries, fibroblasts, collagen fibers and

macrophages. With fixed immobilized fracture the stem cells from periosteum and endosteum differentiate to chondrocytes or directly to osteoblasts. Cartilage tissue is formed between the two fractured ends. Then bone tissue is formed over the cartilage in the same way of any bone formed.^[33&34]

The osteogenic progenitor starts to give osteoblasts then bone matrix and bone mineralization occurs. The first bony callus formed is immature bone with many cells and less collagen and minerals. The immature bone transformed to spongy bone by adding more minerals and collagen fibers to the matrix. The bony callus gradually bridge and fuse with the fractured ends. Periosteum and endosteum changed the spongy bone into compact bone according to the tension forces to be suitable with the stress over the newly formed bone.^[35&36]




Fig. 10: shows healing of bone fracture in four phases^[7].

During mature compact bone formation, the old immature bony callus and cartilage if remained are removed by the active osteoclasts, and finally the remodeling process occurs through the closing and cutting cone to give the best suitable bone structure to function.^[37]

In healthy individuals, this process usually takes from 6 to 12 weeks, depending on the severity and site of the fracture. by using immobilization procedures either by external fixation (by casts or by pins and screws) or holding the bony fractured ends in place by internal fixation (by pins, screws, or plates) the regeneration and healing processes speed and the outcomes will be superior in structure and function.^[7]

The stages of healing of bone fracture could be summarized as Tissue destruction and haematoma formation, Inflammation and cellular proliferation, soft Callus formation, hard callus formation, Consolidation and Remodelling.

Intra-articular Fracture neck femur:

Intraarticular fracture of neck of femur has poor prognosis due to many factors but the most important one is thin or absent periosteum.^[38&39]

Incomplete fractures:

This fracture is characterized by bone continuity due to thick periosteum. It carries good prognosis. Here the bone is incompletely divided and the periosteum remains in continuity. It also called a greenstick fracture as the bone is bent (like a fractured green twig). This is seen in children, whose bones are softer than those of adults.^[16]

Closed reduction of bone fracture:

The fracture is reduced by many maneuvers under appropriate anesthesia and muscle relaxation. This is most effective when the periosteum on one side of the fracture intact. Periosteum prevents over-reduction and stabilizes the fracture after reduction.^[40]

Periosteum manipulation in surgery:

Over manipulation of periosteum during internal bone fixation leads to delayed bone union.^[41]

Osteomyelitis in childhood period:

Acute haematogenous osteomyelitis is much more evident in children, because of the relatively loose attachment of the periosteum, than that in adults. In adults the periosteum is thin and adherent to underlying bone.^[42]

Regeneration of bone:

Thick periosteum of bone during childhood leads to rapid healing. Bone diseases and fractures carry good prognosis.^[42]

SUMMARY

The periosteum is formed of two layers outer fibrous and inner osteogenic. The outer layer formed of blood vessels fibroblasts and collagen fibers. The inner layer consists of osteogenic cells and osteoblasts. Periosteum contains many stem cells of bone and stem cell niche. Osteoblast is basophilic cubical cell with vesicular nucleus and protein synthesizing ability. It forms bone matrix and mineralize it through matrix vesicles. Periosteal functions are bone formation during fetal, childhood and adult ages. Bone remodeling unit is formed of closing cone and cutting cone. Bone remodeling unit could be explained by osteoblasts activation to osteoclasts. This activation occurs through RANKL-RANK interactions. Bone formation is regulated by hormonal, mechanical, genetic, environmental factors and diseases. Periosteum has many clinical applications. Most important applications are healing of fracture, good prognosis of childhood fracture, bad prognosis of intra-articular fracture neck of femur and intact periosteum helps in closed reduction.

FURTHER RESEARCH FIELDS

From the previous review we open a way for further research in:

- Treatment of osteoporosis by parathyroid hormone.
- The role of Osteoprotegerin in treatment of osteoporosis.

- Periostin effect on periosteum as a stimulating agent of regeneration.
- Periosteum transplant or mobilization to the sites of non union bone fracture or resistant bone healing.

REFERENCES

1. AMH Elshawarbi, MS Mohamed, HKK Mostafa, MM Magdi: Histological study on the effect of nicotine administration on the bone of adult male albino rat and the possible protective role of vitamin E. Egyptian Journal of Histology (2014) 37 (3), 526-536
2. Mills, S. (2018). Histology For Pathologists. [S.L.]: Wolters Kluwer.
3. Squier CA, Ghoneim S, Kremenak CR. Ultrastructure of the periosteum from membrane bone. J Anat 1990;171:233-9.
4. Tang XM, &Chai BF. Ultrastructural investigation of osteogenic cells. Chin Med J (Engl) 1986;99:9 50-6.
5. Simon TM, Sickle DC, Dennis H. Cambium cell stimulation from surgical release of the periosteum. J Ortho Res 2003;21:470-80.
6. Michael H. Ross & Wojciech Pawlina: Histology: A Text and Atlas: with correlated cell and molecular biology. Wolter and Kluwer Health, Philadelphia. 2016: 7th edition.
7. Kierszenbaum A L. and Laura L. Tres: Histology and cell biology: an introduction to pathology. Fourth edition. Elsevier Saunders Philadelphia PA .2016, page;161 – 181.
8. Antony Mescher :Junqueira's Basic Histology Text and Atlas. McGraw-Hillcompany printed in China. 14th edition 2018. P. 138 – 159.
9. Barbara YGand O'Dowd PW: Wheater's Functional histology. New York: Churchill Livingstone 6th edition 2013;149.
10. Wu Z, Li Q, Pan Y, Yao Y, Tang S, Su J, Shin JW, Wei J, Zhao J Nanoporosity improved water absorption, in vitro degradability, mineralization, osteoblast responses and drug release of poly(butylene succinate)-based composite scaffolds containing nanoporous magnesium silicate compared with magnesium silicate. Int J Nanomedicine 12, 3637-3651 (2017).
11. Litvin J, Selim AH, Montgomery M *et al.* Expression and function of periostin-isoforms in bone. J Cell Biochem 2004;92:1044-106.
12. Oshima A, Tanabe H, Yan T *et al.* A novel mechanism for the regulation of osteoblast differentiation: transcription of periostin, a member of the fasciclin I family, is regulated by the bHLH transcription factor, twist. J Cell Biochem 2002;86:792-804.

13. Li, L., and Xie, T. 2005. Stem cell niche: structure and function. *Annu. Rev. Cell Dev. Biol.* 21: 605–631.
14. Simpson AH. The blood supply of periosteum. *J Anat* 1985;140:697-70.
15. Chang H, Knothe Tate ML. Structure function relationships in the stem cell's mechanical world B: Emergent anisotropy of the cytoskeleton correlates to volume and shape changing stress exposure. *Mol Cell Biomech* 2011;8:297–318.
16. Forriol F, Shapiro F. Bone development: interaction of molecular components and biophysical forces. *ClinOrthopRelat Res* 2005;432:14-33.
17. Crabtree N, Lunt M, Holt G *et al.* Hip geometry, bone mineral distribution, and bone strength in European men and women: The EPOS Study. *Bone* 2000; 27:151-9.
18. Michikami I, Fukushi T, Tanaka M, Egusa H, Maeda Y, Ooshima T, Wakisaka S, Abe M (2012) Krüppel-like factor4 regulates membranous and endochondral ossification. *Exp Cell Res*, 318: 311–325.
19. Elkasrawy MN, Hamrick MW. Myostatin (GDF-8) as a key factor linking muscle mass and bone structure. *J Musculoskelet Neuronal Interact.* 2010;10(1):56–63.
20. Turner RT, Wakley GK, Hannon KS. Differential effects of androgens on cortical bone histomorphometry in gonadectomized male and female rats. *J Orthop Res* 1990;8:612-7.
21. Specker B, Binkley T. Randomized trial of physical activity and calcium supplementation on bone mineral content in 3- to 5-year-old children. *J Bone Miner Res.* 2003;18(5):885-892.
22. Orwoll ES. Androgens: Basic biology and clinical implication. *Calcif Tissue Int* 2001;69:185-8.
23. Bikle D, Majumdar S, Laib A *et al.* The skeletal structure of insulin-like growth factor I-deficient mice. *J Bone Miner Res* 2001;16:2320-9.
24. Parfitt AM. Parathyroid hormone and periosteal bone expansion. *J Bone Miner Res* 2002; 17:1741-3.
25. Van der Meulen MC, Moro M, Kiratli BJ, Marcus R, Bachrach LK. Mechanobiology of femoral neck structure during adolescence. *J Rehabil Res Dev.* 2000;37(2):201-208.
26. Falder S, Sinclair JS, Rogers CA, Townsend PL. Long-term behavior of the free vascularized fibula following reconstruction of large bony effects. *Br J Plast Surg.* 2003;56(6):571-584.
27. Seeman E. An exercise in geometry. *J Bone Miner Res* 2002;17:373-80.
28. Goodship AE, Lanyon LE, McFie H. Functional adaptation of bone to increased stress. An experimental study. *J Bone Joint Surg Am.* 1979;61(4):539-546.
29. Falder S, Sinclair JS, Rogers CA, Townsend PL. Long-term behavior of the free vascularized fibula following reconstruction of large bony effects. *Br J Plast Surg.* 2003;56(6):571-584.
30. Schoenau E, Neu CM, Mokov E, Wassmer G, Manz F. Influence of puberty on muscle area and cortical bone area and cortical of the forearm in boys and girls. *J Clin Endocrinol Metab.* 2000;85(3): 1095-1098.
31. Looker AC, Beck TJ, Orwoll ES. Does body size account for gender differences in femur bone density and geometry? *J Bone Miner Res* 2001;16:1291-9.
32. Nelson DA, Barondess DA, Hendrix SL, Beck TJ. Cross-sectional geometry, bone strength, and bone mass in the proximal femur in black and white postmenopausal women. *J Bone Miner Res* 2000;15:1992-7.
33. R, Turner R, Skinner L *et al.* Mapping quantitative trait loci that influence femoral cross sectional area in mice. *J Bone Miner Res* 2002 ; 17:1752-60.
34. Zhu, Y., Mao, Z. & Gao, C. Control over the gradient differentiation of rat BMSCs on a PCL membrane with surface-immobilized alendronate gradient. *Biomacromolecules* 14, 342–9 (2013).
35. Michikami I, Fukushi T, Tanaka M, Egusa H, Maeda Y, Ooshima T, Wakisaka S, Abe M (2012) Krüppel-like factor4 regulates membranous and endochondral ossification. *Exp Cell Res*, 318: 311–325.
36. Hartmann C: Skeletal development—Wnts are in control. *Mol Cell* 2007; 24:177.
37. Alman BA: Skeletal dysplasias and the growth plate. *Clin Genet* 2008; 73:24.
38. Szechinski JW, Grigorian MA, Grainger AJ *et al.* Femoral neck and intertrochanteric fractures: radiographic indicators of fracture healing. *Orthopedics* 2002;25:1365–8.
39. Midura RJ, Su X, Morcuende JA *et al.* Parathyroid hormone rapidly stimulates hyaluronan synthesis by periosteal osteoblasts in the tibial diaphysis of the growing rat. *J Biol Chem* Dec 2003; 278:51462–8.

40. Elkasrawy MN, Hamrick MW. Myostatin (GDF-8) as a key factor linking muscle mass and bone structure. *J Musculoskelet Neuronal Interact.* 2010;10(1):56–63.
41. Kelly, D. J. & Jacobs, C. R. The role of mechanical signals in regulating chondrogenesis and osteogenesis of mesenchymal stem cells. *Birth Defects Res C Embryo Today* 90, 75–85 (2010).
42. Solomon, Louis., Warwick, David., Nayagam, Selvadurai. and Apley, A. Graham. *Apley's system of orthopaedics and fractures.* 2010. London: Hodder Education.