

The Possible Ameliorative Action of L-Carnitine Against Chlorambucil-Induced Testicular Damage in Adult Rat: Histological Study

Diana Eid Aziz, Nawal Rizkalla, Mennatulla Elrashidy and Ahmed S. Sadek

Department of Anatomy and Embryology, Faculty of Medicine, Ain Shams University, Egypt

ABSTRACT

Introduction: The safety of anti-cancer agents on normal tissues has come under examination due to the increase in the usage of these medications. Chlorambucil, which is anticancerous drug is associated with toxic side effects on testes. L-carnitine might have a protective effect against a wide variety of testicular damage that might progress to male infertility.

Aim of the Work: To demonstrate the possible ameliorative action of L-carnitine on chlorambucil-induced testicular damage on rats' testes.

Materials and Methods: 40 adult male albino rats were assigned into four groups; Control group (I); L- carnitine group (II), where rats receiving daily oral dose of L-carnitine (500 mg/kg); Chlorambucil group (III), where rats were received chlorambucil orally by gastric tube at a dose of 0.2 mg/kg/day; and Combined group (IV), where rats were co-administered L-carnitine and chlorambucil. After 21 days, all rats were sacrificed, and their testes were weighted, processed into paraffin blocks, and prepared to be examined under light microscope.

Results: Chlorambucil strongly altered the testicular architecture which was evidenced by seminiferous epithelial vacuolization and rarefaction, germ cell degeneration and the presence of multinucleated giant cells. Also, there was a high percentage of damaged tubules, decreased germinal epithelial height, and absence of sperms in lumina. Histological examination of sections from combined group showed a considerable amelioration of testicular damage and vacuolations reflected by a statistically significant decline in damaged tubules count. Additionally, there was a significant increase in testicular weight and germinal epithelial height when compared to the chlorambucil group.

Conclusion: L- carnitine can protect against chlorambucil-induced testicular insult in rats.

Received: 07 October 2023, **Accepted:** 17 November 2023

Key Words: Chlorambucil, L- carnitine, oxidative stress, rat, testis.

Corresponding Author: Diana Eid Aziz, MD, Department of Anatomy and Embryology, Faculty of Medicine, Ain Shams University, Cairo, Egypt, **Tel.:** +20 12 2374 9875, **E-mail:** dr.didi.9@gmail.com

ISSN: 1110-0559, Vol. 47, No. 2

INTRODUCTION

The safety of anti-cancer agents on normal tissues has come under examination due to the increase in the usage of these medications. Numerous kinds of anticancer drugs were recognized to cause tissue damage in biological systems by producing high levels of oxidative stress^[1]. In Western countries, chronic lymphocytic leukemia (C.L.L) is considered the most prevalent variant of the disease. The nitrogen mustard alkylating agent, chlorambucil, is the most used form of treatment when it is necessary. ^[2] Also, chlorambucil is used in management of Hodgkin's and non-Hodgkin's lymphomas^[3]. Many studies suggested that Chlorambucil toxicity might be elicited by free radicals' formation or by depletion of the body's supply of antioxidants^[4].

Since the testis is a lipid-rich organ, therefore the extensive exposure to pro-oxidants may exhaust its antioxidant reserve, putting the risk of excessive lipid

peroxidation and eventual tissue damage on the cells^[5]. It was estimated that administering antioxidants in addition to chlorambucil might provide some protection against oxidative damage to the testes. Consequently, supplementation with antioxidants may lessen the severity of these hazardous side effects without affecting the medication's anti-cancer properties^[6].

The natural amino acid, L-carnitine, can be now described as a potential cytoprotective medication and plays an important role in cellular energy generation^[7]. It is essential for the mitochondria to produce ATP through fatty acid oxidation^[8,9]. L- carnitine was considered to have potent anti-oxidant, anti-inflammatory and anti-apoptotic functions^[10,11,12].

The aim of the current study was to demonstrate the possible ameliorative action of L-carnitine on chlorambucil-induced oxidative histological changes on adult rats' testes.

MATERIAL AND METHODS

Experimental animals

40 male adult albino rats (200-250 grams) were utilized in the current work. Rats were bought from the Medical-Ain-Shams-Research-Institute (MASRI). All animals were living in the same environment and had unrestricted access to water. The research plan was completed in concordance with the guidelines of Research-Ethics-Committee (REC), Faculty of Medicine, Ain-Shams University. Ethical approval committee number FMASU MS 420/2022. Ethical conduct in experimenting on laboratory animals was carefully considered all through the study.

Drugs

1. Chlorambucil (Leukeran2 mg tablet) was manufactured by Excella GmbH & CO.KG, Feucht, Germany. The tablets were pulverized, then dissolved in distilled water and the solution was given to rats via gastric tube at a dose of 0.2 mg/kg/day^[13,14].
2. L-carnitine 1000 mg tablets produced by MEPACO, Sharkeya, Egypt. Tablets were pulverized and dissolved in distilled water and the solution was given to rats via gastric tube^[15].

Study design

Animals were divided into four equal groups [N=10]; **Group I** (Control group) receiving distilled water by gastric gavage; **Group II** (L-carnitine group) having 500 mg/kg/day of L-carnitine administered; **Group III** (chlorambucil group) receiving chlorambucil at a dose of 0.2 mg/kg/day; and **Group IV** (Combined group), where rats were co-administered L-carnitine and chlorambucil. The experimental period lasted for three consecutive weeks. Then, all rats were anesthetized and sacrificed in concordance with the protocol of REC, Faculty of Medicine, Ain-Shams University.

histological studies

Both testes from each animal were carefully dissected then weighed. One of both testes was fixed in Bouin's solution for 24 hours, processed to paraffin sections and stained with Hematoxylin & Eosin (Hx & E). The other testis was prepared for semithin sections, where 1 mm³ specimens were fixed in glutaraldehyde 2.5% at 4 ° C for 24H, then washed three times in phosphate buffer, post fixed in 1% aqueous osmium-tetroxide for 2H. The specimens were dehydrated using propylene oxide and a graded ethanol series before being embedded in epoxy resin. The embedding blocks were divided into semi-thin (1 m) pieces, analyzed, and photographed after being stained with 1% toluidine-blue^[16].

Morphometric study

The Image-J software (Image-J 1.52a, Maryland, USA) was used to analyze images. The seminiferous epithelial height and the percentage of damaged tubules were

assessed at low power field (X100) per cut section of the testes for all groups of the study.

Statistical Analysis

Records of seminiferous heights and percentage of damaged tubules were expressed as mean \pm standard deviation. one-way analysis of variance was used to identify any differences between studied groups. The findings were esteemed statistically-significant and high-significant with $P < 0.05$ and 0.001 , respectively.

RESULTS

Histological results

Group I (Control group): Examination of Hx & E-stained testicular sections from both control and L-carnitine groups looked similar and showed numerous seminiferous tubules (ST) attained regular outline with interstitial tissues in between (Figure 1). ST were enclosed by a well-defined basement membrane (BM) and acquired a whirly appeared lumen due to arrangement of sperms. The germinal epithelium composed of spermatogenic cells at various phases of spermatogenesis. These cells involved spermatogonia, primary (1ry) spermatocytes the largest cell, rounded spermatids with acrosomal cap and elongated spermatids (Figures 1,2). Semithin sections showed the arrangement of spermatogenic cells with basal layer of spermatogonia located very close to the BM. The 1ry spermatocytes, appeared larger in size than spermatogonia, constituted the next layer. The early or rounded spermatids were arranged in two or three layers that could be identified. Finally, mature, or late spermatids. Pyramidal-shaped Sertoli cells were observed with their large triangular nuclei laying on the basement membrane. (Figure 3).

Group II (L-carnitine group): The examination of hematoxylin and eosin-stained sections of rat testes of the L-carnitine group (group II) showed normal organization of the seminiferous tubules with interstitial tissues in between. The tubules were lined by germinal epithelium and sertoli cells. The lumens of the tubules showed whirly arrangement of the sperms (Figure 4).

The germinal epithelial layer showed normal arrangement of spermatogonia, primary spermatocytes, and rounded spermatids (Figure 5).

Semithin sections showed normal appearance of the spermatogonia, primary spermatocytes, rounded spermatids and, Sertoli cells (Figure 6).

Group III (Chlorambucil group): Examination of Hx&E-stained sections of chlorambucil group revealed disruption of the ST architecture. Absence of sperms in the tubular lumen, and wide spacing between tubules was detected in most of the sections (Figure 7). Another sign indicating tubular damage was the depletion of germinal epithelial layers with sloughing of spermatogonia into the lumen. Most of the tubules showed diffuse areas of

vacuolations with eosinophilic residual bodies dispersed throughout their lumina. Some cells appeared with dark shrunken nuclei, while others showed multiple nucleated giant cells (Figures 8,9). Semithin sections showed tubular damaged with loss of general architecture. Whereas Spermatogonia, primary spermatocytes, and spherical spermatids had disappeared from the germinal epithelium. There were desquamated cells observed near the lumen (Figure 10).

Group IV (Combined group): Examination of Hx &E-stained sections of the combined group (group IV) revealed retaining of the normal architecture in most of the ST, where they showed adequate thickness of germinal epithelial layers which are surrounding by spindle shaped telocytes. However, some tubules still demonstrated some signs of damage such as vacuolations, detachment of BM, and separation of the germinal layers (Figure 11). On higher magnification, there was preserved germinal epithelial architecture with intact primary spermatocytes and rounder spermatids (Figure 12). Semithin sections showed intact germinal epithelial cells layers such as spermatogonia, primary spermatocytes, and rounded spermatids. On the other hand, tubules revealed evidence of damage such as vacuolation and detachment of BM (Figure 13).

Histo-morphometric results

Estimation of the rats' testicular weight: Comparing Chlorambucil group to control group, there was a highly significant ($P < 0.001$) decline in the weight of rats' testes. Co-administration of L- carnitine and chlorambucil (Combined group) led to a highly statistically significant ($P < 0.001$) rise in rats' testicular weight in comparison with group III (Chlorambucil Group) (Figure 14).

Estimation of the germinal epithelial height: Assessment of the germinal epithelial height changes in various groups when compared to the control group assumed a highly statistically significant ($P < 0.001$) decline in germinal epithelial height of ST in group III (Chlorambucil group) and group IV (combined group). However, animals in group IV (Combined group) revealed a highly statistically significant ($P < 0.001$) rise in germinal epithelial height in comparison with group III (Chlorambucil Group) (Figure 15).

Estimation of the percentage of damaged ST to normal ones: The percentage of damaged ST in rats of group III (Chlorambucil Group) and group IV (Combined group) displayed a highly statistically significant ($P < 0.001$) when comparing it to the control group. However, rats in group IV (Combined group) exhibited a highly statistically significant ($P < 0.001$) decline in the percentage of damaged tubules in comparison with group III (Chlorambucil Group) (Figure 16).

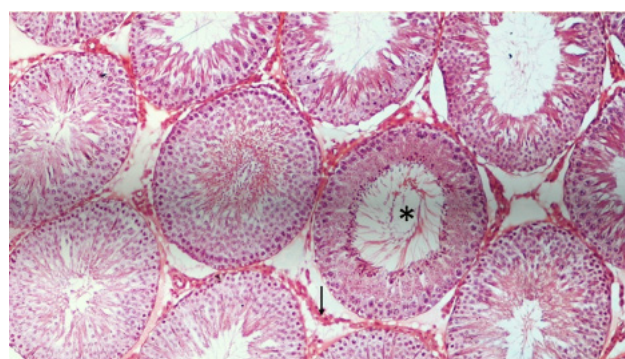


Fig. 1: A photomicrograph of testicular section of control rat showing the ST compactly packed together as rounded or oval shape having multiple layers of germinal cells. The lumen of the tubules shows the presence of sperms in a whirly appearance (*). Notice the presence of the interstitial tissue between the tubule (black arrow). (H & E 100X)

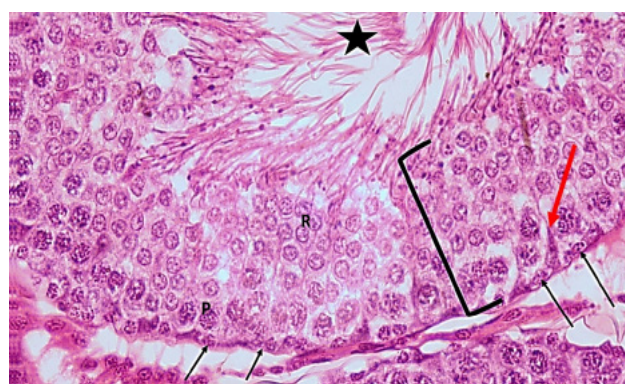


Fig. 2: Higher magnification of a control rat testicular section showing part of ST with several layers of germinal epithelium (black bracket), Spermatogonia (black arrow) resting on basement membrane, primary spermatocytes (P), rounded spermatids with its acrosomal cap (R) and elongated sperms towards the lumen (black star). Notice elongated triangle Sertoli cells (red arrow) and interstitial cells. (Hx &E 400)

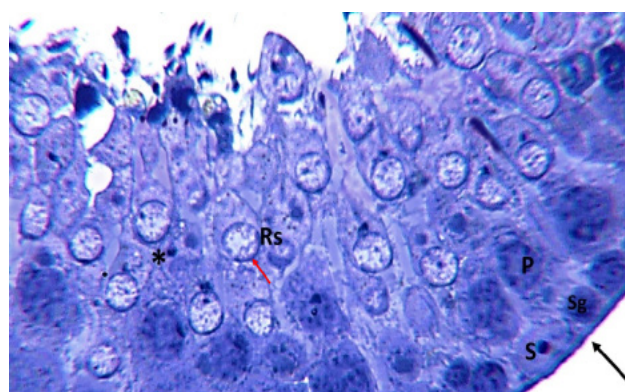


Fig. 3: A photo-micrograph of a control rat testicular section showing ST lined by germinal epithelium & Sertoli cells (S) with characteristic nucleus and nucleolus. Various cells of germinal epithelium; Spermatogonia (Sg) near the base of the tubule on the basement membrane, 1ry spermatocytes (P), and rounded spermatids (Rs) with acrosomal cap (red arrow). Notice the regular adherent basement membrane (black arrow) and the intercellular bridges (*). (Toluidine blue 1000)

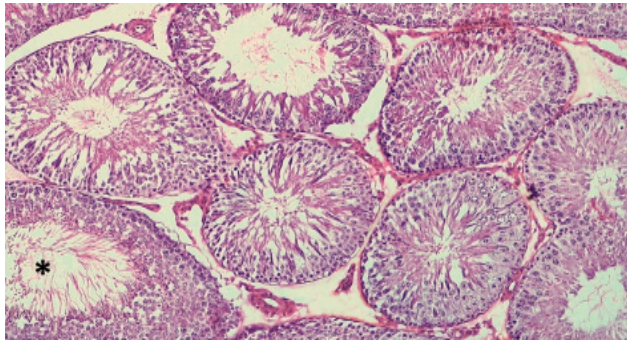


Fig. 4: A photomicrograph of testicular section of L-Carnitine treated group showing seminiferous tubules packed together with germinal epithelial cells arranged in a normal manner. Note the presence of the whirly distribution of sperms in lumen (*). (H&E X100)

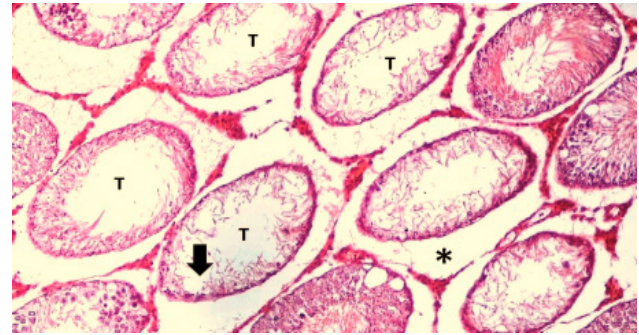


Fig. 7: A photo-micrograph of testicular section of a chlorambucil-treated group showing apparent decrease in tubular diameter (T). The tubules are widely separated STs with interstitial tissue in between (*). Some tubules are devoid of germinal epithelium and contain acidophilic threads of Sertoli cell cytoplasm. Other tubules show vacuolated germinal epithelium (black arrow) (Hx &E 100)

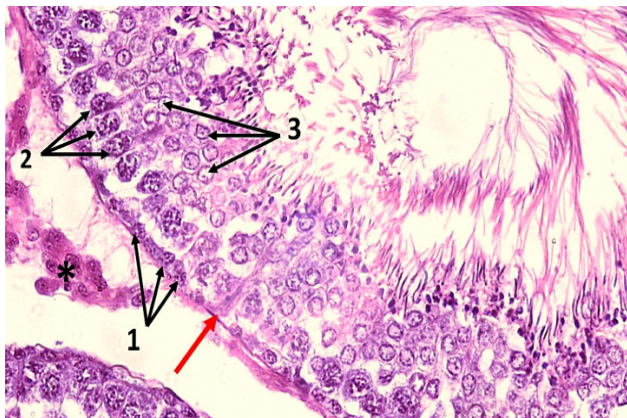


Fig. 5: A photomicrograph of testicular section of L-Carnitine treated group showing the spermatogonia (1), 1ry spermatocytes (2) and rounded spermatids (3) and the Sertoli cell laying on the basement membrane (red arrow). Notice the interstitial tissues (*). (H&E 400X)

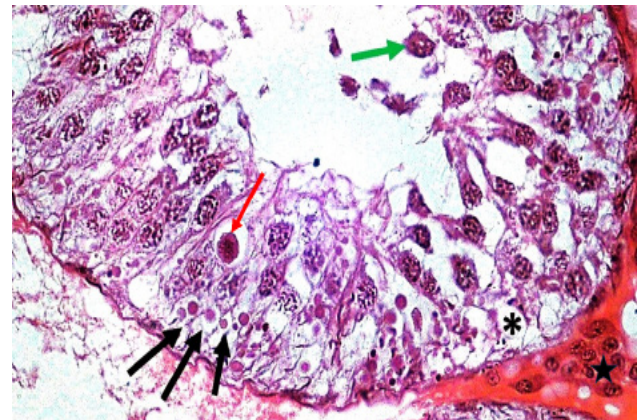


Fig. 8: A photo-micrograph of testicular section of chlorambucil-treated group showing disruption of the normal epithelial architecture of the tubule. Germ cells lie on thick irregular basement membrane and are widely separated. Multiple vacuoles are seen in the germinal epithelium (*). Primary spermatocytes are present in the tubular lumen (green arrow). Notice the appearance of Multinucleated giant cell (red arrow), residual bodies (black arrow) and interstitial cells (black star). (Hx &E 400)

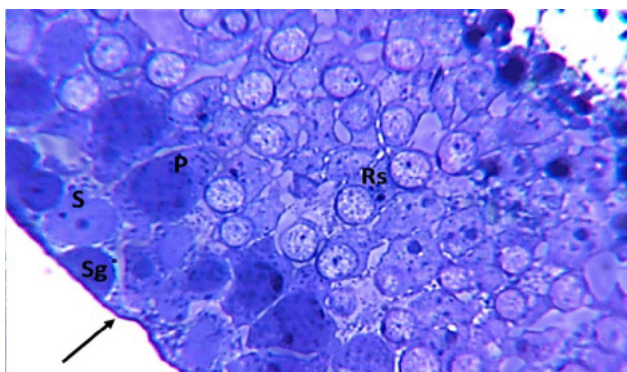


Fig. 6: A photomicrograph of a semithin section of testicular section of L-carnitine treated rat showing normal stages of the germinal epithelium: spermatogonia (Sg), Sertoli cells(S), primary spermatocytes(P), and rounded spermatids (Rs). Notice adherent basement membrane (black arrow). (Toluidine blue 1000X)

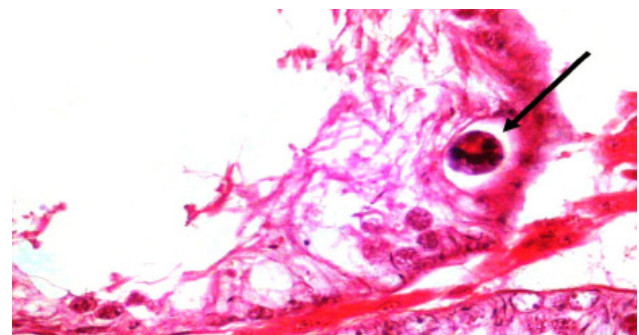


Fig. 9: A photo-micrograph of a testicular section of chlorambucil-treated group showing a multinucleated giant cell within the damaged germinal epithelium (black arrow). (Hx &E 400)

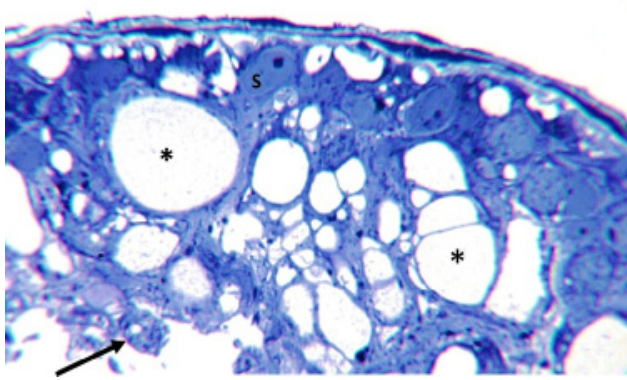


Fig. 10: A photo-micrograph of a testicular section of chlorambucil-treated group showing the ST lined by only Sertoli cells (S). Many vacuoles are present at varying depth in the tubule (*). Notice absence of germinal epithelium with desquamated cells near the lumen (black arrow). (Toluidine blue 1000)

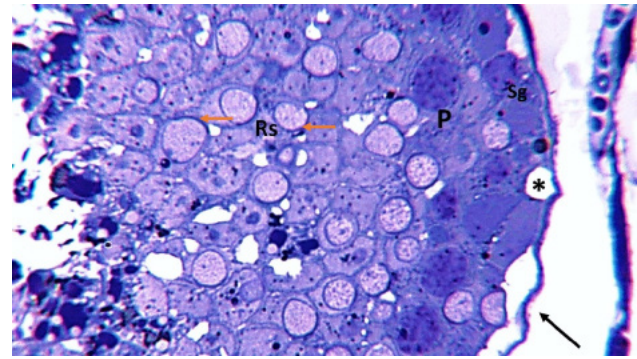


Fig. 13: A photo-micrograph of testicular section of group IV showing preserved germinal epithelial cells; spermatogonia (Sg), Iry spermatocytes(P), and rounded spermatids (Rs) with acrosomal cap (red arrow). Notice focal detachment of BM (black arrow) and the vacuolation of the germinal epithelium (*). (Toluidine blue 1000)

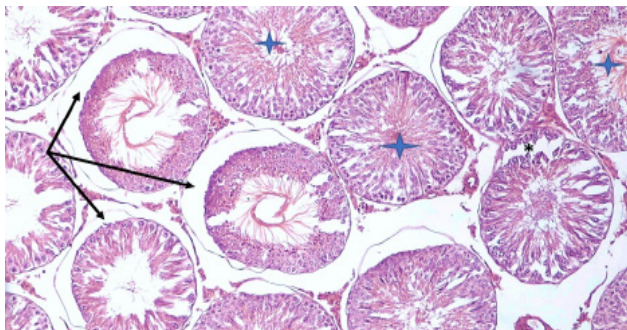


Fig. 11: A photo-micrograph of testicular section of the group IV showing widely separated tubules. Some tubules appear to have normal structure with sperms inside the lumen (). Other tubules showing separation in the layers of germinal epithelium (*) in addition to vacuolations. Notice the presence of network of spindle shaped cells surrounding both tubular basement membrane and interstitial cells. (Hx &E 100)

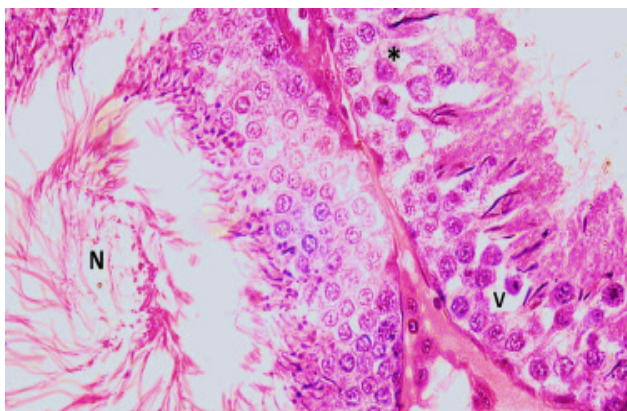


Fig. 12: A photo-micrograph of testicular section of group IV showing two adjacent ST, one revealed normal appearance (N) except for some vacuolations (V) and relative fewer cells (*) within the epithelial germ cell. (Hx &E 400)

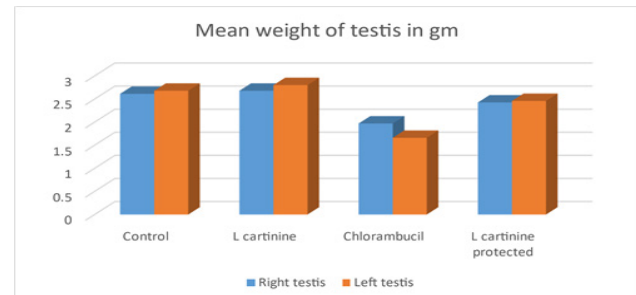


Fig. 14: The mean weight of the right and left testes in rats among the four studied groups

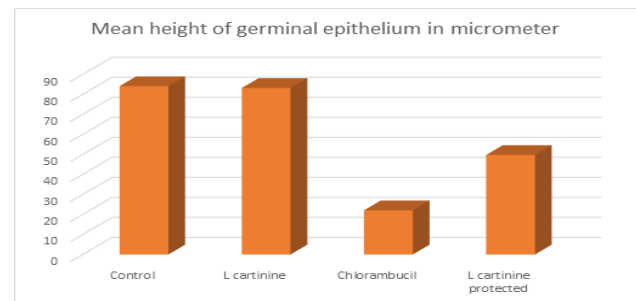


Fig. 15: The mean germinal epithelial height in in rats among the four studied groups

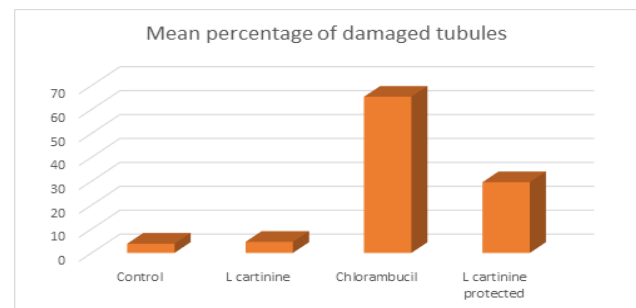


Fig. 16: The mean percentage of damaged ST in rats among the four studied groups

DISCUSSION

Numerous antineoplastic medications are annually formulated due to the high incidence of neoplastic diseases. Most often, these medications could cause injury to vital organs, but investigations on reproductive organs, particularly the testes, have been relatively scarce. There are few studies conducted on chemotherapy-induced damage attributed to the disturbance of the testicular antioxidant system^[4]. Finding efficient ways to lessen the adverse effects of chemotherapeutic agents has taken great concern especially in young cancer patients to maintain their fertility. In addition to freezing the gonadal tissues, which is an effective method for preventing infertility after chemotherapy, Antioxidants are also capable of protecting cells and tissues from disorders resulted from release of reactive oxygen containing elements and free radicals^[17].

The rationale of the present study was to study the possible ameliorative action of L-carnitine against the gonado-toxic effects of one of the medications used in the treatment of leukemia, which is chlorambucil, and its sequel on the histological architecture of adult male albino rats' testes.

Chlorambucil is a chemo-therapeutic agent used in the treatment of CLL. It has the potential to cause oxidative stress or deplete tissue antioxidant reserves^[4]. Testicular oxidative stress has a detrimental effect on male fertility. Numerous research on anti-cancer drugs have demonstrated that they can disrupt testicular function via inducing oxidative stress^[18]. Kim *et al.*, 2023 found that reduced testicular weight, decreased sperm motility and count, and unorganized morphology of the ST were all signs of testicular damage, which might have been caused by increased oxidative stress in the testis. According to Marco di Antonio *et al.*, 2014 Chlorambucil can be used as anti-cancer medication by inhibiting DNA replication and damaging the DNA in a cell. This DNA damage leads to cell cycle arrest and cell apoptosis.

Our study declared that chlorambucil administration led to severe histopathological and histo-morphometrical damage in the testicular structure over the fixed predetermined time of the study which was three weeks. Pathological changes in the testicular architecture included all components of ST.

In the contemporary work, we found a significant decline in rats' testicular weight in chlorambucil group in comparison with the control group. This result was agreed with the previous work of Adejuwon *et al.*, 2015, who explained that lack of germ cell maturation and ceased spermatocytes throughout various phases of division led to ST shrinkage, which in turn resulting in gonadal weight reduction.

Intertubular spaces were seen widened than normal in rats' testes of chlorambucil group (Group III). This indicated that the tubules might shrunk and decreased in size. Kim *et al.*, 2023 suggested that tubular atrophy resulted from the downregulation of Sertoli cells' adhesion

proteins like cadherin, could accelerate the seminiferous epithelial cells' sloughing^[19].

Irregular and detached BM were found in the ST of many treated rats with chlorambucil Group III^[20,21]. Severe functional impairment of the testis could be attributed to altered BM structure^[22]. Sasso-Cerri & Cerri, 2008 also explained that there is a close association between affection of Sertoli cells and BM damage^[23].

In the ongoing study, there was marked depletion in germinal epithelial layers of the spermatogenic cells with remaining Sertoli cells only in many ST. This was explained by Maran & Arudhas., 2009 who stated that the depletion of the germinal epithelial cells were occurred by the arrest in differentiation and proliferation of germ cells. This finding is similar to the Sertoli-cells only syndrome, only sertoli cells were found lining the ST with extremely low or absent spermatogenesis^[24].

Monses *et al.*, 2000 stated that the abnormality in the Sertoli cells led to loss of spermatogenic cells, mostly due to blood testicular barrier disruption. The damage of this barrier also explained the degeneration of the primary spermatocytes and the spermatids in this study^[25].

In the concurrent work, desquamation of spermatogenic cells in the lumen was observed, a finding was common with the study of Shaaban *et al.*, 2023^[26]. It was explained by many authors that organized germ cells were preserved in situ due to strong link between their plasmalemmas and the cell membranes of Sertoli cells^[27]. Hess & Nakai, 2000 mentioned that germ cells' early signs of degeneration could cause disruption in their plasmalemmas resulting in shedding of these cells into ST lumina^[28].

In the current study, vacuolations within the germinal epithelium is due to destruction of cellular processes of Sertoli cells and this is finding was repeated in many treated groups. According to Justin D. and Katherine M. [2014] vacuolations seen within and between Sertoli cells is an early indicator of the damage of these cells^[29]. Injury to the Sertoli cells is commonly present with losing its function instead of death and loss of the Sertoli cells themselves^[30]. Cellular process of Sertoli cells destruction leads to loss of nutrition of cells, loss of barrier, loss of junction between apex of Sertoli cells and head of sperms, and finally sloughing of cells inside the lumen^[31]. Vacuolated ST epithelium due to the affection of the spermatogenesis process leading to germinal epithelium disorganization^[32].

Other findings were detected in this study involve the appearance of giant cells and eosinophilic hyaline materials inside the tubules in rats' section of group III [Chlorambucil group]. Giant cells seemed to be a strong indicator of testicular degeneration^[33]. Testicular degeneration can be manifested by non-specific cells stacked together forming multinucleate giant cells. When the testicular damage is occurring slowly, then the nearby germ cells may form multinucleated giant cells. This finding mostly occurred due to destruction of the cytoskeletal fibers supporting the cytoplasmic bridges connecting these cells. These giant

cells cannot be easily phagocytized by Sertoli cells^[34]. Wang S, *et al.*, 2020 & Yadav *et al.*, 2022 assumed that oxidative stress on testis can lead to apoptosis of germ cells and then these apoptotic cells were replaced by eosinophilic hyaline materials^[35,36].

Turk *et al.*, 2008 suggested that chemotherapy accelerated intra-cellular ATP loss, causing sperm motility to decline, and reduced viability of sperms^[37]. Additionally, it was stated that the unusual production of ROS and oxidant\antioxidant imbalance in the gonadal tissue might be responsible for histological alterations produced by chemotherapy^[38].

On the other hand, all these pathological findings were markedly ameliorated in the rats receiving L-carnitine and chlorambucil together. According to Eid *et al.*, 2016, L-carnitine could significantly reduce testicular injury by reducing inflammation, oxidative stress, as well as enhancement of testicular histological characteristics and spermatogenesis^[14].

In the present work, L- carnitine could ameliorate gonadal weight decline induced by chlorambucil and lead to substantial restoration of testicular function through preserving intact ST morphology. In addition, the percentage of damaged ST in rats' testes of the combined group was highly significant declined in comparison with those of chlorambucil group. Hafezi *et al.*, 2022 found that L-carnitine led to restoration of testicular volume and germinal epithelial height of ST^[17]. Ramadan *et al.*, 2002 also affirmed that pre-treatment with L- carnitine could transpose most of the histo-pathological alterations induced by oxidative stress^[39]. This came in correspondence with Olayinka and Ore, 2014 who added that antioxidant supplementation prevented the degeneration of germ cells^[4]. Sagar, 2005. also claimed that the observed anti-oxidant capabilities of L-carnitine might be implicated in the scavenging of ROS produced by chlorambucil^[40]. Famularo G. *et al.*, 2004 proposed that l-carnitine promotes ATP action, and this can be involved in DNA protection, which by its role stimulates protein phosphorylation used in the nucleic acid synthesis and processing^[41]. it was reported that l-carnitine activates the DNA repair enzyme poly (ADP ribosyl) polymerase, a nuclear protein that is linked with the occurrence of DNA repair mechanisms^[35].

Koohpeyma *et al.*, 2022 confirmed the finding in this study by stating that L- carnitine elevates serum level of LH, FSH and testosterone resulting in a significant increase of the weight of the testis, the length, the diameter, and the height of the germinal epithelium. L-carnitine enhances testosterone production, so it improves testicular function and makes presenting testosterone more active^[42].

In this study, it is likely that L-carnitine provides protection to the seminiferous tubules by acting mainly on Sertoli cells improving their development and maturation^[43], and by maintaining blood-testis barrier as the Sertoli cells express OCTN2 (organic cation transporter 2) and the carnitine/organic cation transporter 2^[44]. This

also can be proved by the presence of the telocytes which play an important role in communication between ST and establishing intact blood-testis barrier^[45].

CONCLUSION

In conclusion, L-carnitine can exert a considerable ameliorative action against chlorambucil induced testicular damage in rats. Because of its potential to eliminate ROS and boost antioxidants, L-carnitine can be advantageous as an adjunctive treatment with chlorambucil in cancer patients.

CONFLICT OF INTERESTS

There are no conflicts of interest.

REFERENCES

- Vardi, N., Parlakpınar, H., Ates, B., *et al.* Antiapoptotic and antioxidant effects of β -carotene against methotrexate-induced testicular injury. *Fertility and sterility*, (2009) 92(6):2028-2033. doi: 10.1016/j.fertnstert.2008.09.015.
- Begleiter, A., Mowat, M., Israels, L. G., *et al.* Chlorambucil in chronic lymphocytic leukemia: mechanism of action. *Leukaemia & lymphoma*, (1996) 23(3-4), 187-201. DOI: 10.3109/10428199609054821.
- Dighiero, G., Maloum, K., Desablens, B., *et al.* Chlorambucil in indolent chronic lymphocytic leukemia. *New England Journal of Medicine*, (1998) 338(21): 1506-1514. DOI: 10.1056/NEJM199805213382104
- Olayinka, ET and Ore, A. Kolaviron and L-ascorbic Acid attenuate chlorambucil-induced testicular oxidative stress in rats. *J Toxicol.*, (2014):587015. doi: 10.1155/2014/587015
- Mylonas, C., and Kouretas, D. Lipid peroxidation and tissue damage. In *Vivo* (Athens, Greece), (1999) 13(3), 295-309.
- Seufi, A., Ibrahim, S., Elmaghraby, T., *et al.* Preventive effect of the flavonoid, quercetin, on hepatic cancer in rats via oxidant/antioxidant activity: molecular and histological evidence. *Journal of Experimental & Clinical Cancer Research*, (2009) 28(1):1-8. doi: 10.1186/1756-9966-28-80.
- Radwan, R., Shaban, E., Kenawy, S., *et al.* Protection by low-dose γ radiation on doxorubicin-induced nephropathy in rats pre-treated with curcumin, green tea, garlic or l-carnitine. *Bulletin of Faculty of Pharmacy, Cairo University* (2012), 50(2): 133-140. DOI:10.1016/j.bfopcu.2012.09.002
- Al-Majed, A. Carnitine deficiency provokes cisplatin-induced hepatotoxicity in rats. *Basic Clin Pharmacol Toxicol*, (2007) 100(3): 145-150.
- Aleisa, A., Al-Majed, A., Al-Yahya, A., *et al.* Reversal of cisplatin-induced carnitine deficiency and energy starvation by propionyl-L-carnitine in rat kidney tissues. *Clin Exp Pharmacol Physiol*, (2007) 34(12): 1252-1259. doi: 10.1111/j.1742-7843.2006.00024.x.

10. Cetinkaya, A., Bulbuloglu, E., Kantarceken, B., *et al.* Effects of L-carnitine on oxidant/antioxidant status in acetic acid-induced colitis. *Dig Dis Sci*, (2006) 51(3): 488-494. doi: 10.1007/s10620-006-3160-9.
 11. Dokmeci, D., Inan, M., Basaran, U., *et al.* Protective effect of L-carnitine on testicular ischaemia-reperfusion injury in rats. *Cell Biochem Funct*, (2007) 25(6): 611-618. doi: 10.1002/cbf.1355.
 12. Izgut-Uysal, V., Agac, A. and Derin, N. Effect of L-carnitine on carrageenan-induced inflammation in aged rats. *Gerontology*, (2003) 49(5): 287-292. doi: 10.1159/000071709.
 13. Tomenendálová J, Mayer J, Doubek M, *et al.* Toxicity of high dose chlorambucil in Wistar rats. *Acta Veterinaria Brno*, (2008) 77(4):595–602. DOI:10.2754/avb200877040595.
 14. Eid, A. Protective effect of L-carnitine against cisplatin-induced testicular toxicity in rats. *Al-Azhar Journal of Pharmaceutical Sciences*, (2016) 53(1):123-142. DOI: 10.21608/AJPS.2016.6891
 15. Cayir, K., Karadeniz, A., Yildirim, A., *et al.* Protective effect of L-carnitine against cisplatin-induced liver and kidney oxidant injury in rats. *Open Med*, (2009) 4(2): 184-191. <https://doi.org/10.2478/s11536-009-0021-x>.
 16. Bancroft J. and Gamble M. Bancroft's theory and Practice of Histological techniques, 8th edition, Elsevier, London, (2013) pp. 69-95.
 17. Hafezi, H., Vahdati, A., Forouzanfar, M., *et al.* Ameliorate effects of resveratrol and l-carnitine on the testicular tissue and sex hormones level in busulfan induced azoospermia rats. *Theriogenology*, (2022) 191, 47-53. doi: 10.1016/j.
 18. Yuluğ, E., Türedi, S., Alver, A., *et al.* Effects of resveratrol on methotrexate-induced testicular damage in rats. *The scientific world journal*, 2013: 489659. <https://doi.org/10.1155/2013/489659>
 19. Kim, K. H., Park, M. J., Park, N. C., *et al.* Effect of N-acetyl-L-cysteine on Testicular Tissue in Busulfan-Induced Dysfunction in the Male Reproductive System. *The World Journal of Men's Health*, (2023) 41(4):882-891. DOI: 10.5534/wjmh.220100
 20. Marco Di Antonio Keith I. E. , and Shankar B. Reprogramming the Mechanism of Action of Chlorambucil by Coupling to a G-Quadruplex Ligand. *J. Am. Chem. Soc.* 2014, 136, 16, 5860–5863. doi. org/10.1021/ja5014344
 21. Adejuwon, S., Femi-Akinlosotu, O., and Omirinde, J. Cisplatin-induced testicular dysfunction and its amelioration by L aunaea taraxacifolia leaf extract. *Biomedicine online*, (2015) 8(4), 376-384. doi: 10.1111/and.12302.
 22. Ghanami N, Sadighi M, and Abbasi M. Sertoli cell-only syndrome: etiology and clinical management. *J Assist Reprod Genet*, Mar; (2021) 38(3):559-572. DOI: 10.1007/s10815-021-02063-x
 23. Sasso-Cerri, E. and Cerri, P. Morphological evidence indicates that the interference of cimetidine on the peritubular components is responsible for detachment and apoptosis of Sertoli cells. *Reproductive biology and endocrinology*, (2008) 6(1),1-10. doi: 10.1186/1477-7827-6-18
 24. Bostancieri, N., Taslidere, A., Elbe, H., *et al.* Protective effects of quercetin against testis damage caused by cisplatin. *Biotechnic & histochemistry*, (2022) 97(3), 180-184. doi: 10.1080/10520295.2021.1924405.
 25. Monsees, T., Franz, M., Gebhardt, S., *et al.* Sertoli cells as a target for reproductive hazards. *Andrologia*,(2000) 32(4-5), 239-246. doi.org/10.1046/j.1439-0272.2000.00391.x
 26. Shaaban, Z., Derakhshanfar, A., Shirazi, M. R. J., *et al.* The effects of letrozole-induced maternal hyperandrogenism on sexual behaviours, testicular histology, and serum biochemical traits in male offspring rats: An experimental study. *International Journal of Reproductive BioMedicine (IJRM)*, (2023) 21 (1):71-82. doi: 10.18502/ijrm.v21i1.12669.
 27. Simorangkir, D. R., Wreford, N. G., and De Krester, D. M. Impaired germ cell development in the testes of immature rats with neonatal hypothyroidism. *Journal of andrology*, (1997) 18(2), 186-193. DOI:10.1002/J.1939-4640.1997.TB01899.X
 28. Hess, R. and Nakai, M. Histopathology of the male reproductive system induced by the fungicide benomyl. *Journal of histology and histopathology*, (2000) 15: 207-224. DOI: 10.14670/HH-15.207
 29. Justin D. and Katherine M. Morphologic manifestations of testicular and epididymal toxicity. *Spermatogenesis*, (2014) 4(2): e979099. doi: 10.4161/21565562.2014.979099
 30. Moffit J., Bryant, B., Hall, S., *et al.* Dose dependant effects of sertoli cell toxicants 2,5-hexanedione, carbendazim, and mono-(2-ethylhexyl) phthalate in adult rat testis. *Toxicol pathol*, (2007) 35: 719-727. doi: 10.1080/01926230701481931.
 31. Dolores, D., and Yan Cheng C. The mammalian blood-testis barrier: its biology and regulation. *Endocr Rev*. (2015) 36(5): 564-591. doi: 10.1210/er.2014-1101.
 32. Wistuba, J., Mittag, J., Luetjens, C., *et al.* Male congenital hypothyroid Pax8-/- mice are infertile despite adequate treatment with thyroid hormone. *Journal of endocrinology*, (2007) 192(1): 99-109. doi: 10.1677/JOE-06-0054.
-

33. Khattab, F. and Khattab, I. Histological and ultrastructural studies on the testis of rat after treatment with aluminum chloride. *Aust J Basic /appl Sci*, (2007) 1(1), 63-72.
34. Lynda, L., Dianne, M., Robert, E., *et al.* Recommended approaches for the evaluation of testicular and epididymal toxicity. *Toxicol Pathol*, (2002) 30(4): 20-507. DOI: 10.1080/01926230290105695.
35. Wang S, Xu J, Zheng J, *et al.* Anti-Inflammatory and Antioxidant Effects of Acetyl-L-Carnitine on Atherosclerotic Rats. *J.Med Sci Monit.* 2020 Jan 16;26:e920250. doi: 10.12659/MSM.920250
36. Yadav, A., Yadav, K., Rajpoot, A., *et al.* Sub-chronic resistance stress exposure toin adult rats: an insight into possible inhibitory mechanism on testicular function in relation to germ cell dynamics. *Andrologia*, (2022) 54(11): e14575. doi: 10.1111/and.14575.
37. Türk, G., Ateşşahin, A., Sönmez, M., *et al.* Improvement of cisplatin-induced injuries to sperm quality, the oxidant-antioxidant system, and the histologic structure of the rat testis by ellagic acid. *Fertility and Sterility*, (2008) 89(5), 1474–1481. doi: 10.1016/j.fertnstert.2007.04.059.
38. Ilbey, Y. O., Ozbek, E., Cekmen, M., *et al.* Protective effect of curcumin in cisplatin-induced oxidative injury in rat testis: mitogen-activated protein kinase and nuclear factor-kappa B signaling pathways. *Human reproduction*, (2009) 24(7), 1717-1725. doi: 10.1093/humrep/dep058.
39. Ramadan, L. A., Abd-Allah, A. R., Aly, H. A., *et al.* Testicular toxicity effects of magnetic field exposure and prophylactic role of coenzyme Q10 and L-carnitine in mice. *Pharmacological research*, (2002) 46(4), 363-370. doi: 10.1016/s1043661802001718.
40. Sagar, S. M. Should patients take or avoid antioxidant supplements during anticancer therapy. An evidence-based review. *Current Oncology-Toronto*, (2005) 12(2), 44. doi: 10.1093/jnci/djn148.
41. Famularo, G., De Simone, C., Trinchieri, V., *et al.* Carnitines and its congeners: a metabolic pathway to the regulation of immune response and inflammation, *Ann. N. Y. Acad. Sci.*(2004) 1033: 132–138. doi: 10.1196/annals.1320.012.
42. Koopeyma, F., Gholizadeh, F., Hafezi, H., *et al.* The protective effect of L-carnitine on testosterone synthesis pathway, and spermatogenesis in monosodium glutamate-induced rats. *BMC Complementary Medicine and therapies*, (2022) 22(1): 1-7. doi: 10.1186/s12906-022-03749-0.
43. Palmero S, Bottazzi C, Costa M, *et al.*, Metabolic effects of L-carnitine on prepubertal rat sertoli cells. *Horm Metab Res*, (2000) 32, 87–90. doi: 10.1055/s-2007-978596.
44. Kobayashi D, Goto A, Maeda T, *et al.*, Octn2-mediated transport of carnitine in isolated sertoli cells. *Soc Reprod Fert*, (2005) 129: 729–736. doi: 10.1530/rep.1.00507.
45. Yifei L, Yu L, Siyi W, *et al.*, Identification and characterization of telocytes in rat testis. *Aging*, (2019) 11(15): 57575768. doi: 10.18632/aging.102158

المخلص العربي

التأثير العلاجي المحتمل لعقار الإل-كارنيتين ضد تلف الخصية الناجم عن الكلورامبيوسيل في الجرذان البالغة: دراسة نسيجية

ديانا عيد عزيز، نوال رزق الله، منة الله الرشيدى، أحمد صادق

قسم التشريخ والأجنة، كلية الطب، جامعة عين شمس، مصر

الخلفية: لقد أصبحت خطورة استخدام مضادات السرطان على الأنسجة الطبيعية قيد الدراسة بسبب الزيادة المضطردة فى استخدام هذه الأدوية. يرتبط الكلورامبيوسيل، وهو مضاد للسرطان، بآثار جانبية سامة على الخصيتين. قد يكون لعقار الإل-كارنيتين تأثير وقائي ضد مجموعة واسعة من تلف الخصية التي قد تتطور إلى حدوث عقم عند الذكور. **الهدف من الدراسة:** إثبات التأثير العلاجي المحتمل لعقار الإل-كارنيتين على تلف الخصية الناجم عن الكلورامبيوسيل. **المواد والطرق:** تم تقسيم ٤٠ جرذاً أبيضاً من الذكور البالغين إلى أربع مجموعات؛ مجموعة التحكم (مجموعة I)؛ مجموعة الإل-كارنيتين (مجموعة II)، حيث تتلقى الجرذان جرعة يومية (٥٠٠ ملجم/كجم) عن طريق الفم من الإل-كارنيتين؛ مجموعة الكلورامبيوسيل (مجموعة III) حيث تلقت الجرذان الكلورامبيوسيل بجرعة ٠,٢ ملجم/كجم يومياً عن طريق الفم عن طريق الأنبوب المعدي والمجموعة المشتركة (مجموعة IV) حيث تلقت الجرذان عقارى الإل-كارنيتين والكلورامبيوسيل بشكل مشترك. بعد ٢١ يوماً تم التضحية بجميع الفئران ثم تم وزن خصيتها ومعالجتها ووضعها فى كتل بارافينية وإعدادها للفحص تحت المجهر الضوئي.

النتائج: أحدث الكلورامبيوسيل تغييراً قوياً فى بنية الخصية والذي يتضح من خلال التفريغ الظهاري المنوي والخلخلة وضمور فى الخلايا الجرثومية ووجود خلايا عملاقة متعددة النوى. كما كانت هناك نسبة عالية من تلف الأنابيب ونقص ارتفاع الظهارة الجرثومية وغياب الحيوانات المنوية فى تجاويف الأنابيب المنوية. وقد أظهر الفحص النسيجي لعينات المجموعة المشتركة تحسناً كبيراً فى تلف الخصية التي يعكسها إحصائياً الانخفاض الكبير فى عدد الأنابيب التالفة. بالإضافة إلى ذلك كانت هناك زيادة كبيرة فى وزن الخصية مع زيادة ارتفاع الظهارة الجرثومية بالمقارنة مع مجموعة الكلورامبيوسيل.

الإستنتاج: يمكن لعقار الإل-كارنيتين أن يحمي من تلف الخصية الناجم عن تعاطى الكلورامبيوسيل فى الجرذان.