

PREVALENCE OF AN OUTBREAK OF CHICKEN INFECTIOUS ANAEMIA VIRUS IN SHARKIA

A. A. ABOU ZEAD * and I. E. MOHAMED

Poultry Diseases and Pathology Units

Animal Health Research Laboratory, Zagazig

Received: 15. 3. 2003

Accepted: 9. 11. 2003

SUMMARY

Two isolates of suspected virus are obtained from different broiler flocks 2-3 week in age. These broiler flocks had problems suggestive of chicken infectious anaemia (CIA) such as poor flock performance, poor weight gain, anaemia and increased mortality.

The identification of the virus strains as CIAV is based on:

1- The lesions recorded in naturally infected chickens were compatible with those reported for CIA (thymus atrophy, yellow bone marrow, anaemia and haemorrhage).

2- These lesions were also reproduced in chickens inoculated with materials treated with chloroform and passed through 50 nm filters.

3- Low haematocrite value of naturally and experimentally infected chickens under investigation (27%).

- 4- Inoculation of embryonated chicken eggs via yolk sac.
- 5- Isolated virus strains did not agglutinate chicken and/or sheep erythrocytes (RBCs).
- 6- The isolates induced histo-pathological lesions which were a reflection of macroscopic observations.
- 7- These findings are the characteristic lesions of the virus and demonstrate that CIAV is present in some flocks in Sharkia.

INTRODUCTION

Chicken infectious anaemia was first described in Japan by Yuasa et al. (1979). CIA is an icosahedral virus, 25 nm in diameter which on the basis of its circular single-stranded DNA genome, has recently been classified in the family, Circoviridae (Todd et al., 1996).

CIA is characterized by severe anaemia and lymphoid depletion followed by thymus atrophy, bone marrow aplasia, low haematocrite values and reduced body weight (McNulty, et al., 1991). The presence of CIA has been confirmed in recent years in Egypt, Zaki and El Sonousi (1994) and El-Shahedy et al. (1997).

During the last 5 years, an increasing number of broiler flocks in Sharkia were reported to have problems suggesting of CIA and the complications described. Materials were obtained from some of these flocks for further study.

Hence, this study described the isolation, identification, serological and pathological determination of chicken infectious anaemia (CIAV) in some flocks in Sharkia and experimental infection of one day old chickens for confirmative diagnosis of CIAV. The experimental chicken were subjected to further clinical, serological, pathological, haematological examinations.

MATERIAL AND METHODS

1- Flocks history:

In Sharkia province two flocks of broiler meat chickens (9500 birds) 2-3 weeks in age, they were obtained from 2 private farms, showed increased mortality, anaemia reduction in body weights and poor performance (Table 1).

2-Samples:

A total of thirty chicks, 15 from each flock were subjected to virological, haematological and pathological examination for the presence of CIAV infection.

3- Virus isolation, propagation, titration and characterization:

a- Chicken infectious anaemia virus propagation:

Field isolates were propagated by homogenization and disruption of liver, spleen, thymus, bone marrow and rectal content by two freeze/thaw cycles from the natural infected chickens, the homogenates were clarified by low-speed centrifugation. The supernatant fluid was extracted with chloroform and part was filtered through 50 nm filters according to Yuasa et al. (1983). Twenty percent of the supernatant was inoculated in the yolk sac (Y/S) of embryonated chicken eggs at 5 days incubation. Antigen(s) were obtained from whole embryos harvested 14 days later for detection CIAV antigen(s), after 3rd passage this antigen served as field strains and used for experimental infection according to Bülow and Witt (1986).

b-Virus titration:

The virus titration was done by intra-abdominal inoculation (I/P) of 10 fold serial dilutions (0.2 ml/bird) from each isolates into one-day old native Egyptian breed chickens that proved to be free from CIAV.

At 14 days post inoculation chickens are characterized to be infected with CIAV when they had a haematocrite value $<27\%$ and/or discoloured anaemic bone marrow according to Otaki et al. (1991) and chicken infective dose (CID₅₀) was calculated.

4- Haemagglutination of CIAV:

Haemagglutination ability of CIAV to agglutinate chickens and sheep erythrocytes were evaluated using both rapid slide and microplate method with 0.5% or 0.1% erythrocyte suspensions at pH 6.5 and 7 at ambient temperature or at 4°C following 30, 60, 120 or 240 minutes according to Rosenberger and Cloud (1989).

5-Experimental infection:

Thirty one day-old broiler chicks obtained from 34 week old Egyptian native baladi breed proved to be free from CIAV, were divided into 3 equal groups (1-3). Two out of them (groups 1-2), were challenged with the 2 field isolates that obtained during natural outbreaks by intra abdominal I/P injection, using 0.1 ml/bird of CIAV suspension containing chicken infective dose (CID₅₀) 103.1. Uninoculated group (group 3) was kept separately as chicks control group. At 7 and 14 days post inoculation, blood samples were collected to estimate packed cell volume (PCV) and to collect serum. Chickens were examined for infection with CIAV by determination of haematocrite val-

ue (Todd et al., 1995) and presence of discoloured anaemic bone marrow and/or thymus atrophy according (Otaki et al., 1991).

6-Blood examination:

Blood from each bird was collected in heparinized tube for estimation packed cell volume according to Jain (1993).

7-Serology:

All chickens were bled and serum was collected and stored at -20°C until used. Serum antibodies were detected with the chicken anaemia virus antibody test kit (IDEXX Laboratories, Inc, Westbrook, ME) according to the manufactures instructions.

8-Histopathology:

Livers, spleen, thymus, bursa of Fabricius, and kidney were collected from field cases, inoculated and control chickens, were fixed in 10% neutral buffered formalin, paraffin-embedded, sectioned as 5 micron thick, stained with haematoxylin and eosin, and examined by light microscopy according to Bancroft et al. (1996).

RESULTS

Flock history:

CAV infection was demonstrated in 2-3 week old broiler chickens originated from various parent flocks in Sharkia, manifested anorexia, depres-

sion, blue wing or anaemic dermatitis like syndrome. Total loss in the broiler flock was estimated at 9-13%. About 20% of the infected chickens failed to reach target body mass by the 8th week of life (Table 1).

Grossly, affected birds have focal skin lesions. Subcutaneous and intramuscular haemorrhages especially in the shoulder joints (both uni- and bilateral, elbow joints (Fig. 1), but may be present on the thigh and breast in small percentage of cases (Fig. 2). The skin turn blue and breaks, releasing a serosanguinous exudate, leading to gangrenous dermatitis. Anaemia associated with atrophy of haemopoietic tissues was also recorded. The colour of bone marrow specially of femur bone was yellow and paleness (Fig. 3). Most prominent lesion which attracts attention is the haemorrhages in and around the proventricular glands. The thymus lobes showed very distinct atrophy. Bursa of fabricius also slightly atrophied (Table 1 and Fig. 4). The blood of anaemic chickens were slow to coagulate. Bone fragility lead to fractures and epiphysiolysis.

Table (2) showed that the haematocrite values of naturally infected broiler chickens varied from 9-29% in flock (1) with a mean of $12.4 \pm 1.7\%$ and 10-18% with a mean of $14.6 \pm 0.8\%$ to flock 2, showing that 1 out of 30 (3.3%) over the cut-off (27%).

The isolated, CIAV isolates did not agglutinate chicken and/or sheep erythrocytes.

Histopathology of naturally infected chickens with CIAV:

Severe depletion of the lymphocytes in the thymic cortex was seen Figs. (5 and 6). The cortical thymic lymphocytes disappeared and were replaced with reticular cells in some cases. Reduction of the medullary lymphocytes were also seen (Table 2). Moderate lymphocytic depletion was detected in the follicles of bursa of fabricius Figs. (7 & 8). Marked necrosis and depletion of the hematopoietic cells in the bone marrow. The white pulps of the spleen showed mild lymphocytic depletion. The liver and kidney, showed edema and congested blood vessels beside hydropic degeneration of its cells.

Clinical signs of experimental infected chicken:

Inoculation of susceptible 1 day-old chicks with CIAV-positive tissue extracts from naturally diseased broiler caused pathological changes characteristic of CIAV infection. The first clinical signs of disease usually developed towards the second week of life. Birds are anorexic and depressed, with pallor of the comb and wattles, ruffled feathers and impaired growth and an increased daily mortality ensues, overall mortality is 10% (15% male and 3% female) and morbidity rate about 30%, Peak mortality occurs within 4-5 days of onset of disease signs, and mortality has often de-

returned to normal levels after a further 5-7 days, i.e. clinical signs changes of the experimental infected chicks were similar to those of naturally occurring CIAV induced infectious anaemia in young chicken except that skin lesions were not a feature of the experimental disease. None of the uninoculated controls (G3) developed any sign of CIA (Table 3).

Haematocrite values of experimentally infection:

Haematocrite levels measured at 14 days of age has a normal levels of over 28% in only 1 of 10 the CIAV inoculated chicken tested of Group 2 (G2) only (10%), while the all birds of Group 1 (G1) has no positive haematocrite levels over 28% i.e., 19:20 (95%) were considered of low haematocrite values in the 2 inoculated groups (No. 1 & 2), where the mean of G1 was 19.3 ± 0.1 with a range of 12-23% and 11-29% with a mean of 21.4 (0.7%) for group (2), whereas the haematocrite value over 33% in the control group (Uninoculated control No. 3) (Table 6).

Serology:

Sera collected from each inoculated chicks in periods ranging from 7 and 14 d.p.i were pooled and tested for antibodies to CIAV. Sera were negative for CIAV antibodies.

Histopathology of experimentally infected with CIA:

One week after infection, the major pathologic changes in the bone marrow, represented by hypocellularity with increased number of fat cells beside atrophy and aplasia of the haemopoietic tissue Fig. (9 and 10). Some cases showed activation of the amyloid tissue Fig. (11), atrophy of the thymic cortex and medulla were seen with severe depletion in the lymphocyte Fig. (12). Scattered necrotic foci were detected in the outer cortex followed by repopulation with lymphoid cells starting from 2 weeks after infection. The follicles of bursa of Fabricius became atrophied with lymphocytic depletion. Proliferation of inter follicular tissue was seen in some cases. Fig. (13). Atrophy, degeneration and necrosis of the white pulp of spleen were seen with severe depletion in the lymphocytes Fig. (14). The liver showed mild congested blood vessels, hemorrhages and edema with cloudy swelling of the hepatic cells with lymphocytic infiltration. The hepatocytes suffered from fatty changes 2 weeks post infection. Fig. (15). Kidney showed cloudy swelling in the epithelial lining of the renal tubules Fig (16).

None of the uninoculated controls (G3) developed lesions and all had haematocrite values varying from 30 to 36% (Table 7).

Evaluation of pathogenicity of field isolates of CIAV:

When criteria such as development of anaemia, paleness of bone marrow and thymus atrophy

were considered, it was apparent that following inoculation of field CIAV isolates produced anaemia in 6 of 10 (60%) chicks and 4 of 10 chick (40%) respectively, the proportion of bird that had pale bone marrow (80% and 70%) for groups (1 & 2), atrophied thymus 90% and 80% respectively, atrophied bursa 20% for groups (1) and (2).

Association of thymic atrophy with CIAV:

Thymic atrophy was present in 72.2% of samples positive for CIAV isolate (1) and 61.1% for isolate (2) (Table 7).

Association of bursal atrophy with CIAV:

Bursal atrophy was present in 24.3% of samples positive for CIAV for isolate No. 1 and 28.6% for isolate (2) as in Table (7).

Table (1): History, post mortem lesion of naturally infected broiler chickens with CIAV in Sharkia Governorate.

Flock No.	Age/ week	Clinical signs of flock %	Mortality /flock %	Thymus atrophy%	Bursa of fabricius atrophy %	Yellow bone marrow %	Anaemia (pale muscles and visceral organs) %	Skin lesion %	Haemorrhages of muscles joints %
1	3	30%	13%	13/15 (86.7%)	4/15 (26.7%)	11/15 (73.3%)	5/15 (33.3%)	2/15 (13.3%)	6/15 (40%)
2	2	20	9%	9/15 (60.7%)	4/15 (26.7%)	12/15 (80%)	7/15 (46.7%)	0	7/15 (46.7%)

Table (2): Haematocrite values and histopathological investigation of naturally infected broiler chickens with CIAV in Sharkia Governorate.

Flock No.	Haematocrite values				Histopathological changes		
	Range of 15 samples	Mean±SE of 15 samples	No. of samples with haematocrite value below the cut-off (27%)	%	Thymus/ samples	Bursa of fabricius/ samples	Bursa of fabricius/ samples
1	9-29%	12.4±1.7%	14/15	93.3%	13/15 (86.6%)	5/11 (45.5%)	12/14 (85.7%)
2	10-18%	14.6±0.8%	15/15	100%	9/11 (81.8%)	N.D*	11/15 (75.3%)

N.D= not done.

Table (3): Clinical signs and Macroscopic lesions in chickens experimentally inoculated with CIAV isolates at 1 day of age.

Isolate	No. of chicken inoculated	Mortality rate during 14 days PI	No. of chickens with anaemia	No. of birds with thymus congestion	No. of chicken with pale bone marrow	No. of chicken with thymic atrophy	No. of bursal congestion	No. of chicken with bursal atrophy	Haemorrhage in poventric ulus	Haemorrhage muscles
1	10	1 (10%)	6/10 (60%)	0/10 (60%)	8/10 (80%)	9/10 (90%)	0/10	2/10 (20%)	2/10 (20%)	1/10 (10%)
2	10	1 (10%)	4/10 (40%)	1/10 (10%)	7/10 (70%)	8/10 (80%)	0/10	2/10 (20%)	0/10 (0%)	0/10 (0%)
Control	10	0 (0%)	0 (0%)	0/10	0 (0%)	0 (0%)	0/10	0 (0%)	0/10 (0%)	0/10 (0%)

Cont. Table (3):

Kidney paleness	Liver paleness	Spleen congestion	Spleen atrophy
3/10 (30%)	5/10 (50%)	0/10	5/10 (50%)
2/10 (20%)	6/10 (60%)	0/10	4/10 (40%)
0/10	0/10	0/10	0/10

Table (4): Percentages of histopathological changes in the tissue examined (spleen, thymus, and bursa of Fabricius) in experimentally infected chickens with CIAV.

	Haemorrhages	Lymphocytic depletion
Spleen	0%	93%
Thymus	25%	97%
Bursa	0%	91%

Table (5): Histopathologic changes in the liver of experimentally infected chickens with CIAV.

	Cs	H	LI	N
Infected groups*	0	4	34	0
Control	0	0	0	0

Cs = Cloudy swelling

H = haemorrhage

LI = Lymphocytic infiltration

N = Necrosis

* = Values are the percentages of birds showing lesions in all groups (n=10).

Table (6): Haematocrite values of birds experimentally infected with CIAV.

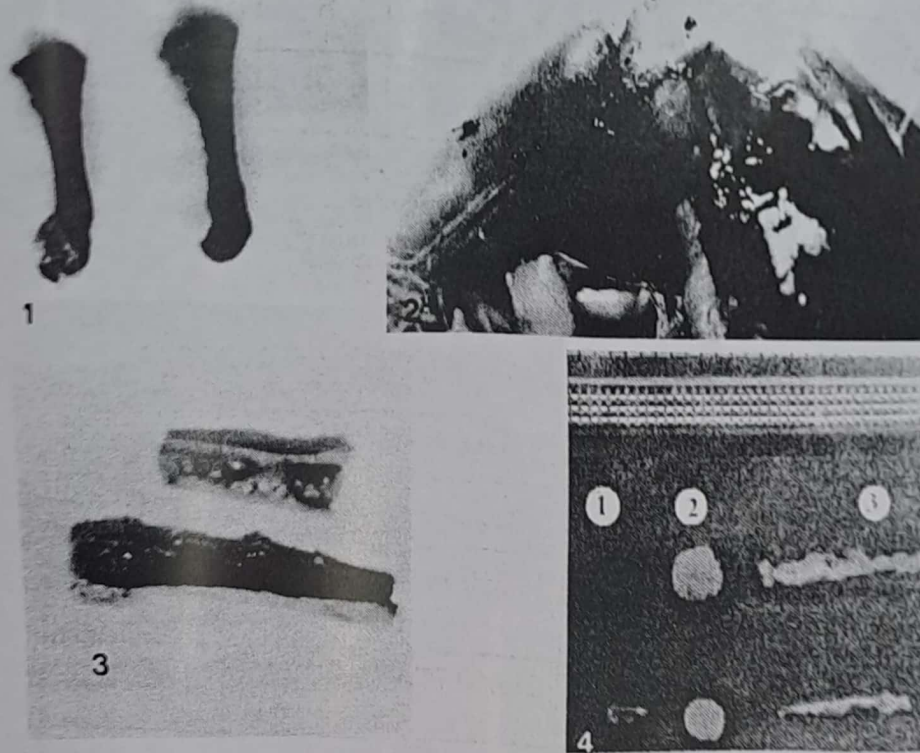
Group	No. of birds	Haematocrite values			
		Range	Mean	Range	Mean
1	10	12-23%	19.3±0.1%	0/10	100%
2	10	11-29%	21.4±0.7%	9/10	90%
3	10	31-36	33.9±1.2	0/10	0%

Table (7): Evaluation of pathogenicity of field isolates of CIAV.

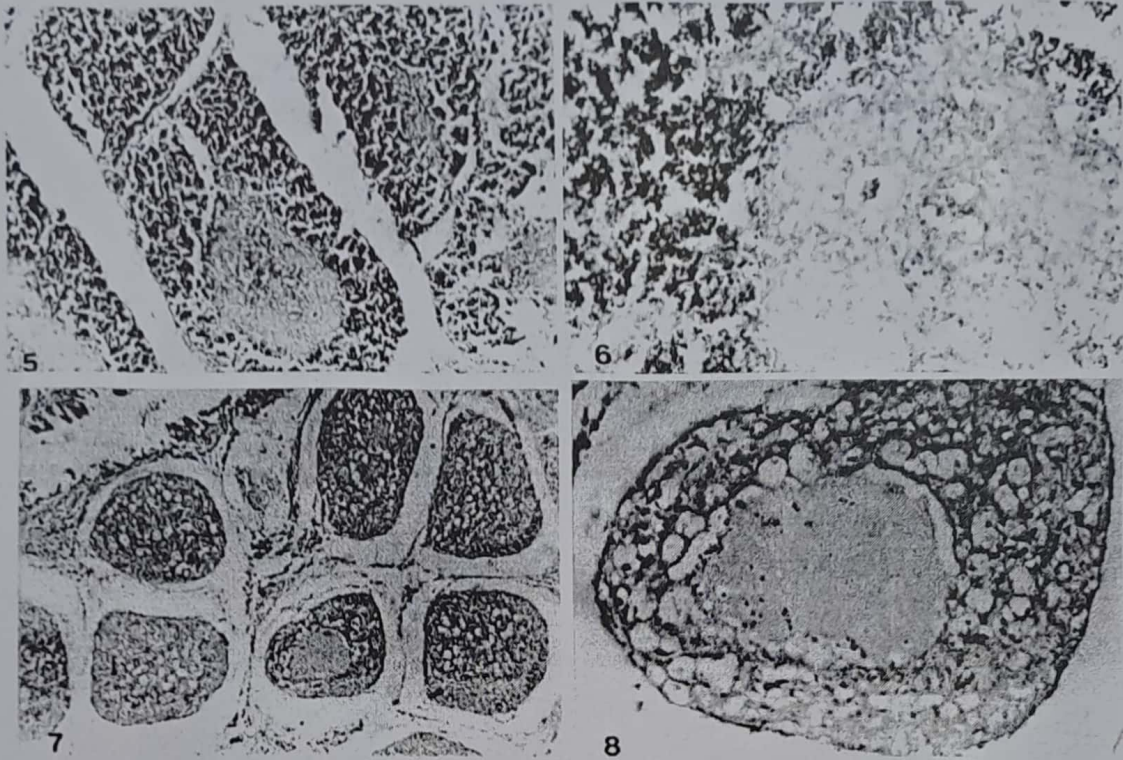
Isolate	No. of birds inoculated	No. of birds with anaemia	No. of birds with pale bone marrow	No. of chickens with thymic atrophy*	No. of chickens with bursal atrophy**	Haematocrite values less than 28%	Commutative ratio for evaluation
1	10	6/10 (60%)	8/10 (80%)	9/10 (90%)	2/10 (20%)	10/10 (100%)	6/10 + 8/10 + 9/10 + 0/10 + 10/10 = 35/50 (70%)
2	10	4/10 (40%)	7/10 (70%)	8/10 (80%)	2/10 (20%)	9/10 (90%)	4/10 + 7/10 + 8/10 + 2/10 + 9/10 = 30/50 (60%)
Control (3)	10	0 (0%)	0/10 (0%)	0/10 (0%)	0/10 (0%)	0/10 (0%)	0/50 (0%)

* Association of thymic atrophy with CIAV = $\frac{6}{10} + \frac{8}{10} + \frac{2}{10} + \frac{10}{10} = \frac{26}{40} = 65\%$ - $\frac{65}{90} = 72.2\%$ for isolate (1) and 61.1% for isolate (2).

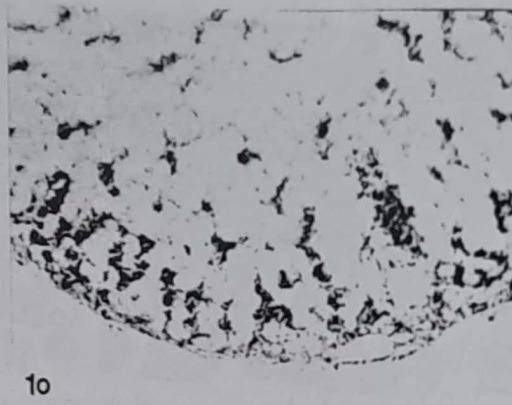


** Association of bursal atrophy with CIAV $\frac{6}{10} + \frac{8}{10} + \frac{10}{10} = \frac{33}{40} = 82.3\%$ = $\frac{20}{82.3} = 24.3\%$ for isolate (1) and 28.6% for isolate (2).



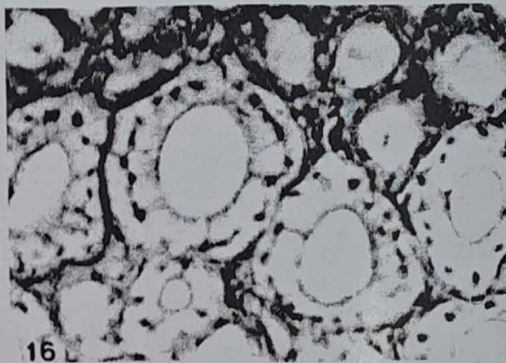
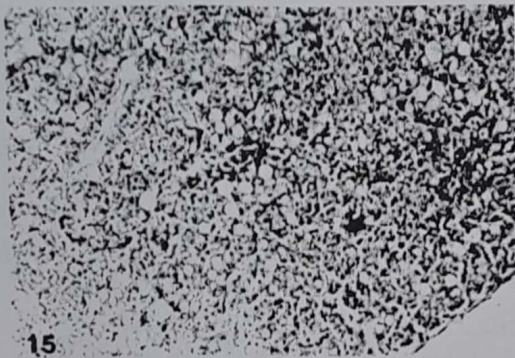
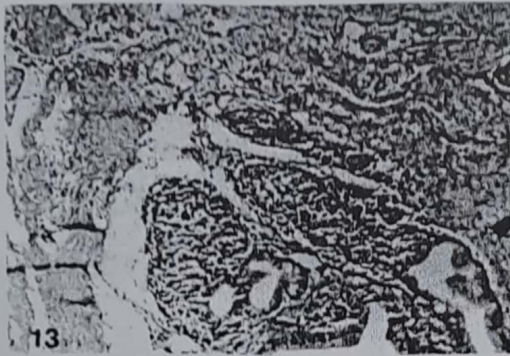
- Fig. (1): Incisions in the shoulder joint reveals haemorrhage.
- Fig. (2): Haemorrhages in thigh and leg muscles in chicken associated with chicken infections anaemia.
- Fig. (3): Examination of femoral bone marrow of affected chickens with CIAV (top) reveals distinct paleness when compared with normal darkened bone marrow (bottom).
- Fig. (4): Normal control spleen (1), bursa (2) and thymus (3) (top) compared with spleen, bursa and thymus with CIAV-induced atrophy (bottom), where the thymus lobes show very distinct atrophy while bursa of Fabricius and spleen are slightly atrophic.



- Fig. (5): Thymus showing follicles with depletion of thymocytes with atrophy of the follicles (H & E. x150).
- Fig. (6):The high power of the previous figure showing depletion of thymocytes (H. & E. x300).
- Fig. (7):Bursa of Fabricius, showing depletion of lymphocytes in the lymphoid follicles (H. & E. x150).
- Fig. (8):The high power of the previous figure showing the depletion of lymphocyte in the center of the follicle (H. & E. x300).



- Fig. (9): Bone marrow showing hypocellularity with increased No. of fat cells (H. & E. x150).
Fig. (10): Bone marrow showing atrophy of haemopoietic tissue (H. & E. x150).
Fig. (11): Bone marrow showing activation of the amyloid tissue. (H. & E. x150).
Fig. (12): Thymus showing depletion of thymocytes. (H. & E. x150).



- Fig. (13): Bursa of Fabricius showing proliferation of the interfollicular tissue (H. & E. x150).
Fig. (14): Spleen showing depletion of lymphocytes in the white pulp.
Fig. (15): Liver, showing fatty change (H. & E. x150).
Fig. (16): Kidney showing cloudy swelling of the epithelial lining of the renal tubules. (H. & E. x600).

DISCUSSION

The history of natural outbreaks of CIAV showed that first three weeks of life chickens became more susceptible to the infection (table 1). This agreed with that reported by Yuasa et al. (1979), Engstrom and Luthman (1984), Yuasa and Imai (1986), Bulow and Witt (1986), Conner et al. (1991) and Zaki and El-Sonousi (1994).

Age related resistance to clinical disease after first three weeks is also has been reported, Yuasa et al. (1979); Rosenberger and Cloud (1989), McNeilly et al. (1994) and Todd et al. (1995) they reported that birds infected after 2 weeks post-hatching fail to develop clinical signs. This resistance in older birds to the disease has been attributed to the disappearance of susceptible cells, Jeurissen et al. (1992) or, alternatively, to increase in the immunity of the older birds and subsequently a more effective humoral immune response. Yuasa et al. (1983) or, more likely, to increase immunocompetence, Hu et al. (1993). They reported that embryonally bursectomized (Ebx) chickens developed signs and lesions typical of CIA when infected with CIA-1 isolate of CIAV at 21 or 38 days. In both cases, the chickens had low haematocrite values after the 14th day of infection and the percentage of CD4+ and CD8+ cells in the thymus was markedly reduced at 21 days post inoculation. Even though intact chickens became in-

fectured, they never developed low haematocrite values. The data support the hypothesis that age-related resistance to CIA is antibody-mediated and is not due to disappearance of the CIAV target cells, the data also suggest that CD4+ and CD8+ cells are the target of infection.

The mortality rate varied in the naturally infected chickens was between 9-13% (Table 1), but the experimentally infected chickens was 10% (Table 3). This difference could be attributed to challenge dose virulence of the CIAV, route of exposure, presence of stress factors (either bacterial, other viral, environmental and managemental) and difference in age, Yuasa et al. (1979), Otaki et al. (1987), Engstrom (1988), presence of maternal antibodies, McNulty et al. (1991) and/or difference of breeds of chickens.

CAV infection under field circumstances have usually a subclinical course, but reduce the growth of the chickens, agreed with that reported by McNulty et al. (1991). The presence of other chicken pathogens under field condition, however, may create a different situation for example, dual infections of very young chickens with CAV and various chickens pathogens such as Marek's disease virus (MDV), reticuloendotheliosis virus, adenovirus, reovirus, infectious bursal disease (IBD) colestridial infection, and Newcastle disease resulted in aggravation of the mortality ascribed to the other agent, (Bulow et al., 1986; Engstrom, 1988 and De Boer et al., 1994).

Skin lesions are more severe in field outbreaks. Extravasation of serosanguinous fluid from skin lesions occur only in the natural disease, but not in the experimental disease, this agreed with that reported by Engstrom (1988) that this due to mixed infection of CAV with secondary infection which do not normally occur under experimental conditions. Examples of these gangrenous dermatitis (Bisgaard, 1983; Vielitz and Landgraf, 1988) Colibacillosis (Goryo et al., 1987). This support the hypothesis that CIAV infection plays a role in disease syndromes complicated by other viral, bacterial or fungal infection (Lynn et al., 2000).

Very little information is available on genetic resistance or susceptibility to CIAV. Most studies on the pathogenesis of CIAV have been done in SPF chickens of undetermined or variable genetic background, Carol et al. (2000). In one comparative study on viral antigen distribution in thymic tissue, CIVA antigen was more extensively distributed in S13 chicken than in P2a chicken after experimental infection. The studies between genetic strain and humoral response to CIAV which may translate to the reported increase in susceptibility to CIAV infection in the S13 strain, (Hu, 1992).

Our study showed that CIAV was propagated in chicken embryo following yolk sac inoculation, viral antigen(s) were obtained after 14 days from

all parts of the embryo. Lesions observed after inoculation were rare in about 20% of total inoculated embryo including embryo being haemorrhagic, oedematous and stunted, this agreed with that reported by Bülow and Witt (1986).

The results revealed that 2 isolates did not agglutinates chicken and sheep erythrocytes at pH 6.5 and 7 ambient temperature or at 4°C this agreed with that reported by Rosenberger and Cloud (1989).

Inoculation of susceptible 1-day-old chickens with a CIVA positives tissue extracts from naturally diseased broilers caused pathological changes characteristic of CIAV infection (Table 3 and Figs. 5-14), namely marked atrophy of thymus, where the thymic atrophy is the most consistent, but bone marrow atrophy the most characteristic lesions. Bursal atrophy is less obvious in small proportion of birds, agreed with Goryo et al. (1985), impaired growth, intramuscular haemorrhages (Fig. 2) and severe anaemia (Fig. 3), bone fragility and epiphysiolysis (separation of an epiphysis from its bone), these results agreed with that reported by Bülow et al. (1983); Otaki et al. (1987); Goryo et al. (1989); Farkas et al. (1992) and Mohamed (1998). This may be due to, the multiplication of the CAV in the haematopoietic cells of the bone marrow lead to bone fragility causing of fractures and epiphysiolysis. This results in erosion of the epiphysis of the humerus

femur which causes bleeding (Mohamed, 1998).

Haematologically, the reduction in PCV (Table 6) were similar to that reported by McNulty (1991); De Boer et al. (1994) and Todd et al. (1995) can be explained by the preference of CAV for thymocytes on the one hand and for haematopoietic precursor cells on the other is of great interest for the understanding of the CAV pathogenesis. Taniguchi et al. (1983) have suggested that the erythropoietic function of the bone marrow is under control of T. lymphocytes, so that depletion of T. lymphocytes would cause a reduced proliferation of erythroblasts.

The anaemia in experimentally infected birds is due to inhibition of the haemopoietic function of the bone marrow caused by destruction of thymic lymphocytes, (Taniguchi et al. 1983). However, Goryo et al. (1989) suggested that CIAV is directly cytotoxic for bone marrow haematopoietic precursor cells. Haemorrhage due to CAV caused haematocrite values, counts of thrombocytes, mature erythrocytes and white blood cells declined (Heterophil and lymphocytes), subsequently hypoplasia, aplasia or more correctly atrophy of the haematopoietic tissues in the bone marrow, (Bülow and Witt (1986).

Sera collected from experimentally inoculated chickens at 7-14 days post infection were nega-

tive for CIAV antibodies by ELISA test. The absence of CIAV antibodies in sera from inoculated chickens was reported, by Yuasa et al. (1983), they reported that seroconversion in chick inoculated at 1 day of age generally occurred only after 3 or more weeks post-infection.

No significant difference were found between inoculated groups (1 and 2) and control (3) in major production parameters such as sex feed manufacturer, type of litter and age of slaughter. However, group3 achieved 14% greater in net income, 4% better feed conversion ratio and 5.5% greater average weight per bird than groups (1 & 2) (data not shown). These results showed that subclinical CIAV infection has a substantial, significant effect on commercial broiler performance and profitability.

The main histopathological changes produced by CIAV have been characterized as generalized lymphoid atrophy and thus agreed with reported by Bülow et al. (1986), Goryo et al. (1989) and Tanguchi et al. (1983). The bone marrow was depleted from lymphocytes as well as the thymus, spleen, bursa of Fabricius. Cortical thymic lymphocytes disappeared and were replaced by reticular cells. Medullary lymphocytes were also reduced in number. This agreed with Goryo et al. (1989) and McNulty (1991). The lesions produced by CAV, 1st week post infection occurred due to a reduction in number of mature erythrocytes and hemopoietic cells in the bone marrow and

depletion of cortical thymic lymphocytes. Subsequently, lymphocyte depletion occurs in the spleen and the medulla of the thymus, (Toro et al., 2000). The swelling of hepatocytes and epithelial lining of the renal tubules were observed at the highest of the anaemic phase of the disease, and thus mainly due to hypoxia caused by the disease. These agreed with that reported by Taniguchi et al. (1982), Goryo et al. (1989) and Jones et al. (1997).

Researches has shown that, *in vivo*, CAV replicate in precursor T-cells in the thymus and mature T-lymphocytes in the spleen (Jeurissen et al., 1992). Evidence has been presented that CAV also infects a population of bone marrow cells that are not T-lymphocytes and this population may well be a precursor cells of erythroblastoid origin (Adair et al., 1993). Histopathological investigations of CAV-infected chicks in our study support this view, this agreed with that reported by Smyth et al. (1993) and Taniguchi et al. (1983).

In the recent past, anatomic and clinical pathological diagnosis of so-called chicken anaemia agent (CAA) infections have been based on lesions such as anaemia and haematopoietic organ atrophy (HOA). This study indicated that, splenic atrophy and bursal atrophy were of low association (24.3% for isolate 1 and 28.6% for isolate 2) (Table 7), while high association 72.2% for isolate

(1) and 61.1% for isolate (2) were seen in thymic atrophy (Table 7).

This study regarding only HOA and anaemia is not only sufficient to allow pathologists to diagnose CIAV in broiler chickens submitted to diagnostic laboratories:

- 1- The isolation and identification of the virus strain(s) as CIAV is based on: the clinical signs and lesions recorded in naturally infected chickens were compatible with those reported for CIA, Yuasa et al. (1979); Taniguchi et al. (1983); Engestron and Lothman (1984) and Otaki et al. (1987).
- 2- The lesions were also reproduced in 1-day old chickens inoculated with material treated with chloroform and passed through 50-nm filter, these agreed with that reported by Yuasa et al. (1983).
- 3- Decreased haematocrite levels were reported in the two CIAV-infected groups at 14 days of age, this is similar to that reported by De Boer et al. (1994) and Todd et al. (1995).
- 4- Inoculation of embryonated chicken eggs via yolk sac gave the lesions similar to that mentioned by Bûlow and Witt (1986).
- 5- The isolated virus strains in our study did not agglutinate chickens and/or sheep RBCs, this results were also registered by Rosenberger and Cloud (1989).
- 6- Histopathological changes observed in the internal organs in both naturally and experimen-

tally infected chickens similar to that reported by Taniguchi et al. (1982); Otaki et al. (1987); McNulty et al. (1989); Lucio et al. (1990) and Smyth et al. (1993).

The results reported here provide evidence of the occurrence of CIAV in some flocks at Sharkia. It will be important to determine the impact of its presence on the poultry industry. The distribution of CIA in the country. Its role on poultry diseases "vaccination failures" and the real value of the presence of antibodies against CIA disease.

REFERENCES

Adair, B.M.; McNeilly, F.; McConnell, C.D.G. and McNulty M.S. (1993): Characterization of surface markers present on cells infected with chicken anaemia virus in experimentally infected chickens. *Avian Diseases* 37: 943-950.

Bancroft, J., Stevens A. and Turner D. (1996): *Theory and practice of histological technique*. 4th ed., Curchil Livingstone Co., London.

Bülow V., Fuchs B., Vieliz E. and Landgraft H. (1983): Frühsterblichkeitssyndrom bei kuken nach cloppelintekion mit dem virus der marekschen trankhirt (MDV) und einem Anamieer reger (CAA). *Zentral blatt für Veterinar Medizin* B30.

Bülow V. von and Witt M. (1986): Vermehrung des Erregers der aviaren infektiösen Anämie (CAA) in embryoierten Hühnereiern. *Journal of Veterinary Medicine*, B33, 644-664.

Bülow V. von, Rudolph R. and Fuchs B. (1986): Erhöhte Pathogenität des Erregers der aviären infektiösen anämie Hühnerkuken (CAA) bei simultaner Infektion mit virus der marekschen krankheit (MDV), Bursistisvirus (BDV) oder reticuloendotheliosevirus (REV). *Journal of Veterinary Medicine*, B33: 93-116.

Carol Cardona, B., Lucio, P.O Connell, Gara Gagne and K. A. Schat (2000): Humeral immune response to chicken infectious anaemia virus in three strains of chickens in a closed flock. *Avian disea.* (44) 661-667.

Connor T.J., McNeilly, F., Firth G.A. and McNulty M.S. (1991): Biological characterization of Australian isolates of chicken anaemia agent. *Australian Veterinary Journal* 6: 199-201.

De Boer, G.F.; D.J. Van Roozelaar, R.J. Moormann, S.H.M. Jeurissen, J.C. Van Den Wijngaard, F. Hilbink (1994): Interaction between chicken anaemia virus and live Newcastle disease vaccine. *Avian Path.* (1994), 23: 263-275.

El-Shahedy M., Ghanem I. and Ibrahim A. (1997): Contribution on experimental infection with chicken janaemia agent (CAA) in chickens and its influence on ND vaccination. *Zag. Vet. J.*, 24 (4): 1-11.

Engstrom B. and Luthman M. (1984): Blue wing disease of chickens. Signs, Pathology and Natural transmission. *Avian pathology* 13, 1-12.

Engstrom B. (1988): Blue wing disease of chickens: isolation of avian reovirus and chicken anaemia agent. *Avian Path.* 17: 23-32.

Farkas, T.; Dren, C.; Nemeth, I.; Dobos-Kovacs, M.; Povazsan, J. and Saghy, E. (1992): isolation of chicken anaemia virus from broiler. *Acta. Vet. Hung* (1992), 40

- (3): 207-223.
- Goryo M., Shibata Y., Suwa T., Umemura T. and Itakura C. (1987): Outbreak of anaemia associated with chicken anaemia agent in young chicks. *Japanese Journal of Veterinary Science*, 49: 867-873.
- Goryo M., Sugimura H., Matsumoto S., Umemura T. and Itakura C. (1985): Isolation of an agent inducing chicken anaemia. *Avian Pathology* 14: 483-496.
- Goryo M., Suwa T., Umemura T., Itakura C. and Yunashiro S. (1989): Histopathology of chickens inoculated with chicken anaemia agent (MsB1-TK5803 strain). *Avian Path.* 18: 73-89.
- Hu, L. B (1992): Role of humoral immunity and T cell sub-population in the pathogenesis of chicken infectious anaemia. M. Sc. Thesis Cornell Univ. Ithaca, Ny.
- Hu, L.B.; B. Lucio, and K.A. Schat (1993): Abrogation of age-related resistance to chicken infectious anaemia by embryonal bursectomy. *Avian Dis.* (37): 157-169.
- Jain N. (1993): Essential of veterinary hematology. Lea and Febiger, Philadelphia.
- Jeurisson, S.H.M.; Jonse, M.E.; Van Roozelaar, D.J.; Koch, G. and De Boer, G.F. (1992): Susceptibility of thymocytes for infection by chicken anaemia virus is related to pre-and posthatching development. *Developmental Immunology*, 2: 123-129.
- Jones T.C., Hunt R.D. and King N. W. (1997): *Veterinary pathology*, 6th ed. Williams and Wilkins. Baltimore, Philadelphia, London, Paris.
- Lucio B., Schat K. and Shiva H. (1990): Identification of chicken anaemia agent, reproduction of the disease and serological survey in the United States. *Avian Dis.* 34: 146-153.
- Lynn T. Hagood, Tamara F.K.; James C.W. and Frederic J.H. (2000): Evaluation of chicken infectious anemia virus and associated risk factors with disease and production losses in broilers. *Avian Dis.* (44); 803-808.
- McNeilly, F.; B.M. Adair and M.S. McNulty (1994): In vitro infection of mononuclear cells derived from various chicken lymphoid tissue by chicken anaemia virus. *Avian Path.* (1994), 23: 547-556.
- McNulty, M.S.; Connor, T.J.; McNeilly, F. and Spackman, D. (1989): Chicken anaemia agent in the United State: isolation of the virus and detection of antibody in broiler breeder flocks. *Avian Diseases*, 33: 691-694.
- McNulty, M.S.; McIlroy S.G.; Bruce, D.W. and Todd, D. (1991): Economic effects of subclinical chicken anaemia agent infection in broiler chickens. *Avian Dis.* (1991), 35 (2): 263-268.
- McNulty, MS. (1991): Chicken anaemia agent: a review. *Avian Path.* (20): 187-203.
- Mohamed A. (1998): CAV and broiler downgrading. *Poult International*, April, 30 (1998).
- Otaki Y., Kazuko Saito, Tajima M. and Nomura Y. (1991): Detection of antibody to chicken anaemia agent: a comparison of three serological tests. *Avian Path.* (1991), 20: 315-324.
- Otaki Y., Tajima M., Saito K. and Nomura Y. (1987): Isolation of chicken anaemia agent and Marek's disease virus from chicken vaccinated with turkey herpes virus and lesions induced in chicks by inoculation both agents. *Avian Pathology*, 16: 291-306.
- Rosenberger, J.K. and Cloud, S.S. (1989): The effects of age, route of exposure and coinfection with infectious bursal disease virus on the pathogenicity and transmissi-

- ability of chicken anemia agent (CAA). *Avian Dis.* 33: 753-759.
- Smith, J.A.; Moffett, D.A.; McNulty, M.S.; Todd, D. and Mackie, D. (1993): A sequential histopathologic and immunocytochemical study of chicken anaemia virus infection at one day of age. *Avian Dis.* (37): 324-338.
- Taniguchi T., Yuasa N., Maeda M. and Horiuchi T. (1982): Haematopathological changes in dead and moribund chicks induced by chicken anaemia agent. *National Institute of Animal Health, Quarterly*, 22: 61-69.
- Taniguchi, T.; Yuasa, N.; Maeda, M. and Horiuchi, T. (1983): Chronological observations on haematopathological changes in chicks inoculated with chicken anaemia agent. *National Institute of Animal Health Quarterly*, 23: 1-12.
- Todd D., Connor T.J., Viola M., Calvert, Julie L. Creelan, Mehan, B.M. and McNulty M.S. (1995): Molecular cloning of an attenuated chicken anaemia virus isolate following repeated cell culture passage. *Avian path.* 24: 171-187.
- Todd, D.; Creelan, J.L.; Mehan, B.M. and McNulty M.S. (1996): Investigation of the transfection capability of cloned tandemly-repeated chicken anaemia virus DNA fragments. *Arch. Virol.* (1996) 141, (8): 1523-1534.
- Toro, H.; Gonzalez, C.; Cerda, L.; Hess, M.; Reyes, E. and Geisse, C. (2000): Chicken anemia virus and fowl adenoviruses : Association to induce the inclusion body hepatitis / hydropericardium syndrome. *Avian Dis.* (44): 51-58.
- Vielz E. and Landgraf H. (1988): Anaemia-dermatitis of broilers: Field observation on its occurrence, transmission and prevention. *Avian Path.* 17: 113-120.
- Yuasa, N. and Imai, K. (1986): Pathogenicity and antigenicity of eleven isolates of chicken anaemia agent (CAA). *Avian Path.* 15: 639-645.
- Yuasa, N.; Taniguchi, T. and Yoshida, I. (1979): isolation and characteristics of an agent inducing anaemia in chicks. *Avian Dis.* 23: 366-385.
- Yuasa, N.; Taniguchi, T.; Imada, T. and Hihara, H. (1983): Distribution of chicken anaemia agent (CAA) and detection of neutralizing antibodies in chicks experimentally inoculated with CAA. *National Institute of Animal Health Quarterly*, 23: 78-81.
- Zaki M. and El-Sanousi A. (1994): Chicken anaemia agent in Egypt. I. A serological survey of antibodies against chicken anaemia agent in some commercial chicken flocks using indirect immunofluorescent. *Vet. Med. J. Giza* 42 (3): 53-58.