

Administration of olive oil optimizes acetic acid induced colitis in CD1 mice

Mohamed L. Salem^{1,2,*}, Ehab M. Tousson³ and Dina Abd El Aziz Ali³

¹Immunology and Biotechnology Division, Zoology Department, Faculty of Science, Tanta University, Egypt.

² Center of Excellence in Cancer Research, Tanta Teaching Hospitals.

³ Zoology Department, Faculty of science, Tanta University, Egypt.


ABSTRACT

Colitis is a chronic disease that affects individuals at different ages and affects the quality of their life. So far, there are three different experimental models for colitis. However, animals in these models die quickly due to the associated toxicity. The aim of this study is to optimize acetic acid induced acute colitis mouse model with olive oil co-administration. Male albino CD1 mice (n= 91) were randomly divided into 13 groups (n= 7/group). To induce colitis, mice were administered with different volumes (100 or 200 µl) and concentrations (1%, 2% and 4%) of acetic acid by intrarectal (IR) injection either for three consecutive days or every other day for a total of 6 days. Olive oil (1 µL) was co-injected with acetic acid. One day later, mice were sacrificed and colon tissues were fixed in 10% formalin for histological examinations. The induction of colitis by acetic acid was dependent on both the volume and the concentration of acetic acid. Interestingly, co-administration of olive oil with different volumes and concentrations of acetic acid, although did not alter the severity of inflammation, it increased the animal survival rate and decreased the associated toxicity. Injection of co-administration of olive oil with acetic acid is a new modification to enhance the application of this model.

Keywords: Acetic acid, Colitis, colon, model.

Abbreviation: IBD; Inflammatory Bowel Diseases, CD; Crohn's Disease UC; Ulcerative Colitis.

ARTICLE INFO



Article history:

Received: April 24, 2018

Revised: May 18, 2018

Accepted: May 29, 2018

Correspondence to:

Dina Abd El Aziz Ali, M.Sc.
Department of Zoology,
Faculty of Science, Tanta
University, Egypt.
Tel: +02-01023102726
E-mail:
dinaabdelaziz123@yahoo.com

INTRODUCTION

Inflammatory bowel diseases (IBD), including Crohn's disease and ulcerative colitis (UC) have a high incidence in industrialized nations and severely affect the life quality of patients (Amosy and Koma 2013). These diseases are defined clinically through inflammatory disorder in gastrointestinal tract accompanied with diarrhea, abdominal pains,

weight loss, nausea and pathological changes such as a loss of mucosal integrity and inflammatory cell infiltration (Xavier et al., 2007). In addition, the presence of white blood cells at the intestinal mucosal tissue is characteristic feature of this disease (Wang et al., 2005). Colitis affects the distal colon portion and induces non-transmural inflammation, massive necrosis of mucosal and

sub-mucosal layers, neutrophil infiltration of the mucosa and sub-mucosal ulceration (Randhawa et al., 2014).

Induction of colitis might be as a result of the exposure to different inflammatory agents and due to production of free radicals (Hanauer et al., 1996; Hanauer et al., 2006). Additionally, free radicals reduce antioxidant agents and thus increase the severity of the disease (Radko et al., 2007). Due to the activation of W. B. Cs and free radical production in the intestinal mucosal tissues, lipid peroxidation is elevated and may cause an inflammation (Bhattacharyya et al., 2014), resulting in increasing the permeability of blood vessels, the entrance of neutrophils to the site of inflammation and finally caused an expansion of the inflammatory area in the intestinal mucosal tissue (Cekici et al., 2014). Furthermore, the release of inflammatory mediators and certain enzymes cause intestinal damage, injury, bleeding and diarrhea (Gasche et al., 2004). To treat colitis, the conventional therapeutic agents, for instance, the anti-inflammatory agents such as mesalazine, corticosteroids and immunosuppressive agents which act as non-specific drugs have been used to reduce inflammation and the immune responses (John et al., 2011).

So far there are three identified models used to induce experimental colitis in rats and mice (Antonioni et al., 2016). These models include DSS, oxalone and acetic acid (MacPherson et al., 1978; Boirivant et al., 1998; Kawada et al., 2007). Although acetic acid-induced colitis is a good model to study the efficacy of compounds with potential anti-colitis (Cetinkaya et al., 2005; Tahan et al., 2011), induction of this model associates with severe injury, which leads to mortality in less than a week (Elson et al., 1995), limiting its application since it does not mimic the clinical setting in human.

Therefore, optimizing this model to be more specific may help to test new effective treatments. With regard to the third model, there are a large number of reports that describe compounds that can ameliorate acetic

acid-induced colitis (Choudhary et al., 2001, Karawya and Metwally 2016). Several compounds such as N-acetyl cysteine, trimetazidine, vitamin E, and melatonin were evaluated in acetic acid induced colitis model to decrease the reactive oxidative species (Wang Q et al., 2013; Uraz S et al., 2013).

The present study was conducted to induce a clinically relevant UC model by intrarectal (IR) administration of olive oil in combination with acetic acid doing induction of colitis. The results showed that injection of a 100 μ L of 4% acetic acid in combination with olive oil every other day for 6 days induced well characteristic colitis in mice but with less toxicity and better survival.

MATERIALS AND METHODS

Mice

Male Albino mice (n = 91) weighed 25 ± 2 g were acclimatized for one week before the study. Mice were purchased from housed in the Animal facility, Faculty of Science, Tanta University, Egypt. Animals were kept and maintained under a 12 h light/ 12 h dark cycle at a constant temperature ($22 \pm 2^\circ\text{C}$) with a relative humidity of $55 \pm 5\%$. The experimental protocol was approved by the institutional Ethics Committee of the use of animals in research of Faculty of Science, Tanta University, Egypt.

Reagents and chemicals

Acetic acid was purchased from Sigma Chemical Co., (St. Louis, Mo., USA) and reconstituted according to the manufacture description, and then diluted with saline to prepare 1, 2 and 4%. Olive oil (50 μ L) was obtained from Sigma Chem. Co., (St. Louis, Mo., USA), 50 μ L was mixed with 50 ml of acetic acid (1, 2 and 4% v/v in 0.9% saline)

Induction of ulcerative colitis

Mice were administered with IR injection of 100 μ L or 200 μ L of 1, 2 and 4% acetic acid in combination with 1 μ L of olive oil. Immediately, after administration, the mice were held horizontally for 2 min to prevent fluid leakage. Control animals were underwent similar procedure using equal volume of olive

oil instead of acetic acid as shown in Figure (1,3).



Figure 1: Photomicrograph showed normal appearance of mouse anal opening dilated by inserting the retractor into the ano-rectum. polyurethane cannula (external diameter 2 mm) was inserted into 3 cm proximal to the anus and instilled with an acetic acid solution.

As shown in Diagram 1, 13 groups were divided as follow: Gp1 to Gp7 were treated every other day for 6 days with olive oil (Gp1) or with different volumes and different concentrations of acetic acid in combination with 1 µL of olive oil (Gp2 to Gp7). While the Gp8 to Gp13 were treated similarly to Gp2 to Gp7 but for three consecutive days.

After 7 days of the 1st IR treatment, mice were fasted overnight and then anaesthetized by an intraperitoneal (i.p.) injection before sacrificing. The colon was excised extended proximally 2cm above anus opening (Morris *et al.*,1989).

Histological preparation

Colon tissues from all the experimental groups were excised and cleaned by 0.9% saline and immediately fixed in 10% buffered formalin. For histological preparations, the colon tissues were washed until complete removal of formalin with running water. Tissues were then hydrated using different ascending concentrations of ethyl alcohol (50, 60, 70, 80, 90 and 100%) and then embeded by using 1:1 xylene: wax and 100% wax. Thin sections (5 µm) were cut from the different blocks and processed according to the regular protocol for staining by eosin and hematoxylin (Bancroft *et al.*, 1994). Finally, the stained sections were mounted on glass slides for histological examination by light microscopy and photographed.

RESULTS

Clinical symptoms

Injection with different volumes and concentration of acetic acid in the presence of olive oil led to some clinical symptoms which indicated to the presence of colitis such as bleeding as shown in Figure 2a, weight loss (data not shown) and diarrhea (Figures 3 a, b). As shown in Figure 4a, administration of acetic acid and olive oil led to induction of ulcerative colitis.

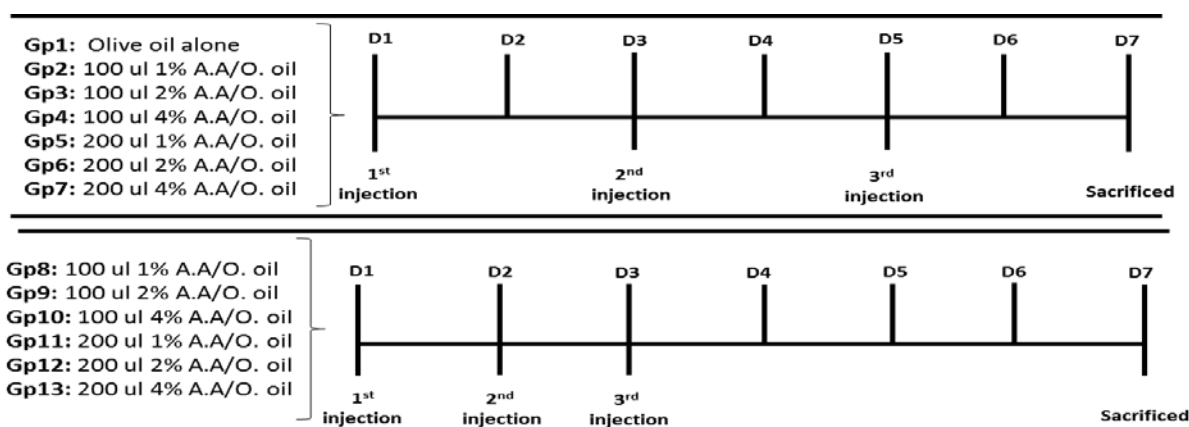


Diagram 1: Shows the experimental diagram the 13 groups under the study, A, A; acetic acid, O. Oil; olive oil.

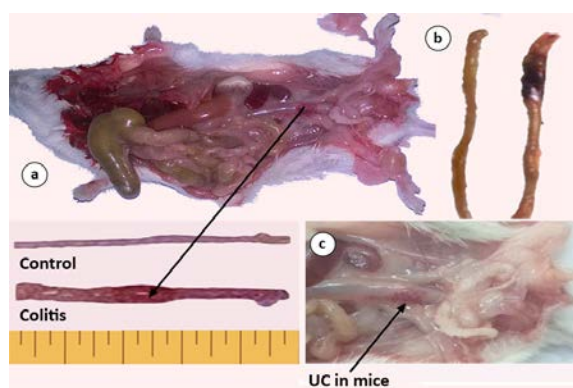


Figure 2: a) Photomicrograph showed that acetic acid-induced ulcerative colitis, b) Photomicrograph showed the colon inflammation associated with bleeding, clearly showed control group and colitis group. c) Photograph showed the induction of colitis in mice treated with acetic acid and olive oil.

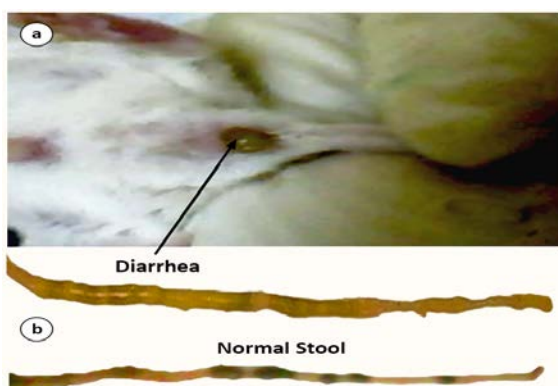


Figure 3: a) after acetic acid induction all the mice eventually had diarrhea increased over time, outside of the anus. b) Photomicrograph showed the stool consistency. a: normal appearance of stool in control colon & diarrhea in colitis colon.

Histopathological changes of colitis induced by acetic acid.

To investigate the pathological changes in the colon tissues in the different groups (Gp1 to Gp13), the microscopic examination was conducted. The results showed H and E stained colon sections of control group (Gp1) revealed normal histological structures of the different layers of the colon. The colon mucosa showed normal intestinal crypts lined by epithelial columnar cells and goblet cells. The lamina propria contained few mucosal mast cells full of cytoplasmic granules (Fig. 4 a). Investigation of colon sections of groups of mice treated with different volumes and concentrations of acetic acid showed a variety of histological

abnormalities in colon structure, which clearly indicated to the induction of colitis of these groups. The present study clearly showed that intrarectal (IR) administration of 100 μ L acetic acid combined with 1 μ L of olive oil into male albino mouse induced colitis in groups as measured by the grade of ulcers as compared to control (Figs. 4, b-f and 5 a-f). Of note, the IR administration of 200 μ L acetic acid of different concentrations (1, 2 and 4%) led to high mortality as compared to 100 μ L (data not shown).

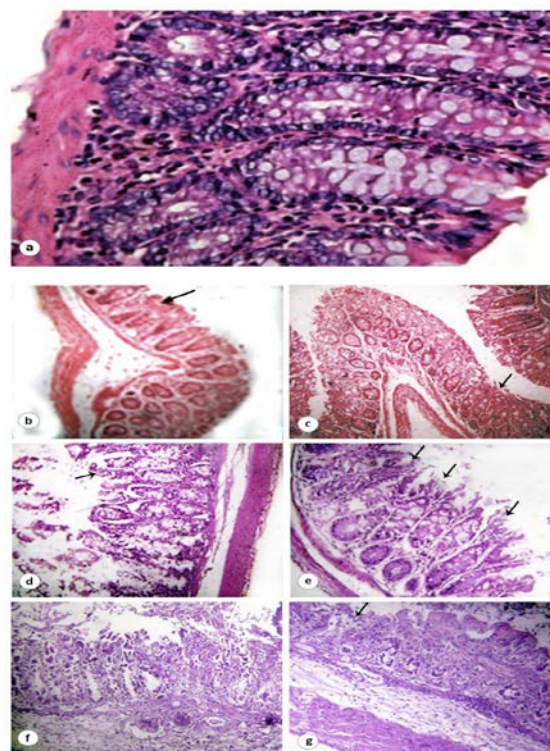


Figure 4: a) Hematoxylin and Eosin sections showed the histological structure of colon mouse in control group. (Gp1) injected with olive oil every other day for 6 days showed normal histological structure. (100X). (b-e) Hematoxylin and Eosin sections showed the histopathological changes in colon of mice treated with different volumes and concentration of acetic acid with tiny volume of olive oil for 3 successive days. b: Mice treated with 100 μ L acetic acid revealed mild colitis (arrows) in colon mucosa with mild inflammations. c: Colon sections in treated mice with 100 μ L of 2% acetic acid revealed moderate colitis (arrows). d: Colon sections of treated mice with 100 μ L of 4% acetic acid revealed moderate colitis (arrows). e-g: Colon sections in treated mice with 200 μ L of 1%, 2%, 4% acetic acid, respectively, revealed strong damage in colon with marked inflammation (stars) and colitis (arrows). b - f (200X), f (400X).

Abnormal structures in all layers of colon were found in particular, a marked epithelial cell damage was found represented by the form of epithelial separation, cellular loss, congestion of blood vessels, crypt hyperplasia and focal depletion of goblet cells. Additionally, severe mononuclear cellular infiltration in lamina propria in the muscularis mucosa and the submucosa were observed (Fig. 4 b-g). Interestingly, these abnormalities in colon were increased with the increase of acetic acid concentrations

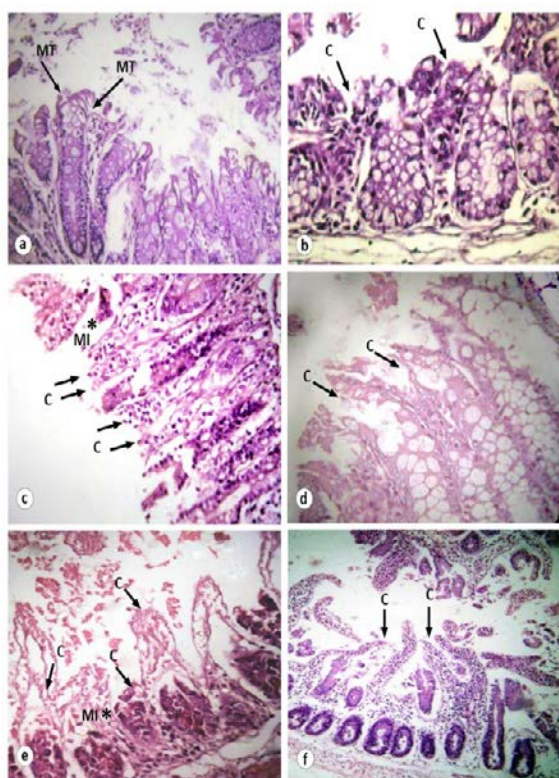


Figure 5: Hematoxylin and Eosin sections showed the histopathological changes in the colon in mice treated with different concentration of acetic acid every other day for 6 days. **a:** Mice treated with 100 μ L of 1% acetic acid revealed mild a trophy (arrows) in colon mucosa with mild inflammations. **b-f:** Colon sections in treated mice with 100 or 200 μ L of 1% 2% and 4% of acetic acid, respectively, revealed strong damage in colon with marked inflammation (stars) and colitis (arrows). **a – f** (200X), **d** (400X).

As shown in Figures 5 a-f, and 2c, the changes in the colon in mice treated with different concentrations of acetic acid every other day for 6 days with 100 μ L of 1% acetic acid revealed mild a trophy (arrows) in colon

mucosa with mild inflammations. The results showed that colon sections in treated mice with 100, 200 μ L acetic acid at concentrations of 1% 2% and 4% induced a strong damage in colon with marked inflammation (stars) and colitis, respectively (Figure 5 b-f. Interestingly, treatment with different concentrations of acetic acid induced diarrhea which increased with the time after the treatment as shown in Figure 1 and 3 b. associated with bleeding as seen in Figure

DISCUSSION

Colitis is IBDs are chronic and relapsing inflammatory disorders of the gastrointestinal tract combined with diarrhea, weight loss and nausea and by different pathological features such as a loss of mucosal integrity and inflammatory cell infiltration (Xavier et al., 2007). So far, there are three identified models used to induce experimental colitis in rat and mice (Bramhall 2015; Almeida et al., 2017). These models include DSS, oxalone and acetic acid (MacPherson et al., 1978; Boirivant et al., 1998; Kawada et al., 2007). Concerning the third model, there are a large number of reports that, described the possibility of several potential compounds can ameliorate acetic acid-induced colitis (Lean et al., 2015). Other studies showed also that, many drugs as well as diet could worsen or improve colonic functions and symptoms according to type and severity of colitis (Valdez et al., 2000). Several compounds such as N-acetyl cysteine, trimetazidine, vitamin E, and melatonin were tested by using acetic acid colitis model to decrease the reactive oxidative species (Kurutas et al., 2005). On the other hand, other colitis models is accompanied by side effects. some critical parameters and troubleshooting as DSS-induced colitis model depends on numerous key factors, including DSS source, molecular weight, concentration, duration, mouse strain, source, age, gender and body weight as well as environmental factors including the hygienic condition of the vivarium (Nell et al., 2010). The aim of present study was to establish a clinically relevant ulcerative colitis model that induced by different

concentrations of acetic acid. In this study, the results showed that the IR administration with acetic acid in combination with olive oil into male albino mouse induced colitis. This indicating that acetic acid damage was effective and had the ability to increase the abnormalities in the intestinal mucosal tissues, mucosal injury, degeneration in epithelial cells of mucosa, depletion in goblet cells. Off note the presence of olive oil as a component of the treatment with acetic acid reduced the toxic effect of acetic acid upon the injection because of olive oil prevented the development of aberrant crypt foci and colon carcinomas, eating olive oil can improve the efficiency of intestines. Olive oil also encourages intestines to absorb more of the vitamins and minerals from the foods (Tsimidou *et al.*, 2015). Additionally, IR administration with acetic acid into male albino mouse increased the leucocytic infiltrations, abnormal changes in the intestinal crypt and a loss of mucosal integrity. Microscopic examination of colon tissues of mice are IR administrated with different concentrations with acetic acid in combination with tiny volume of olive oil showed an increase in the number of neutrophil and infiltration of inflammatory cells. Our finding was in agreement with previous studies which showed that acetic acid induced colon inflammation (Hartmann *et al.*, 2012). In conclusion having olive oil as a component of the injection with different volumes and concentrations of acetic acid induced colitis with less severity and low mortality rate. The results postulated that the combinatorial treatment with a 100 μ L of 4% acetic acid and a tiny volume of olive oil was the optimal to induced colitis.

REFERENCES

- Almeida ACA, Felipe MF, Ricardo JD, Luis Paulo Bognoni M, Alba R, Monteiro SB and Anderson LF (2017). Recent Trends in Pharmacological Activity of Alkaloids in Animal Colitis: Potential Use for Inflammatory Bowel Disease. Evidence-Based Complementary and Alternative Medicine e 8528210, 24.
- Amosy E and Koma M (2013). Inflammatory Bowel Disease: An Expanding Global Health Problem. Clin Med Insights Gastroenterol. 6: 33–47.
- Antoniou E, Margonis GA, Angelou A, Pikouli A, Argiri P, Karavokyros I, Papalois A and Pikoulis E (2016). The TNBS-induced colitis animal model: An overview. Ann Med Surg (Lond). 2016 Nov; 11: 9–15.
- Bancroft JD, Cook HC and Stirling RW (1994). Manual of Histological Techniques and Their Diagnostic Application. 4th ed, New York. 50 – 61.
- Bhattacharyya A, Chattopadhyay R, Mitra S and Sheila E. (2014). Oxidative Stress: An Essential Factor in the Pathogenesis of Gastrointestinal Mucosal Diseases. Physiol Rev. 2014 Apr; 94(2): 329–354.
- Boirivant M, Fuss IJ, Chu A and Strober W (1998) Oxazolone colitis: a murine model of T helper cell type 2 colitis treatable with antibodies to interleukin 4. J Exp Med., 188(10):1929–1939.
- Bramhall M, Oscar Flórez-Vargas, Robert Stevens, Andy Brass and Sheena Cruickshank (2015). Quality of Methods Reporting in Animal Models of Colitis. Inflamm Bowel Dis. 2015 Jun; 21(6): 1248–1259.
- Cekici A, Kantarci A, Hasturk H and Thomas E. V (2014). Inflammatory and immune pathways in the pathogenesis of periodontal disease. Periodontol 2000. 2014 Feb; 64(1): 57–80.
- Cetinkaya A, Bulbuloglu E, Kurutas EB, Ciralik H, Kantarceken B and Buyukbese MA (2005). Beneficial effects of N-acetylcysteine on acetic acid-induced colitis in rats. Tohoku J Exp Med., 206(2):131–139.
- Choudhary S, Keshavarzian A, Yong S, Wade M, Bocckino S, Day BJ and Banan A (2001) Novel antioxidants zolimid and AEOL11201 ameliorate colitis in rats. Dig Dis Sci 46, 2222–2230.
- Elson CO, Sartor RB, Tennyson GS and Riddell RH (1995). Experimental models of

- inflammatory bowel disease. *Gastroenterology*, 109(4):1344–1367
- Gasche C, Lomer M C E, Cavill I, and G Weiss4 (2004). Iron, anaemia, and inflammatory bowel diseases. *Gut*. 2004 Aug; 53(8): 1190–1197.
- Hanauer SB (2006). Inflammatory bowel disease: epidemiology, pathogenesis, and therapeutic opportunities. *Dis.*, 12: 3-9.
- Hanauer SB and Engl N (1996). Inflammatory bowel disease *J. Med.*, 334: 841-848.
- Hartmann RM, Morgan Martins MI, Tieppo J, Fillmann HS and Marroni NP (2012): Effect of *Boswellia serrata* on antioxidant status in an experimental model of colitis rats induced by acetic acid. *Dig Dis Sci.*, 57: 2038-2044.
- John K Triantafillidis, Emmanuel Merikas, and Filippos Georgopoulos (2011). Current and emerging drugs for the treatment of inflammatory bowel disease. *Drug Des Devel Ther.* 5: 185–210.
- Karawya FS and Metwally EA (2016). Effects of jujube fruit extract on acetic acid-induced colitis in adult male rats. *J Exp Clin Anat.* 15:19-26.
- Kawada M., Arihiro A. and Mizoguchi E. (2007). Insights from advances in research of chemically induced experimental models of human inflammatory bowel disease. *World J. Gastroenterol.*, 13(42):5581–5593
- Kurutas E B,1 Ali Cetinkaya,2,* Ertan Bulbuloglu,3 and Bulent Kantarceken4 Author information Article notes Copyright and License information (2005). Effects of Antioxidant Therapy on Leukocyte Myeloperoxidase and Cu/Zn-Superoxide Dismutase and Plasma Malondialdehyde Levels in Experimental Colitis. *Mediators Inflamm.* 2005 Dec 14; 2005(6): 390–394.
- Lean QY, Eri RD, Fitton JH, Patel RP, Gueven N (2015) Fucoidan Extracts Ameliorate Acute Colitis. *PLoS ONE* 10(6): e0128453.
- MacPherson BR and Pfeiffer CJ (1978). Experimental production of diffuse colitis in rats. *Digestion.*, 17(2):135–150.
- Morris GP, Beck PL, Herridge MS, Depew WT, Szewczuk MR and Wallace JL (1989). Hapten-induced model of chronic inflammation and ulceration in the colon. *Gastroenterology.*, 96:795–803.
- Nell S, Suerbaum S and Josenhans C (2010): The impact of the microbiota on the pathogenesis of IBD: lessons from mouse infection models. *Nature reviews. Microbiology.*, 8:564–577.
- Radko L and Cybulski W (2007) The investigation of silymarin effect on colon ulcer induced acetic acid in mice balb /C *J. Pre-Clin. Clin Res.*, 1(1): 022-026.
- Randhawa PK, Kavinder S, Nirmal S, Amteshwar SL (2014). A Review on Chemical-Induced Inflammatory Bowel Disease Models in Rodents. *Korean J Physiol Pharmacol.*; 18:279–288.
- Tahan G, Gramignoli R, Marongiu F (2011). Melatonin expresses powerful anti-inflammatory and antioxidant activities resulting in complete improvement of acetic-acid-induced colitis in rats. *Dig Dis Sci.*, 56(3):715–720.
- Uraz S, Tahan G, Aytekin H, Tahan V. (2013). N-acetylcysteine expresses powerful anti-inflammatory and antioxidant activities resulting in complete improvement of acetic acid-induced colitis in rats. *Scand J Clin Lab Invest.* 2013 Feb; 73(1):61-6.
- Valdez R, Appelman H, Bronner MP, et al. Diffuse duodenitis associated with ulcerative colitis. *Am J Surg Pathol* 2000; 24:1407–1413
- Wang J and Fu YX (2005). Stimulating lymphotoxin beta receptor on the dendritic cells is critical for their homeostasis and expansion. *Rev.*, 204: 144-155.
- Wang Q, Yongqing H, Dan Yi, Lei Wang, Binying Ding, Xing Chen, Minhui Long, Yulan Liu, and Guoyao Wu (2013). Protective effects of N-acetylcysteine on acetic acid-induced colitis in a porcine model. *BMC Gastroenterol.* 2013; 13: 133.

Xavier RJ and Podolsky DK (2007) Unravelling the pathogenesis of inflammatory bowel disease. Nature acetic acid able to induced pathological alterations in the different layers of colon tissues (Choudhary et al., 2001.,448:427-434.

Tsimidou, Maria, George Papadopoulos, and Dimitrios Boskou. "Phenolic compounds and stability of virgin olive oil-Part I." Food Chem 45.2 (1992): 141-4.