



ORIGINAL ARTICLE

Interlay Technique Tympanoplasty: Surgical Difficulties with Variable Grafts

Alaa El-Din Mohamed El-Feky¹, Magdy Kamel Abdelmaksod¹, Said Abdel-Monem Mohamed¹, Ramadhan Yousuf Ramadhan Abd Aldaem²

¹Otorhinolaryngology Department, Faculty of Medicine, Zagazig University, Zagazig, Egypt

²Otorhinolaryngology Department, Faculty of Medicine, Almergeb University, Libya

Corresponding Author:

Ramadhan Yousuf Ramadhan
Abd Aldaem

Otorhinolaryngology
Department, Faculty of
Medicine, Almergeb
University, Libya

E-mail:

ramadanabduldaim@gmail.com

ABSTRACT

Background: Perforation of the tympanic membrane is most commonly the result of chronic ear disease. However, it can also result from various forms of trauma, which includes iatrogenic and direct physical injuries, burns, scalds and pressure effects. Most of these perforations heal spontaneously, whereas the remaining long-standing perforations that lead to recurrent ear discharge need tympanoplasty. **Objectives:** the aim of this study was to evaluate the results of interlay technique of tympanoplasty with respect to graft uptake and hearing status and to compare surgical difficulties between variable grafts. **Patients and Methods:** A total of 20 Patients included in the study were 6 males and 14 females, their age ranged from 10 years to 50 years presented with dry large central tympanic membrane perforations being inactive for at least one month without treatment were operated by interlay myringoplasty. **Results:** In our study, we recorded the success rate to be 90% in interlay myringoplasty and this is in accordance with the success rate reported by other studies using interlay technique. **Conclusions:** Interlay tympanoplasty results in excellent graft uptake and good post operative air bone gap (ABG) closure. A main advantage of this technique includes prevention of anterior blunting, lateralization and medialization of graft. Interlay tympanoplasty abolishes chances of epithelial cyst formation as in overlay technique and myringitis due to endothelium overgrowth as in underlay technique

Keywords: Interlay Technique Tympanoplasty, Otitis Media, Tympanic Membrane.

INTRODUCTION

Perforation of the tympanic membrane is most commonly the result of chronic ear disease. However, it can also result from various forms of trauma, which includes iatrogenic and direct physical injuries, burns, scalds and pressure effects^[1]. Most of these perforations heal spontaneously, whereas the remaining long-standing perforations that lead to recurrent ear discharge need tympanoplasty^[2].

Chronic suppurative otitis media (CSOM) has a major impact on the social life of a person in the form of hearing disability^[3]. The discharge from the ear is also troublesome causing great discomfort to the patient. The mucosal type of CSOM can be treated surgically by tympanoplasty^[4,5].

Tympanoplasty is a procedure done to repair the defect in the tympanic membrane after eradicating all the disease in the middle ear cleft with or without reconstruction of ossicular chain^[6]. Type I tympanoplasty is a surgical technique that involves the repair of the tympanic membrane in cases where the only existing lesion is a tympanic membrane perforation. It is the most common otological procedure after myringotomy^[5].

It is classified based on the placement of graft in relation to the remnant tympanic membrane as: a) The underlay technique: graft is placed medial to the mucosal layer, b) The overlay technique: graft is placed lateral to the fibrous layer of tympanic membrane after elevating all squamous epithelium, and c) The interlay technique: graft is placed

between the fibrous layer and the endothelial (mucosal) layer of the drum remnant^[7].

Hypothesis:

We supposed that the interlay technique of myringoplasty, in terms of graft uptake and hearing improvement was effective and gave good results.

AIM OF THE WORK

The aim of the present study was to evaluate the results of interlay technique of tympanoplasty with respect to graft uptake and hearing status and to compare the difficulties during surgery between temporalis fascia and perichondrial grafts.

PATIENTS AND METHODS

This prospective study was conducted in ORL-HNS department, Zagazig University from November 2017 until November 2018. The study included 20 patients with large tympanic membrane perforation and all were subjected to repair of their tympanic membrane perforation by the interlay technique using perichondrial graft (from Concha or tragus) or temporalis fascia graft. Inclusion criteria: Age: From 10-50 years; Sex: Both males and females; Patients with large central (involving three or more quadrants) tympanic membrane perforation, dry tympanic membrane perforation for at least 6 weeks without treatment, has conductive hearing loss, with no ossicular chain pathology, and has no past history of ear surgery. Written informed consent was obtained from all patients and the study was approved by the research ethical committee of Faculty of Medicine, Zagazig University. The work has been carried out in accordance with The Code of Ethics of the World Medical Association (Declaration of Helsinki) for studies involving human.

Exclusion criteria: Patient with active foul smelling discharge, vertigo, tinnitus, granulation, or cholesteatoma; those having sensorineural hearing loss or mixed hearing loss; history of revision or combined procedures (mastoidectomy and ossiculoplasty), those having any deformity or congenital anomaly of the external ear, unusual infections such as malignant otitis externa or complication of chronic ear diseases (meningitis, brain abscess, lateral

sinus thrombosis), patients with upper respiratory tract infection.

A careful history is obtained from all patients. Otolaryngologic examination including otoscopic examination with the aid of microscope for better evaluation of the size of the perforation, the type of the perforation and condition of the middle ear mucosa. The detailed procedure will be explained in a vernacular language and those patients with an inactive CSOM. Investigations include routine haemogram, audiometry and anesthesia fitness. The cases with an active CSOM will be given a conservative treatment and underwent surgery after the ear became inactive. Patients with chronic sinus disease are treated for control of their condition before myringoplasty is planned. These contributing factors can usually be brought under control within four to six weeks while the patient is awaiting his otologic procedure. Hearing assessment was done using pure tone audiometry (PTA) and Tuning fork tests. Eustachian tube function (ETF): Eustachian tube function was assessed by Tympanometry.

A post auricular approach was used in all patients. Post auricular incision was started from the highest point of helix to mastoid tip approximately 5 mm behind the post auricular groove. Temporalis fascia or perichondrium (from Concha or tragus) was harvested and used as graft material. Freshening of the perforation; the edge of the perforation is first circumcised to freshen by using a hook and microcup forceps. Tympanomeatal flap was elevated circumferentially (up to the level of the fibrous annulus), except superiorly, in the region of head of malleus. Canalplasty was done in cases with a bony overhang obscuring the view of annulus. After taking the fibrous annulus out of the bony sulcus all around, using a curved blunt hook. Fibro-squamous layer of the remnant TM along with the annulus was elevated leaving behind the mucosal layer. The ossicles were inspected for continuity and the mobility was checked. Oto-endoscopy was done to inspect the middle ear cleft and ossicular status with Karl Storz HOPKINS Telescope 0° and 45°. Temporalis fascia or perichondrium graft was placed between the fibro-squamous and

mucosal layers of tympanic membrane; in such a fashion that it rested on the mucosal layer and bony canal all around and above the handle of malleus. The tympanomeatal flap was repositioned carefully, gel foam was kept in external auditory canal and the incision was sutured in two layers. On the day of surgery patient was kept on IV antibiotics (Ceftriaxone) and analgesics. Patients were discharged on 2nd post operative day. They received antibiotics for 2 weeks (Amoxicillin with clavulonic acid in first week and Roxithromycin in second week). Diclofenec sodium 50 mg was given twice a day for 5 days as an analgesic. Patients were called for follow up weekly up to 1 month and on every 15th day for next 2 months.

Postoperative follow up; the external packing was removed after one week. Removal of post-auricular incision sutures one week post-operative. Removal of the inner pack of ear canal after two weeks. Assessment for successful graft taking one month post-operative and PTA after three months.

STATISTICAL ANALYSIS

Data were checked, entered and analyzed using SPSS 20, software for Windows. Data were expressed as number and percentage for qualitative variables and mean + standard deviation (SD) for quantitative one. The significance level was set at $P < 0.05$. T-test was used for quantitative data, and chi-square test.

RESULTS

This is a prospective study carried on twenty patients with large central tympanic membrane perforation selected from the outpatient clinic, ENT Department, Faculty of Medicine, Zagazig University along the period from November 2017 to November 2018, they subjected to interlay myringoplasty, the results is tabulated in the following tables.

Table (1) showed that the mean age of the case group was (23.1 ± 8.8) ranged from (10-40) years and (70.0%) of them were females and (30.0%) were males. Table (2) showed that (60.0%) of the case group were right sided ear diseased, (50.0%) had temporalis fascia graft and (50.0%) had perichondrial graft, (70.0%) of the case group had the operation in less than 1 hour and (10%) had complications, complications have been recorded in 2 cases in the form of postoperative ear infection. The two cases have failed tympanoplasty and the other cases had successful graft uptake. No lateralization, no retractions, no myringitis, no canal stenosis, no blunting, no epithelial pearls, the surgical difficulties occurred in (30.0%) of cases. Surgical difficulties have been noted in 6 cases as follow: Difficult separation of mucosal layer and fibrous layer of TM in 4 cases, Anterior canal bulge (hump) in 1 case, Tympanosclerosis in 1 case and (70.0%) of the case group had the operation in less than 1 hour and (10%) had complications. Table (3) showed that there was highly statistically significant difference between the pre and post-operative mean ABG

Table (1): Socio-demographic characteristics of the case group

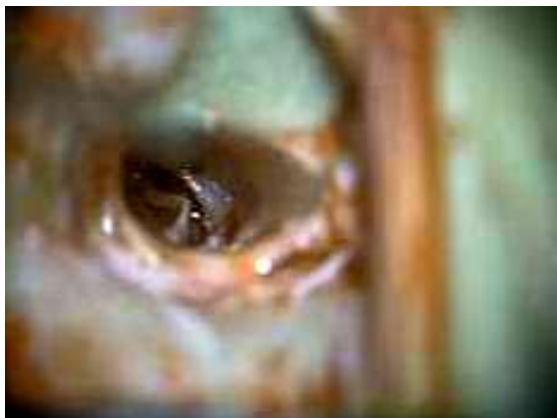Variable	The case group(20) mean \pm SD (Range)	
Age (years):	23.1 \pm 8.8 (10-40)	
Variable	NO(20)	%
Sex	6	30.0%
Male	14	70.0%
Female		

Table (2): Side of ear, type of graft, Time of surgery, complications, Percent of surgical difficulties and Percent of graft uptake in the case group

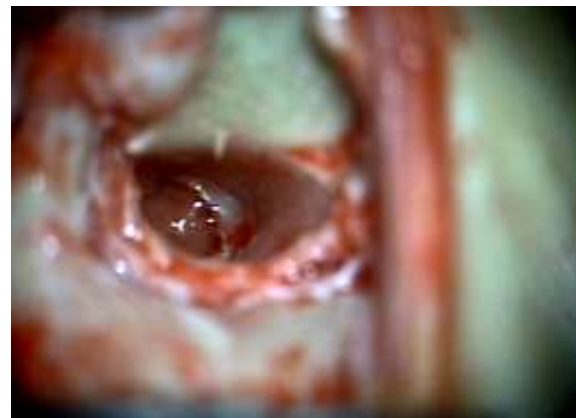Variable	NO (20)	%
Side of ear		
<i>Right</i>	12	60.0%
<i>Left</i>	8	40.0%
Type of graft		
<i>Temporalis fascia</i>	10	50.0%
<i>Perichondrial</i>	10	50.0%
Time of surgery		
<1 hour	14	70.0%
1.5 hour	6	30.0%
Complications		
No	18	90.0%
Yes	2	10.0%
Surgical difficulties		
No	14	70.0%
Yes	6	30.0%
Graft uptake		
Successful	18	90.0%
Failed	2	10.0%

Table (3): Comparing pre and post-operative Mean ABG (dB)

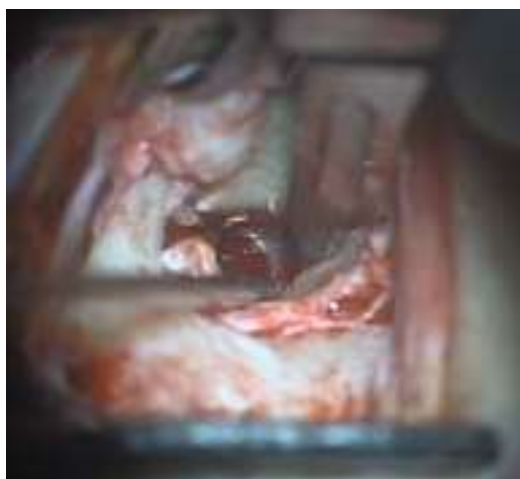
Variable	Pre-operative (20)	Post-operative (20)	paired t-test	p-value
ABG (dB) mean ± SD (Range)	23.2±7.1 (15-35)	11.4±3.9 (0.0-21.5)	8.6	0.001**



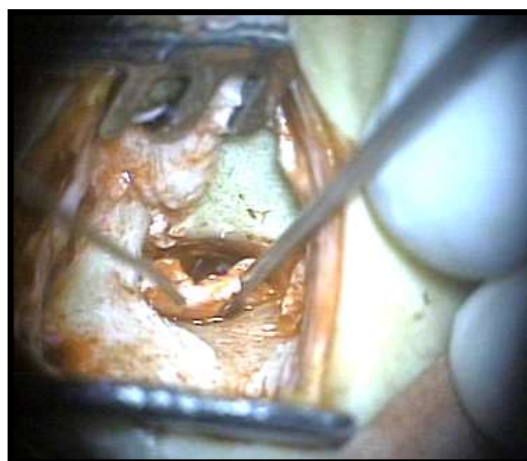
A



B



C



D

Figure 1. A; Refreshment of the perforation edge, B; Preoperative tympanic membrane perforation, C; Canal wall incision, D; Tympanomeatal flap elevation

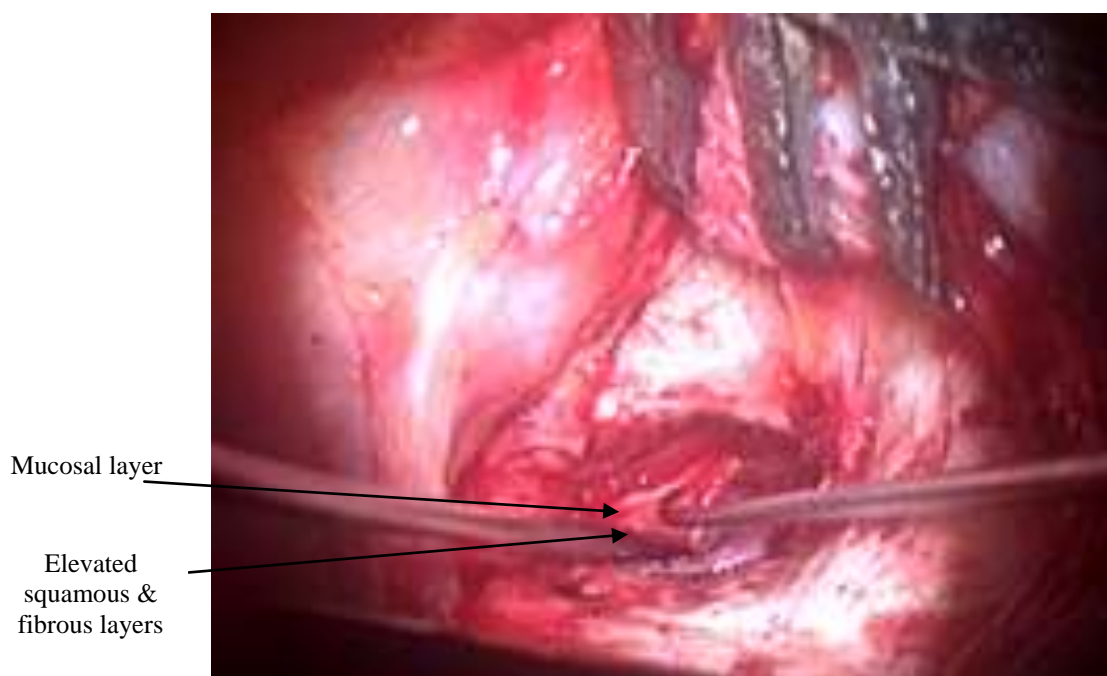


Figure 2. Separation of mucosal layer and fibrous layer of TM

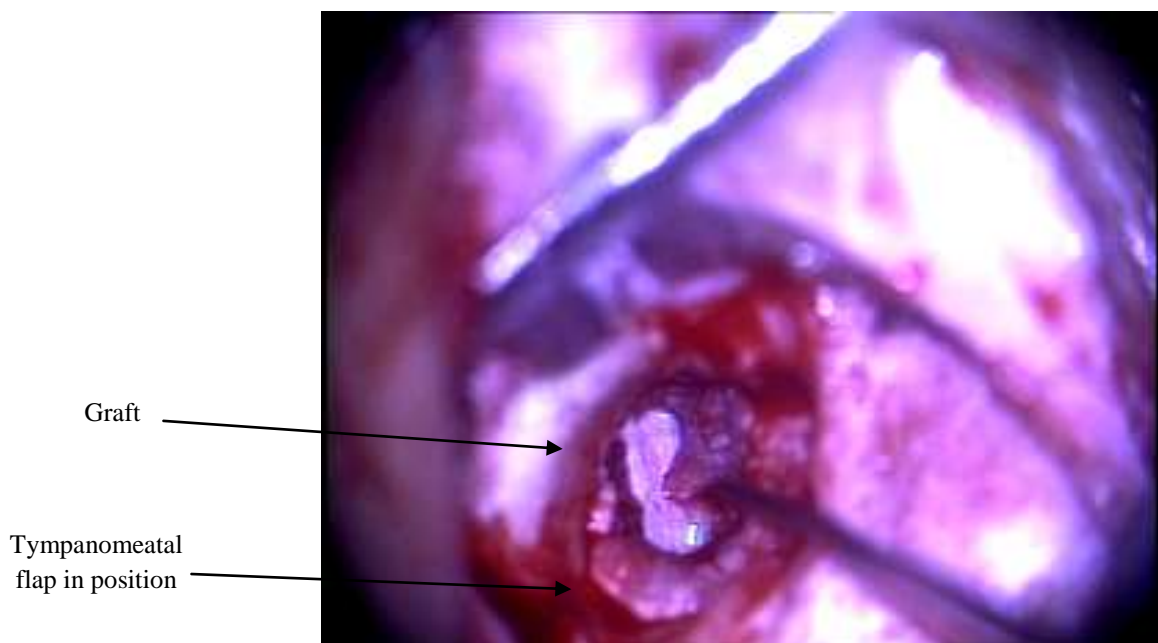


Figure 3. Tympanomeatal flap repositioned back

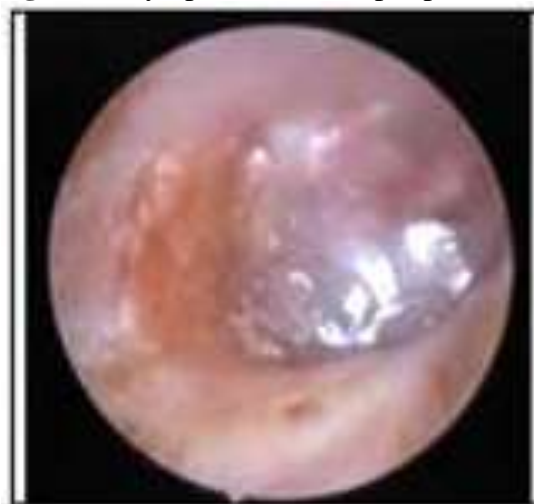

Figure 4. Endoscopic view of TM (2 months postoperative)

DISCUSSION

Tympanoplasty is the simplest operative procedure performed to repair the perforation in ear drum by repairing the tympanic membrane only. There are at least a dozen techniques to repair membrane defect, among these the Underlay and Overlay are quite common and are widely used. In underlay technique graft is placed medial to the mucosal layer whereas in overlay technique, graft is placed lateral to fibrous layer of tympanic membrane. A new technique Interlay has also emerged and is being successfully used with promising results^[8]. In Interlay technique the graft is supported medially by mucosal layer and laterally by fibro squamous layer.

Our study was undertaken with the objective of determining the feasibility of interlay myringoplasty using temporalis fascia and perichondrial graft for large tympanic perforation. (The tympanic membrane “TM” is divided into four quadrants: anterosuperior, posterosuperior, anteroinferior, and posteroinferior. The TM perforation is classified as small perforation (involving a single quadrant), medium perforation (involving two quadrants), or large perforation (involving three or more quadrants)^[9]. In the present study operations were performed in all 20 patients of chronic suppurative otitis media with inactive mucosal disease with large tympanic membrane perforation. 6 patients were males (30 %) and 14 were females (70%). Showing female

preponderance but it was statistically insignificant. Successful tympanoplasty was defined as the one that should include (1) integrity of the graft, (2) post-operative gain of minimum of 10 dB in the auditory threshold, or conservation of hearing, and (3) complete healing with the space of the aerated middle ear manifested by the graft located in the correct anatomical position, with neither atelectasis nor otitis media with effusion (OME) [10-13].

In our study, we recorded the success rate to be 90% in interlay myringoplasty, and this is in accordance with the success rate (91%) reported by Hay and Blanshard [14]. In our study Two (10%) patients had complications and graft failure, which was contributed to post operative infection. There were no other complications such as graft lateralization, canal stenosis or blunting in those patients. As far as air bone gap resolution is concerned, the results shown are variable in different studies for different techniques. However, Patil et al., [7] in their series of 100 cases who were approached using Interlay method showed a phenomenal reduction in air bone gap from a pre-operative mean value of 36.42 ± 12.0 dB to 9.7 ± 6.71 dB. In accordance with observation in this study we found in our study a reduction in ABG was from a pre-operative mean value of 23.2 ± 7.1 to 11.4 ± 3.9 post-operative. A better air bone gap reduction in Interlay method is mainly possible owing to its better conductive efficacy.

Owing to the flap's position between two interlaying layers the frequency loss is controlled and that is the reason for a better conduction and reduced air bone gap. There is also no risk of lateralization or medialization of the graft due to well supported by fibro-squamous layer laterally and mucosal layer medially.

Fouad et al [15] observed a mean post operative ABG to be 13.7 ± 4.6 dB, Which in close proximity of the mean post operative ABG (11.4 ± 3.9) of our study .

In a study by Yigit et al., [16], the rate of atelectasis by underlay was greater than overlay technique. No patient had atelectasis in our study.

Anterior canal wall blunting chances are very low by the interlay technique as the fibrous annulus which is elevated during the procedure is meticulously placed back onto the bony annulus all around and secured with small pieces of gelfoam. There is no medialization or lateralization of the graft as the graft is supported medially by the mucosal layer and laterally by the fibro-squamous layer.

As the mucosal layer is below the graft there are no chances of endothelium overgrowing on the graft leading to myringitis. The fibro-squamous layer of the tympanic membrane is elevated completely hence there is no fear of leaving residual epithelium behind leading to the formation of epithelial pearls or an iatrogenic cholesteatoma if it gets buried under the graft.

None of the cases in the present study had blunting, lateralization, epithelial cyst formation, and medialization. This finding was consistent with the study done by Patil et al., [7]. It could be seen that all the studies, including the present study the success rates for Interlay technique have been quite promising, generally above 90%. The better graft take in Interlay method is that it provides support to graft from both sides.

The difference in the surgical success results between the studies may be attributed to the number of the patients included in each study, the mean follow up period, the types of graft used, the cumulative experience of the ear surgeons.

However, given the number of studies and result of Interlay myringoplasty, we find that it is not as much popular. The reason for its lower popularity is that it requires additional skill and it is time consuming. Preparation of margins for interlaying and tactical positioning of the graft needs precise handling and manipulation of the graft and hence they are generally attempted in a setup with adequate technical and physical infrastructure. This may explain surgical difficulties in our study which observed in six cases (30%). we found the time consumed at first six cases was about one and half hour(1.5hr, 30%) .This time was decreased below one hour (<1hr, 70%) in the rest of cases. This potentially long and slow learning

curve in the earlier cases in this study may attribute to difficulties of adapting this new technique. To overcome the surgical difficulties, adequate exposure of ear drum is a must before proceeding with surgery, it is not necessary to see all areas of drum in one view, different areas of drum should be seen by simple manipulation of patient position, 5-10% of patients may have a prominent bulge in the anterior canal wall obscuring the anterior rim of ear drum and anterior portion of the annulus^[17].

In our study, one case showed surgical difficulties due to anterior hump which had been overcome by proper manipulation of patient position. Myringoplasty performed under these conditions may fail because graft could medialize in the anterior recess area, this could be prevented by elevation of wright Guil Ford Flap which is raised from over the bulge of anterior canal wall through an incision made circumferentially using a Rosen's Knife about 7 mm lateral to the ear drum, skin and periosteum are elevated from bony hump, in the majority of these patients this procedure alone brings anterior margin of ear drum and annulus tympanicus in to view^[18]. During our operations, two types of graft materials were used out of twenty cases, temporalis fascia graft was used in 10 cases. tragal or conchal perichondrium was used in other 10 cases. The success rate with temporalis fascia was 100%, while in perichondrium was 80%.

Our results are comparable with study of Jain et al.,^[19] they found a successful take-up rate of 96.6% for temporalis fascia, while Chandra and Jassal,^[20] they found a successful take-up rate of 96% for temporalis fascia, other study done by Patil et al.,^[21] the success rate was 96% with temporalis fascia, while in the study done by Kumar et al.,^[22] the success rate with temporalis fascia was 93.3%. There is no related studies using perichondrial graft with interlay technique. The Temporal fascia graft have high success rate and hearing restoration in primary tympanoplasty, temporalis fascia remains the gold standered and most popular grafting materials for its unique qualities like low metabolic rate, hence less oxygen requirement, more ischemic tolerability,

resistant to infection, easily obtained in ample amount in same incision site. Tragal perichondrium was more successful in case of large perforations, Eustachian tube dysfunction and revision tympanoplasty. Incidence of healing problems (blunting, lateral healing) was minimum with temporal fascia. Tragal perichondrium is thicker and stiffer than temporalis fascia. They are easier to manipulate in the middle ear as they do not get folded on itself, thus have ideal handling qualities^[23].

In our study, normal translucent appearance of neotympanum in the postoperative period was seen only with temporalis fascia while in tragal perichondrial graft, the neotympanum was whitish, thicker, and translucent to opaque. Our results show that, the graft material doesn't influence the success rate of tympanoplasty in terms of graft uptake, hearing improvement and surgical difficulties.

CONCLUSION

The interlay technique is considered better than both the overlay as well as the underlay techniques as getting an interlay plane is easier and faster, there is no reduction in the middle ear space, the bed size for the graft is not limited. The interlay approach has shown promising results with success rates higher than 90%.

The interlay tympanoplasty results in excellent graft uptake and good post operative ABG closure. The main advantage of this technique includes prevention of anterior blunting and lateralization or medialisation of the graft and abolishes the chances of epithelial cyst formation as in the overlay technique and myringitis due to endothelium overgrowth as in the underlay technique.

Declaration of interest

The authors report no conflicts of interest. The authors alone are responsible for the content and writing of the paper.

Funding information

None declared

REFERENCES

- 1-Kawatra R, Maheshwari P and Kumar G (2014): A comparative study of the techniques of myringoplasty – Overlay, underlay & interlay. IOSR J Dent Med Sci; 13:12-16.
- 2-Gladstone HB, Jackler RK and Varav K (1995): Tympanic membrane wound healing. An

- overview. *Otolaryngologic Clinics of North America*; 28(5):913-932.
- 3-Matsuda Y, Kurita T, Ueda Y et al. (2009): Effect of tympanic membrane perforation on middle-ear sound transmission. *The Journal of Laryngology & Otology*; 123(31):81-89.
 - 4-Castro-Sismanis A (2010): Tympanoplasty: tympanic membrane repair. In: Gulya AJ, Minor LB, Poe DS (eds) *Glasscock-Shambaugh surgery of the ear*, 6th edn. Peoples Medical Publishing House, Shelton, pp 465-488.
 - 5-Castro O, Pérez-Carro AM, Ibarra I et al. (2013): Myringoplasties in children: Our results. *Acta Otorrinolaringologica (English Edition)*; 64(2):87-91.
 - 6- Athanasiadis-Sismanis A (2010): Tympanoplasty: tympanic membrane repair. In: Gulya AJ, Minor LB, Poe DS (eds) *Glasscock-Shambaugh surgery of the ear*, 6th edn. Peoples Medical Publishing House, Shelton, pp 465-488.
 - 7-Patil BC, Misale PR and Mane RS (2014): Outcome of Interlay Grafting in Type 1 Tympanoplasty for Large Central Perforation. *Indian Journal of Otolaryngology and Head & Neck Surgery*; 66(4):418-424.
 - 8- Kartush JM (1994): Ossicular chain reconstruction. capitulum to malleus. *Otolaryngologic Clinics of North America*; 27(4): 689-715.
 - 9-El-Ahl MA, Amer HS and El-Anwar MW (2013): Simultaneous bilateral myringoplasty as a single-stage operation. *The Egyptian Journal of Otolaryngology*, 29(1), 16.
 - 10-Collins WO, Telischi FF, Balkany TJ and Buchman CA (2003): Pediatric tympanoplasty: effect of contralateral ear status and outcomes. *Archives of Otolaryngology- Head & Neck Surgery*; 129(6):646-651.
 - 11-Denoyelle F, Gilles R, Chauvin P and Garabedian EN (1999): Myringoplasty in children: predictive factors of outcome; 109(1):47-51.
 - 12-Yung M, Neumann C and Vowler S (2007): A longitudinal study on pediatric myringoplasty. *Otology & Neurotology* 28(3):353-355.
 - 13-Gersdorff M, Garin P, Decat M and Juantegui M (1995): Myringoplasty: long-term results in adults and children. *American journal of otology*; 16 (4): 532-535.
 - 14 -Hay A and Blanshard J. (2014): The anterior interlay myringoplasty: outcome and hearing results in anterior and subtotal tympanic membrane perforations. *Otology & Neurotology*; 35(9):1569-1576.
 - 15-Fouad T, Rifaat M and Buhaibeh Q (2010): Utilization of amniotic membrane for graft repair of the tympanic membrane perforation. *Egypt J Ear Nose Throat Allied Sci* ;11(1):97-101.
 - 16-Yigit U, Seyhan U, Ebru T, Berne USLV, Ozlem UNSAL and Barsan D (2005): Short term evaluation of over-underlay myringoplasty and underlay technique. *European Archives of Otorhinolaryngology* 262(5):400-405.
 - 17-Mowlavi A and Pham S (2010): Anatomical characteristics of the conchal cartilage with suggested clinical applications in rhinoplasty surgery. *Aesthetic Surgery Journal*; 30 (4): 522-526.
 - 18-Phillips JS and Yung MN (2015): Myringoplasty outcomes in the UK. *Journal of Laryngology & Otology*; 129: 860-864.
 - 19- Jain S, Gupta N, Gupta R and Roy A (2017): Interlay Type I tympanoplasty in large central perforations: Analysis of 500 cases. *Indian Journal of Otology*; 23(1): 32.
 - 20- Chandra M and Satveer SJ (2017): Longitudinal Study of Type I Interlay Tympanoplasty. *Indian Journal of Otolaryngology and Head & Neck Surgery*: 1-6.
 - 21-Gersdorff M, Gérard JM and Thill MP (2003): Overlay versus underlay tympanoplasty. Comparative study of 122 cases. *Revue de Laryngologie- Otologie- Rhinologie (Bord)*; 124(1):15-22.
 - 22-Kumar G, Sharma R, Shakeel M and Singh SJ (2016): interlay myringoplasty: hearing gain and outcome in large central tympanic membrane perforation; 43-47.
 - 23-Bhoopendra S, Neetu B, Naveen K et al. (2015): Study of various grafts in closure of tympanic membrane perforation. *Scholars Journal of Applied Medical Sciences* ; 3(3): 1509-1515.

To cite this article: El-Feky AE, Abdelmaksod MK, Mohamed SA, Aldaem RY. Interlay Technique Tympanoplasty: Surgical Difficulties with Variable Grafts. *ZUMJ* 2019;25(5);539-547, DOI: 10.21608/zumj.2019.10135.10760