



## Prophylactic and therapeutic effect of fenbendazole against *Encephalitozoon cuniculi* infection in immunosuppressed rabbits

Somaia S Abu-Akkada<sup>1</sup>,  
Samah S Oda<sup>2</sup>

Departments of <sup>1</sup>Parasitology  
and <sup>2</sup>Pathology, Faculty of  
Veterinary Medicine, Alexandria  
University, Egypt

### Abstract:

The present study was conducted to evaluate the efficacy of oral administration of fenbendazole (20 mg/kg body weight) prior and after experimental infection of immunosuppressed rabbits with *Encephalitozoon cuniculi*. A total of thirty rabbits were divided into five groups; NN (non-immunosuppressed; non-infected); IN (immunosuppressed non-infected); IPI (immunosuppressed prophylactic-infected); ITI (immunosuppressed treated-infected) and II (immunosuppressed infected) groups. Fenbendazole was administered as a prophylactic for seven successive days before infection with *E. cuniculi* and as a treatment for four weeks initiated on the 28<sup>th</sup> day post-challenge (PC). Experimental rabbits were infected with intraperitoneal injection of  $2 \times 10^5$  *E. cuniculi* spores. Parameters evaluated were body weight, detection of spores in urine, serum antibody assay, hematological, biochemical and histopathological changes. The IPI and ITI groups showed a significant better final bwt than the II group. Spores were detected in the urine of all infected rabbits from the 28<sup>th</sup> day PC and until the end of the study. The IPI group showed the least values of antibodies (IgG) compared to the ITI and II groups. Concerning histopathological changes, the intensity of the lesions was marked particularly in the II rabbits and to a lesser extent in the ITI rabbits, while, a noticeable improvement was found in the IPI rabbits. It could be concluded that fenbendazole was effective to some extent as a prophylaxis for rabbits against *E. cuniculi* infection, while when administered as a therapeutic did not display significant effects.

**Key words:** Rabbits, *Encephalitozoon cuniculi*, Prophylactic, Therapeutic, immunosuppression

### INTRODUCTION

*Encephalitozoon cuniculi* is an intracellular microsporidian pathogen of mammals and birds with the rabbit as the main host (Wasson and Peper, 2000). Most of the knowledge offered now on microsporidia is based on this species (Kotkova et al., 2013). *E. cuniculi* and other microsporidia are also important as opportunistic pathogens in immunosuppressed human patients, e.g. people suffering from HIV infections or undergoing organ transplantation (Mathis et al., 2005). In rabbits, *E. cuniculi* causes mainly neurological signs, chronic renal failure or phacoclastic uveitis (Jordan et al., 2006).

There are currently no standardized treatment protocols, prophylactic methods, or effective means of control for encephalitozoonosis in domestic rabbits (Künzel et al., 2008). Several treatment protocols have been published in the past for treatment of rabbit encephalitozoonosis: sulphonamide/trimethoprim, furosemide and dexamethasone (Meyer-Breckwoldt, 1996); oxytetracycline, betamethasone and fenbendazole (Harcourt-Brown and

Holloway, 2003); and, most recently, oxytetracycline or enrofloxacin, combined with fenbendazole and dexamethasone (Kunzel et al., 2008). However, none of these studies focused on clear documentation of therapeutic success. According to Beauvais et al. (1994), albendazole is considered as the most effective drug against microsporidiosis in humans. However, albendazole is known to be embryotoxic and teratogenic in rabbits (Kotler and Orenstein, 1999). Fenbendazole, another benzimidazole, has also been revealed to prevent and treat *E. cuniculi* infections in rabbits (Suter et al., 2001). But this study was lacking a lot of parameters for evaluation and was not enough to support their findings. In Egypt, a recent study was performed to evaluate the prevalence of *E. cuniculi* infection in seven different animal hosts (cattle, buffaloes, sheep, goat, rabbit, dog, and rat) in different provinces (Abu-Akkada et al., 2015). The results of serological examination confirmed the occurrence of antibodies against *E. cuniculi* in 38.9% (126 out of 324) of the examined animals. The highest positivity was observed in goats (67%) followed by buffaloes, rabbits, dogs, rat,

and cattle (46.42, 41, 40, 36.2, and 28.1%, respectively), while the least was recorded in sheep (9%). This indicates a wide distribution of *E. cuniculi* in Egypt and confirms that these animals may be reservoirs of the spores and thus potential sources of infection for human and animals. However, to the best of our knowledge, there is no reported data about treatment trials for this protozoon in Egypt.

So, the objective of the present study was to investigate the prophylactic and therapeutic effects of fenbendazole against *E. cuniculi* infection in immunocompromised rabbits. Serological, hematological, biochemical and pathological parameters were used to assess such effects.

## MATERIALS AND METHODS

### 1. Experimental animals

A total of thirty rabbits, 8 weeks of age, were obtained from the department of Animal Husbandry and Animal Wealth Development, Faculty of Veterinary Medicine, Alexandria University, Egypt. During the experimental period, rabbits were housed in metal cages with metallic grids on the bottom. Rabbits were fed pelleted commercial feed (Ibex Co., Cairo, Egypt), and water was supplied *ad libitum*. Rabbits were allowed to acclimate for one week prior to their use in the experiment.

### 2. Fenbendazole

The pure active ingredient of fenbendazole was kindly provided by Pharmaswede Company. It was orally administered at a daily dose of 20 mg/kg body weight (bwt) (Suter et al., 2001) to the prophylactic and treated groups of rabbits using a gastric tube.

### 3. Dexamethasone

Before infection, rabbits were immunosuppressed by intramuscular injection of dexamethasone (Intervet), 2

mg/kg bwt three times every 72 h each and repeated once a week for the rest of the experimental period.

### 4. Parasite

Spores of *E. cuniculi* (strain ATCC 50503) were kindly supplied by Dr. Esther van de Ven, QM Diagnostics (231QM), Nijmegen, Netherlands. Spores were used as inoculum for infection of rabbits and used also as antigens in serological tests. Rabbits were infected by intraperitoneal (ip) injection of  $2 \times 10^5$  *E. cuniculi* spores.

### 5. Experimental design

Rabbits were divided into five equal groups:

**NN** group: served as non-immunosuppressed non-infected (negative control); **IN** group: served as immunosuppressed non-infected; **IPI** group: served as immunosuppressed prophylactic- infected; **ITI** group: served as immunosuppressed treated-infected; **II** group: served as immunosuppressed infected (positive control).

Fenbendazole was administered as a prophylactic to the IPI group for seven successive days just before challenge with *E. cuniculi*. Challenge was performed on the eighth day after administration of fenbendazole. As a therapeutic, fenbendazole was administered daily to the ITI group for four weeks initiated on the 28<sup>th</sup> day post-challenge (PC), when infection was confirmed by serology and detection of *E. cuniculi* spores in urine of infected rabbits. The experimental design is presented in Table 1. Sera of all rabbits were tested before infection for presence of specific anti *E. cuniculi* antibodies using an enzyme-linked immunosorbent assay (ELISA). The experiment was terminated and all rabbits were slaughtered 8 weeks PC.

### 6. Parameters evaluated

#### 6.1. Body weight

All rabbits were weighed and approximately equalized the initial body weights among the different groups at the

Table 1: Experimental design

Group	Immunosuppression (Dexamethasone)	Infection ( $2 \times 10^5$ <i>E. cuniculi</i> spores)	Fenbendazole (20 mg/kg bwt)	
			Protection	Treatment
<b>NN</b> (Non-Immunosuppressed Non-Infected) Negative Control	-	-	-	-
<b>IN</b> (Immunosuppressed, Non-Infected)	√	-	-	-
<b>IPI</b> (Immunosuppressed, Prophylactic, Infected)	√	√	√	-
<b>ITI</b> (Immunosuppressed, Treated, Infected)	√	√	-	√
<b>II</b> (Immunosuppressed, Infected) Positive Control	√	√	-	-

beginning of the experiment. They were again weighed at the end of the experiment (8 weeks PC) (Table 2).

### 6.2. Detection of *E. cuniculi* spores in urine

Urine samples were collected weekly from each group for parasitological examination beginning on the 21<sup>st</sup> day PC until the end of the experiment (8 weeks PC). Smears were prepared from sediments of urine samples. Smear samples were left to dry then fixed with methanol and stained with Modified Trichrome Stain (MTS). Stained smears were examined under a light microscope (Kokoskin et al. 1994).

### 6.3 Serum antibody assay

Three rabbits from each group were bled from the ear vein at weekly intervals from the 3<sup>rd</sup> to 8<sup>th</sup> week PC. Sera were separated and tested for IgG antibodies to *E. cuniculi* using ELISA.

### 6.3.1. Preparation of *E. cuniculi* antigen (Akerstedt, 2002)

Following three cycles of freezing/thawing, spores of *E. cuniculi* were sonicated (30 min, 60 W) in BRANSON sonicator. The protein content of the supernatant was estimated according to Lowry et al. (1951). The soluble antigen solution was stored at -20°C until use.

### 6.3.2. Reference sera

A negative reference serum was kindly supplied by Lisa Bowers (Division of Microbiology, Tulane National Primate Research Center, Covington, LA, USA). A positive reference serum was obtained by experimental infection of rabbits with *E. cuniculi* spores. Sera were collected after 3 weeks post infection (PI), stored at -20 °C, and used as the positive control.

### 6.3.3. ELISA procedures

Rabbit sera were examined by indirect ELISA as described

Table 2: Effect of administration of fenbedazole on body weight, hematological and serum biochemical parameters in different groups of rabbits

Parameter	Groups				
	NN	IN	IPI	ITI	II
Initial body weight, g	1783±40.1 a	1788±42.7 a	1792±45.5 a	1783±33.3 a	1783±38.0 a
Final body weight, g	2912±91.6 a	2480±120.0 bc	2675±47.9 ab	2535±70.3 bc	2361±95.2 c
WBCs, 10 <sup>3</sup> /ml	8.50±0.35 ab	5.17±0.03 b	5.67±0.61 b	6.20±1.15 b	10.07±1.76 a
RBCs, 10 <sup>6</sup> /ml	6.20±0.29 a	5.73±0.03 a	5.60±0.35 a	6.10±0.17 a	6.10±0.06 a
Hemoglobin, g/dl	12.80±0.52 a	11.40±0.12 b	11.90±0.46 ab	12.37±0.09 ab	12.67±0.15 a
PCV, %	41.80±0.46 a	39.77±0.32 a	38.67±1.88 a	40.40±0.64 a	41.20±0.17 a
MCV, fL	67.64±2.41 a	69.25±0.34 a	69.22±1.12 a	66.31±0.56 a	67.50±0.45 a
MCH, pg	20.66±0.12 ab	19.86±0.14 b	21.34±0.55 a	20.28±0.35 b	20.72±0.01 ab
MCHC, g/dl	30.60±0.92 a	28.70±0.06 b	30.83±0.32 a	30.57±0.26 a	30.70±0.23 a
Lymphocytes, 10 <sup>3</sup> /ml	5.11±0.36 a	2.15±0.03 c	2.25±0.26 c	1.87±0.07 c	3.50±0.11 b
Monocytes, 10 <sup>3</sup> /ml	0.60±0.04 a	0.40±0.00 a	0.39±0.12 a	0.45±0.09 a	0.63±0.07 a
Granulocytes, 10 <sup>3</sup> /ml	2.81±0.24 b	2.60±0.00 b	3.01±0.23 ab	3.88±1.07 ab	5.92±1.66 a
Lymphocytes, %	60.00±1.73 a	41.77±0.32 b	39.70±0.35 b	32.47±6.03 b	37.00±6.12 b
Monocytes, %	7.10±0.17 a	7.77±0.03 a	6.67±1.36 a	7.20±0.06 a	6.40±0.40 a
Granulocytes, %	32.90±1.44 b	50.50±0.29 a	53.67±1.70 a	60.37±5.98 a	56.60±6.52 a
AST, U/L	30.70±2.14 b	31.60±1.10 b	30.57±1.65 b	33.37±1.13 b	47.40±2.66 a
ALT, U/L	28.40±1.67 b	30.30±0.69 b	39.00±1.44 a	41.87±0.09 a	39.87±0.43 a
Urea, mg/dl	36.80±1.67 a	37.60±1.27 a	37.50±1.21 a	39.47±2.22 a	39.70±1.10 a
Creatinine, mg/dl	1.30±0.06 b	1.40±0.06 ab	1.30±0.06 b	1.40±0.00 ab	1.50±0.06 a

Values are means ± standard errors.

WBCs, white blood cells count; RBCs, red blood corpuscles count; PCV, packed cell volume; MCV, mean corpuscular volume; MCH, mean corpuscular hemoglobin; MCHC, mean corpuscular hemoglobin concentration, AST, aspartate aminotransferase; ALT, alanine aminotransferase.

NN, IN, IPI, ITI, II

Means in the same row without a common letter differ significantly (P<0.05).

by **Akerstedt (2002)**. Briefly, Polystyrene microliters plates (Immunoplate Maxisorb; Nunc, Roskilde, Denmark) were coated with the soluble antigen at a concentration of 2 µg/ml. Subsequently, the plates were incubated overnight at 4°C, then washed with 200 µl PBS/Tween 20, and then treated with the blocking solution (3% bovine serum albumin (BSA) with 0.05 % Tween 20). A total of 50 µl of each diluted (1:10) tested rabbit serum, negative control sera, and positive control sera were added to each well and then incubated at 37°C for 1 h. After incubation, the plates were washed three times with 200 µl PBS/0.05 % Tween 20. After washing, horseradish peroxidase (HRP) conjugated Goat anti-rabbit IgG (KOMABIOTECH) was diluted at 1:5000 in PBS-T and added to the plates (100 µl/well). Finally, the plates were washed three times with PBS/0.05 % Tween 20, and the enzyme activity of bound peroxidase was revealed by adding 100 µl of ortho-phenylenediamine substrate (OPD) (Laboratories Inc., San Diego, CA, USA) to each well. After incubation in darkness, the enzymatic color reaction was stopped by adding 100 µl of 1 M phosphoric acid to each well, and the optical density was read at 490 nm using a microplate reader (Corona Electrical, Japan). Comparative ELISA values between groups were expressed as direct OD values (**Engvall and Perlmann, 1972; Salat et al., 2001**).

#### **6.4. Hematological and Biochemical assays**

At the end of the experiment (8 weeks PC), blood samples were collected during slaughtering from all groups. A part of blood samples was collected in tubes containing dipotassium salt of EDTA as anticoagulant and used for evaluation of hematological parameters. The other part was placed in plain centrifuge tubes and centrifuged at 3000 rpm for 15 minutes for separation of serum. The clear serum was separated and kept at -20°C for biochemical analysis. The blood parameters; red blood cells (RBCs) count, packed cell volume (PCV%), hemoglobin (Hb) concentration, the erythrocytic indices (mean corpuscular volume (MCV), mean corpuscular hemoglobin (MCH), mean corpuscular hemoglobin concentration (MCHC)), total leukocytic count (TLC) and the differential leukocytic counts were estimated automatically using a veterinary hematology analyzer (Boule medical for multispecies veterinary applications, Stockholm, Sweden). The serum activities of serum alanine aminotransferase (ALT) and aspartate aminotransferase (AST) were estimated colorimetrically

according to **Reitman and Frankel (1957)**. The concentration of blood urea was colorimetrically assayed according to the method described by **Tabacco et al. (1979)** and creatinine was determined by colorimetric kinetic method according to **Fabiny and Ertingshausen (1971)**.

#### **6.5. Postmortem and histopathological examinations**

After scarification of rabbits, gross pathological examination was performed and tissue specimens were collected from the brain, kidneys, liver, lungs, intestines, heart and spleen. These tissue specimens were fixed in 10% formalin for 24 hours and processed by paraffin embedding technique. Five micron thick sections were stained by hematoxylin and eosin (HE) (**Bancroft and Stevens, 1996**) and Brown and Brenn gram staining for detection of spores (**Luna, 1968**).

**6.6. Statistical Analysis** Data were analyzed using the GLM procedure of the Statistical Analysis System software (**SAS, 2002**). The analysis model included the effect of group. Means were compared using the Least Squares Means (LSM) of the same program, and the level of significance was 0.05.

## **RESULTS**

### **Clinical diagnosis**

During the experimental period, none of the rabbits showed clinical signs typical for encephalitozoonosis. No mortalities were recorded in all experimental animals throughout the study. *E. cuniculi* infection significantly reduced the final bwt of all infected groups compared to the NN group. The reduction in growth was more pronounced in the II group. However, the IPI group showed significantly better final bwt than the ITI group (Table 2).

### **Urine examination**

Microscopic examination of MTS-stained smears of urine sediments showed spores of *E. cuniculi* as oval bodies measuring approximately 1.5-2.5 µm (Fig. 1). The first spore output in urine was observed on the 28<sup>th</sup> PC and spores were shed until the end of the study in all experimentally infected groups.

### **Serology**

Median ELISA values are given in Figure 2. High levels of specific antibodies to *E. cuniculi* were demonstrated in sera of infected rabbits from the 21<sup>st</sup> day PC till the end of the experiment. The antibody response was episodic

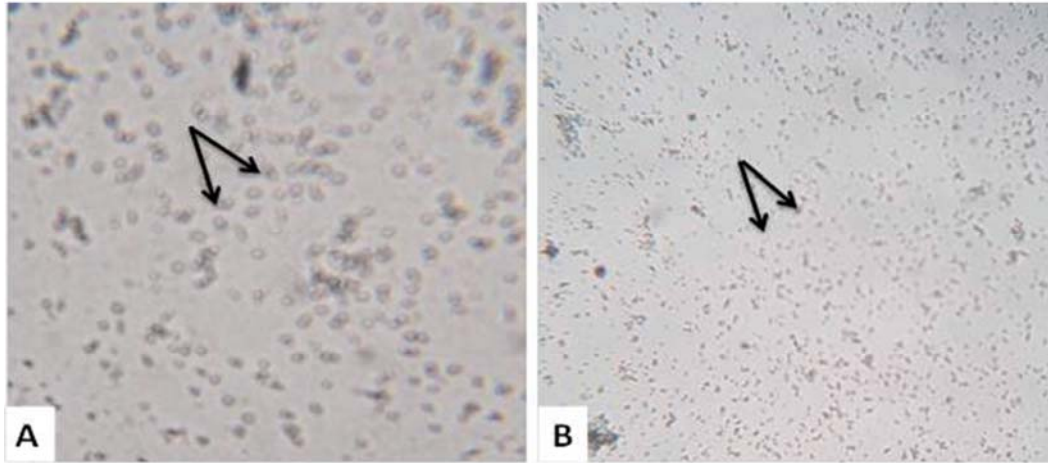


Figure 1: Spores of *E. cuniculi* in the urine of experimentally infected rabbits (arrows). The smears were stained with Modified Trichrome stain (MTS) and visualized with a light microscope, (A) = 1000x, (B) = 400x.

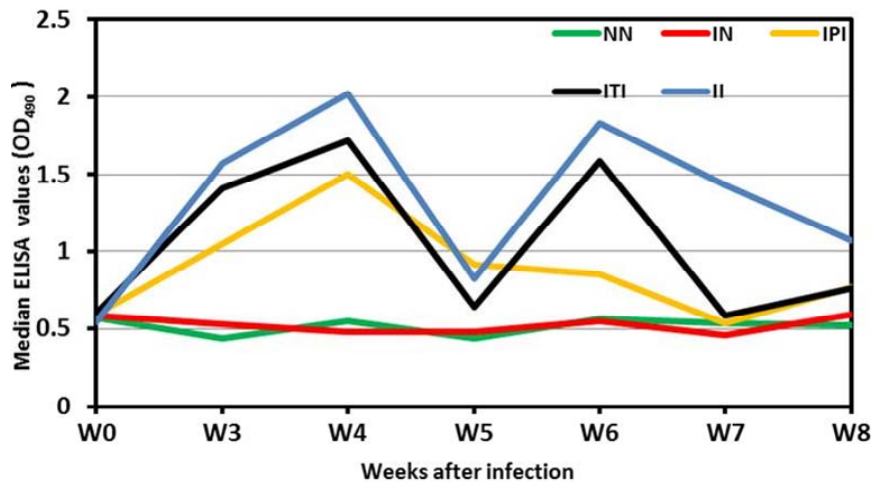


Figure 2: Humoral antibody response in different groups of experimental rabbits after infection with *E. cuniculi*: NN: non- immunosuppressed non-infected group, IN: immunosuppressed non-infected group, IPI: immunosuppressed prophylactic-infected group, ITI: immunosuppressed treated-infected group and II: immunosuppressed infected group, W: week, OD: optical density.

response in all infected groups; where there was a rise of ELISA values from the 3<sup>rd</sup> week PC, reached the highest around the 4<sup>th</sup> week and then decreased to the minimum at the 5<sup>th</sup> week. Thereafter, they retain a second peak at the 6<sup>th</sup> week and then decreased at the 7<sup>th</sup> week and until the end of the experiment. The levels of antibodies were the highest in the II rabbits and lower to some extent in the ITI rabbits. The IPI group showed the least ELISA values compared to the ITI and II groups and reached the normal level around the 7<sup>th</sup> week. The antibody values of NN and IN groups remained at the preinoculation level throughout the trial.

#### Hematological and biochemical assays

Results of hematological and serum biochemical profiles for all groups of experimental animals at the end of the experiment are shown in Table 2. Dexamethasone applications to immunosuppressed groups (IN, IPI, ITI, and

II) of rabbits significantly decreased the levels of lymphocytes by as much as 50% in the blood compared to NN group. No significant difference ( $p < 0.05$ ) in PCV%, Hb content and RBCs counts were observed in *E. cuniculi* infected, protected or treated rabbits. Monocyte values were comparable in all groups while granulocytes percentage significantly ( $p < 0.05$ ) increased in all treated groups compared to NN group. Moreover, *E. cuniculi* infection significantly enhanced ( $p < 0.05$ ) serum ALT enzyme activities compared to the NN and IN groups. While values of serum AST enzyme was improved in the IPI and ITI groups compared to the II group. No significant changes were recorded in serum urea levels compared to the NN and IN groups as well as the serum creatinine level was significantly elevated only in the II group.

#### Postmortem findings

At necropsy, lungs of the ITI and II rabbits were heavy,

meaty in appearance and fail to collapse. Kidneys of II and ITI rabbits were pale with adherence of the capsule to the parenchyma and presence of numerous subcapsular pits on their surface or few whitish foci, however, kidneys of IPI rabbits showed only few subcapsular pits on their surface.

#### Histopathological findings

Tissue specimens of organs collected from the NN and IN rabbits were with nearly normal histologic structure. Incidence and severity of histopathological lesions in the liver, lungs, kidneys, brain and heart of the experimental groups are summarized in Table 3. In general, the intensity of the lesions was marked particularly in the II rabbits and to a lesser extent in the ITI rabbits. The noticeable improvement was found in the IPI rabbits. Liver of the II rabbits showed moderate portal hepatitis and few focal areas of hepatocytic coagulative necrosis associated with mononuclear cell infiltrates (Fig. 3). Liver of the IPI and ITI rabbits showed moderate to marked dilatation of hepatic sinusoids and veins and mild portal mononuclear cell infiltrates without occurrence of hepatic necrosis. Pulmonary lesions were similar in severity in both II and ITI groups (Fig. 4) and less severe in IPI rabbits. These lesions were consisted of thickening of the interalveolar septa with mononuclear cell infiltrates and some alveoli contained necrotic epithelial cells accompanied by alveolar macrophages. Hyperplasia of bronchial associated lymphoid tissue (BALT) with or without bronchial epithelial necrosis and desquamation were noticed. Kidneys of both II and ITI rabbits had multifocal tubular necrosis with epithelial cell desquamation that accompanied by lymphocytic interstitial infiltrates (Fig. 5A) and fibrosis (Fig. 5B). Renal lesions were mild in the IPI group and were consisted of few focal areas of tubular necrosis with mild interstitial lymphocytic cell infiltrations. Most of the renal parenchyma in IPI rabbits was not affected by the parasite (Fig. 5C). Brain lesions of the II rabbits were minute multifocal cerebral granulomas (Fig. 6A) with prominent diffuse gliosis (Fig. 6B) and perivascular cuffs were clear in the cerebrum and meninges. Fenbendazole treatment ameliorated cerebral lesions to some extent (Fig. 6C) and no significant cerebral lesions were observed in the prophylactic group of rabbits. Moreover, there were multifocal aggregates of lymphocytes within the myocardium of the II rabbits (Fig. 7) and to minimal involvement only focal lymphocytic aggregates were found in ITI rabbits that were disappeared in IPI rabbits. No considerable lesions were noticed in the spleen of the experimental animals.

#### DISCUSSION

*E. cuniculi* is the most studied species of microsporidia and the majority of information about the pathogenesis of microsporidiosis is derived from studies of this organism. *E. cuniculi* causes disease when the host's immunity is impaired, in these hosts; *E. cuniculi* has a rapid course with fatal consequences (Sak et al., 2006; Salat et al., 2006). There is extensive literature on the life cycle and diagnostic tests for *E. cuniculi*, but there is very little scientific data on effective treatment protocols. In the current study, the efficacy of prophylactic and therapeutic effects of fenbendazole against *E. cuniculi* infection was evaluated in immunocompromised rabbits. Fenbendazole as one of benzimidazoles bind to the tubulin of the parasite and block it. The assemblage of this dimeric tubulin protein form microtubules, that plays important functional and structural roles in the parasites (transport of nutritive molecules and cell division); this will furthermore block a certain metabolism of parasites, such as the transport and uptake of glucose, without affecting the host (Praag, 2011). The only drug recommended for the treatment of disseminated *Encephalitozoon* species infections in human patients was albendazole (Kotler and Orenstein, 1999). However, albendazole is embryotoxic and teratogenic in rats and rabbits (Kotler and Orenstein, 1999). Like albendazole, fenbendazole is well absorbed and rapidly metabolized to oxfenbendazole. Both these compounds were active *in vitro* against *E. cuniculi* and *E. intestinalis* (Katiyar and Edlind, 1997). In the present study, *E. cuniculi* infection significantly reduced the final bwt of all infected groups compared to the NN group. Weight loss may be due to subclinical neurological or renal disease caused by chronic granulomatous lesions (Harcourt-Brown, 2005) or chronic azotemia that lead to weight loss and emaciation despite a normal dietary intake (Csokai et al., 2009). However, the protected group of rabbits (IPI) showed significantly better final bwt than ITI and II groups. These results agreed with those of Suter et al. (2001) who reported the prevention of *E. cuniculi* infection in rabbits with prophylactic administration of fenbendazole prior to experimental infection. ELISA was used to confirm infection with *E. cuniculi* as serological examination has been established as a reliable diagnostic test for *E. cuniculi* infection (Boot et al., 2000). The median values of antibodies were high in infected rabbits suggesting intense spore multiplication. The change in these values can provide us a rough estimation of the progression of microsporidiosis (Garcia, 2002). In our study, the

Table 3: Incidence and severity of histopathological lesions in the liver, lungs, kidneys, brain and heart of the experimental groups

Organ/Lesion	*Incidence and Severity of Histopathological Lesions														
	IPI						ITI						II		
	Absent (-)	Mild (+)	Moderate (++)	Severe (+++)	Absent (-)	Mild (+)	Moderate (++)	Severe (+++)	Absent (-)	Mild (+)	Moderate (++)	Severe (+++)	Mild (+)	Moderate (++)	Severe (+++)
<b>Liver</b>															
Congestion	1	1	4	0	0	0	0	2	4	0	0	0	0	6	0
Portal mononuclear cell infiltrates	3	3	0	0	2	4	0	0	0	1	1	0	1	4	0
Hepatocytic coagulative necrosis	6	0	0	0	6	0	0	0	0	0	0	0	0	3	0
<b>Lungs</b>															
Thickened interalveolar septa	1	1	4	0	0	1	1	1	4	0	0	0	0	1	5
Hyperplasia of BALT	0	3	3	0	0	1	2	2	3	0	0	0	0	3	3
Bronchial epithelial necrosis	3	2	1	0	2	1	3	3	0	0	0	0	0	3	3
<b>Kidneys</b>															
Renal tubular necrosis	0	4	2	0	0	1	4	4	1	0	0	1	0	1	5
Interstitial lymphocytic cell infiltrates	0	4	2	0	0	1	2	2	3	0	0	0	0	0	6
Interstitial fibrosis	3	3	0	0	0	1	3	3	2	0	0	0	0	2	4
<b>Brain</b>															
Cerebral granulomas	6	0	0	0	4	2	0	0	0	2	0	0	0	4	0
Diffuse gliosis	6	0	0	0	5	1	0	0	0	1	0	0	0	2	3
Perivascular cuffs	6	0	0	0	0	1	3	3	2	0	0	0	0	0	6
<b>Heart</b>															
Lymphocytic aggregates	6	0	0	0	4	2	0	0	0	4	0	0	0	2	0

\*Number of rabbits with lesions per total examined (6 rabbits per group).

The IPI: immunosuppressed protected- infected group, the ITI: the immunosuppressed treated-infected group and the II: the immunosuppressed infected group  
 Lesion scoring: (-) absence of the lesion=0%, (+) mild=1-10%, (++) moderate=11-59%, and (+++) severe=>60% of the examined tissue sections



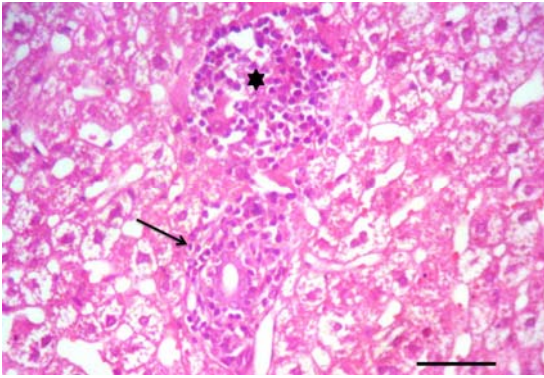


Figure 3: Liver of an immunosuppressed rabbit infected with *E. cuniculi*: Portal mononuclear cell infiltration (arrow) and focal periportal hepatic necrosis with mononuclear cell infiltrates (asterisk). HE. Bar=50µm.

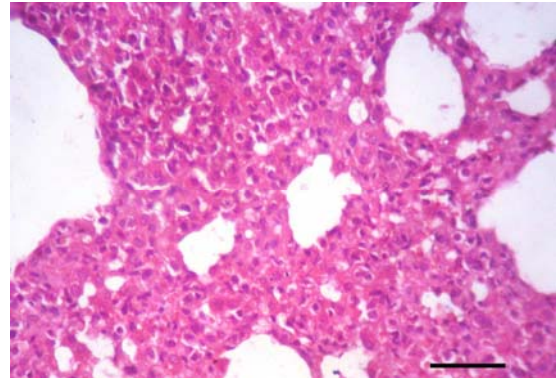


Figure 4: Lung of an immunosuppressed rabbit infected with *E. cuniculi* after 28 days treatment with fenbendazole: Marked thickening of the interalveolar septa with mononuclear cell infiltrates. HE. Bar=50µm.

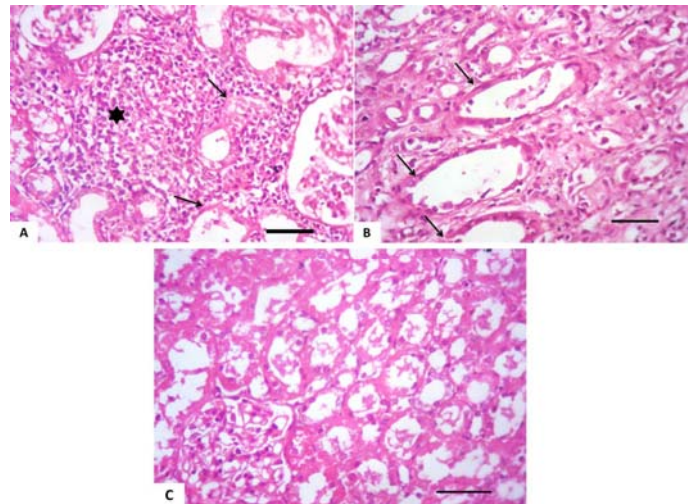


Figure 5: Kidney of an immunosuppressed rabbit infected with *E. cuniculi*: (A) Cortical tubular necrosis (arrows) with epithelial cell desquamation that accompanied by lymphocytic interstitial infiltrates (asterisk), (B) 28 days fenbendazole treatment: Cortical tubular necrosis (arrows) and interstitial fibrosis, (C) Seven successive days prophylaxis with fenbendazole: the majority of the renal parenchyma nearly normal except lumina of some renal tubules contained eosinophilic material. HE. Bar=50µm

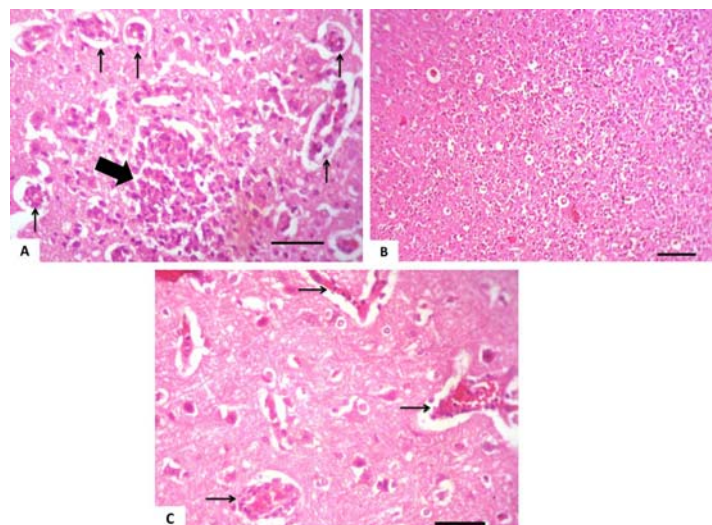


Figure 6: Brain of an immunosuppressed rabbit infected with *E. cuniculi*: (A) Cerebral granuloma (thick arrow) with lymphocytic perivascular cuffing (thin arrows), (B) Prominent diffuse gliosis, (C) 28 days fenbendazole treatment: lymphocytic perivascular cuffing (arrows). HE. Bar (A), (C) =50µm, (B) =100µm.



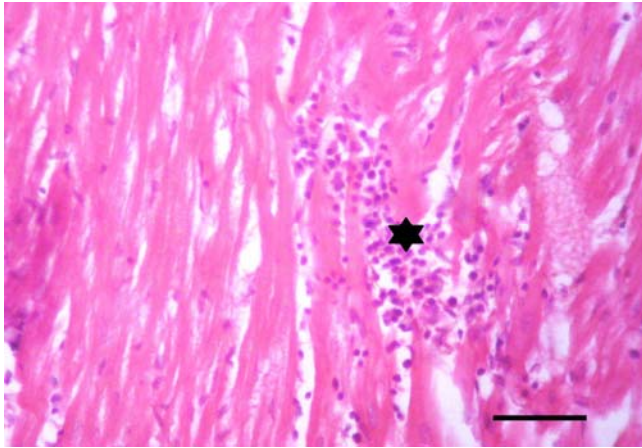


Figure 7: Heart of an immunosuppressed rabbit infected with *E. cuniculi*: lymphocytic aggregates within the myocardium (asterisk). HE. Bar=50µm.

circulating antibody response was episodic responses. This observation agreed with those recorded by **Kunstyr et al. (1986)** who observed three types of responses; short, long and episodic. They explained this by the probable genetic heterogeneity of random-bred rabbits and by individual differences in responsiveness. Moreover, inconsistent IgG pattern and differing responses may be influenced by *E. cuniculi* exposure load and individual variation in immune response (**Latney et al., 2014**). Nevertheless, the protected group of rabbits (IPI) showed lower values of IgG antibodies followed by the ITI and finally the II groups. These results agreed with those of **Suter et al. (2001)**. Beside the sera examined for *E. cuniculi* antibodies, urine samples were examined for *E. cuniculi* spores. This was achieved by microscopic examination of MTS-stained smears. MTS is a well-established standard method to detect the spores in body fluids (**Corcoran et al., 1995**). However, examination of urine may be an underutilized tool for the detection of *E. cuniculi* infection because it will not identify microsporidia at the species level and requires experts and well trained personnel as the spores could be readily mistaken with different precipitates in the sample (**Kokoskin et al., 1994**). Regarding the hematological examination, the lymphocytic counts were significantly decreased in all treated groups in comparison with the NN group, indicating a depression of cell mediated immunity evoked by administration of dexamethasone and/or *E. cuniculi* infection. Heterophil percentages were increased in infected rabbits since they are the initial responders to numerous pathogens and irritants (**Redmond et al., 2009**) and to adapt stress condition (**Aengwanich, 2007**). Additionally, *E. cuniculi* infection significantly enhanced ( $p < 0.05$ ) serum ALT and AST

enzymes activities parallel well with the subsequent detrimental alterations in the hepatic tissues and biliary system. The significant elevation of the serum creatinine level in II group could be attributed to the marked renal lesions induced by the parasite. Our study revealed histopathological lesions in various organs particularly, liver, lungs, kidneys, brain and heart. In general, the intensity of the lesions was marked particularly in the II rabbits and to a lesser extent in the ITI rabbits. The hepatic lesions were consisted of hepatic necrosis with mononuclear cell infiltrations and portal hepatitis. Similar hepatic lesions were recorded by **Fuentealba et al. (1992)**. Pulmonary lesions were consisted of thickening of the interalveolar septa with mononuclear cell infiltrates as well as bronchial epithelial necrosis and sloughing. These results agree with **Anete Lallo et al. (2013)**. The classic histopathological findings in rabbits were noticed and consisted of chronic interstitial nephritis and granulomatous meningoencephalitis. These findings were established by **Csokai et al. (2009)**. Unfortunately, the detection of *E. cuniculi* in tissue sections is seemed to be difficult, this may be explained by the chronicity of the infection as the number of organisms decreases as the lesions become older (**Franzen and Müller, 1999**), their unpredictable distribution in tissues and the tiny size of single spores as well (**Habenbacher et al., 2012**).

It could be concluded from the present study that the oral administration of fenbendazole prior experimental infection of *E. cuniculi* was effective to some extent and can be used to reduce the infection as a prophylactic of rabbits against *E. cuniculi* infection, while when administered as a therapeutic, had a little significant action in reducing infection. This conclusion suggests that fenbendazole should be further examined as antimicrosporidial by using other different doses which may produce more effective results. Moreover, a long-term monitoring study on using of fenbendazole for the treatment of chronic *E. cuniculi* infections in rabbits is needed to confirm the clinical efficacy of this medication in chronic cases exhibiting advanced neurological signs.

## REFERENCES

- Abu-Akkada, S.S., Ashmawy, K. I. and Dweir, A.W. (2015):** First detection of an ignored parasite, *Encephalitozoon cuniculi*, in different animal hosts in Egypt. *Parasitol. Res.* 114: 843-850.
- Akerstedt, J. (2002):** An indirect ELISA for detection of *Encephalitozoon cuniculi* infection in farmed blue foxes (*Alopex lagopus*). *Acta Vet. Scand.* 43:211-220.

- Aengwanich, W. (2007):** Comparative ability to tolerate heat between Thai indigenous chicken, Thai indigenous chicken crossbred and broilers by using heterophil/lymphocyte ratio. *Pak. J. Biol. Sci.* 10:1840–1844.
- Anete Lallo, M., Vidoto da costa, L.F. and Manoel de Castro, J. (2013):** Effect of Three Drugs against *Encephalitozoon cuniculi* Infection in Immunosuppressed Mice. *Antimicrob. Agents Chemother.* 57(7):3067.
- Bancroft, J. D. and Stevens, A. (1996):** Theory and practice of histological technique, 4<sup>th</sup> Ed., Churchill, Livingston, New York, London, San Francisco, Tokyo.
- Beauvais, B., Sarfati, C., Challier, S. and Derouin, F. (1994):** In vitro model to assess effect of antimicrobial agents on *Encephalitozoon cuniculi*. *Antimicrob. Agent Chemother.* 38(10):2440-2448.
- Boot, R., Hansen, C., Nozari, N. and Thuis, H. (2000):** Comparison of assays for antibodies to *Encephalitozoon cuniculi* in rabbits. *Lab. Anim.* 34(3):281–289.
- Corcoran, G.D., Tovey, D.G., Moody, A.H. and Chiodini, P.L. (1995):** Detection and identification of gastrointestinal microsporidia using non-invasive techniques. *J. Clin. Pathol.* 48:725-727.
- Csokai, J., Gruber, A., Kunzel, F., Tichy, A. and Joachim, A. (2009):** Encephalitozoonosis in pet rabbits (*Oryctolagus cuniculus*): pathohistological findings in animals with latent infection versus clinical manifestation. *Parasitol. Res.* 104(3):629–635.
- Engvall, E. and Perlmann, P. (1972):** Enzyme-linked immunosorbent assay, Elisa. 3. Quantitation of specific antibodies by enzyme-labeled anti-immunoglobulin in antigen-coated tubes. *J. Immunol.* 109(1):129-35.
- Fabiny, D.L., Ertingshausen, G. (1971):** Automated reaction rate method for determination of serum creatinine with certificated chemicals. *Clin. Chem.* 17: 696-700.
- Franzen, C. and Muller, A. (1999):** Molecular techniques for detection, species differentiation, and phylogenetic analysis of microsporidia. *Clin. Microbiol. Rev.* 12: 243-285.
- Fuentealba, I.C., Mahoney, N.T., Shaddock, J.A., Harvill, J., Wicher, V. and Wicher, K. (1992):** Hepatic lesions in rabbits infected with *Encephalitozoon cuniculi* administered per rectum. *Vet. Pathol.* 29:536-540.
- Garcia, L.S. (2002):** Laboratory identification of the microsporidia. *J. Clin. Microbiol.* 40: 1892–1901.
- Habenbacher, B., Klang, A., Fragner, K., Dinhopf, N., Kunzel, F. and Weissenböck H (2012):** evaluation of specific methods for labeling of *Encephalitozoon cuniculi* in paraffin wax- embedded tissue samples. *J Vet Diagn Invest* 24: 370.
- Harcourt-Brown, F.M. (2005):** *Encephalitozoon cuniculi* In Pet Rabbits. 56<sup>th</sup> Int. Cong., SCIVAC, Rimini, Italy.
- Harcourt-Brown, F.M. and Holloway, H.K.R. (2003):** *Encephalitozoon cuniculi* in pet rabbits. *Vet. Rec.* 152:427–431.
- Jordan, C.N., Zajac, A.M. and Lindsay, D.S. (2006):** *Encephalitozoon cuniculi* infection in rabbits. *Compend. Contin. Educ. Vet.* 28:108–116.
- Katiyar, S.K. and Edlind, T.D. (1997):** In vitro susceptibilities of the AIDS associated microsporidian *Encephalitozoon intestinalis* to albendazole, its sulfoxide metabolite, and 12 additional benzimidazole derivatives. *Antimicrob. Agents Chemother.* 41:2729-2732.
- Kokoskin, E., Gyorkos, T.W., Camus, A., Cedilotte, L., Purtil, T. and Ward, B. (1994):** Modified technique for efficient detection of Microsporidia. *J. Clin. Microbiol.* 32:1074-1075.
- Cedilotte, L., Purtil, T. and Ward, B. (1994):** Modified technique for efficient detection of Microsporidia. *J. Clin. Microbiol.* 32:1074-1075.
- Kotkova, M., Sak, B., Kvetonova, D. and Kvac, M. (2013):** Latent microsporidiosis caused by *Encephalitozoon cuniculi* in immunocompetent hosts: a murine model demonstrating the ineffectiveness of the immune system and treatment with albendazole. *Plos One* 8(4): Article ID e60941.
- Kotler, D. and Orenstein, J.M. (1999):** Clinical syndromes associated with microsporidiosis. In: Wittner M, Weiss L (Eds.), *The Microsporidia and Microsporidiosis.. Amer. Soc. Microbiol., Washington, DC*, pp. 258-292.
- Kunstyr, I., Lev, L. and Naumann, S. (1986):** Humoral antibody response of rabbits to experimental infection with *Encephalitozoon cuniculi*. *Vet. Parasitol.* 21(4):223–232.
- Künzel, F., Gruber, A., Tichy, A., Edelhofer, R., Nell, B., Hassan, J., Leschnik, M., Thalhammer, J.G. and Joachim, A. (2008):** Clinical symptoms and diagnosis of encephalitozoonosis in pet rabbits. *Vet. Parasitol.* 151:115–124.
- Latney, L.V., Bradley, C.W. and Wyre, N.R. (2014):** *Encephalitozoon cuniculi* in pet rabbits: diagnosis and optimal management. *Veterinary Medicine: Research and Reports.* 5: 169–180.
- Luna, L. (1968):** Manual of Histologic Staining Methods of the AFIP. 3rd ed. New York, NY: McGraw-Hill; 222.
- Mathis, A., Weber, R. and Deplazes, P. (2005):** Zoonotic potential of the microsporidia. *Clin. Microbiol. Rev.* 18: 423–445.
- Meyer-Breckwoldt, A. (1996):** Epidemiologische und klinische Untersuchungen zur Encephalitozoonose beim Zwergkaninchen. Dissertation, Veterinary University, Hannover.
- Praag, E.V. (2011):** Various treatment options for *Encephalitozoon cuniculi*, a protozoal parasite of the nervous system in rabbits? Available from: <http://www.medirabbit.com/EN/Neurology/cuniculi/pyrimethamine.htm>
- Redmond, S.B., Chuammitri, P., Andreasen, C.B., Palić, D. and Lamont, S.J. (2009):** Chicken heterophils from commercially selected and non-selected genetic lines express cytokines differently after in vitro exposure to *Salmonella enteritidis*. *Vet. Immunol. Immunopathol.* 132: 129–134.

**Reitman, S. and Frankel, S. (1957):** A coloremtric method for determination of oxaloacetic transaminase and serum glutamic pyruvic transaminase. *Am. J. Clin. Pathol.* 28: 56-63.

**Sak, B, Salat, J., Horka, H., Sakova, K. and Ditrich, O. (2006):** Antibodies enhance the protective effect of CD4+ T lymphocytes in SCID mice perorally infected with *Encephalitozoon cuniculi*. *Parasite Immunol.* 28: 95–99.

**Salat, J., Braunfuchsova P. and Kopecky, J. (2001):** Experimental infection of immunocompetent and immunodeficient mice with *Encephalitozoon cuniculi*. *Folia Parasitol.* 48: 249-254.

**Salat, J, Horka, H., Sak, B. and Kopecky, J. (2006):** Pure CD4+ T lymphocytes fail to protect perorally infected SCID mice from lethal microsporidiosis caused by *Encephalitozoon cuniculi*. *Parasitol. Res.* 99: 682-686.

**SAS (2002):** Statistical Analysis System. Version 9, SAS Institute Inc., Cary NC, USA.

**Suter, C., Müller-Doblies, U.U., Hatt, J.M. and Deplazes, P. (2001):** Prevention and treatment of *Encephalitozoon cuniculi* infection in rabbits with fenbendazole. *Vet. Rec.* 148: 478–480.

**Tabacco, A., Meiattini, F., Moda, E. and Tarli, E. (1979):** Simplified enzymatic/colorimetric serum nitrogen determination. *Clin. Chem.* 25: 336-337.