

## Fixation of Fractures of Ulnar Styloid Associated with Distal Radius Fractures by K wires "Tension Band"

Adnan Abd-aleem El sebaey, Galal Mohamed Mansour, Sobhy Taher Sobhy Daoud\*

Department of Orthopaedic Surgery, Faculty of Medicine, Al-Azhar University

\*Correspondence author: Sobhy Taher Sobhy Daoud, Mobile: (+20) 01225274402, E-mail: dr\_daoud86@yahoo.com

### ABSTRACT

**Background:** fracture of the distal radius is the most common type of fracture in the upper extremity. Because the radius plays a fundamental role in the stability of the wrist joint, preservation of ligamentous function of the wrist and the biomechanics of radiocarpal and radioulnar joints, anatomical reduction and correction of articular surface incongruity decreases the potential of degeneration and accelerates post-injury rehabilitation.

**Objective:** the aim of this study is targeting fixation of ulnar styloid fracture associated with distal radius fracture by K wires" Tension Band" and detecting the effect of these fractures on final wrist outcome.

**Patients and Methods:** ten cases with fracture of ulnar styloid were managed over the last year from July 2017 to march 2018. Case selection was according to: 1- Base fracture of ulnar styloid (Type 2). 2- Involvement more than 50% of the height of ulnar styloid.

**Results:** our study showed that one patient developed non-union, one patient developed infection, two patients with injury to dorsal cutaneous branch of ulnar nerve and one patient developed DRUJ instability. According to Mayo Clinic Wrist Score; one patient achieved excellent Mayo Score, two with good score, five with satisfactory score and two with poor score.

**Conclusion:** although Open reduction and internal fixation is recommended in case of base fracture if there is displacement more than 2mm or if there is associated DRUJ instability as it is associated with high union rate and less rate of DRUJ instability.

**Keywords:** Ulnar Styloid, DRUJ, K wires.

### INTRODUCTION

Ulnar styloid fractures are often associated with fractures of the distal radius, and are present in up to 50 to 65% of these fractures<sup>(1)</sup>. The effects of ulnar styloid fractures in the setting of distal radius fractures are unclear. Although some studies suggest that ulnar styloid fractures have little effect on radiographic or clinical outcomes. Other studies showed that these fractures can contribute to poor results, including distal radioulnar joint (DRUJ) instability, ulnar sided wrist pain, stiffness, and weakness<sup>(2)</sup>.

The ulnar styloid plays a crucial role in wrist biomechanics; the ulnar styloid base and the fovea are the insertion points for the primary stabilizers of the DRUJ, the superficial and deep portions of the palmar and dorsal radioulnar ligaments. In addition, the ulnar styloid functions as a strut, helping to stabilize the extensor carpi ulnaris (ECU), its sub-sheath, and the ulnocarpal ligaments<sup>(3)</sup>.

Because of its anatomic importance, the potential exists for ulnar styloid fractures to cause ulnar-sided wrist symptoms. However, the clinical significance of ulnar styloid fractures in association with distal radius fractures is not clear. Although some investigators have found no correlation between outcomes and the presence of ulnar styloid fractures<sup>(4)</sup>; others have noted that ulnar styloid fractures can have a negative impact on outcomes after distal radius fracture<sup>(5)</sup>.

The management of acute ulnar styloid fractures is based on the long-term effect that they may have on the stability of the distal

radioulnar (DRU) joint. The relationship of the ulnar styloid to the stabilizing ligaments determines whether a specific fracture type is likely to result in DRU joint instability<sup>(6)</sup>.

### AIM OF THE WORK

The aim of this study is targeting fixation of ulnar styloid fracture associated with distal radius fracture by K wires" Tension Band" and detecting the effect of these fractures on final wrist outcome.

### PATIENTS AND METHODS

#### Patients:

Ten cases with fracture of ulnar styloid were managed over the last year from July 2017 to march 2018.

Case selection was according to:

- 1- Base fracture of ulnar styloid (Type2).
- 2- Involvement more than 50% of the height of ulnar styloid.

Cases with neglected fracture or open fracture were excluded.

#### Methods:

Patients were evaluated by history taking, physical examination, investigation, consent taking and radiographic assessment.

The treatment was by open reduction and internal fixation using K-wire and tension band.

Follow up was done using **Mayo** (wrist performance score)<sup>(7)</sup>.

**Pre-operative:**

**History:**

In this prospective study, we fulfilled the following data:

- 1- Patient age, sex and type of work.
- 2- Right or left handed and dominance.
- 3- Mode of trauma.
- 4- Special habits (e.g. smoking).

**Physical Examination:**

Standard hand examination was performed in the form of:

- 1- Skin condition.
- 2- Functions of muscles, tendons and nerves.

**Investigation:**

- 1- **Laboratory:** Routine preoperative labs (e.g. CBC, PT, PC, Renal and liver function).

**2 - X-rays:**

- Affected wrist is imaged posteroanterior and lateral view to detect the site of the fracture, displacement and assessment of distal radioulnar joint.
- Assessment of associated distal radius fractures.
- Elbow x-ray to detect higher level of fracture or dislocation.

**Written informed consent:**

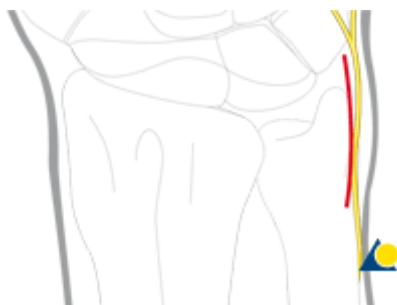
An approval of the study was obtained from Al-Azhar University Academic and Ethical Committee. Every patient signed an informed written consent for acceptance of the operation.

**Operative:**

- Patient was treated by open reduction and internal fixation using tension band wiring.
- Patients were anesthetized using general anesthesia and then positioned supine. We started by fixing the distal radius fracture then ulnar styloid fracture was fixed.

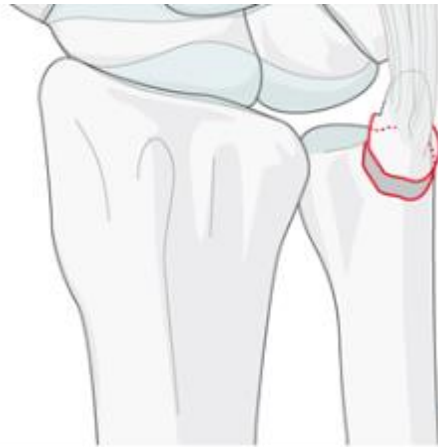**K-wires and a tension band:**

The ulna is accessed through 2-3 cm straight longitudinal incision over the distal ulna, between the tendon of flexor and extensor carbiulnaris.



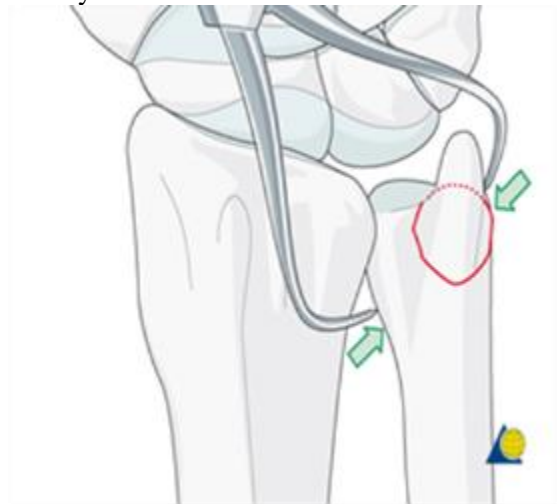
**Figure (1):** Approach.

Assessment of the fracture size irrigation and cleaning of the fracture site.



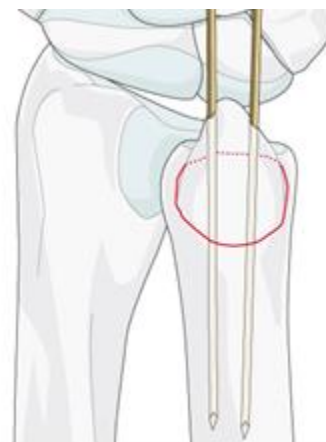**Figure (2):** Fracture assessment

The fragment is reduced by the use of small pointed reduction clamp. It is important to recognize the ulnar styloid is occasionally more palmer than it appears in an X-ray.



**Figure (3):** Reduction.

Then we insert two smooth k wires from the tip of styloid in such direction as to engage their tips in ulnar cortex. Then we check the position by image intensifier.



**Figure (4):** K wire fixation.

We Drill a hole in the ulna from dorsal to palmar 2 cm proximal from styloid tip. Care must be

taken to avoid injury to dorsal cutaneous branch of ulnar nerve.

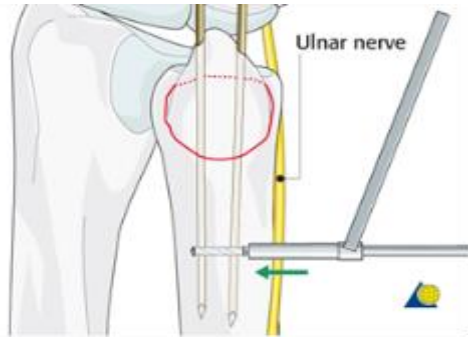


Figure (5): Drill hole.

The dorsal branch of ulnar nerve arises about 5 cm. proximal to the wrist; it passes backward beneath the Flexor carpi ulnaris, perforates the deep fascia, and, running along the ulnar side of the back of the wrist and hand, divides into two dorsal digital branches; one supplies the ulnar side of the little finger; the other, the adjacent sides of the little and ring fingers<sup>(8)</sup>.

We passed the wire through the drill hole, using a hypodermic needle as a guide; the wire was passed around the k-wire, to create a figure of eight loop.

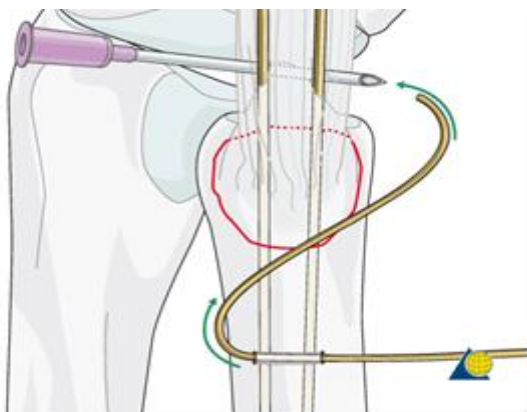


Figure (6): Loop formation.

We twist the wire. The wire is tensioned by pulling on the twist until the desired tension is achieved. Then we cut the twist and bend it so as not to irritate the soft tissue.

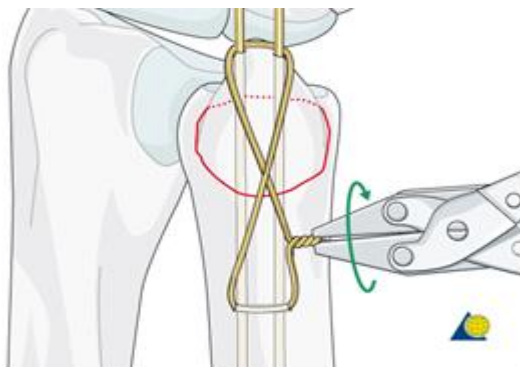


Figure (7): Tensioning.

Using the bending iron for k-wire, the wire are bent at the level of the tip of the styloid and cut short. They are impacted into the bone using small punch, or other appropriate tool.

**Postoperative:**

- Patients were immobilized in above elbow slab for four weeks during which range of motion of fingers and shoulder is encouraged. Patients were followed up at 2weeks, 4 weeks and monthly for 6 months for union and stability of DRUJ.
- Patient functional outcome is assessed using Mayo Wrist Score<sup>(Ref)</sup>.

**Statistical analysis**

Recorded data were analyzed using the statistical package for social sciences, version 20.0 (SPSS Inc., Chicago, Illinois, USA). Quantitative data were expressed as mean± standard deviation (SD). Qualitative data were expressed as frequency and percentage.

**The following tests were done:**

- Independent-samples t-test of significance was used when comparing between two means.
- Chi-square ( $\chi^2$ ) test of significance was used in order to compare proportions between two qualitative parameters.
- The confidence interval was set to 95% and the margin of error accepted was set to 5%. The p-value was considered significant as the following:
  - Probability (P-value)
  - P-value <0.05 was considered significant.
  - P-value <0.001 was considered as highly significant.
  - P-value >0.05 was considered insignificant.

**RESULT**

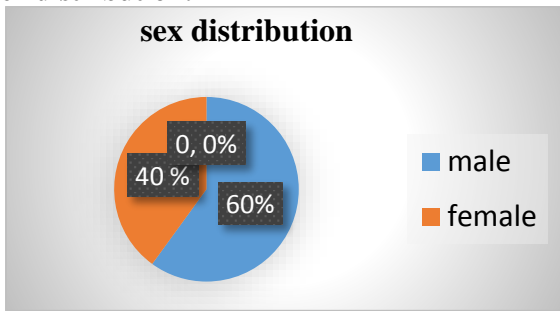
**Patients:**

- Age of the patients range from 15 to 65.
- The dominant hand was involved in 6 patients (60%).
- All the patients have associated distal radius fracture.

**Table (1): Preoperative evaluation**

Case No.	Age	Sex	Work	Mode of trauma
1	27	Male	Barber	Motor bike accident
2	65	Male	Mechanic	Fall to ground
3	20	Male	Delivery	Motor bike accident
4	21	Female	Seller	Direct trauma
5	20	Female	Housewife	Motor car accident
6	45	Male	Worker	Fall to ground
7	15	Male	Student	Fall down stairs
8	20	Female	Housewife	Fall to ground
9	50	Female	Housewife	Fall to ground
10	45	Male	Worker	Fall from height

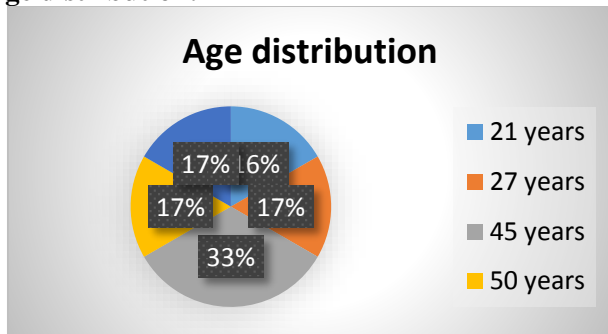
**Sex distribution:**



**Figure (8):** Sex distribution.

Ten cases with ulnar styloid fracture, six males and four females, were encountered in this study denoting that males (60%) are more exposed to this fracture than females (40%).

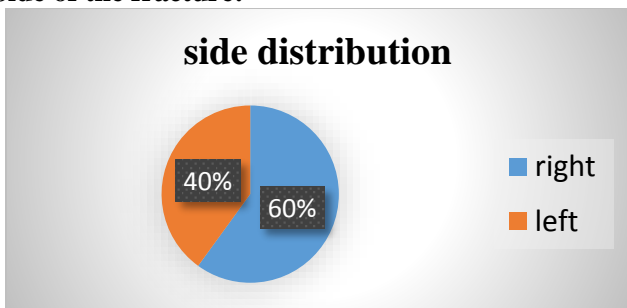
**Age distribution:**



**Figure (9):** Age distribution

Ages of the patients range from 15 to 65 years with mean age 33 years.

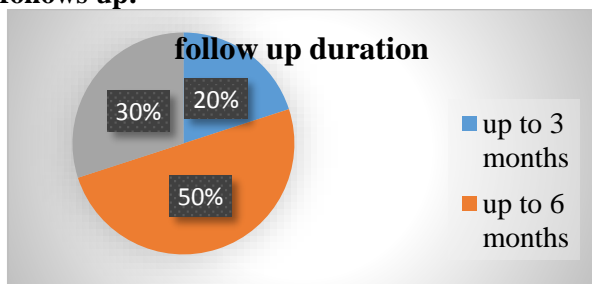
**Side of the fracture:**



**Figure (10):** Side of the fracture.

This chart denotes that six (60%) patient out of ten had right side fracture, four (40%) patients had left side fracture and the right hand was dominant in all patients

**Distribution according to period of postoperative follows up:**



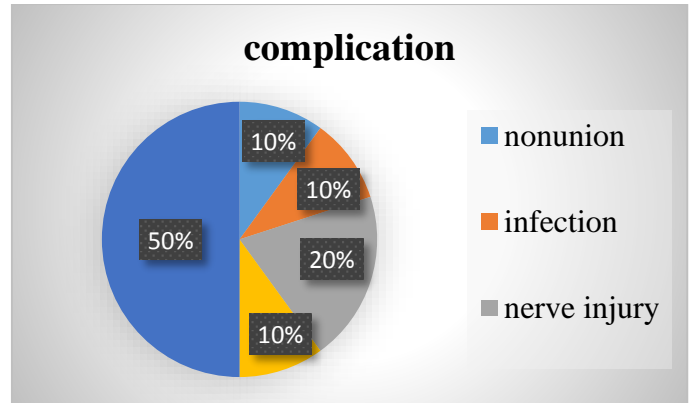
**Figure (11):** Follow up duration.

**Case presentation**

This chart denotes that two (20%) cases out of ten were followed up over period less three months, five (50%) cases three to six months and three (30%) cases more than six months follow up.

**Complication:**

This demonstrate that one (10%) cases complicated by nonunion, one cases (10%) complicated by infection, two (20%) cases with injury to dorsal cutaneous branch of ulnar nerve and one cases (10%) with DRUJ dislocation.



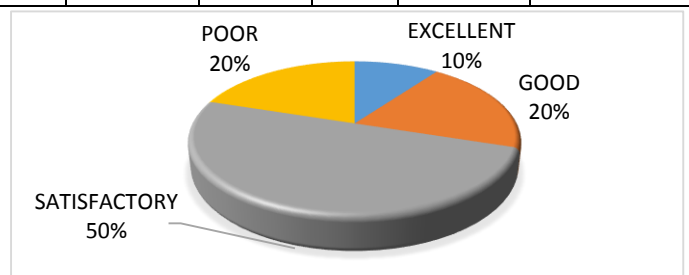
**Figure (12):** Complications.

**According to Mayo clinic wrist score and complication:**

Results: was that one (10%) patient with excellent score, two (20%) with good score, five (50%) with satisfactory score and two (20%) with poor score, **Table 2, Figure 13.**

**Table 2: Mayo clinic wrist score and complication**

Case No.	non union	infection	nerve injury	DRUJ instability	Mayo. Score
1	No	No	No	No	Excellent
2	No	No	No	No	Good
3	No	No	Yes	No	Satisfactory
4	No	Yes	No	No	Satisfactory
5	No	No	No	Yes	Satisfactory
6	Yes	No	No	No	Good
7	No	No	No	No	Satisfactory
8	No	No	No	No	Poor
9	No	No	Yes	No	Satisfactory
10	No	No	No	No	Poor

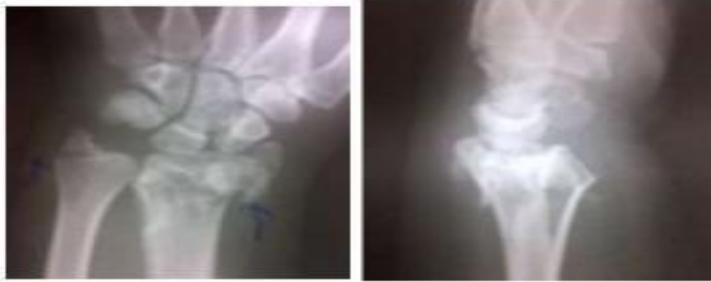

**Figure (13):** Final patients score.

**CASE 1:**

Twenty years old female patient, housewife, presented to El-Mogamaa El-Teby hospital with intraarticular fracture distal radius associated with base fracture of ulnar styloid from motor bike accident, x-rays were done and he was prepared for operation.

Pre-operative poster anterior and lateral X-rays:




**Figure (14):** Preoperative PA and lateral X-rays.

Immediate post-operative X-rays:

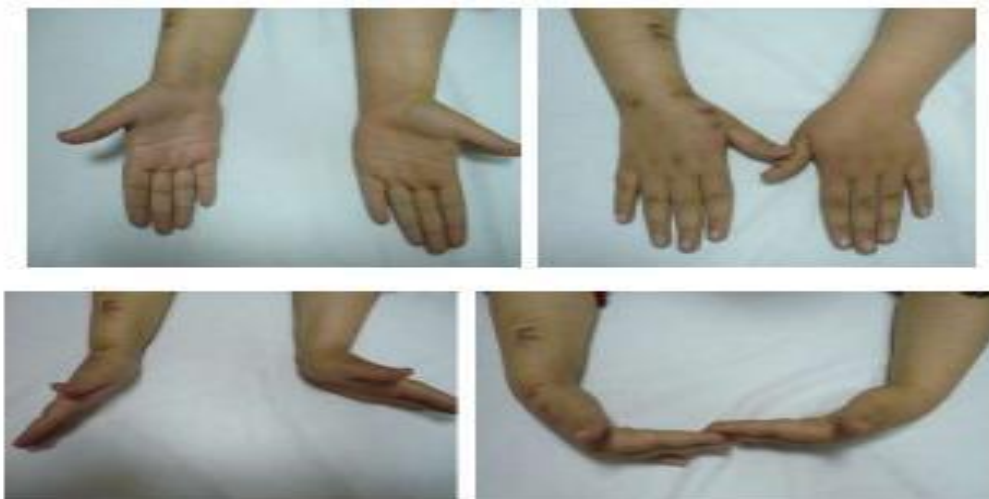

**Figure (15):** Immediate post-operative X-rays.

Four months follow up:



**Figure (16):** Four months follow up X-rays showing union.

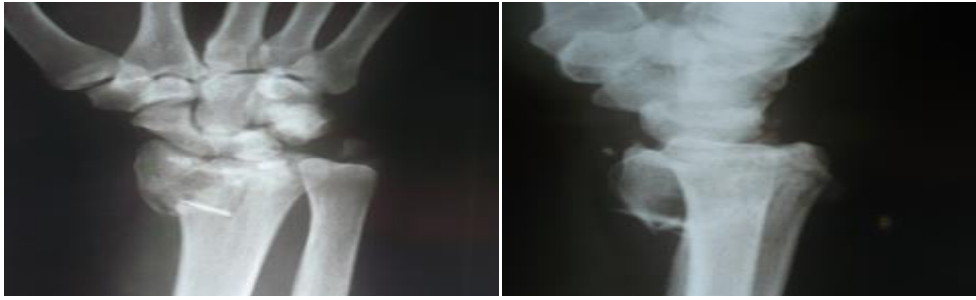


**Figure (17):** Six months wrist assessment



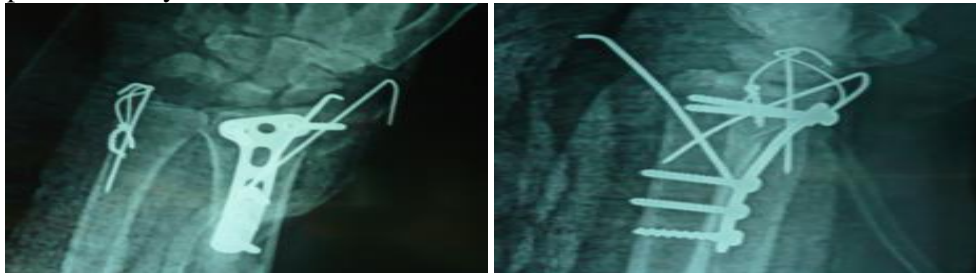
**CASES 2**

45 years old male patient, worker, smoker presented to El-mogamaa El-teby hospital with fracture distal radius associated with ulnar styloid fracture following fall to ground, x-rays were done and he was prepared for operation.



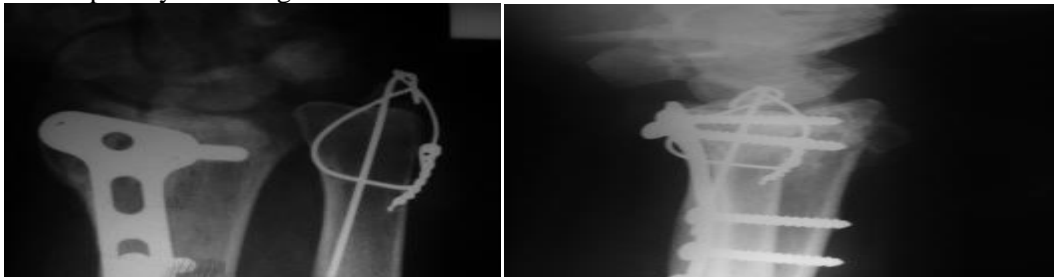
**Figure (18):** Preoperative PA and lateral X-ray.

Immediate postoperative X-rays:



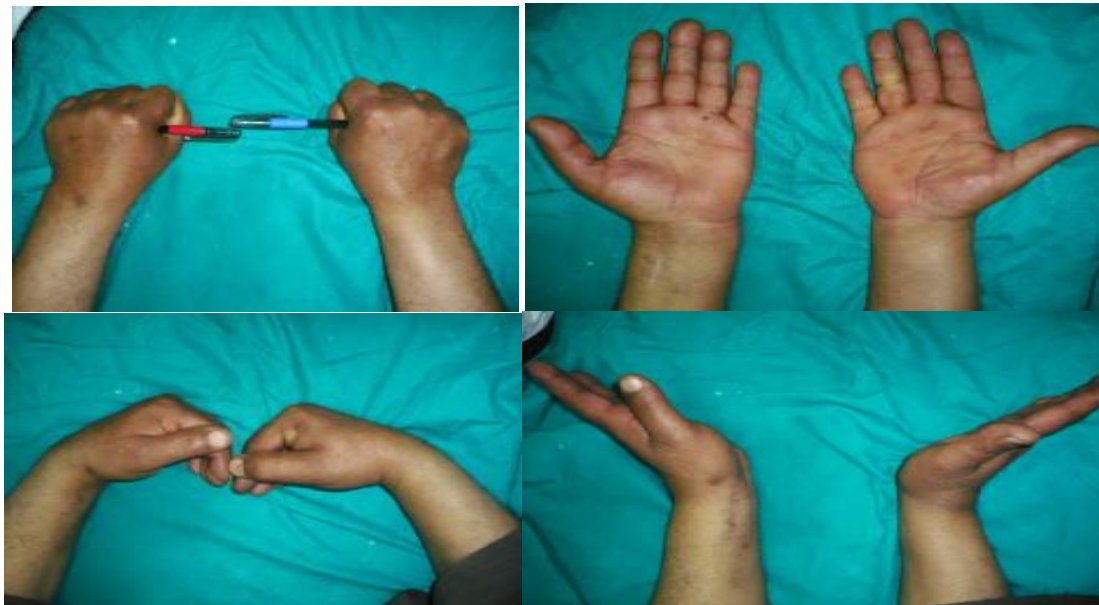**Figure (19):** Immediate post-operative X-rays.

Six months follow up x-rays showing nonunion:



**Figure (20):** Six months follow up x-rays showing Non union

Six months wrist assessment:



**Figure (21):** Six months wrist assessment.

## DISCUSSION

On one side, several studies revealed that ulnar styloid nonunion does not appear to affect wrist functional outcomes, ulnar-sided wrist pain or DRUJ stability.

**Kim et al.**<sup>(9)</sup> studied a total of 91 patients with a distal radius fracture (DRF) and an accompanying ulnar styloid fracture treated by open reduction and volar locking plate fixation were included in this study. In the first part of the analysis, the 91 study subjects were subdivided according to the presence or not of ulnar styloid union (20 and 71, respectively) by radiography at final follow-up (average 23 months). These two cohorts were compared with respect to wrist functions at 3 months postoperatively and the final follow-up visit, and ulnar-sided wrist pain and DRUJ instability at the final follow-up visit and ulnar styloid length as determined radiographically at final follow-up. In the second part of the analysis, 49 of the 91 study subjects with an ulnar styloid base fracture were subdivided according to the presence or not of ulnar styloid base fracture union (12 and 37, respectively) at final follow-up by radiography. These two groups were also compared with respect to the above-mentioned parameters.

The Result revealed that Ulnar styloid fractures united in 20 (22%) of the 91 patients at final follow-up visit (average 23 months). No significant differences were found at any time during follow-up between patients who achieved or did not achieve ulnar styloid fracture union or ulnar styloid base fracture union<sup>(9)</sup>.

This results is also supported by **Zenke et al.**<sup>(10)</sup> who conducted a review of DRF cases with persistent ulnar sided wrist pain after open reduction and volar-locking-plate fixation, and they concluded that ulnar-sided wrist pain is probably related to an initial high-energy injury rather than ulnar styloid nonunion. This findings are also consistent with those of **Buijze and Ring**<sup>(11)</sup>, who performed a comparison of the clinical impact of united versus non-united fractures of the proximal half of the ulnar styloid following volar-plate fixation of the DRF. They found that nonunion of the proximal half of the ulnar styloid has no effect on wrist function, pain and DASH, although their conclusions were based on only a 6-month postoperative evaluation<sup>(12)</sup>.

On the other side, other studies revealed the role of ulnar styloid fracture fixation on the final outcome of distal radius fracture and its association with DRUJ instability.

This is supported by **Megan et al.**<sup>(13)</sup> study in which they retrospectively reviewed for 166 distal radius fractures treated during a 1-year interval. Distal radius fractures were classified according to the AO system, and accompanying ulnar styloid fractures were evaluated for both size and displacement. Each distal radius fracture was also evaluated for radiographic and clinical evidence of distal radioulnar joint instability.

All distal radius fractures complicated by distal radioulnar joint instability were accompanied by an ulnar styloid fracture. A fracture at the ulnar styloid's base and significant displacement of an ulnar styloid fracture were found to increase the risk of distal radioulnar joint instability.

Also according to **Megan et al.**<sup>(13)</sup> study both the size of the ulnar styloid fracture and its displacement at the time of injury were statistically significant risk factors for the development of DRUJ instability. Each of the distal radius fractures complicated by acute or chronic DRUJ instability had an associated ulnar styloid fracture. Statistical analysis indicated that distal radius fractures with concomitant ulnar styloid fractures were more likely to be complicated by DRUJ instability than those without ulnar styloid fractures. Fracture of the ulnar styloid at its base was associated with a greater incidence of DRUJ instability than was a smaller fracture. Significantly displaced ulnar styloid fractures were associated with a greater incidence of DRUJ instability than were ulnar styloid fractures that were minimally displaced or nondisplaced. A significantly displaced ulnar styloid fracture at its base was also more likely to be associated with DRUJ instability than a smaller fracture or a large fracture that was not significantly displaced.

According to our study we treated ten patients with acute ulnar styloid fracture with open reduction and internal fixation. We followed up the patients for six months to detect union and possible complications .patients were finally assessed using Mayo cilinc wrist performance score. Open reduction and internal fixation of fracture of ulnar styloid resulted in high union rate 90%(only onecase with non-union) and low DRUJ instability10 % (only one case with DRUJ) than observed in other studies in which ulnar styloid was treated conservatively as in **Kim et al.**<sup>(9)</sup> study.

However the overall functional results as determined by Mayo clinic wrist score which tests ROM, pain, patient satisfaction and grip strength werenot favorable as only one patients with excellent score, two with good score, five with satisfactory score and two patients with poor score.

However the results of our study is criticized by limited number of patients and short follow up period and lack of comparison group to compare the results of internal fixation with patients treated conservatively.

This results are matched with other studies which consider ulnar styloid fracture is a poor predictive factor on the final functional outcome of accompanying distal radius fracture<sup>(12)</sup>.

This imply that the ulnar styloid is anatomical and functional structure that should not be under evaluated. It is important to note that, in contrast to worse functional outcomes, the type of ulnar styloid fracture was not associated with bad radiological results suggesting that soft tissue damage (e.g., capsular

ligament lesion) could be responsible for this bad functional performance. It is possible that ulnar styloid fracture is a marker or predictive factor for osseous and cartilage injury<sup>(12)</sup>.

## CONCLUSION

Ulnar styloid fracture is commonly associated with distal radial fracture; it should not be under evaluated during assessment of distal radius fracture.

Although open reduction and internal fixation is recommended in case of base fracture if there is displacement more than 2mm or if there is associated DRUJ instability as it is associated with high union rate and less rate of DRUJ instability, the presence of ulnar styloid fracture itself has a poor predictive factor for the final functional outcome of distal radius fracture.

## REFERENCES

1. **Sammer DM, Shah HM, Shauver MJ *et al.* (2009):** The effect of ulnar styloid fractures on patient-rated outcomes after volar locking plating of distal radius fractures. *J Hand Surg.*, 34A:1595-1602.
2. **Lindau T, Adlercreutz C, Aspenberg P (2000):** Peripheral tears of the triangular fibrocartilage complex cause distal radioulnar joint instability after distal radial fractures. *J Hand Surg.*, 25A:464-468.
3. **Ishii S, Palmer AK, Werner FW *et al.* (1998):** An anatomic study of the ligamentous structure of the triangular fibrocartilage complex. *J Hand Surg (Am)*, 23(6):977-85.
4. **Hagberg L, Lindau T, Adlercreutz C *et al.* (2000):** Distal radioulnar instability is an independent worsening factor in distal radius fractures. *ClinOrthop.*, 37b :229-235.
5. **Stoffelen D, De Smet L, Broos P(1998):** The importance of the distal radioulnar joint in distal radial fractures. *J Hand Surg (Br Eur)*, 23-B(4):50-51.
6. **Logan J and Lindau TR (2008):**The management of distal ulnar fractures in adults: a review of the literature and recommendations for treatment. *StratTraum Limb Recon.*, 3:49-56.
7. **Hudak PL, Amadio PT, Bombatier C (1996):** Development of an upper extremity outcome measure : the DASH ( Disabilities of Arm ,Shoulder and Hand) (the upper extremity collaborative group). *Ind Med.*, 29:602-608.
8. **Green DP, Hotchkiss RN, Pederson WC (1999):** Green's operative hand surgery, Scott W. Wolfe, Robert N. Hotchkiss, William C. Pederson, Churchill Livingstone, Pp. 1.
9. **Kim JK, Koh YD, Do NH (2010):** Should an ulnar styloid fracture be fixed following volar plate fixation of a distal radial fracture? *J Bone Jt Surg (Am)*, 92: 1-6.
10. **Zenke Y, Sakai A, Oshige Tet al. (2009):** The effect of an associated ulnar styloid fracture on the outcome after fixation of a fracture of the distal radius. *J Bone Joint Surg Br.*, 91:102-7.
11. **Buijze GA, Ring D (2010):** clinical impact of united versus nonunited fracture of the proximal half of the ulnar styloid following volar plate fixation. *J Hand Surg.*,35(2):223.
12. **Belotti JC, Morales VY, Alberes MB *et al.* (2010):**Ulnar styloid effect on wrist fracture. *J Orthop Sci.*, 15:216-222.
13. **Megan MM, Lawton JN, Blazar PE (2002):** Ulnar styloid fractures associated with distal radius fractures: incidence and implications for distal radioulnar joint instability. *J Hand Surg. (Am)*, 27(6):965e71.