

AMELIORATIVE EFFECT OF ALOE VERA GEL ON TRAMADOL REPRODUCTIVE TOXICITY IN ADULT ALBINO RATS

Rabab Fawzy Hindawy¹, Nagah Elsayed Mohammed Ali¹ and Fatma Fawzi Hendawy²

Forensic Medicine & Clinical Toxicology Department¹, and Pharmacology Department², Faculty of Medicine, Benha University, Egypt.



ABSTRACT

Background: Tramadol is an opioid pain medication used to treat premature ejaculation and as an antidepressant also young population abuse tramadol. Long-term administration of tramadol has negative impacts on many organs like ovary and testis. **Objectives:** The aim of study was to assess effect of tramadol on testes and ovaries of adult albino rats and to elucidate possible protective effect of Aloe Vera gel. **Methodology:** One hundred adult albino rats were used in present study. Animals were divided into five groups: control group; solvent control group; Aloe Vera gel group, tramadol group and tramadol and Aloe Vera gel group. Testes and ovaries were excised and specimens were processed for light, and electron microscopic examination. Blood samples were obtained to be tested for: testosterone, malondialdehyde (MDA), and reduced glutathione (GSH). **Results:** The present work detected a highly significant reduction in serum testosterone, and GSH levels and a highly significant increase in serum MDA levels in tramadol group as compared to control group. A highly significant increase in serum testosterone, and GSH levels and a highly significant reduction in serum MDA levels in tramadol and Aloe Vera gel group as compared to tramadol group and these results were non-significant as compared to controls. Tramadol-treated male rats showed dilatation in seminiferous tubules and vacuolation, testicular atrophy, and spermatogenic arrest, ovaries of tramadol-treated rats showed atretic follicles, with hyperplasia of corpus luteum (CL) and vacuolation. All histopathological changes, were ameliorated when Aloe Vera was co-administered with tramadol. **Conclusion:** Tramadol has harmful effect on testes and ovaries of rats. Administration of Aloe Vera accelerates healing of testicular tissue structure and has positive effect on testosterone level.

Keywords: testes, ovaries, rats, tramadol, Aloe Vera gel.

Corresponding author: Rabab Fawzy Hindawy (dr_rababhindawi@yahoo.com)

I. INTRODUCTION

Some diseases such as diabetic neuropathy, neuropathic pain, and perioperative conditions are associated with acute and chronic pain of moderate to severe intensity need intervention with a centrally acting synthetic opioid analgesic drug as tramadol hydrochloride. It is used also for premature ejaculation and as an antidepressant (Rafati et al., 2012). The testes and ovaries are affected by the long term use of tramadol, poor libido and erectile difficulty; in addition, testosterone and follicle stimulating hormone (FSH) levels were significantly reduced (Bliesener et al., 2005). An imbalance between the reactive oxygen species (ROS) production and the

ability to neutralize them via antioxidant enzymatic and/or non-enzymatic activity known as Oxidative stress (Anilakumar et al., 2010 and Behmanesh et al., 2017). This oxidative stress via large amounts of reactive intermediates leads to cell component damage and production of secondary toxic compounds e.g., reactive aldehydes and ketones. Moreover, MDA increased and thiol protein (G-SH) decreased (Agarwal and Parbakaran, 2005). Opioid administration may be involved in this mechanism and causes a decrease in the testosterone level by lowering the antioxidant capacity. Many herbs and plant products have been shown to have antioxidant action, which have led to increasing demand for herbal

products with antioxidant and disease preventive properties which have lower side effects (Marwa and Adel, 2014). Administration of Aloe Vera accelerates the total antioxidant capacity, accelerates healing of testicular tissue structure and has positive effect on testosterone level (Bliesener et al., 2005). The present work aimed to demonstrate the histopathological and biochemical changes in rat ovary and testicles due to usage of tramadol as well as the ameliorative effect of Aloe Vera gel on tramadol reproductive toxicity in adult male and female albino rats.

II. Material and Methods

1.1. Material:

1.1.1. Chemicals: provided by Hikma Pharmaceutical Co. (Giza, Egypt).

- Tramadol (the drug was in the form of tramadol hydrochloride tablets (225 mg/tablet). Each tablet is suspended in 20 ml distilled water (Soliman et al., 2017).
- Aloe Vera gel (viscous liquid).

1.1.2. Animals:

One hundred Adult albino rats (50 male and 50 female), aged about 6 weeks and weighing 180g - 200g were obtained from Experimental Animal Breeding Farm, Helwan-Cairo. Before experimentation, rats were subjected to one week period of passive preliminaries at animal bread house in order to adapt animals to their new environment, to ascertain their physical wellbeing and to exclude any diseased animals at the Anatomy Department, Benha Faculty of Medicine. This study was approved by the Local Ethical Committee for Scientific Research, Benha Faculty of Medicine

1.2. Methods:

Rats were divided into five equal groups (20 rats each):

1.2.1. Groups

- **Group I (-ve control):** Rats left without intervention to measure the basic parameters, free access to food and tap water was allowed for 4 weeks. It was subdivided into two subgroups:

Subgroup Ia: 10 male rats

Subgroup Ib: 10 female rats.

- **Group II (+ve control)** (solvent control): Each rat received solvent (distilled water) 1 ml/day orally for 4 weeks. It was subdivided into two subgroups:

Subgroup II a: 10 male rats

Subgroup II b: 10 female rats

- **Group III (Aloe Vera gel):** They received a daily oral gavage of Aloe Vera gel 300 mg/kg for 4 weeks (Bliesener et al., 2005). It was subdivided into two subgroups:

Subgroup III a: 10 male rats

Subgroup III b: 10 female rats

- **Group IV (tramadol):** Each animal received 50 mg/kg/day (1/5th LD50) (nearly 10 mg/rat/day) of tramadol orally by gavage for 4 weeks (Soliman et al., 2017).

It was subdivided into two subgroups:

Subgroup IV a: 10 male rats

Subgroup IV b: 10 female rats

- **Group V (tramadol and Aloe Vera gel):** They received tramadol at a dose of 50 mg/kg body weight along with 300 mg/kg Aloe Vera gel daily orally for 4 weeks. It was subdivided into two subgroups:

Subgroup V a: 10 male rats

Subgroup V b: 10 female rats

After experimental duration (4weeks), rats were anesthetized by ether inhalation and sacrificed.

1.2.2. Biochemical study:

Blood samples were obtained from rats' hearts. Samples were centrifuged for 10 min at 3000 r.p.m. Sera were put in the tubes to be tested for:

1.2.2.1. Testosterone concentration of male rats was measured by routine laboratory tests, i.e., radioimmunoassay (RIA) (Picard et al., 2008).

1.2.2.2. Oxidative stress indices: level of serum MDA measured by Spectrophotometry (Ohkawa et al., 1979).

1.2.2.3. Antioxidants: level of serum GSH measured by spectrophotometry (Beutler et al., 1963).

1.2.3. Histopathological study:

Testis and ovary were examined structurally and ultra-structurally by:

1.2.3.1. Light microscopy stained with (Hx&E), the results were examined at Pathology department, Benha faculty of medicine (Kierman, 2000).

1.2.3.2. Transmission electron microscopy at 80 kilo volts. Photographs were taken, developed, printed and examined at Electron microscope unit, Tanta University.

1.2.4. Statistical analysis:

Software (SPSS, Version 20.0 for Windows, SPSS Inc, Chicago, IL, 2011) was used for analyses of the data (Brink, 2011). Values were expressed as mean \pm standard deviation (Mean \pm SD). Kruskal-wallis test (KW) was used for

multiple comparisons of quantitative variables for non-parametric data with using Mann-whitney test (MW) and student t test (St t) for comparing means of two groups. Differences were considered significant at $P \leq 0.05$ and non-significant at $P > 0.05$.

III. Results**2.1. Biochemical study:**

In the present work negative control and positive control groups, showed a non-significant difference ($p > 0.05$) as regard biochemical parameters (testosterone concentrations, MDA and GSH), as showed in table 1. So, the mean of negative control group was chosen as a representative group for the two control groups to be compared with the results of the three treated groups.

Table (1): Statistical comparison between control groups regarding testosterone, serum MDA and GSH after 4 weeks of the study by Mann-Whitney test (MW) and student t test (St t).

Groups N =20	Testosterone ng/ml		MDA nmol/ ml		GSH mg/ ml	
	Median	IQR	Mean	\pm SD	Mean	\pm SD
Negative control	15.6	13.18-18.0	43.21	0.34	10.4	0.26
Positive control	13.2	13.0-18.73	43.60	0.86	10.3	0.26
Statistical test	MW= 1.67		St t= 1.33		St t= 0.86	
P	0.63 (NS)		0.10 (NS)		0.80 (NS)	

IQR: Interquartile range, **\pm SD:** \pm standard deviation, **NS:** non-significant $P > 0.05$ **N=20:** number of rats in each group= 20
MDA: malondialdehyde, and **GSH:** reduced glutathione.

As regard the levels of testosterone as well as serum levels of MDA and GSH, a highly significant difference ($p < 0.001$) between studied groups was observed, as illustrated in tables 2.

The present work detected a highly significant ($p < 0.001$) reduction in serum testosterone, and GSH levels and a highly significant ($p < 0.001$)

increase in serum MDA levels in tramadol treated group as compared to control group.

A highly significant ($p < 0.001$) increase in serum testosterone, and GSH levels and a highly significant ($p < 0.001$) reduction in serum MDA levels in tramadol and Aloe Vera gel treated group as compared to tramadol treated group and these results were non-significant as compared to control.

Table (2): Statistical comparison between studied groups regarding testosterone, serum MDA and GSH after 4 weeks of the study by Kruskal Wallis test (KW).

Groups N=20	Testosterone ng/ml		MDA nmol/ ml		GSH mg/ ml	
	Median	IQR	Median	IQR	Median	IQR
Control	15.6	13.18-18.0	43.1	43.0-43.5	10.41	10.14-10.66
Aloe Vera gel	15.65	13.48-18.05	43.06	43.5-43.8	10.6	10.32-10.8
Tramadol	4.1 [^] #	0.56-4.33	81.4 [^] #	80.64-83.33	3.9 [^] #	3.38-4.0
Tramadol and Aloe Vera gel	16.25 \$	14.49-19.34	43.4 \$	43.28-43.51	10.25 \$	9.7-10.3
Statistical test	KW=31.54		KW=33.21		KW=31.87	
P	<0.001** (HS)		<0.001** (HS)		<0.001** (HS)	

IQR: Interquartile range, N=20: number of rats in each group= 20, MDA: malondialdehyde, and GSH: reduced glutathione
[^]:significant with control #:significant with Aloe Vera gel \$:significant with Tramadol ** (HS): high significant p<0.001

2.2. Histopathological study:

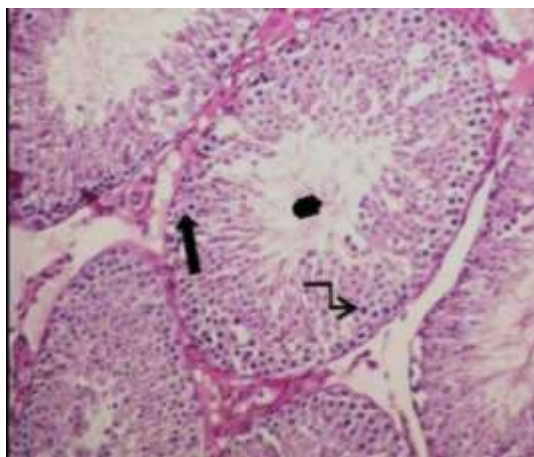


Fig.(1): A photomicrograph of a section from rat's testis of the control group showing normal architecture with well-arranged seminiferous tubules with basal lamina and normal interstitial tissue. Each tubule lined with stratified epithelium (spermatogenic cells) and supporting Sertoli cell (↗). Notice the healthy spermatogenic cells (→) and spermatozoa (⊙). (Hx&E x 200)

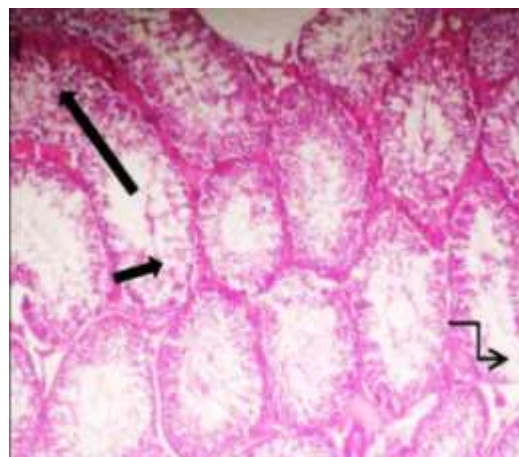


Fig.(2): A photomicrograph of a section from testis of tramadol treated rat showing dilatation of seminiferous tubules with spermatogenic arrest (Long arrow), vacuolation (Short arrow), rupture of a seminiferous tubule (↗). (Hx&E x100).

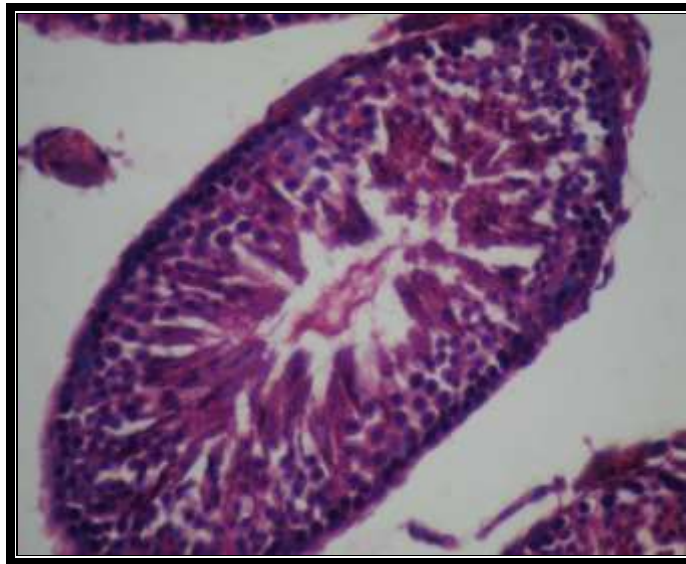


Fig. (3): A photomicrograph of a section in testis from tramadol and Aloe Vera gel treated rat showing normal architecture with well-arranged seminiferous tubule and normal interstitial tissue. (Hx&E x 200)

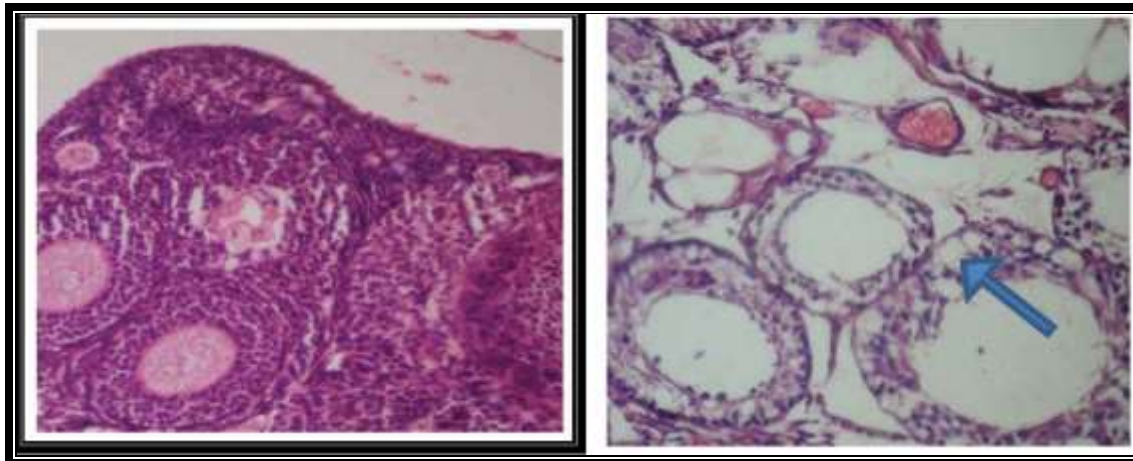


Fig. (4): A photomicrograph of a section in rat's ovary from a control group showing normal architecture with well-arranged follicles. (Hx&E x200).

Fig. (5): A photomicrograph of a section in ovary from tramadol treated rat showing vacuolar degeneration in atretic follicles (**arrow**). (Hx&E x200)

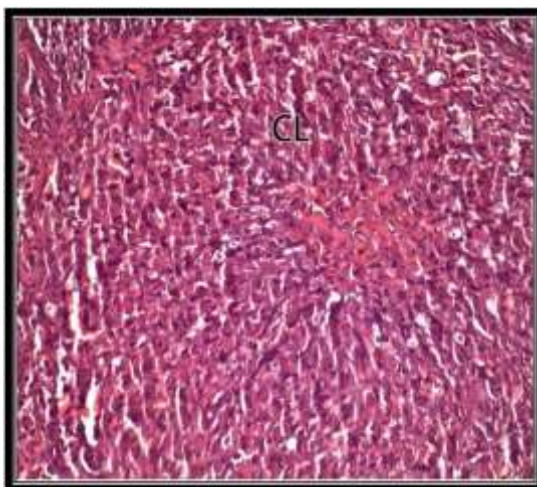


Fig.(6): A photomicrograph of a section in ovary from tramadol treated rat showing corpus luteum hyperplasia (CL). (Hx&E x400)

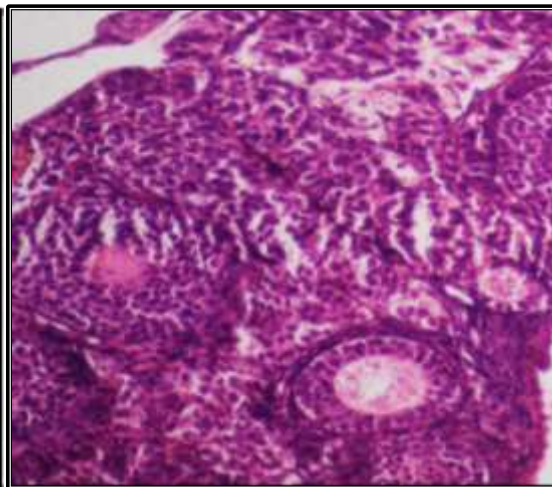


Fig.(7): A photomicrograph of a section in ovary from tramadol and Aloe Vera gel treated rat showing normal architecture with well-arranged follicles. (Hx&E x200)

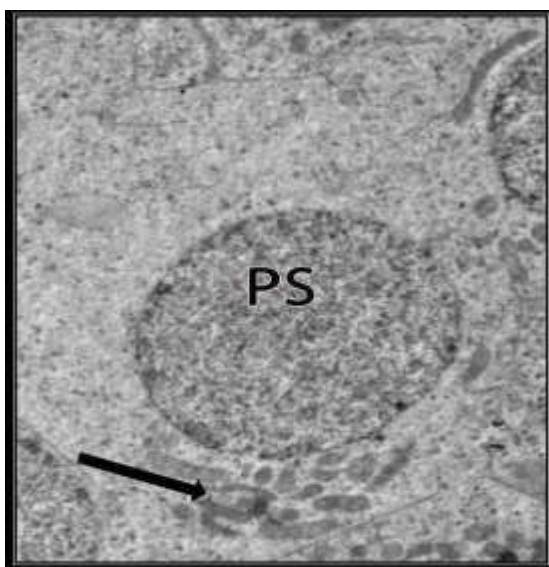


Fig. (8): An electron micrograph of an ultrathin section of testis from a control rat showing primary spermatocyte (PS) with normal architecture and normal interstitial tissue. A primary spermatocyte was with rounded euchromatic nucleus and peripherally arranged mitochondria (arrow) in the cytoplasm (TEM x2000)

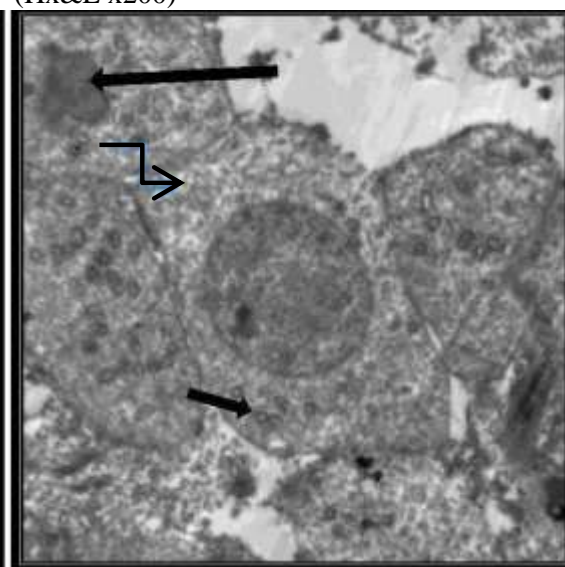


Fig. (9): An electron micrograph of an ultrathin section of testis from tramadol treated rat showing abnormal primary spermatocyte with irregular nucleus (long arrow), swollen mitochondria (short arrow), and vacuolation (blue arrow) (TEM x1500)




Fig. (10): An electron micrograph of an ultrathin section of testis from tramadol treated rat showing abnormal primary spermatocyte with heterochromatic nucleus (**long arrow**), swollen mitochondria (**short arrow**), and vacuolation (**blue arrow**). (TEM x2500)

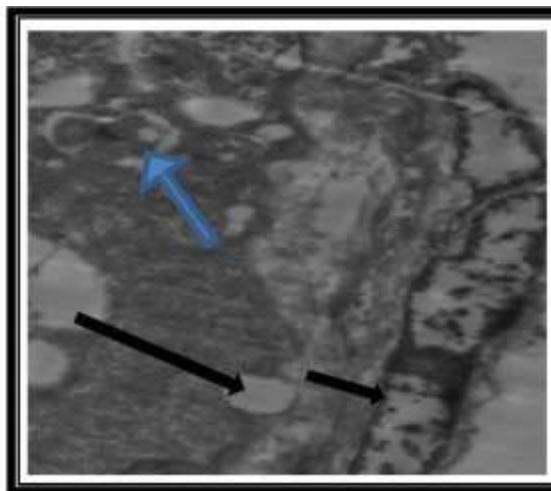


Fig. (11): An electron micrograph of an ultrathin section of testis from tramadol treated rat showing abnormal Basement membrane (**short arrow**), multinucleated giant bodies (**blue arrow**) and vacuolation (**long arrow**). (TEM x1500)

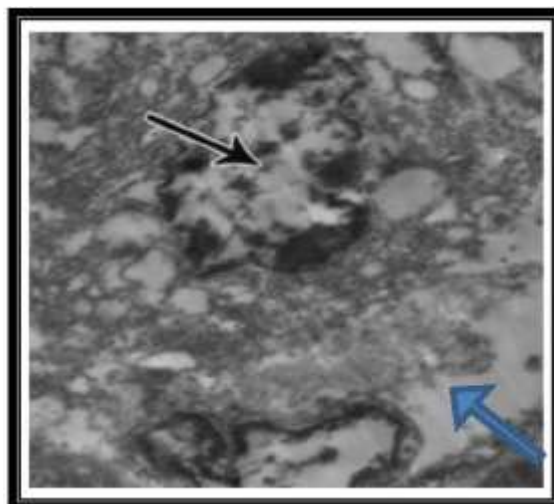


Fig.(12): An electron micrograph of an ultrathin section of testis from tramadol treated rat showing Leydig cell with irregular heterochromatic nucleus (**black arrow**) and intercellular space with more collagen fibers (**blue arrow**). (TEMx2500)

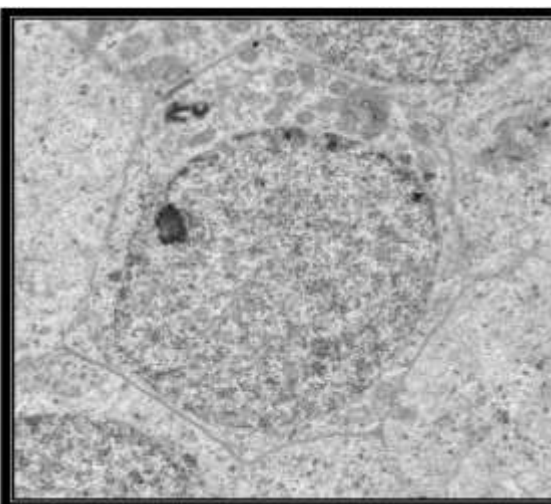


Fig.(13): An electron micrograph of an ultrathin section of testis from tramadol and Aloe Vera gel treated rat showing normal primary spermatocyte. (TEM x3000)

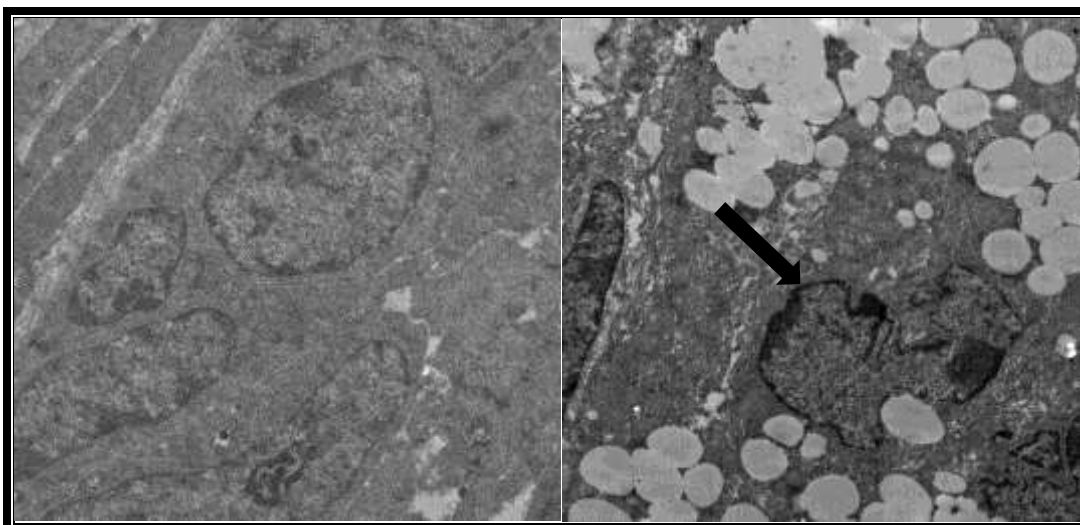


Fig. (14): An electron micrograph of an ultrathin section of ovary from a control rat showing normal follicular cells with regular nucleus. (TEM x2500)

Fig. (15): An electron micrograph of an ultrathin section of ovary from tramadol treated rat showing follicular degeneration with indented nucleus (**arrow**) and vacuolation (follicular atresia). (TEM x2000)

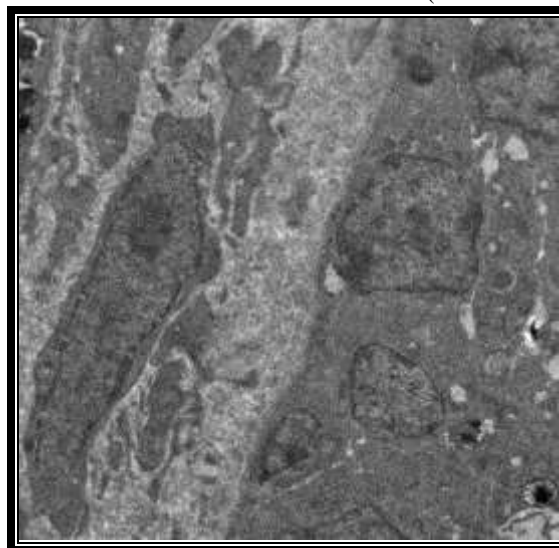


Fig. (17): An electron micrograph of an ultrathin section of ovary from tramadol and Aloe Vera gel treated rat showing normal follicular cells with regular nucleus. (TEM x2500)

IV. DISCUSSION

Tramadol hydrochloride is a centrally acting synthetic opioid analgesic drug. It is used also for premature ejaculation and as an antidepressant (Rafati et al., 2012). The wide abuse of tramadol among young population made it mandatory to investigate the biochemical and histopathological effects of this drug on reproductive tissue in adult albino rats (Caju et al., 2012). This study aimed to assess effect of tramadol on testes and ovaries

of adult albino rats and to elucidate possible protective effect of Aloe Vera gel.

The present work detected a highly significant reduction in serum testosterone in group IVa (tramadol treated group) as compared to control groups. These findings are similar to the results achieved by Omid et al. (2014) who found that significantly reduced serum testosterone hormone level occurred with long-term tramadol use.

Bliesener et al. (2005) observed the decreased FSH, LH and testosterone levels associated

with tramadol administration through affecting gonadotropin-releasing hormone (GnRH). Also, El-Gaafarawi (2006) observed that tramadol causes reduction of serum levels of LH, FSH and testosterone. Furthermore, opioid-binding sites have been found in Sertoli cells, suggesting an additional peripheral site of action capable of blocking testosterone hormone synthesis and/or increasing hormone degradation. Also, Ceccarelli et al. (2006) reported that morphine, tramadol and buprenorphine cause decreasing of testosterone generation, loss of drive and erectile / ejaculatory dysfunctions among men. Sedative manhandle may bring about hypogonadism; basically by diminishing the arrival of GnRH, testosterone deficiency and infertility (Vuong et al., 2010).

Tramadol exposure disrupts oxidant-antioxidant balance (Keshavars et al., 2012) and causes oxidative damage and free radical formation (Anilakumar et al., 2010); especially on testes that contain abundant amounts of polyunsaturated fatty acids in their plasma membranes resulting in lipid peroxidation and free radical formation (Youssef and Zidan, 2016).

The oxidative stress via large amounts of reactive intermediates leads to cell component damage and production of secondary toxic compounds e.g., reactive aldehydes (MDA) and ketones, tramadol administration may be involved in this mechanism and causes a decrease in the testosterone level by lowering the antioxidant capacity. Moreover, MDA increased and GSH decreased (Agarwal and Parbakaran, 2005).

The present work detected a highly significant increase in MDA levels and reduction in serum GSH levels in group IV (tramadol treated group) as compared to control groups.

The present findings confirmed the results of a previous study conducted by Ahmed and Kurkar, (2014) who postulated that tramadol causes lipid peroxidation and increase in MDA levels. The significant decrease in GSH activity can be explained by its consumption during the

detoxification of reactive oxygen metabolites (Hamza and Al-Harbi, 2014).

Aloe Vera gel, having antioxidant properties, can ameliorate tramadol effects when was co-administered with it. Flavonoids present in Aloe Vera gel can increase the level of testosterone (Keshavars et al., 2012). The present study showed a highly significant increase in serum testosterone to normal level in Group Va (tramadol and Aloe Vera gel treated group) as compared to group IVa (tramadol treated group) and these results were non-significant as compared to control groups.

The present work recorded a highly significant reduction in serum MDA and increase in serum GSH levels in Group V (tramadol and Aloe Vera gel) as compared to group IV (tramadol treated group) and these results were non-significant as compared to control groups. All biochemical changes were ameliorated when Aloe Vera was co-administered with tramadol. Aloe Vera was found to be effective in increasing the GSH and decreasing the MDA confirming the previously recorded antioxidant effect, due to its phenolic and flavonoids contents (Keshavars et al., 2012). Also, Haritha et al. (2014) showed that Aloe Vera can reduce highly reactive oxygen species that can cause extensive damage to cell membranes lipids, and decrease MDA, which is in consistency with our study.

Histopathological results supported the evidence of biochemical results in this study. The testicular specimens of tramadol-treated male rats revealed dilatation and rupture in seminiferous tubules, vacuolation, testicular atrophy, hypospermia and spermatogenic arrest. These findings are in agreement with Soliman et al. (2017).

Youssef and Zidan (2016) attributed these findings to the oxidative damage and free radical formation by tramadol, especially on testis because testicular tissue and sperms contain abundant amounts of polyunsaturated fatty acids in their plasma membranes. Ahmed and Kurkar (2014) found that tramadol causes lipid peroxidation, decreases the antioxidant enzyme activities, and increases the level of the

testicular nitric oxide which facilitates testicular tissue damage.

Another explanation of the effects of tramadol is reported by Abou El Fatoh et al. (2014) who demonstrated that tramadol decreases the level of sex hormones in male rats when compared with control. There was a reduction in plasma levels of luteinizing hormone, follicle stimulating hormone, and testosterone, which may be responsible for bad effects of tramadol on testes.

In this study, ultrastructure examination of the testicular specimens of the tramadol-treated male rats revealed abnormal seminiferous tubules, apoptotic spermatogenic cells with irregular heterochromatic nucleus, swollen mitochondria, and vacuolation, also abnormal sertoli cells with irregular nucleus and vacuolation. Giant multinucleated bodies were found. Pleomorphic leydig cells with irregular nucleus, condensed chromatin and vacuolation were observed beside intercellular space presenting greater amount of collagen fibers. These findings were in agreement with Ghoneim et al. (2014) and Elsayy and Abdel Malak (2015). Elkhateeb et al. (2015) said that increased collagen fibers in tissues treated with tramadol occurred due to decreased collagen metabolism, which may be caused by the oxidative stress caused by tramadol.

Abdellatif et al. (2014) explained Sertoli cell vacuolation being secondary to metabolic disturbance. They postulated that Sertoli cells are largely influenced by testosterone, producing androgen-binding protein and other products under the control of follicle stimulating hormone. Tramadol administration disturbed this link and induced morphological alteration due to testosterone deprivation.

The giant multinucleated cells might result from widening of the intercellular bridge between adjacent spermatids resulting in subsequent fusion of two or more cells (Hess and Nakai, 2000).

In this study, histopathological examination of the ovaries of tramadol-treated female rats after 4 weeks of tramadol administration, showed atretic follicles, with hyperplasia of corpus

luteum (CL) and vacuolar degeneration. Ali et al. (2018) observed degenerative changes in the granulosa cells of secondary follicles in ovaries of low dose tramadol. Also, Luteinizing hormone is known to stimulate the development of ovarian follicles in cooperation with follicle-stimulating hormone from the pituitary gland. So, immature ovaries and increased numbers of atretic follicles observed in this study may have been induced by lower LH secretion caused by tramadol (Haritha et al., 2014).

Electron microscopic observation of ovaries revealed that luteal hypertrophy of CL in tramadol treated group which caused by excessive storage of lipid droplets of luteal cells became enlarged (Omid et al., 2014).

All histopathological changes, were ameliorated when Aloe Vera was co-administered with tramadol, this is because flavonoids present in Aloe Vera gel can increase the level of testosterone; also, antioxidant compounds found in Aloe Vera (especially vitamin E) which ameliorate the oxidative stress caused by tramadol and prohibit reductions in the number of Leydig and Sertoli cells (Moghaddam et al, 2015).

V. Conclusion and Recommendations

Tramadol therapy for either addiction or chronic pain may induce hypogonadism. Tramadol causes an increase in MDA and decrease in GSH. Aloe Vera gel, having antioxidant properties, can ameliorate tramadol effects when was co-administered with it. Flavonoids present in Aloe Vera gel could increase the level of testosterone.

In view of the increased use of tramadol for chronic pain, patients on tramadol therapy should be routinely screened for hypogonadism symptoms and for laboratory abnormalities in sex hormones. We recommend nonopioid pain management or use antioxidants e.g. Aloe Vera gel. Also, awareness plans targeting youth should be done to point out tramadol's effects on their hormonal profile and sexual functions. Educational programs should be regularly held focusing rural areas and skilled workers to simplify hazards of tramadol dependence.

VI. ACKNOWLEDGEMENT

Our deep appreciation to the staff members of Forensic Medicine & Clinical Toxicology; Pharmacology, Anatomy and Pathology Departments, Faculty of Medicine, Banha University, and Electron microscope unit, Tanta University for their cooperation.

VII. REFERENCES

1. Abdellatif RB, Elgamal DA and Mohamed EE (2014): Effects of chronic tramadol administration on testicular tissue in rats: an experimental study. *Andrologia*; 47:674–679.
2. Abou ElFatoh MF, Farag M and Sayed AE et al. (2014): Some biochemical, neurochemical, pharmacotoxicological and histopathological alterations induced by long-term administration of tramadol in male rats. *Int J Pharm Sci.*; 4:565–571
3. Agarwal A and Parbakaran SA (2005): Mechanism, Measurement and Prevention of Oxidative Stress in Male Reproductive Physiology. *Indian J. of Experimental Biology*; 43(11): 963-974.
4. Ahmed MA and Kurkar A (2014): Effects of opioid (tramadol) treatment on testicular functions in adult male rats: the role of nitric oxide and oxidative stress. *Clin Exp Pharmacol Physiol.*; 41:317–323.
5. Ali RA, Mohi-Eldin MM and Mohammed HA (2018): Evaluation the Toxicity of Accumulated Dose of Tramadol on Gonads of Albino Rat. *RJPBCS.*; 9(6): 1786-1799.
6. Anilakumar KR, Sudarshanakrishna KR and Chandramohan G (2010): Effect of Aloe Vera gel extract on antioxidant enzymes and azoxymethane-induced oxidative stress in rats. *Indian J Exp Biol.*; 48(8):837–842.
7. Behmanesh MA, Erfani MN and Shahriari A et al. (2017): Evaluation of antioxidant potential of Aloe Vera and pituitary sexual hormones after experimental diabetes in male rats. *Iran J Vet Med.*; 11(2):164–174.
8. Beutler E, Duron O and Kelly BM (1963): Improved method for the determination of blood glutathione. *J Lab Clin Med.*; 61: 882-8.
9. Bliesener N, Albrecht S and Schwager A et al. (2005): Plasma Testosterone and Sexual Function in Men Receiving Buprenorphine Maintenance for Opioid Dependence. *The Journal of Clinical Endocrinology & Metabolism*; 90(1): 203-206.
10. Brink D (2011): *Essentials of statistics*, Brink D (ed.), ventus publishing APS: Frederiksberg, Denmark. 2nd ed.: 1-103.
11. Caju FM, Gian QGD and Sandra MT et al. (2012): Opioid System Manipulation during Testicular Development: Results On Sperm Production and Sertoli Cells Population. *Acta Scientiarum Biological Sciences*; 33(2): 219-225.
12. Ceccarelli I, De Padova AM and Fiorenzani P et al. (2006): Single Opioid Administration Modifies Gonadal Steroids in Both The CNS and Plasma of Male Rats. *Neuroscience*; 140(3): 929-937.
13. Elkhateeb A, El Khishin I and Megahed O et al. (2015): Effect of Nigella sativa Linn oil on tramadol-induced hepato- and nephrotoxicity in adult male albino rats. *Toxicol Rep.*; 2:512–519
14. Elsayy MM and Abdel Malak HW (2015): Effect of tramadol abuse on testicular tissue of adult albino rats: a light and electron microscopic study. *Egypt J Histol.*; 38:356–366
15. Ghoneim FM, Khalaf HA and Elsamanoudy ZA et al. (2014): Effect of chronic usage of tramadol on motor cerebral cortex and testicular tissues of adult male albino rats and the effect of its withdrawal: histological, immunohistochemical and biochemical study. *Int J Clin Exp Pathol.*; 7:7323–7341.
16. Hamza RZ and Al-Harbi MS (2014): Monosodium glutamate induced testicular toxicity and the possible

- ameliorative role of vitamin E or selenium in male rats. *Toxicol Rep.*; 22(1):1037-1045
17. Haritha Kh, Ramesh B and Saralakumari D (2014): Effect of Aloe Vera gel on antioxidant enzymes in streptozotocin-induced cataractogenesis in male and female Wistar rats. *Journal of Acute Medicine*; 4(1):38–44.
 18. Hess RA and Nakai M (2000): Histopathology of the male reproductive system induced by the fungicide benomyl. *Histol Histopathol.*; 15:207–224.
 19. Keshavars M, Takhshid MA and Tavasoli A (2012): The protective effects of vitamin E and C against oxidative stress induced by sulfasalazine in the testis of male adult rats. *J Fasa Univ Med Sci.*; 1:206–221.
 20. Kierman JA (2000): Formaldehyde, formalin, paraformaldehyde and glutaraldehyde: what they are and what they do. *Micros. Today*; 12:8–12.
 21. Marwa AA and Adel K (2014): Effects of Opioid (Tramadol) Treatment on Testicular Functions in Adult Male Rats, the Role of Nitric Oxide and Oxidative Stress. *Clinical and Experimental Pharmacology and Physiology*; 41(4): 317-323.
 22. Moghaddam HS, Samarghandian S and Farkhondeh T (2015): Effect of bisphenol A on blood glucose, lipid profile and oxidative stress indices in adult male mice. *Toxicol Mech Methods*; 25(7):507–513.
 23. Ohkawa H, Ohishi N and Yagi K (1979): Assay for lipid peroxidation in animal tissues by thiobarbituric acid reaction. *Annals of Biochemistry*; 95: 351–358.
 24. Omid A, Ladan E and Reza K et al. (2014): The Effects of Long-Term Administration of Tramadol on Epididymal Sperm Quality and Testicular Tissue in Mice. *Iranian Journal of Veterinary Surgery*; 9(1): 23-30.
 25. Picard WB, Kuczka K and Harder S et al. (2008): Biomarkers and coagulation tests for assessing the biosimilarity of a generic low-molecular-weight heparin: results of a study in healthy subjects with enoxaparin. *J Clin Pharmacol.*; 48(10):1189-96.
 26. Rafati A, Yasini SM and Norani F et al. (2012): Tramadol Dependence Rate As Compared With Morphine in Rats. *World Journal of Medical Sciences*;1(1):40-43.
 27. Shibayama M, Ohno S and Osaka T et al. (2009): Polypyrimidine tract-binding protein is essential for early mouse development and embryonic stem cell proliferation. *FEBSJ.*; 276 (22):6658-68.
 28. Soliman ME, Atteya SE and Ghobashy HA et al. (2017): The effect of tramadol on seminiferous epithelium of albino rats and the protective effect of vitamin C. *Menoufia Med J.*; 30:1125-34.
 29. Vuong T, Matar C and Ramassamy C et al. (2010): Biotransformed blueberry juice protects neurons from hydrogen peroxide-induced oxidative stress and nitogen-activated protein kinase pathway alterations. *Br J Nutr.*; 104(5): 656-63.
 30. Youssef HS and Zidan AHM (2016): Histopathological and biochemical effects of acute and chronic tramadol drug toxicity on liver, kidney and testicular function in adult male albino rats. *J Med Toxicol Clin Forensic Med.*; 1:2.

التأثير المحسن لجل الصبار على الآثار السمية لعقار الترامادول على الجهاز التناسلي في الجرذان البيضاء المشاركون في البحث

رباب فوزى هنداوى¹، نجاح السيد محمد على¹، فاطمة فوزى هنداوى²

قسم الطب الشرعي و السموم الإكلينيكية¹ و قسم الفارماكولوجى²

كلية الطب البشري - جامعة بنها- مصر

ينتمي دواء الترامادول إلى فئة المسكنات الأفيونية ، ويستخدم للتخلص من الآلام المتوسطة والشديدة، ويستخدم كمضاد للاكتئاب وعلاج سرعة القذف. وقد وجد ان الترامادول مسئول عن التأثيرات الضارة الخطيرة التي تصيب الجهاز التناسلي. وعلى ذلك فان هذه الدراسة قد اجريت بهدف تقييم التأثير الوقائي لجل الصبار على التأثيرات السمية للترامادول على الجهاز التناسلي في ذكور واثان الجرذان البيضاء البالغة. وقد أجريت هذه الدراسة على مائة من ذكور واثان الجرذان البيضاء البالغة حيث تم تقسيمهم الى خمس مجموعات (عشرين لكل مجموعة). أما المجموعة الأولى فقد استخدمت كمجموعة ضابطة والمجموعة الثانية مجموعة المذيب الضابطة والمجموعة الثالثة مجموعة جل الصبار والمجموعة الرابعة مجموعة عقار الترامادول و قد تم اعطاؤها (50 مج / كج /يوميا عن طريق الفم) لمدة 4 اسابيع والمجموعة الخامسة مجموعة عقار الترامادول و جل الصبار وقد تم اعطاؤها عقار الترامادول 50 مج / كج مع جل الصبار 300 مج / كج يوميا عن طريق الفم لمدة اربع اسابيع. فى نهاية مدة الدراسة فانه يتم ذبح الجرذان ثم أخذ عينة الدم لاجراء التحليل لهرمون التستوستيرون والجلوتاثيون (احد مضادات الاكسدة) والمالونالدوهيد (احد مؤشرات اجهاد التاكسد). ايضا أخذ عينات من خصى ومبايض الجرذان من كل المجموعات ليتم فحصهم بالميكروسكوب الضوئى والألكترونى و قد نتج عن هذه الدراسة نقصان ذو دلالة إحصائية في مستويات هرمون التستوستيرون والجلوتاثيون وزيادة في المالونالدوهيد في المجموعة الرابعة (الترامادول) بالمقارنة مع المجموعة الضابطة. وزيادة ذو دلالة احصائية في هرمون التستوستيرون والجلوتاثيون ونقصان في المالونالدوهيد فى المجموعة الخامسة (الترامادول و جل الصبار) بالمقارنة مع المجموعة الرابعة (الترامادول) وهذه النتائج ليس لها دلالة احصائية بالمقارنة مع المجموعة الضابطة. ترتبط هذه النتائج البيوكيميائية مع التغيرات الباثولوجية فى أنسجة الخصية المصبوغة بواسطة الهيماتوكسيلين والأيوسين. وكانت هذه التغيرات فى شكل اتساع فى الانابيب المنوية، قلة الحيوانات المنويه أو عدم وجودها، تفكك وفصل فى الخلايا الجرثومية. أظهر النسيج الخلالي تورم مع وجود عدد غير منظم وقليل من خلايا ايديج مع ضمور فى خلايا الخصية . كما أوضح فحص أنسجة المبيض المصبوغة بواسطة الهيماتوكسيلين والأيوسين، أن هناك العديد من الحويصلات مع انحطاط وتفكك فى الحويصلات وتضخم فى الجسم الاصفر غير منتظم الشكل. وهذه التغيرات الباثولوجية تحسنت عند اعطاء الترامادول مع جل الصبار. ومما سبق نستخلص ان التعرض للترامادول يسبب اضطرابات هرمونية و باثولوجية على خصى ومبايض ذكور واثان الجرذان و تحسنت عند اعطاء جل الصبار. يوصى بالتوعية بمخاطر الترامادول على الاعضاء التناسلية (الخصى والمبايض) و دور مضادات الاكسدة (جل الصبار) كمحسن لهذه المخاطر.