

## **Dietary supplementation with Punica and Physalis attenuates the deleterious effects of fenitrothion in rats.**

**Rasha Abdel-Ghany<sup>1</sup>, Ebaa Mohammed<sup>1,#</sup>, Shimaa Anis<sup>1,#</sup>, Ahmed Bihery<sup>2</sup> and Waleed Barakat<sup>1,3,\*</sup>**

<sup>1</sup> Department of Pharmacology & Toxicology, Faculty of Pharmacy, Zagazig University, Egypt. <sup>2</sup> Department of Tropical Medicine, Faculty of Medicine, Zagazig University, Egypt.

<sup>3</sup> Department of Pharmacology & Toxicology, Faculty of Pharmacy, Tabuk University, Kingdom of Saudi Arabia. # Equal contribution.

\* Corresponding author Email: [waled055@yahoo.com](mailto:waled055@yahoo.com)

---

### **ABSTRACT:**

Exposure to pesticides may result in several health hazards including liver impairment which might be followed by impairment of brain functions or renal functions.

The current study was designed to test the beneficial effects of dietary supplement with *Physalis peruviana* and *Punica granatum* against toxicity induced by fenitrothion. The toxic effect of fenitrothion, 10 mg/kg/day, orally for 28 day) on liver, brain and kidney functions and the prophylactic effect of daily *Physalis* (15 % of diet) and *Punica* (3 ml/kg) for 42 days starting 14 days before fenitrothion were investigated.

Fenitrothion caused early impairment in liver functions accompanied by alteration in serum lipid profile and electrolyte level. Fenitrothion caused an elevation in liver ammonia then serum ammonia then brain ammonia. Both brain and kidney functions were impaired later. Fenitrothion caused a state of oxidative stress in liver, brain and kidney. Prophylaxis with *Physalis*, *Punica* or the standard hepatoprotective drug, silymarin largely ameliorated these deleterious effects which might be attributed to their antioxidant properties.

These results suggest that *Physalis* and *Punica* might be future candidates for use in the treatment of toxicity by pesticides and further research is required to identify the active ingredients responsible for these protective actions.

**Key words:** *Physalis peruviana*, *Punica granatum*, fenitrothion, Organ, Injury.

---

### **INTRODUCTION**

The wide use of pesticides as organophosphorous insecticides (OPIs) causes environmental pollution and potential health hazards. From these hazards, liver disorders are the most common including liver cirrhosis (Prakash and Mullen, 2010). The mechanisms behind OPIs toxic effects include exacerbation of oxidative stress, ammonia production, inhibition of cholinesterases (ChE) with subsequent activation of cholinergic receptors (El-Demerdash, 2011) and alterations in the lipid profile (Lasram et al., 2009). Liver injury associated with organophosphorous insecticides (OPIs) is evidenced by an increase in the enzymatic activity of alanine aminotransferase (ALT), aspartate aminotransferase (AST) and

reduced serum albumin level (Celik et al., 2009).

Hepatic injury can be followed by impairment of brain functions or renal functions due to accumulation of various toxic molecules as ammonia which may induce hepatic encephalopathy (HE) and/or hepatorenal syndrome (HRS) (Vaquero et al., 2003). Hepatic encephalopathy, a neuropsychiatric syndrome associated with increased blood and brain ammonia and is characterized by disturbances in mental, emotional and intellectual functions (Ferenci et al., 2002). Oxidative stress is believed to play a role in the pathogenesis of HE because acute doses of ammonia lead to the induction of oxidative stress (Norenberg et al., 2004).

Hepatorenal syndrome represents a functional reversible renal failure including uremia and chronic kidney disease. It is diagnosed by excluding other causes of renal impairment in patients with hepatic failure, acute and chronic liver disease, and portal hypertension (Schepke, 2007).

Natural dietary antioxidants have important role in healthcare because of their wide biological and medicinal activities, higher safety margins and low costs. *Physalis peruviana* has hepatoprotective, antioxidant and anti-inflammatory activities as well as anti-proliferative effects on hepatoma cells (Wu et al., 2004). *Punica granatum* is claimed to have both prophylactic and curative properties against diabetes, cardiovascular diseases, liver damage and aging (Kaur et al., 2006). Silymarin is an antioxidant flavonoid complex derived from the herb milk thistle (*Silybum marianum*) which is frequently used in the treatment of liver diseases (Mansour et al., 2006).

The aim of the present study is to investigate the possible protective effect of dietary supplement with *Physalis*, *Punica* against liver damage induced in rats by fenitrothion (OPIs) in comparison to the standard hepatoprotective silymarin. This study will also investigate the influence of liver injury induced by fenitrothion on brain and kidney functions and whether *Physalis*, *Punica* and silymarin would have a protective effect on brain and kidney functions.

## **MATERIALS and METHODS**

### **1. Materials:**

Fenitrothion insecticide (Sumithion 50<sup>®</sup>) was purchased from Kafr Elzayat Co. for Insecticide Ind., Kafr Elzayat, Egypt. Fenitrothion suspension was freshly prepared by diluting fenitrothion with distilled water to 10 mg/ml and orally administered in a dose of 10 mg/kg (Korany and Ezzat, 2011).

Ripe *Physalis peruviana* fruits (golden berry), family Solanaceae were obtained from local source in Zagazig, Sharkiah, Egypt. The

authenticity of the plant species was confirmed by Pharmacognosy Department, Faculty of Pharmacy, Zagazig University. Only fruits at similar ripening stage were selected for processing. Juice was prepared using a commercial blender (Braun, ZK 200, Germany), filtered and pasteurised at 80 °C for 10 min to inactivate endogenous enzymes. Small aliquots (75 ml) of juice were stored at -20 °C for no longer than 2 months. Aliquots were defrosted and immediately mixed with the animal diet at a ratio of 15 g juice/100 g food (Ramadan and Moersel, 2007).

*Punica granatum* (Pomegranate): Ripe *Punica granatum* fruits, family Punicaceae were obtained from local source in Zagazig, Sharkiah, Egypt. The authenticity of the plant species was confirmed by Pharmacognosy Department, Faculty of Pharmacy, Zagazig University. Pomegranates were washed and manually peeled, without separating the seeds. Juice was prepared using a commercial blender (Braun, ZK 200, Germany), filtered and immediately diluted with distilled water (1:3) and stored at -20°C for no longer than 2 months. Aliquots were defrosted immediately and orally administered in a dose of 3 ml/kg (Faria et al., 2007).

The aqueous extract of silymarin was provided as a kind gift from MEBACO, Pharmaceutical Company, Cairo, Egypt. Silymarin extract suspension was prepared by suspending 100 mg of silymarin extract in 1 ml distilled water and orally administered in a dose of 100 mg/kg (Galal et al., 2012).

### **2. Animals**

Male albino rats weighing 150–180 g were obtained from National Research Center, Cairo, Egypt and were housed in plastic cages, allowed free access to a standard diet and tap water. The rats were housed at 23 ± 2° C 12 hr dark/light cycle. All experimental procedures were approved by the Ethical Committee for Animal Handling at Zagazig University (ECAHZU) (NO: P7-3-2013) and (NO: P8-3-2013). Animals were sacrificed at the end of

experiment by decapitation after fasting overnight.

Animals were randomly allocated into one of the following groups (n = 10): control group (oral distilled H<sub>2</sub>O, 3 ml/kg/day for 42 day), F1 (oral fenitrothion, 10 mg/kg/day for 7 days), F2 (oral fenitrothion 10 mg/kg/day for 14 day), F3 (oral fenitrothion, 10 mg/kg/day for 21 day), F4 (oral fenitrothion, 10 mg/kg/day for 28 day), Phy (oral Physalis juice, 15% of diet/day for 42 day and fenitrothion, 10 mg/kg/day for 28 day starting from day 15 of Physalis administration), Pun (oral Punica juice 3ml/kg/day for 42 day and fenitrothion, 10 mg/kg/day for 28 day starting from day 15 of Punica administration) and Sil (oral silymarin, 100 mg/kg/day for 42 day and fenitrothion, 10 mg/kg/day for 28 day starting from day 15 of silymarin ).

At the end of experiment, after overnight fasting, blood was collected from the retro-orbital plexus vein and centrifuged at 3500 rpm for 15 minutes with or without heparin and serum/plasma was collected and stored at -20°C. Animals were sacrificed and liver, brain cortex and kidney were excised for preparation of tissue homogenates.

### 3. Methods

AChE activity in brain was determined colorimetrically (Ellman et al., 1961), amino acid (glutamate and GABA) and monoamine (DA, NE and 5-HT) level in brain cortex were determined fluoremetrically (Harrison et al., 1979; Lowe et al., 1958).

Catalase (CAT) activity, reduced glutathione (GSH) and malondialdehyde (MDA) level in tissue (liver, brain and kidney) were determined colorimetrically (Beutler et al., 1963; Sinha, 1972; Yoshioka et al., 1979).

The following parameters were assayed in serum using kits supplied by Biodiagnostic Co (Cairo, Egypt); ALT activity, ALP activity, Albumin level, Butrylcholiesterase activity, Sodium level, Potassium level, Magnisium level, Cholesterol level, HDL-cholesterol level, LDL-cholesterol level,

blood urea nitrogen (BUN) level, Creatinine level and Uric acid level. Prothrombin time was determined in plasma using kit supplied by Biodiagnostic Co (Cairo, Egypt). Liver, serum and brain ammonia level was determined by colorimetric method using a kit supplied by Biodiagnostic Co (Cairo, Egypt).

### 4. Statistical analysis:

The results are expressed as means  $\pm$  SD. The statistical significance of the data has been determined using one way analysis of variance (ANOVA) followed by LSD and Tukey's post hoc test using SPSS software package version 10. The level of significance was taken as  $P < 0.05$ .

## RESULTS

### 1. Effect on liver functions

Administration of fenitrothion for 7, 14, 21 and 28 days (F1, F2, F3 and F4 respectively), caused a significant increase in serum ALT, ALP activities and prothrombin time compared with control group while, treatment with Physalis, Punica or silymarin for 42 (starting 14 days before fenitrothion) induced a significant decrease in serum ALT, alkaline phosphatase (ALP) activities and prothrombin time compared with F4 group (**Table 1**).

**Table (1)** also shows that administration of fenitrothion for 7, 14, 21 and 28 days (F1, F2, F3 and F4, respectively), caused significant reduction in serum albumin level and serum butrylcholine esterase (BuChE) activity compared with control group and treatment with Physalis, Punica or silymarin for 42 days (starting 14 days before fenitrothion) caused a significant increase in serum albumin level and serum BuChE activity compared with F4 group.

Table (1): Effects of daily oral administration of fenitrothion (10mg/kg) alone or in combination with Physalisperuviana (15% of diet), Punicagranatum (3ml/kg) or silymarin (100mg/kg) on serum ALT, serum ALP, serum Albumin, serum BuChE and Prothrombin time. Data are presented as mean  $\pm$  S.D. (n = 10).

Parameter	Control	F1	F2	F3	F4	Phy	Pun	Sil
Mean $\pm$ SD								
Serum ALT (U/L)	41.3 $\pm$ 0.97	48.1 $\pm$ 1.1 8* $\pi$ # $\epsilon$	49.6 $\pm$ 1.29* $\pi$ # $\epsilon$	52.1 $\pm$ 1.7* $\pi$ # $\epsilon$	56.3 $\pm$ 0.64* $\pi$ # $\epsilon$	42.2 $\pm$ 0.64 $\pi$ #	42.6 $\pm$ 0.73 $\pi$ #	40.5 $\pm$ 0.9 4 $\pi$ #
Serum ALP (U/L)	112.1 $\pm$ 2.27	137.8 $\pm$ 1.93* $\pi$ #	161.8 $\pm$ 2.2* $\pi$ # $\epsilon$	199.4 $\pm$ 3.17* $\pi$ # $\epsilon$	251.3 $\pm$ 3.66* $\pi$ # $\epsilon$	171.2 $\pm$ 4.24* $\pi$ # $\epsilon$	112.1 $\pm$ 2.56 $\pi$ # $\epsilon$	133.1 $\pm$ 2. 79* $\pi$ #
Serum albumin (gm/dl)	4.8 $\pm$ 0.02	4.1 $\pm$ 0.05 * $\pi$ # $\epsilon$	3.7 $\pm$ 0.06 * $\pi$ # $\epsilon$	3.6 $\pm$ 0.09 * $\pi$ # $\epsilon$	3.1 $\pm$ 0.08 * $\pi$ # $\epsilon$	4.4 $\pm$ 0.07 * $\pi$ # $\epsilon$	4.3 $\pm$ 0.08 * $\pi$ #	4.2 $\pm$ 0.05 * $\pi$ #
Serum BuChE (U/L)	16380 $\pm$ 2 25.7	9696 $\pm$ 125.2* $\pi$ # $\epsilon$	8557 $\pm$ 88.6* $\pi$ # $\epsilon$	7879 $\pm$ 102.7* $\pi$ # $\epsilon$	7544 $\pm$ 83.1* $\pi$ # $\epsilon$	15372 $\pm$ 302.4* $\pi$ # $\epsilon$	14767 $\pm$ 185.3* $\pi$ # $\epsilon$	13973 $\pm$ 45.5* $\pi$ #
Prothrombin time (Sec)	16.1 $\pm$ 0.4	16 $\pm$ 0.27 $\#$ $\pi$	16.8 $\pm$ 0.64*	17.1 $\pm$ 0.19* $\pi$	18.2 $\pm$ 0.63* $\pi$	16.8 $\pm$ 0.34 $\#$	16.7 $\pm$ 0.52 $\#$	16.7 $\pm$ 0.38 $\#$

\* Significantly different from control group,

$\pi$  Significantly different from fenitrothion 1 weeks (F1) group

$\pi$  Significantly different from fenitrothion 2 weeks (F2) group

$\pi$  Significantly different from fenitrothion 3 weeks (F3) group

$\#$  Significantly different from fenitrothion 4 weeks (F4) group

$\epsilon$  Significantly different from silymarin (Sil) group at  $p < 0.05$  using ANOVA followed by LSD and Tukey' Post Hoc test.

## 2. Effect on electrolyte

Administration of fenitrothion for 7, 14, 21 and 28 days (F1, F2, F3 and F4 respectively), caused significant decrease in serum sodium ( $\text{Na}^+$ ) level by 11, 23, 30 and 51%, respectively compared with control group (**Figure 1a**). On the other hand, treatment with Physalis, Punica or silymarin for 42 days (starting 14 days before fenitrothion) caused a significant increase in serum  $\text{Na}^+$  level by 51, 55 and 46%, respectively compared with F4 group (**Figure 1a**).

Administration of fenitrothion for 7, 14, 21 and 28 days (F1, F2, F3 and F4 respectively), induced significant decrease in serum potassium ( $\text{K}^+$ ) level by 2, 19, 32 and 59%, respectively compared with control group (**Figure 1b**). Treatment with Physalis, Punica or silymarin for 42 days (starting 14

days before fenitrothion) induced a significant increase in serum  $\text{K}^+$  level by 68, 83 and 87%, respectively compared with F4 group (**Figure 1b**).

Administration of fenitrothion for 7, 14, 21 and 28 days (F1, F2, F3 and F4 respectively), caused significant decrease in serum magnesium ( $\text{Mg}^{+2}$ ) level by 16, 24, 35 and 42%, respectively compared with control group (**Figure 1c**). Treatment with Physalis, Punica or silymarin for 42 days (starting 14 days before fenitrothion) caused significant increase in serum  $\text{Mg}^{+2}$  level by 48, 51 and 46%, respectively compared with F4 group (**Figure 1c**).

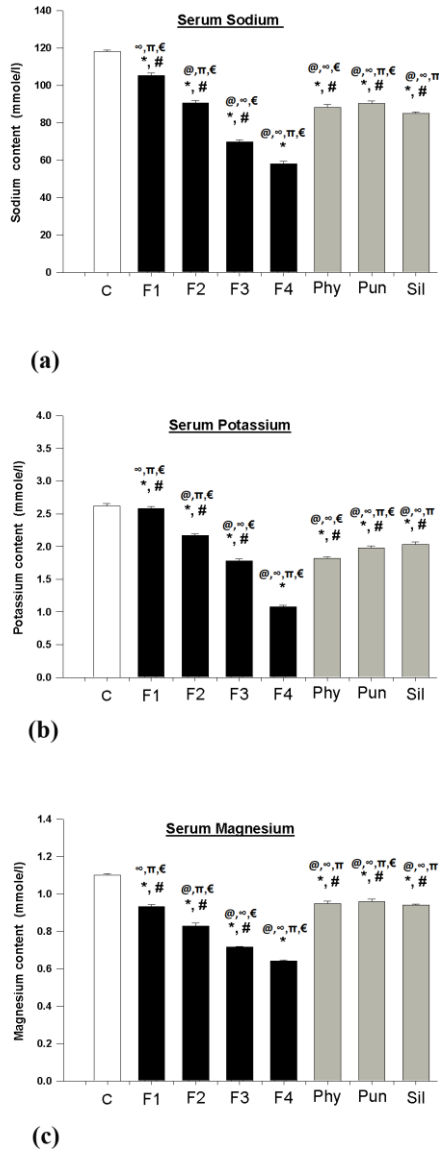


Figure (1)

**Fig.1:** Effects of daily oral administration of fenitrothion (10mg/kg) alone or in combination with *Physalis peruviana* (15% of diet), *Punica granatum* (3ml/kg) or silymarin (100 mg/kg) on serum: a) Sodium, b) Potassium and c) Magnesium. Data are presented as mean  $\pm$  S.D. (n = 10). \* Significantly different from control group, # Significantly different from fenitrothion 4 weeks (F4) group at  $p < 0.05$  using ANOVA followed by LSD and Tukey' Post Hoc test.

### 3. Effect on lipid profile

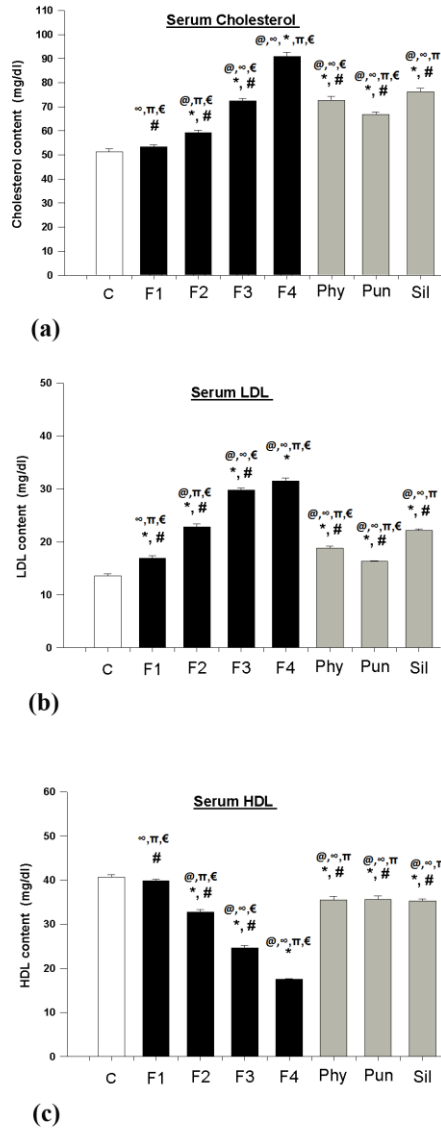
Administration of fenitrothion for 14, 21 and 28 days (F2, F3 and F4, respectively), caused a significant increase in serum cholesterol level by 16, 41 and 77 %, respectively compared with control group (**Figure 2a**). On the other hand, treatment with *Physalis*, *Punica* or silymarin for 42 days (starting 14 days before fenitrothion) induced a significant decrease in serum cholesterol level by 80, 74 and 84 %, respectively compared with F4 group (**Figure 2a**).

Administration of fenitrothion for 7, 14, 21 and 28 days (F1, F2, F3 and F4, respectively), caused a significant increase in serum LDL level by 24, 68, 118 and 131 %, respectively compared with control group (**Figure 2b**). Treatment with *Physalis*, *Punica* or silymarin for 42 days (starting 14 days before fenitrothion) caused a significant decrease in serum LDL level by 40, 48 and 30 %, respectively compared with F4 group (**Figure 2b**).

Administration of fenitrothion for 14, 21 and 28 days (F2, F3 and F4 respectively), caused a significant reduction in serum HDL level by 19, 39 and 57 %, respectively compared with control group (**Figure 2c**). Treatment with *Physalis*, *Punica* or silymarin for 42 days (starting 14 days before fenitrothion) caused a significant elevation in serum HDL level by 103, 103 and 102 %, respectively compared with F4 group (**Figure 2c**).

### 4. Effect on ammonia

Administration of fenitrothion for 7, 14, 21 and 28 days (F1, F2, F3 and F4) respectively, caused a significant increase in liver ammonia level by 26, 71, 129 and 214 % respectively, compared with control group (**Figure 3a**). Additionally, treatment with *Physalis*, *Punica* or silymarin for 42 days (starting 14 days before fenitrothion) caused a significant decrease in liver ammonia level by 48, 50 and 49 %, respectively compared with F4 group (**Figure 3a**).



**Figure (2)**

**Fig.2:** Effects of daily oral administration of fenitrothion (10 mg/kg) alone or in combination with *Physalis peruviana* (15% of diet), *Punica granatum* (3 ml/kg) or silymarin (100 mg/kg) on serum: a) Cholesterol, b) LDL and c) HDL. Data are presented as mean  $\pm$  S.D. (n = 10). \* Significantly different from control group, # Significantly different from fenitrothion 4 weeks (F4) group at  $p < 0.05$  using ANOVA followed by LSD and Tukey' Post Hoc test.

Administration of fenitrothion for 14, 21 and 28 days (F2, F3 and F4 respectively), caused a significant increase in serum ammonia level by 16, 65 and 116 %, respectively compared with control group (**Figure 3b**). On the other hand, treatment with *Physalis*, *Punica* or silymarin for 42 days (starting 14 days before fenitrothion) caused a significant decrease in serum ammonia level by 46, 36 and 37 %, respectively compared with F4 group (**Figure 3b**).

Administration of fenitrothion for 14, 21 and 28 days (F2, F3 and F4, respectively), caused a significant increase in brain ammonia level in cerebral cortex by 15, 30 and 53 %, respectively compared with control group (**Figure 3c**). Meanwhile, treatment with *Physalis*, *Punica* or silymarin for 42 days (starting 14 days before fenitrothion) caused a significant decrease in brain ammonia in cerebral cortex by 26, 25 and 25 %, respectively compared with F4 group (**Figure 3c**).

### 5. Effect on brain neurotransmitters

Administration of fenitrothion for 7, 14, 21 and 28 days (F1, F2, F3 and F4, respectively), caused a significant decrease in brain cortex acetylcholine esterase (AChE) activity, norepinephrine (NE) level and dopamine (DA) level compared with control group, while, treatment with *Physalis*, *Punica* or silymarin for 42 days (starting 14 days before fenitrothion) caused a significant increase in AChE activity, NE level and DA level in cerebral cortex compared with F4 group. On the other hand, administration of fenitrothion for 14, 21 and 28 days (F2, F3 and F4, respectively), caused significant elevation in brain cortex level of glutamate, gamma aminobutric acid (GABA) and 5-hydroxytryptamine (5-HT) compared with control group. Additionally, treatment with *Physalis*, *Punica* or silymarin for 42 days (starting 14 days before fenitrothion) caused a significant reduction in brain cortex level of glutamate, GABA and 5-HT compared with F4 group (**Table 2**).

Table (2): Effects of daily oral administration of fenitrothion (10mg/kg) alone or in combination with Physalisperuviana (15% of diet), Punicagranatum (3ml/kg) or silymarin (100mg/kg) on brain acetylcholine esterase (AChE), glutamate, norepinephrine (NE), dopamine (DA), gamma amino butyric acid (GABA) and serotonin (5-hydroxytryptamine, 5-HT).

Brain Content (per gram)	control	F1	F2	F3	F4	Phy	Pun	Sil
	mean± SD	mean± SD	mean± SD	mean± SD	mean± SD	mean± SD	mean± SD	mean± SD
AChE (µmole/min)	0.464± 0.009	0.439±0.004 <sup>*∞π#€</sup>	0.399± 0.002 <sup>*®π#€</sup>	0.324±0.006 <sup>*®∞#€</sup>	0.207±0.003 <sup>*®∞π€</sup>	0.416±0.004 <sup>*®∞π#€</sup>	0.413±0.006 <sup>*®∞π#€</sup>	0.373±0.007 <sup>*®∞π#</sup>
glutamate (µmole)	20.2± 0.4	21.03±0.29 <sup>#∞π€</sup>	23.3±0.4 <sup>*®π#€</sup>	32.9±0.25 <sup>*®∞#€</sup>	45.1±0.53 <sup>*®∞π€</sup>	25.2±0.18 <sup>*®∞π#</sup>	25.1±0.24 <sup>*®∞π#</sup>	24.9±0.34 <sup>*®∞π#</sup>
NE (µg)	18.3± 0.13	18.87±0.09 <sup>∞π#€</sup>	16±0.08 <sup>*®π#€</sup>	12.4±0.09 <sup>*®∞#€</sup>	8.5±0.17 <sup>*®π∞€</sup>	15.1±0.16 <sup>*®∞π#€</sup>	14.8±0.08 <sup>*®∞π#€</sup>	14.3±0.22 <sup>*®∞π#</sup>
DA (µg)	91.7± 0.89	91.07±0.53 <sup>∞π#€</sup>	69.9±1.41 <sup>*®π#€</sup>	59.7±0.73 <sup>*®∞#€</sup>	50.1±0.75 <sup>*®∞π€</sup>	77.4±0.23 <sup>*®∞π#€</sup>	76.9±0.54 <sup>*®∞π#€</sup>	74.2±1.21 <sup>*®∞π#</sup>
GABA (µmole)	18.3± 0.13	18.87±0.09 <sup>∞π#€</sup>	20.2±0.08 <sup>*®π#€</sup>	23.8±0.1 <sup>*®∞#€</sup>	30.5±0.24 <sup>*®∞π€</sup>	20.1±0.28 <sup>*®π#€</sup>	19.8±0.14 <sup>*®π#</sup>	19.6±0.31 <sup>*®∞π#</sup>
5-HT (µg)	359±5.6	367±3.99 <sup>∞π#€</sup>	427±3.16 <sup>*®π#€</sup>	527±8.51 <sup>*®∞#€</sup>	627±9.73 <sup>*®∞π€</sup>	466±4.24 <sup>*®∞π#</sup>	462±3.63 <sup>*®∞π#</sup>	458±4.51 <sup>*®∞π#</sup>

\* Significantly different from control group,

® Significantly different from fenitrothion 1 weeks (F1) group

∞ Significantly different from fenitrothion 2 weeks (F2) group

π Significantly different from fenitrothion 3 weeks (F3) group

# Significantly different from fenitrothion 4 weeks (F4) group

€ Significantly different from silymarin (Sil) group at p < 0.05 using ANOVA followed by LSD and Tukey' Post Hoc test.

## 6. Effect on kidney function

Administration of fenitrothion for 21 and 28 days (F3 and F4 respectively), caused a significant increase in serum urea level by 48 and 69%, respectively compared with control group (**Figure 4a**). Treatment with Physalis, Punica or silymarin for 42 days (starting 14 days before fenitrothion) caused a significant decrease in serum urea level by 40, 35 and 41%, respectively compared with F4 group (**Figure 4a**).

Administration of fenitrothion for 21 and 28 days (F3 and F4 respectively), caused a significant increase in serum creatinine level by 25 and 62.5%, respectively compared with control group (**Figure 4b**). Additionally, treatment with Physalis, Punica or silymarin for 42 days (starting 14 days before fenitrothion) caused a significant decrease in serum creatinine level by 22, 17 and 16%,

respectively compared with F4 group (**Figure 4b**).

Administration of fenitrothion for 14, 21 and 28 days (F2, F3 and F4 respectively), caused a significant increase in serum uric acid level by 24, 54 and 76%, respectively compared with control group (**Figure 4c**). Treatment with Physalis, Punica or silymarin for 42 days (starting 14 days before fenitrothion) induced a significant decrease in serum uric acid level by 34, 32 and 37%, respectively compared with F4 group (**Figure 4c**).

## 7. Effect on oxidative stress biomarkers

Administration of fenitrothion for 7 days (F1) caused a significant initial increase in catalase (CAT) activity and glutathione

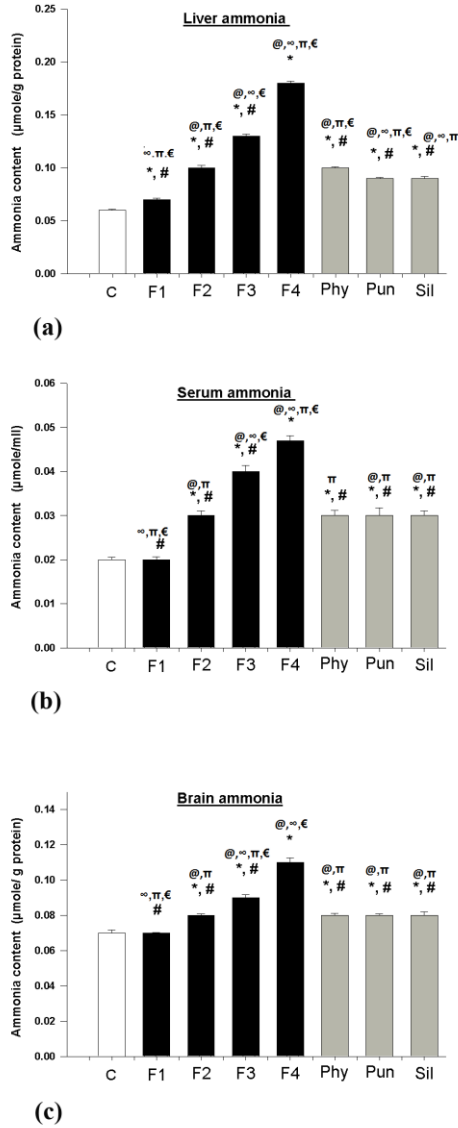


Figure (3)

**Fig.3:** Effects of daily oral administration of fenitrothion (10 mg/kg) alone or in combination with *Physalis peruviana* (15% of diet), *Punica granatum* (3 ml/kg) or silymarin (100 mg/kg) on ammonia level in: a) liver, b) serum and c) brain. Data are presented as mean  $\pm$  S.D. (n = 10). \* Significantly different from control group, # Significantly different from fenitrothion 4 weeks (F4) group at  $p < 0.05$  using ANOVA followed by LSD and Tukey' Post Hoc test.

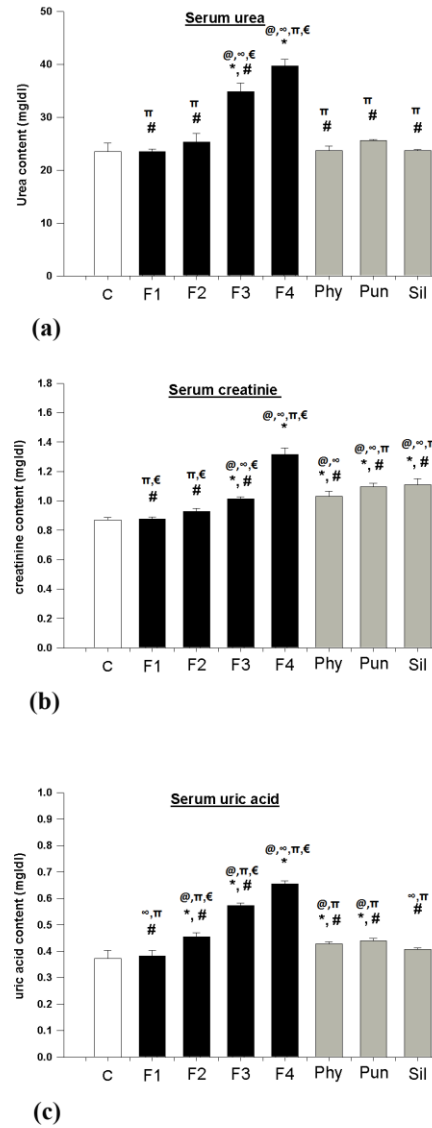


Figure (4)

**Fig.4:** Effects of daily oral administration of fenitrothion (10 mg/kg) alone or in combination with *Physalis peruviana* (15% of diet), *Punica granatum* (3 ml/kg) or silymarin (100 mg/kg) on serum: a) urea, b) creatinine and c) uric acid. Data are presented as mean  $\pm$  S.D. (n = 10). \* Significantly different from control group, # Significantly different from fenitrothion 4 weeks (F4) group at  $p < 0.05$  using ANOVA followed by LSD and Tukey' Post Hoc test.



(GSH) level in liver, brain and kidney compared with control group, however, continued administration of fenitrothion lead to a decrease in catalase (CAT) activity and glutathione (GSH) level in liver, brain and kidney compared with control group. On the other hand, administration of fenitrothion for 7 days (F1) caused a significant initial decrease in malodialdhyde (MDA) level in liver, brain and kidney compared with control group, however, continued administration of

fenitrothion lead to an increase in malodialdhyde (MDA) level in liver, brain and kidney compared with control group (**Table 3**).

Treatment with Physalis, Punica or silymarin for 42 days (starting 14 days before fenitrothion) caused a significant increase in liver, brain and kidney catalase activity and glutathione (GSH) level while liver, brain and kidney malodialdhyde (MDA) level was significantly reduced (**Table 3**).

**Table (3):** Effects of daily oral administration of fenitrothion (10mg/kg) alone or in combination with Physalisperuviana (15% of diet), Punicagranatum (3ml/kg) or silymarin (100mg/kg) on: catalase, glutathione and malondaldhyde in liver, brain and kidney. Data are presented as mean ± S.D. (n = 10).

Parameters	Control	F1	F2	F3	F4	Phy	Pun	Sil
	mean± SD	mean± SD	mean±SD	mean± SD	mean±SD	mean±SD	mean±SD	mean±SD
Liver CAT (µmole /min/mg)	0.069± 0.002	0.085±0.0 01*∞ π #€	0.066±0.0 01® π #€	0.06±0.00 1*®∞#€	0.048±0.0 01*®∞ π€	0.089±0.0 02*∞ π #€	0.09±0.00 2*∞ π #€	0.081±0.0 01*®∞ π #
Liver GSH (mg/g)	2.8± 0.05	3.2±0.05* ∞ π #	2.97±0.03 ® π #	2.7±0.06* ®∞#€	2.4±0.06* ®∞ π€	3.05±0.05 *® π #	3.1±0.05* ®∞ π #	3.1±0.07* ® π #
Liver MDA (µmole/g)	5.2± 0.1	4.1±0.06* ∞ π #€	6.8±0.14* ® π #	10±0.20*® ∞#€	13.6±0.25 *®∞ π€	7.2±0.15* ®∞ π #	6.6±0.1*® π #	6.9±0.06* ® π #
Brain CAT (µmole /min/mg)	0.34±0.00 8	0.37±0*∞ π #€	0.34±0.00 2® π #	0.29±0.00 2*®∞#€	0.24±0.00 5*®∞ π€	0.34±0®# π	0.35±0®# π€	0.33±0®# π
Brain GSH (mg/g)	1.34±0.01	1.57±0.04 *∞ π #€	1.33±0.02 ® π #	1.1±0.01* ®∞#€	1±0.01*®∞ π€	1.3±0.01* ® π #	1.35±0.01 *® π #	1.3±0.01* ® π #
Brain MDA (µmole/g)	2.7±0.06	2.5±0.01* ∞ π #€	4.1±0.07* ® π #€	5.1±0.07* ®∞#€	5.7±0.06* ®∞ π€	2.9±0.02* ®∞ π #	2.6±0.04® ∞ π #€	2.8±0.07® ∞ π #
Kidney CAT (µmole /min/mg)	0.053±0.0 02	0.06±0.00 3*∞ π #	0.054±0.0 01®#€	0.048±0.0 02*®#€	0.041±0.0 03*®∞ π€	0.055±0*∞ π #	0.062±0.0 01*∞ π #	0.06±0.00 1*∞ π #
Kidney GSH (mg/g)	1.7± 0.11	2.02±0.11 *∞ π #€	1.6±0.09* ® π #	1.4±0.08* ®∞#€	1.3±0.06* ®∞ π€	1.7±0.07® π #	1.7±0.04® π #	1.7±0.04® π #
Kidney MDA (µmole/g)	5.7±0.21	5.4±0.11* ∞ π #€	7.04±0.18 *® π #€	8.8±0.18* ®∞#€	11.3±0.21 *®∞ π€	6.2±0.16* ®∞ π #	6.1±0.14* ®∞ π #	6.1±0.06* ®∞ π #

\* Significantly different from control group,

® Significantly different from fenitrothion 1 weeks (F1) group

∞ Significantly different from fenitrothion 2 weeks (F2) group

π Significantly different from fenitrothion 3 weeks (F3) group

# Significantly different from fenitrothion 4 weeks (F4) group

€ Significantly different from silymarin (Sil) group at p< 0.05 using ANOVA followed by LSD and Tukey' Post Hoc test.

## DISCUSSION

The present study was designed to investigate the hepatotoxic effect of fenitrothion as well as the hepatoprotective potential of Physalis and Punica in rats. In

addition this study tried to find out whether fenitrothion directly affects the kidney and brain or its hepatotoxic effect has a distant damaging effect on brain and kidney functions.

Exposure to pesticides is among the most serious health problems in the world (Lasram et al., 2009). Previous studies have shown that exposure to pesticides caused hepatotoxicity (Kalender et al., 2010), hematotoxicity (Durak et al., 2009), genotoxicity (Giri et al., 2002). In addition, OPIs can alter antioxidant enzyme activities and increase the production of free radicals in different tissues including the liver (Kumar et al., 1993); (Hazarika et al., 2003), brain (Kumar et al., 1993); (Brocardo et al., 2005) and kidney (Kumar et al., 1993); (Possamai et al., 2007).

The present study showed that fenitrothion caused liver injury and deterioration in liver function as evidenced by a increase in ALT, ALP activities and prothrombine time and decrease in albumin level and BuChE activity. This alteration in liver function might be attributed to hepatocellular damage and alteration in the permeability of cell membrane (Ncibi et al., 2008); (Ogutcu et al., 2008). Additionally, reduction in albumin level may reflect disturbed amino acid metabolism induced by reactive oxygen species (ROS) generated by OPIs as previously described by Yousef et al., (2006). Furthermore, reduction of BuChE activity is a consequence of direct inhibition of cholinesterases by fenitrothion, BuChE is similar to neuronal acetylcholineesterase but found primarily in the liver. Assay of BuChE activity in plasma can be used as a liver function test (Hillman, 1994); (Franco et al., 2009).

In this study, fenitrothion administration caused a significant decrease in serum sodium, potassium and magnesium which indicates a state of liver damage and cirrhosis (Wong and Blendis, 1994). Numerous previous studies have reported that alterations in the levels of minerals may contribute to the pathogenesis of hepatic impairment as hyponatremia (Borroni et al., 2000); (Castello et al., 2005), hypokalemia (Pitts and Van Thiel, 1986) and

hypomagnesemia (George, 2006) have been shown in patients with liver cirrhosis

Results of the current study showed increase in cholesterol and LDL and decrease in HDL in serum after administration of fenitrothion. This result is in accordance with those reported by Kalender et al., (2010) who related these alterations in lipid profile to the effect of fenitrothion on the blockage of the bile duct, which reduces or stops cholesterol secretion into the duodenum.

Ammonia, one of the principal products of nitrogen metabolism, is normally converted to urea in the liver by a series of enzymatic reactions (Larsen et al., 2001). Liver impairment may cause elevation in blood ammonia concentration, therefore, ammonia level is used widely in the diagnosis of hepatic encephalopathy in cirrhotic patients with altered mental status (Albrecht and Jones, 1999; Jalan et al., 2003).

One important finding of this study was the gradual elevation in liver ammonia starting in the first week, of fenitrothion administration while, significant increase in serum ammonia started in the second week and a significant increase in brain ammonia level started in the third week. These results imply that the damage which started in the liver was followed by blood then brain. These results are in agreement with those reported by Subash and Subramanian, (2008), who reported a significant increase in blood ammonia in Ammonium chloride -induced liver damage in rats. Excess ammonia in blood can cross the blood brain barrier (BBB) causing hepatic encephalopathy (Bosoi et al., 2012) through several mechanisms including, free radical production, changes in lipid composition in brain due to alteration in lipid profile, increased BBB permeability, brain edema and imbalance between excitatory and inhibitory neurotransmitters (Swapna et al., 2006). Ammonia was also shown to impair brain energy metabolism and autoregulation of blood flow (Larsen et al., 2001).

In the present study, a gradual increase in brain glutamate, GABA and 5-HT level was observed after fenitrothion administration. While, a gradual decrease in NE and DA level was observed after fenitrothion administration in brain. These results are in agreement with those reported by Jalan et al., (2003) who reported the changes of brain neurotransmitters after liver injury.

The state of hyperammonemia was previously shown to induce changes in GABAergic tone due to modulation by central and peripheral benzodiazepine receptors (Desjardins et al., 1997), while, changes in glutamatergic, dopaminergic and cholinergic system were caused by disturbances in the synthesis and degradation of the amino acids (Hertz et al., 2000); (Sonnewald et al., 1996), and amino acid efflux from and/or reuptake by astrocytes (Zielinska et al., 2002).

The present study, demonstrated inhibition in brain AChE after the first week of administration of fenitrothion. Inhibition of AChE enzyme causes an increase in ACh level at causing neuronal excitation then paralysis of the cholinergic transmission (Bartling et al., 2007).

Hepatorenal syndrome (HRS) is the development of renal failure in patients with severe liver disease in the absence of any other identifiable cause. Prevention of hepatorenal syndrome is frequently neglected in clinical practice (McCormick and Donnelly, 2008). This study showed gradual decline in kidney function evidenced by elevation in blood urea nitrogen (BUN), serum creatinine and serum uric acid starting in the third week after fenitrothion administration. These results coincide with previous studies (Al-Attar, 2010).

Oxidative stress is a major mechanism in the pathophysiology of several diseases including a variety of liver disorders (Medina and Moreno-Otero, 2005). In this study, an initial increase in antioxidant status in liver, brain and kidney was noticed as evidenced by

the initial increase in catalase activity, glutathione level and the decrease in malodialdehyde level which was reversed with continued administration of fenitrothion indicating an initial attempt of the body to combat the oxidative stress state induced by fenitrothion which failed and resulted in an evident state of oxidative stress in liver, brain and kidney. Similar effects of OPIs were previously reported (Prasanthi et al., 2005).

The previous results imply that liver damage was the first to occur as it is the first organ to encounter any exogenously administered substance and was confirmed by disturbance in liver function from the first week of exposure. Repeated/continued exposure to the pesticide resulted in a disturbance in the brain and kidney functions starting from the 3rd week and peaked at the 4th week.

This might be a delayed or cumulative effect of the pesticide or due to a cross talk between the liver and other organs mediated mainly by; elevation of the level of toxic byproducts as ammonia that can reach the brain causing neurotoxicity, electrolyte disturbances that might alter the renal hemodynamics causing nephrotoxicity, a state of hepatic oxidative stress that spreads to other organs as the brain and kidney, the brain is the most sensitive organ to the oxidative stress induced either directly due to exposure to pesticides or indirectly due to liver damage and alteration of lipids (profile or generalized alteration of lipid membranes in all body organs).

Recent research has shown that fresh *Physalis* juice contains (70mg/100ml) polyphenols and high level of flavonoids which have antioxidant actions (Coskun et al., 2005). Fresh *Punica* juice is rich in polyphenolic compounds (Lansky, 2006; Seeram et al., 2005) which were linked to prevention of cardiovascular diseases, cancer and neurological damage (Lansky and Newman, 2007). Similarly, flavonoids and polyphenolic compounds present in silymarin

have been shown to possess antioxidant and anti-inflammatory properties (Shaker et al., 2010).

The current study has shown a hepatoprotective effect of Physalis juice which was evidenced by restoration of ALT, ALP, albumin, prothrombin time and BuChE to near normal values. A similar hepatoprotective effect of Physalis was previously reported by (Arun and Asha, 2007; Wu et al., 2004) who suggested that the reversal of increased serum enzymes in rats fed by Physalis was due to the prevention of the leakage of intracellular enzymes by its membrane stabilizing activity. Similar hepatoprotective effect was observed in punica-treated rats as evidenced by normalization of liver function parameters including ALT, ALP, albumin, prothrombin time and BuChE which were altered by fenitrothion. This might be attributed to the ability of Punica to scavenge free radicals due to polyphenol and flavonoid level, thus preventing hepatocellular damage, thereby preserving the structural integrity of cell and suppressing the leakage of enzymes through plasma membranes (Toklu et al., 2007). In the present study, pretreatment with silymarin confirmed its hepatoprotective effect (Pradeep et al., 2007) on ALT, ALP, albumin, prothrombin time and BuChE.

The present study showed that administration of physalis, physalis and silymarin caused an increase in serum sodium, potassium and magnesium. These effects may be due to the high level of minerals (Ross and Desai, 2005) and/or flavonoid level (Wang et al., 2000).

Results of the current study showed a decrease in cholesterol and LDL and an increase in HDL in serum after administration of Physalis, Punica and silymarin. Punica juice was previously reported to reduce cholesterol oxidation and reduce the retention of LDL (Singh et al., 2002) while, Punica was reported to decrease total lipids and total cholesterol in albino rats subjected to CCl<sub>4</sub>

toxicity and silymarin was shown to reduce cholesterol synthesis (Nassuato et al., 1991) in rats.

Wasan et al., have related the decrease of TC and LDL-cholesterol with an increase in HDL-cholesterol level to the wealth of phytosterols which are known to decrease in cholesterol solubility and absorption across the intestinal barrier and consequently decreasing cholesterol level in plasma (Wasan et al., 2001). In addition, flavonoids were reported to inhibit LDL oxidation and platelet aggregation thus leading to reduced LDL and cholesterol levels (Kurowska et al., 2000). In addition, (Basu and Penugonda, 2009) suggested that the principal mechanisms of action of Punica juice as anti-atherogenic may be due to its potent antioxidative capacity.

In the present study, administration of Physalis, Punica and silymarin with fenitrothion normalized the alteration in ammonia level in liver, serum and brain. The current finding supports those obtained by (Subash and Subramanian, 2009) who reported that administration of morin (a flavonoid) decreased the levels of blood ammonia and urea in rats with ammonium chloride induced hyperammonemia.

In the present study, administration of Physalis, Punica and silymarin with fenitrothion ameliorated the disturbed neurotransmitters induced by fenitrothion. This may be a local direct antioxidant action of flavonoid present in these plants in the brain as previously described (Youdim et al., 2004); (Jager and Saaby, 2011) or an indirect effect due to their hepatoprotective effect and prevention of excessive ammonia formation (Subash and Subramanian, 2008).

The present study showed that administration of Punica, Physalis and silymarin had a nephroprotective effect as evidenced by the decrease in the level of BUN, serum creatinine and uric acid induced by Fenitrothion. The nephroprotective effect was previously described for Physalis (Moneim and El-Deib, 2012). Punica (Parmar

and Kar, 2008) and silymarin (Karimi et al., 2005) by detoxifying excess urea and creatinine, free radical scavenging and antioxidant properties. In addition, other natural compounds with antioxidant activity as green tea were previously reported to protect against fenitrothion effects on kidney (Elhalwagy et al., 2008).

It is well documented that antioxidants play an important role in ameliorating the damaging effects of oxidative stress on cells. According to the results obtained in the current study, oral administration of Physalis, Punica and silymarin before fenitrothion normalized the oxidative stress biomarkers; CAT, GSH and MDA in liver, brain and kidney which were altered by Fenitrothion. This could be attributed to their potent antioxidant activity and free radical scavenging capability (Ramadan and Morsel, 2003).

Previous studies have suggested that the antioxidant activity of Physalis may be due to flavonoids, phenols and high amounts of vitamins (A,B and C) as well as the presence of essential minerals, magnesium, calcium, potassium, sodium and phosphorus which are classified as macronutrients (Wu et al., 2005). Also, (Turk et al., 2008) reported that there was a significant decrease in malondialdehyde (MDA) level and a marked increases in reduced glutathione (GSH), GPx and CAT activities, and vitamin C level in rats treated with different doses of Punica juice. Similarly, (Karimi et al., 2005) reported similar actions of silymarin on oxidative stress biomarker in rats treated with cisplatin.

#### **CONCLUSION**

In conclusion, excessive use of pesticides in agricultural schedules causes potential health hazards in human and animals in different organs including hepatic damage, neurological and renal disorders. The use of Physalis and Punica as dietary supplement was able to protect from pesticide-induced hepatotoxicity and its possible complications on the brain and kidney. It seems wise – at this

point - to advice people susceptible to toxicity by pesticides to include Physalis and Punica in their daily food level as they were shown to protect against pesticide-induced hepatotoxicity, neurotoxicity and nephrotoxicity.

These protective actions might be attributed to their antioxidant properties acting as free radical scavengers and inhibitors of lipid peroxidation and a plasma membrane stabilizer. Further analysis of the constituents of Physalis and Punica is required to characterize and possibly isolate the ingredients that mediated these protective actions.

#### **Conflict of interest**

The authors declare that they have no conflict of interest.

#### **ACKNOWLEDGMENTS:**

This work was funded by the Academy for Scientific Research and Technology, Egypt (R11/2013-25/05/2014).

#### **REFERENCES**

1. Al-Attar, A.M. (2010). Physiological and histopathological investigations on the effects of alpha-lipoic acid in rats exposed to malathion. *J Biomed Biotechnol* 2010, 203503.
2. Albrecht, J. and Jones, E.A. (1999). Hepatic encephalopathy: molecular mechanisms underlying the clinical syndrome. *J Neurol Sci* 170, 138-146.
3. Arun, M. and Asha, V.V. (2007). Preliminary studies on antihepatotoxic effect of *Physalis peruviana* Linn. (Solanaceae) against carbon tetrachloride induced acute liver injury in rats. *J Ethnopharmacol* 111, 110-114.
4. Bartling, A.; Worek, F.; Szinicz, L. and Thiermann, H. (2007). Enzyme-kinetic investigation of different sarin analogues reacting with human acetylcholinesterase and butyrylcholinesterase. *Toxicology* 233, 166-172.

5. Basu, A. and Penugonda, K. (2009). Pomegranate juice: a heart-healthy fruit juice. *Nutr Rev* 67, 49-56.
6. Beutler, E.; Duron, O. and Kelly, B.M., (1963). Improved method for the determination of blood glutathione. *J Lab Clin Med* 61, 882-888.
7. Borroni, G.; Maggi, A.; Sangiovanni, A.; Cazzaniga, M. and Salerno, F. (2000). Clinical relevance of hyponatraemia for the hospital outcome of cirrhotic patients. *Dig Liver Dis* 32, 605-610.
8. Bosoi, C.R.; Yang, X.; Huynh, J.; Parent-Robitaille, C.; Jiang, W.; Tremblay, M. and Rose, C.F. (2012). Systemic oxidative stress is implicated in the pathogenesis of brain edema in rats with chronic liver failure. *Free Radic Biol Med* 52, 1228-1235.
9. Brocardo, P.S.; Pandolfo, P.; Takahashi, R.N.; Rodrigues, A.L. and Dafre, A.L. (2005). Antioxidant defenses and lipid peroxidation in the cerebral cortex and hippocampus following acute exposure to malathion and/or zinc chloride. *Toxicology* 207, 283-291.
10. Castello, L.; Pirisi, M.; Sainaghi, P.P. and Bartoli, E. (2005). Hyponatremia in liver cirrhosis: pathophysiological principles of management. *Dig Liver Dis* 37, 73-81.
11. Celik, I.; Yilmaz, Z. and Turkoglu, V., (2009). Hematotoxic and hepatotoxic effects of dichlorvos at sublethal dosages in rats. *Environ Toxicol* 24, 128-132.
12. Coskun, O.; Kanter, M.; Korkmaz, A. and Oter, S., (2005). Quercetin, a flavonoid antioxidant, prevents and protects streptozotocin-induced oxidative stress and beta-cell damage in rat pancreas. *Pharmacol Res* 51, 117-123.
13. Desjardins, P.; Bandeira, P.; Raghavendra Rao, V.L.; Ledoux, S. and Butterworth, R.F. (1997). Increased expression of the peripheral-type benzodiazepine receptor-isoquinoline carboxamide binding protein mRNA in brain following portacaval anastomosis. *Brain Res* 758, 255-258.
14. Durak, D.; Uzun, F.G.; Kalender, S.; Ogutcu, A.; Uzunhisarcikli, M. and Kalender, Y. (2009). Malathion-induced oxidative stress in human erythrocytes and the protective effect of vitamins C and E in vitro. *Environ Toxicol* 24, 235-242.
15. El-Demerdash, F.M. (2011). Lipid peroxidation, oxidative stress and acetylcholinesterase in rat brain exposed to organophosphate and pyrethroid insecticides. *Food Chem Toxicol* 49, 1346-1352.
16. Elhalwagy, M.E.A.; Darwish, N.S. and Zaher, E.M. (2008). Prophylactic effect of green tea polyphenols against liver and kidney injury induced by fenitrothion insecticide. *Pesticide Biochemistry and Physiology* 91, 81-89.
17. Ellman, G.L.; Courtney, K.D.; Andres, V. Jr. and Feather-Stone, R.M. (1961). A new and rapid colorimetric determination of acetylcholinesterase activity. *Biochem Pharmacol* 7, 88-95.
18. Faria, A.; Monteiro, R.; Mateus, N.; Azevedo, I. and Calhau, C. (2007). Effect of pomegranate (*Punica granatum*) juice intake on hepatic oxidative stress. *Eur J Nutr* 46, 271-278.
19. Ferenci, P.; Lockwood, A.; Mullen, K.; Tarter, R.; Weissenborn, K. and Blei, A.T. (2002). Hepatic encephalopathy--definition, nomenclature, diagnosis, and quantification: final report of the working party at the 11th World Congresses of Gastroenterology, Vienna, 1998. *Hepatology* 35, 716-721.
20. Franco, J.L.; Posser, T.; Mattos, J.J.; Trevisan, R.; Brocardo, P.S.; Rodrigues, A.L.; Leal, R.B.; Farina, M.; Marques, M.R.; Bainy, A.C. and Dafre, A.L. (2009). Zinc reverses malathion-induced impairment in antioxidant defenses. *Toxicol Lett* 187, 137-143.

21. Galal, R.M.; Zaki, H.F.; Seif El-Nasr, M.M. and Agha, A.M. (2012). Potential protective effect of honey against paracetamol-induced hepatotoxicity. *Arch Iran Med* 15, 674-680.
22. George, J. (2006). Mineral metabolism in dimethylnitrosamine-induced hepatic fibrosis. *Clin Biochem* 39, 984-991.
23. Giri, S.; Prasad, S.B.; Giri, A. and Sharma, G.D. (2002). Genotoxic effects of malathion: an organophosphorus insecticide, using three mammalian bioassays in vivo. *Mutat Res* 514, 223-231.
24. Harrison, M.J.; Marsden, C.D. and Jenner, P. (1979). Effect of experimental ischemia on neurotransmitter amines in the gerbil brain. *Stroke* 10, 165-168.
25. Hazarika, A.; Sarkar, S.N.; Hajare, S.; Kataria, M. and Malik, J.K., 2003. Influence of malathion pretreatment on the toxicity of anilofos in male rats: a biochemical interaction study. *Toxicology* 185, 1-8.
26. Hertz, L.; Yu, A.C.; Kala, G. and Schousboe, A. (2000). Neuronal-astrocytic and cytosolic-mitochondrial metabolite trafficking during brain activation, hyperammonemia and energy deprivation. *Neurochem Int* 37, 83-102.
27. Hillman, J.V. (1994). Emergency care of insecticide poisonings. *J Fla Med Assoc* 81, 750-752.
28. Jager, A.K. and Saaby, L. (2011). Flavonoids and the CNS. *Molecules* 16, 1471-1485.
29. Jalan, R.; Shawcross, D. and Davies, N. (2003). The molecular pathogenesis of hepatic encephalopathy. *Int J Biochem Cell Biol* 35, 1175-1181.
30. Kalender, S.; Uzun, F.G.; Durak, D.; Demir, F. and Kalender, Y. (2010). Malathion-induced hepatotoxicity in rats: the effects of vitamins C and E. *Food Chem Toxicol* 48, 633-638.
31. Kalender, Y.; Uzunhisarcikli, M.; Ogutcu, A.; Acikgoz, F. and Kalender, S., 2006. Effects of diazinon on pseudocholinesterase activity and haematological indices in rats: The protective role of Vitamin E. *Environ Toxicol Pharmacol* 22, 46-51.
32. Karimi, G., Ramezani, M. and Tahoonian, Z., 2005. Cisplatin nephrotoxicity and protection by milk thistle extract in rats. *Evid Based Complement Alternat Med* 2, 383-386.
33. Kaur, G., Jabbar, Z., Athar, M. and Alam, M.S., 2006. Punica granatum (pomegranate) flower extract possesses potent antioxidant activity and abrogates Fe-NTA induced hepatotoxicity in mice. *Food Chem Toxicol* 44, 984-993.
34. Korany, N.S. and Ezzat, B.A., 2011. Prophylactic effect of green tea and *Nigella sativa* extracts against fenitrothion-induced toxicity in rat parotid gland. *Arch Oral Biol* 56, 1339-1346.
35. Kumar, R., Roy, S., Rishi, R. and Sharma, C.B., 1993. Metabolic fate of fenitrothion in liver, kidney and brain of rat. *Biomed Chromatogr* 7, 301-305.
36. Kurowska, E.M., Spence, J.D., Jordan, J., Wetmore, S., Freeman, D.J., Piche, L.A. and Serratore, P., 2000. HDL-cholesterol-raising effect of orange juice in subjects with hypercholesterolemia. *Am J Clin Nutr* 72, 1095-1100.
37. Lansky, E.P., 2006. Beware of pomegranates bearing 40% ellagic Acid. *J Med Food* 9, 119-122.
38. Lansky, E.P. and Newman, R.A., 2007. Punica granatum (pomegranate) and its potential for prevention and treatment of inflammation and cancer. *J Ethnopharmacol* 109, 177-206.
39. Larsen, F.S., Gottstein, J. and Blei, A.T., 2001. Cerebral hyperemia and nitric oxide synthase in rats with ammonia-induced brain edema. *J Hepatol* 34, 548-554.
40. Lasram, M.M., Annabi, A.B., El Elj, N., Selmi, S., Kamoun, A., El-Fazaa, S. and

- G. N. (2009). Metabolic disorders of acute exposure to malathion in adult Wistar rats. *J Hazard Mater* 163, 1052-1055.
41. Lowe, I.P.; Robins, E. and Eyerman, G.S. (1958). The fluorometric measurement of glutamic decarboxylase and its distribution in brain. *J Neurochem* 3, 8-18.
  42. Mansour, H.H.; Hafez, H.F. and Fahmy, N.M. (2006). Silymarin modulates Cisplatin-induced oxidative stress and hepatotoxicity in rats. *J Biochem Mol Biol* 39, 656-661.
  43. McCormick, P.A. and Donnelly, C. (2008). Management of hepatorenal syndrome. *Pharmacol Ther* 119, 1-6.
  44. Medina, J. and Moreno-Otero, R. (2005). Pathophysiological basis for antioxidant therapy in chronic liver disease. *Drugs* 65, 2445-2461.
  45. Moneim, A.E.A. and El-Deib, K.M. (2012). The Possible protective effects of *Physalis peruviana* on carbon tetrachloride-induced nephrotoxicity in male albino rats. *Life Science Journal-Acta Zhengzhou University Overseas Edition* 9, 1038-1052.
  46. Nassuato, G.; Iemmolo, R.M.; Strazzabosco, M.; Lirussi, F.; Deana, R.; Francesconi, M.A.; Muraca, M.; Passera, D.; Fragasso, A.; Orlando, R. (1991). Effect of Silibinin on biliary lipid composition. Experimental and clinical study. *J Hepatol* 12, 290-295.
  47. Ncibi, S.; Ben Othman, M.; Akacha, A.; Krifi, M.N. and Zourgui, L. (2008). *Opuntia ficus indica* extract protects against chlorpyrifos-induced damage on mice liver. *Food Chem Toxicol* 46, 797-802.
  48. Norenberg, M.D.; Jayakumar, A.R. and Rama Rao, K.V., 2004. Oxidative stress in the pathogenesis of hepatic encephalopathy. *Metab Brain Dis* 19, 313-329.
  49. Ogutcu, A.; Suludere, Z. and Kalender, Y. (2008). Dichlorvos-induced hepatotoxicity in rats and the protective effects of vitamins C and E. *Environ Toxicol Pharmacol* 26, 355-361.
  50. Parmar, H.S. and Kar, A., (2008). Medicinal values of fruit peels from *Citrus sinensis*, *Punica granatum*, and *Musa paradisiaca* with respect to alterations in tissue lipid peroxidation and serum concentration of glucose, insulin, and thyroid hormones. *J Med Food* 11, 376-381.
  51. Pitts, T.O. and Van Thiel, D.H. (1986). Disorders of the serum electrolytes, acid-base balance, and renal function in alcoholism. *Recent Dev Alcohol* 4, 311-339.
  52. Possamai, F.P.; Fortunato, J.J.; Feier, G.; Agostinho, F.R.; Quevedo, J.; Wilhelm F. D. and Dal-Pizzol, F. (2007). Oxidative stress after acute and sub-chronic malathion intoxication in Wistar rats. *Environ Toxicol Pharmacol* 23, 198-204.
  53. Pradeep, K.; Mohan, C.V.; Gobianand, K. and Karthikeyan, S. (2007). Silymarin modulates the oxidant-antioxidant imbalance during diethylnitrosamine induced oxidative stress in rats. *Eur J Pharmacol* 560, 110-116.
  54. Prakash, R. and Mullen, K.D. (2010). Mechanisms, diagnosis and management of hepatic encephalopathy. *Nat Rev Gastroenterol Hepatol* 7, 515-525.
  55. Prasanthi, K.; Muralidhara and Rajini, P.S., (2005). Morphological and biochemical perturbations in rat erythrocytes following in vitro exposure to Fenvalerate and its metabolite. *Toxicol in Vitro* 19, 449-456.
  56. Ramadan, M.F. and Moersel, J.T. (2007). Impact of enzymatic treatment on chemical composition, physicochemical properties and radical scavenging activity of goldenberry (*Physalis peruviana* L.) juice. *Journal of*



- the Science of Food and Agriculture 87, 452-460.
57. Ramadan, M.F. and Morsel, J.T. (2003). Oil goldenberry (*Physalis peruviana* L.). *J Agric Food Chem* 51, 969-974.
58. Ross, M.G. and Desai, M. (2005). Gestational programming: population survival effects of drought and famine during pregnancy. *Am J Physiol Regul Integr Comp Physiol* 288, R25-33.
59. Schepke, M. (2007). Hepatorenal syndrome: current diagnostic and therapeutic concepts. *Nephrol Dial Transplant* 22 Suppl 8, viii2-viii4.
60. Seeram, N.P.; Adams, L.S.; Henning, S.M.; Niu, Y.; Zhang, Y.; Nair, M.G. and Heber, D. (2005). *In vitro* antiproliferative, apoptotic and antioxidant activities of punicalagin, ellagic acid and a total pomegranate tannin extract are enhanced in combination with other polyphenols as found in pomegranate juice. *J Nutr Biochem* 16, 360-367.
61. Shaker, E.; Mahmoud, H. and Mnaa, S. (2010). Silymarin, the antioxidant component and *Silybum marianum* extracts prevent liver damage. *Food Chem Toxicol* 48, 803-806.
62. Singh, R.P.; Chidambara Murthy, K.N. and Jayaprakasha, G.K. (2002). Studies on the antioxidant activity of pomegranate (*Punica granatum*) peel and seed extracts using *in vitro* models. *J Agric Food Chem* 50, 81-86.
63. Sinha, A.K. (1972). Colorimetric assay of catalase. *Anal Biochem* 47, 389-394.
64. Sonnewald, U.; Therrien, G. and Butterworth, R.F. (1996). Portacaval anastomosis results in altered neuron-astrocytic metabolic trafficking of amino acids: evidence from <sup>13</sup>C-NMR studies. *J Neurochem* 67, 1711-1717.
65. Subash, S. and Subramanian, P., 2008. Effect of morin on the levels of circulatory liver markers and redox status in experimental chronic hyperammonaemic rats. *Singapore Med J* 49, 650-655.
66. Subash, S. and Subramanian, P. (2009). Morin a flavonoid exerts antioxidant potential in chronic hyperammonemic rats: a biochemical and histopathological study. *Mol Cell Biochem* 327, 153-161.
67. Swapna, I.; Kumar, K.V.; Reddy, P.V.; Murthy Ch, R.; Reddanna, P. and Senthilkumaran, B. (2006). Phospholipid and cholesterol alterations accompany structural disarray in myelin membrane of rats with hepatic encephalopathy induced by thioacetamide. *Neurochem Int* 49, 238-244.
68. Toklu, H.Z.; Dumlu, M.U.; Sehirli, O.; Ercan, F.; Gedik, N.; Gokmen, V. and Sener, G. (2007). Pomegranate peel extract prevents liver fibrosis in biliary-obstructed rats. *J Pharm Pharmacol* 59, 1287-1295.
69. Turk, G.; Sonmez, M.; Aydin, M.; Yuce, A.; Gur, S.; Yuksel, M.; Aksu, E.H. and Aksoy, H. (2008). Effects of pomegranate juice consumption on sperm quality, spermatogenic cell density, antioxidant activity and testosterone level in male rats. *Clin Nutr* 27, 289-296.
70. Vaquero, J.; Chung, C. and Blei, A.T. (2003). Brain edema in acute liver failure. A window to the pathogenesis of hepatic encephalopathy. *Ann Hepatol* 2, 12-22.
71. Wang, C.J.; Wang, J.M.; Lin, W.L.; Chu, C.Y.; Chou, F.P. and Tseng, T.H. (2000). Protective effect of Hibiscus anthocyanins against tert-butyl hydroperoxide-induced hepatic toxicity in rats. *Food Chem Toxicol* 38, 411-416.
72. Wasan, K.M.; Najafi, S.; Wong, J.; Kwong, M. and Pritchard, P.H. (2001). Assessing plasma lipid levels, body weight, and hepatic and renal toxicity following chronic oral administration of a water soluble phytosterol compound,

- FM-VP4, to gerbils. J Pharm Pharm Sci 4, 228-234.
73. Wong, F. and Blendis, L., 1994. Pathophysiology of sodium retention and ascites formation in cirrhosis: role of atrial natriuretic factor. Semin Liver Dis 14, 59-70.
74. Wu, S.J.; Ng, L.T.; Chen, C.H.; Lin, D.L.; Wang, S.S. and Lin, C.C. (2004). Antihepatoma activity of *Physalis angulata* and *P. peruviana* extracts and their effects on apoptosis in human Hep G2 cells. Life Sci 74, 2061-2073.
75. Wu, S.J.; Ng, L.T.; Huang, Y.M.; Lin, D.L.; Wang, S.S.; Huang, S.N. and Lin, C.C. (2005). Antioxidant activities of *Physalis peruviana*. Biol Pharm Bull 28, 963-966.
76. Yoshioka, T.; Kawada, K.; Shimada, T. and Mori, M. (1979). Lipid peroxidation in maternal and cord blood and protective mechanism against activated-oxygen toxicity in the blood. Am J Obstet Gynecol 135, 372-376.
77. Youdim, K.A.; Qaiser, M.Z.; Begley, D.J.; Rice-Evans, C.A. and Abbott, N.J. (2004). Flavonoid permeability across an in situ model of the blood-brain barrier. Free Radic Biol Med 36, 592-604.
78. Yousef, M.I.; Awad, T.I. and Mohamed, E.H. (2006). Deltamethrin-induced oxidative damage and biochemical alterations in rat and its attenuation by Vitamin E. Toxicology 227, 240-247.
79. Zielinska, M.; Hilgier, W.; Law, R.O.; Gorynski, P. and Albrecht, J. (2002). Effects of ammonia and hepatic failure on the net efflux of endogenous glutamate, aspartate and taurine from rat cerebrocortical slices: modulation by elevated K<sup>+</sup> concentrations. Neurochem Int 41, 87-93.

### التكميل الغذائي بالبونيكيا والفيساليس يقلل التأثير الضار للفينيتروثيون في الجرذان.

رشا عبد الغني – ابناء محمد – شيماء انيس – احمد بحيري – وليد بركات

التعرض للمبيدات الحشرية قد يؤدي الي العديد من المخاطر الصحية مثل خلل الكبد والذي قد يتبعه خلل في وظائف المخ والكلي.

تم تصميم البحث الحالي لدراسة التأثير النافع للتكميل الغذائي بالفيساليس بيروفيانا والبونيكيا جراناتم ضد التسمم المحدث بالفينيتروثيون. تم دراسة التأثير السام للفينيتروثيون (١٠ مجم/كجم/يوم بالفم لمدة ٢٨ يوم) على وظائف الكبد والمخ والكلي وكذا التأثير الوقائي للاستعمال اليومي للفيساليس (١٥ % من الغذاء) والبونيكيا (٣ مل/كجم) لمدة ٤٢ يوما بدأت قبل الفينيتروثيون ب ١٤ يوما.

تسبب الفينيتروثيون في حدوث اضطراب مبكر في وظائف الكبد مصحوبا بتغيير في مستوي الدهون والاملاح بالدم. الفينيتروثيون سبب ارتفاع في مستوي الامونيا في الكبد ثم الدم ثم المخ. حدث اضطراب في كلا من وظائف المخ والكلي فيما بعد. كذلك فان الفينيتروثيون قد تسبب حالة من الاجهاد التاكسدي في الكبد والمخ والكلي. الاستخدام الوقائي للفيساليس او البونيكيا او العقار الواقي للكبد المعياري السيليمارين أحدث تحسن كبير في هذه الآثار الضارة والذي قد يعزي الي الخصائص المضاد للاكسدة لهذه المركبات.

هذه النتائج تشير الي امكانية استخدام الفيساليس والبونيكيا مستقبلا في علاج التسمم بالمبيدات الحشرية بعد اجراء المزيد من الاختبارات لتحديد المواد الفعالة المسؤولة عن هذه الانشطة الوقائية.