


Pathological Assessment of Aspirin-Induced Gastric Ulcers Treated with Cordia Myxa

SHIMAA SWILAM ¹, AHMED FOTOUH  ¹, NANI NASRELDIN  ¹, ELHAGAG AHMED HASSAN  ² SARY KHALEEL ABD-ELGHAFFAR ³

¹Department of Pathology and Clinical Pathology. Faculty of Veterinary Medicine. New Valley University, El-Kharga, P.O. Box 72511, Egypt. 

²Department of Botany and Microbiology, Faculty of Science, Assiut University, Assiut 71516, Egypt. 

³Department of Pathology and Clinical Pathology, Faculty of Veterinary Medicine, Assiut University, Assiut, P.O. Box 71526, Egypt, School of Veterinary Medicine, Badr University in Assiut, Egypt. 

*Corresponding author:  shymaa.swilam@vet.nvu.edu.eg

Received at: 2024-08-30 Accepted at: 2024-11-03

ABSTRACT: This study investigates the therapeutic potential of Cordia myxa extract in treating gastric ulcers induced by Aspirin in rats, motivated by the limitations of existing treatments and the growing interest in herbal remedies, which are often associated with better cultural acceptance and fewer side effects. Forty-eight male albino rats were divided into six groups of eight. The control group received saline via gastric gavage, while the remaining groups were administered 500 mg/kg body weight of Aspirin once orally to induce gastric ulcers. The early ulcer group was sacrificed 6 hours post-Aspirin administration, while the late ulcer group was sacrificed 14 days later. The ulcer & Cordia myxa group received the extract at a dosage of 125 mg/kg/day for 14 days following Aspirin treatment. The ulcer & Pantoprazole group was treated with Pantoprazole at 40 mg/kg/day for the same duration, and the ulcer, Cordia myxa & Pantoprazole group received both treatments at the same dosages for 14 days after Aspirin induction. Histopathological analysis revealed severe gastric damage and bleeding in both the early and late ulcer groups, indicated by a significantly elevated ulcer index. In contrast, the group receiving both Cordia myxa and Pantoprazole demonstrated significantly reduced ulceration, well-preserved gastric mucosa, and intact epithelium, with a notable decrease in the ulcer index and high inhibition index compared to the late ulcer group. These results suggest that the combination of Cordia myxa and Pantoprazole provides an effective treatment for gastric ulcers, as confirmed by both macroscopic and histological evaluations.

KEYWORDS: Gastric ulcer, Cordia myxa, Pantoprazole, ulcer index

1. Introduction

Gastric ulcers, persistent sores on the stomach lining, pose a significant global health concern [1]. The development of these ulcers is primarily attributed to an imbalance between the stomach's protective mucus layer and aggressive factors such as stress, tobacco, alcohol, and certain drugs [2]. Excessive stomach acid production, often triggered by prolonged non-steroidal anti-inflammatory drug (NSAID) use or Helicobacter pylori infection, is a key contributor to the development of stomach ulcers. These factors activate specific cellular and molecular mechanisms that can lead to the formation of ulcers in the stomach or duodenum [3]. Anorexia, nausea, vomiting, bloating, gastrointestinal discomfort and acid reflux are all common clinical symptoms. Gastric ulcer affects 8%

to 10% of the world's population, with 40% in developed countries and 80% in developing nations [4]. Aspirin, a commonly prescribed NSAID, has been utilized for many years as a pain reliever, antipyretic, and anti-inflammatory drug to combat various forms of inflammation and to prevent cardiovascular thrombotic conditions [5]. Despite, its therapeutic benefits, it presents a significant issue because of its association with gastric ulcers, gastrointestinal bleeding and perforation [6]. Where, aspirin inhibits the enzyme cyclooxygenase (COX), which produces prostaglandins [7]. This inhibition can lead to decreased secretion of mucus and bicarbonate, reduced mucosal blood flow, neutrophil infiltration, alterations in microvascular architecture, diminished cell proliferation, increased acid and pepsinogen secretion, ultimately compromising mucosal defense and impairing healing [8].

Additionally, NSAID-induced ulcers, particularly those caused by Aspirin, are linked to higher lipid peroxidation and elevated reactive oxygen species (ROS) production. Moreover, aspirin can break down phospholipids in mucosal epithelial cells, which can increase permeability and induce inflammation [9]. Primary treatments for gastric ulcers involve the use of proton pump inhibitors (PPIs) like Pantoprazole, Omeprazole, and Lansoprazole to reduce acid production and promote mucosal healing, along with antibiotics to eradicate *Helicobacter pylori* infection [10, 11]. However, prolonged use of these medications can lead to complications such as antimicrobial resistance, reduced nutrient absorption, enteric infections and cognitive decline [12]. So, the plant-based medicines are regarded as the primary choice for preserving health and fighting illnesses, serving as a key reservoir for developing new therapeutic drugs even in modern time [13]. Furthermore, medicinal plants are recognized for their effectiveness, safety and accessibility as alternative treatments for gastric ulcer disease [14]. *Cordia myxa* (*C.myxa*) is a flowering plant from the Boraginaceae family that grows in both subtropical and tropical regions of Asia, Australia and Africa. *Cordia* species fruits are high in key minerals, carbs, essential fatty acids, vitamins and proteins [15]. It is widely used in traditional medicine for its varied therapeutic properties, including wound healing, demulcent, anthelmintic, diuretic, astringent, emollient, expectorant, hepatoprotective, analgesic, immune modulator, hypoglycemic, anti-inflammatory, laxative, antioxidative stress, hypolipidemic, aphrodisiac and antiulcer activities [16]. *Cordia myxa*, known as Mokhed in Arabic, is cultivated in the New Valley Governorate, Egypt. This versatile tree is utilized for various purposes, including food, medicine and local materials. Its cultivation dates back to ancient Egyptian times, and it continues to be valued for its culinary and healing qualities in numerous

tropical and subtropical regions [17]. The gastroprotective effects of *Cordia myxa* are thought to be due to its antioxidant and anti-inflammatory properties. The fruit pulp of *Cordia myxa* contains compounds such as Quercetin and Kaempferol. They are flavonoids which have been shown to have these effects [18]. Therefore, this study was performed to investigate the antiulcer activities and potential efficacy of *Cordia myxa* alone or combined with Pantoprazole in treating gastric ulcers induced by Aspirin in rats.

2. Materials and Methods

2.1. Animals

Forty-eight male Albino rats weighing between 180 and 200 g obtained from the Assuit Animal House, Faculty of Veterinary Medicine, Assuit University were used for the study. Rats were acclimatized for two weeks under controlled conditions, including full access to water and food, at a constant temperature of $25 \pm 2^\circ\text{C}$, humidity, and a 12-hour light-dark cycle. The experimental procedures followed the ethical guidelines of the New Valley Research Committee of the Faculty of Veterinary Medicine, New Valley University in Egypt (ethical permission number: 02-2-12-2023-4).

2.2. *Cordia myxa* preparation

Fresh fruits of *Cordia myxa* were obtained from New Valley Governate. According to Abdallah et al [18] the fruits of *Cordia myxa* were thoroughly cleaned and washed many times with running water. The ethanolic extract was prepared by soaking 500 g of *Cordia myxa* fruits in 1 liter of a solvent containing 700 ml of 95% ethanol and 300 ml of distilled water. The solvent was shaken every day for two days while being prepared, and then refrigerated. After filtering the infusion through a piece of double-layered gauze, fresh solvent was added to the plant materials. The mixed filtrates were evaporated using a Swiss rotary evaporated apparatus linked to a vacuum pump and centrifuged at 3000 rpm for 10 minutes.

2.3. Chemicals

This study utilized Aspirin (Rivo® tablets, 320mg) obtained from the Arab Drug Company (ADCO) for Pharmaceuticals and Chemical Industries [19]. Pantoprazole was obtained from Pharonia Pharmaceuticals (Batch NO:200060070322).

2.4. Experimental design

Forty-eight rats were randomly divided into six groups (n=8 in each group) where prior to the induction of Aspirin, all rats, with the exception of those in the control group, were fasted for 24 hours, with access to water during the last 2 hours of the fasting period:

- Control group (G1): Rats received saline via gastric gavage.
- Early ulcer group (G2): Rats sacrificed 6 hours post-aspirin administration (500 mg/kg, orally) [20, 19].
- Late ulcer group (G3): Rats sacrificed 14 days post-aspirin administration (500 mg/kg, orally) [20, 19].
- Ulcer & Cordia myxa group (G4): Rats received 125 mg/kg/day of Cordia myxa extract dissolved in distilled water orally beginning 24 hours after ulcer induction and continuing for 14 days [21].
- Ulcer & Pantoprazole group (G5): Rats treated with pantoprazole at 40 mg/kg/day dissolved in distilled water orally commencing 24 h after gastric ulcer induction and continuing for 14 days [22].
- Ulcer, Cordia myxa & Pantoprazole group (G6): Received Cordia myxa (125 mg/kg/day) and Pantoprazole (40 mg/kg/day) orally starting 24 h after gastric ulcer induction and continuing for 14 days.

2.5. Assessment of Gastric Juice pH

After 6 hours in early ulcer group and following a 14-day treatment period for all other groups, the rats were euthanized, and their stomachs were removed. Gastric contents were collected, transferred to centrifuge tubes and centrifuged at (4000 rpm/10 min/4°C). The pH of the resulting supernatant was measured using a pH meter.

2.6. Macroscopic Examination and Evaluation of ulcer index (UI) and percentage of inhibition index (I%):

Stomach was opened along the greater curvature, washed with cold phosphate buffer saline (pH 7.4) and flattened on paraffin cardboard, with the mucosal surface pointed upwards and images were taken to measure the ulcer area. The parameters for determination of UI were color of the mucosa, hyperemia, hemorrhagic spots and number of ulcers. These scores (Table 1) were graded according to as follows on the basis of their intensity according to Mohamed et.al [23].

- No ulcer: Score of 0
 - Reddish mucosa: Score range of 0.5 - 1
 - Presence of hemorrhagic spots: Score range of 1 - 2
 - 1-5 Small ulcers present: Score range of 2 - 3
 - Multiple small ulcers observed: Score range of 3 - 4
 - 1-3 Large ulcers: Score range of 4 - 5
 - Combination of several small and large ulcers: Score range of 5 - 6
 - Stomach completely covered in ulcers or perforations: Score of 6
- Moreover, the percentage inhibition index (I%) associated with UI was calculated using the following equation (Yang et al., 2024). $I\% = [(UI \text{ Late ulcer group} - UI \text{ treated group}) / UI \text{ Late ulcer group}] \times 100\%$

2.7. Histopathological evaluation

Then, stomachs from all animals were immediately immersed in 10% neutral buffer formalin, dehydrated in ethanol, cleared in xylene, paraffin embedded, processed, sectioned in 5 µm thickness and stained with hematoxylin and eosin (H&E) [24].

2.8. Statistical analysis

The results were expressed as the mean ± S.D. Comparisons between groups were performed by one-way analysis of variance (ANOVA), post-hoc test with LSD corrections. Using SPSS. 27. Where, $P \leq 0.05$ was considered significant.

3. Results

3.1. Gross Image Analysis, Ulcer Index (UI), and Inhibition Index (I%)

The macroscopic examination showed that the stomachs from the control group had normal mucosa with prominent rugae without any visible injuries (Fig. 1.A), the stomachs from early ulcer group exhibited severe morphological damage with ulcerative lesions and hemorrhagic damage (Fig. 1.B), with an elevated UI compared to the control group ($P < 0.001$) (Fig. 4). Stomach from the late ulcer group displayed severe ulcer injuries and widespread hemorrhagic lesions of the gastric mucosa (Fig. 1.C), along with a statistically significant increase in the UI ($P < 0.001$) (Fig. 4). The gastric mucosa in ulcer & Cordia myxa group demonstrated marked decrease in the size and severity of the ulcerative lesions (Fig. 1.D) and a significant reduction in the UI compared to the untreated Late ulcer group ($P < 0.001$). (Fig. 4). Pantoprazole treatment in ulcer & Pantoprazole resulted in superficial punctate and minor hemorrhages (Fig. 1.E), with a significant decrease in the UI compared to the Late ulcer group ($P > 0.001$) (Fig. 4). Finally, ulcer, Cordia myxa & Pantoprazole, the combined treatment was significantly reduced the severity of the ulcerative lesions and promoted the healing of the gastric mucosa (Fig. 1.F), as evidenced by the significant decrease in the UI compared to late ulcer group. (Fig. 4). The calculation of I% demonstrated that rats administered Cordia myxa alone exhibited a net I% of 69.71%, whereas rats given Pantoprazole showed a net I% of 85.71%. While the rats which treated by Cordia myxa and Pantoprazole showed a net I% of 89.14%, suggesting that the combined treatment of Cordia myxa and Pantoprazole had a more substantial therapeutic effect. The results for UI and I% were summarized in (Table 1).

3.2. Effect of Different Treatments on Gastric pH

The gastric pH was found to be significantly lower in the early ulcer and late ulcer groups compared to the control group ($P < 0.001$). In contrast, groups ulcer & Cordia

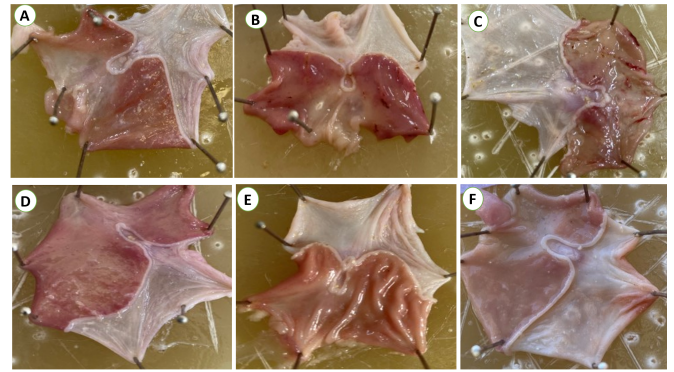


Figure 1: Gross picture of gastric mucosa in different experimental groups; Control group (A), Early ulcer group (B), Late ulcer group (C), Ulcer & Cordia myxa group (D), Ulcer & Pantoprazole group (E) and Ulcer, Cordia myxa & Pantoprazole group (F).

myxa, ulcer & pantoprazole, and ulcer, Cordia myxa & pantoprazole showed a significant increase in gastric pH compared to the late ulcer group ($P < 0.001$ and $P < 0.001$, respectively). The gastric pH levels in various groups in the experiment were presented in (Fig. 3).

3.3. Histopathological findings

Histopathological evaluation of stomach from control group illustrates intact, normal histological structure. The gastric mucosa has a simple columnar epithelium lining, broad crypts, and gastric glands. It contains loose connective tissue, blood vessels, nerves, and muscularis externa. The outermost layer, the serosa, is made up of a thin layer of connective tissue (Fig. 2.A). In contrast, the histopathological evaluation of the early ulcer group revealed massive erosions with necrosis and sloughing of epithelium in tips of mucosa, severe congestion and edema in the submucosa as well as coagulative necrosis in the gastric glands (Fig. 2.B). Where, late ulcer group revealed acute ulceration after 14 days, with significant gastric mucosal damage. This damage involved necrosed and detached epithelial cells, disrupting the mucosal integrity (Fig. 2.C). Examination of the stomachs in the ulcer & Cordia myxa group showed that the stomach lining was nearly restore its simple columnar epithelium with presence of slight erosions (Fig. 2.D). The ulcer & Pantoprazole group showed

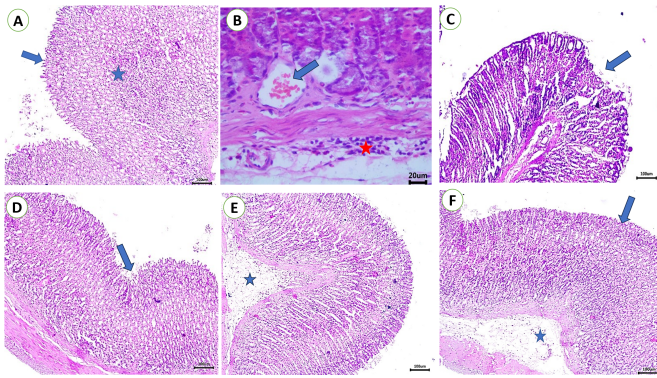


Figure 2: Histopathological findings of gastric specimens in the different experimental groups stained by H& E stain: (A) Photomicrograph of gastric tissue of rats in control group showing intact histological structure in fundic region as normal intact mucosa (simple columnar epithelium, arrow) and normal gastric gland (parietal cells and gastric pits, star) bar 100 μ m. (B): Photomicrograph of stomach of rats in early ulcer group revealing congestion in deep layer of mucosa (arrow), inflammatory cell infiltration in submucosa (red star) bar 20 μ m. (C): Photomicrograph of stomachs of rats of late ulcer group illustrating massive necrosis and sloughing of tips of the mucosa (arrow) bar 100 μ m. (D): Photomicrograph of rat stomach in ulcer & Cordia myxa group exhibiting superficial erosion in epithelium (arrow) bar 100 μ m. (E): Photomicrograph of rat stomach of ulcer & Pantoprazole group manifesting edema and inflammatory cell infiltration in lamina propria (star) bar 100 μ m. (F): Photomicrograph of gastric tissue in ulcer, Cordia myxa & Pantoprazole group revealing a well-preserved glandular architecture of the gastric mucosa (arrow), with intact surface epithelium and normal gastric pits and glands with mild edema in the gastric submucosa (star) bar 100 μ m.

a well-preserved glandular architecture of the gastric mucosa, with intact surface epithelium and normal gastric pits and glands with mild edema and inflammatory cell infiltration could be observed in the gastric submucosa (Fig. 2.E). The photomicrograph of gastric tissue in ulcer, Cordia myxa & Pantoprazole revealed a well-preserved glandular architecture of the gastric mucosa, with intact surface epithelium and normal gastric pits and glands with mild edema in the submucosa (Fig. 2.F).

	Control (n=8)	Early ulcer (n=8)	Late ulcer (n=8)	Ulcer & Cordia myxa (n=8)	Ulcer&pantoprazole (n=8)	Ulcer:Cordia myxa &pantoprazole (n=8)
UI	NR	2.13±1.33	3.5±1.69	1.06±0.62	0.5±0.46	0.38±0.35
I%	NR	NR	NR	69.71%	85.71%	89.14%

Table 1: Ulcer index (UI) values were presented as mean \pm SD, and the percentage inhibition index (I%) was calculated. A p-value of >0.01 was deemed highly statistically significant when compared to the Late ulcer group. “NR” denotes that the data is not relevant.

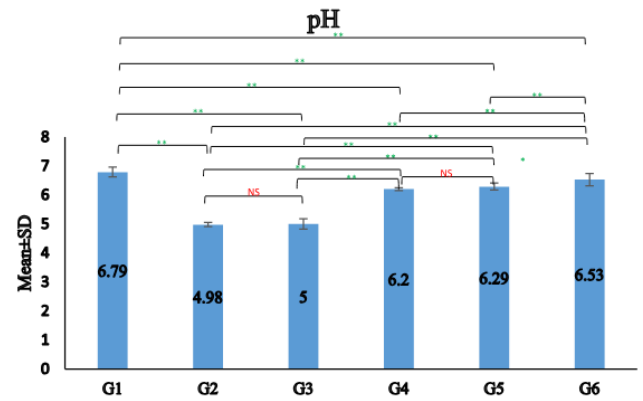


Figure 3: Comparison of gastric pH among experimental groups. Data represent mean \pm standard deviation (SD) pH values for each experimental group (n=8). Statistical significance was determined using one-way ANOVA with *p < 0.05 and **p < 0.01 indicating significant and highly significant differences, respectively. While, NS denotes no significant difference (p > 0.05).

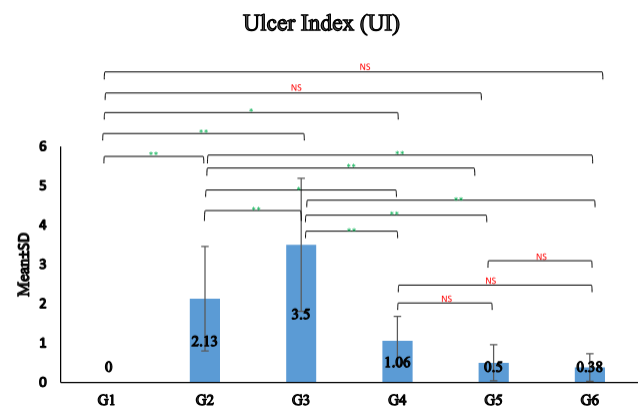

Figure 4: Comparison of ulcer index (UI) between the studied groups. Ulcer index values (mean \pm SD) were compared among experimental groups (n=8). Statistical significance was determined using one-way ANOVA with *p < 0.05 and **p < 0.01 indicating significant and highly significant differences, respectively. While, NS denotes no significant difference (p > 0.05).

4. Discussion

The study investigated the efficacy of Cordia myxa fruit extract as a potential treatment for aspirin-induced gastric ulcers in rats prompted by the limitations of proton pump inhibitors as inadequate healing, adverse long-term effects, and high costs, which have driven interest in natural products as alternative therapies [2]. The current study revealed various macroscopic changes in the gastric mucosa. In the control group, the gastric mucosa

appeared healthy with normal white rugae. In contrast, the early ulcer group, treated with 500 mg/kg of Aspirin and sacrificed after 6 hours, showed significant gastric damage, including ulcerative lesions and hemorrhagic areas, resulting in a marked increase in UI. The late ulcer group, receiving the same aspirin dosage but sacrificed after 14 days, exhibited widespread ulcer injuries and extensive hemorrhagic lesions, with a statistically significant increase in UI as compared to control group. These findings suggest that Aspirin administration results in both acute and chronic gastric ulceration, with the development of ulcerative lesions and hemorrhagic areas attributed to multiple pathogenic mechanisms responsible for gastric mucosal damage, consistent with previous research by Mahmoud and Abd El-Ghffar [19]. These mechanisms of NSAIDs include increased gastric acid secretion, oxidative stress, inflammation, impaired mucosal defense and nitric oxide dysregulation. The combination of these factors likely leads to the breakdown of the gastric epithelial barrier, resulting in the formation of extensive ulcerative lesions and hemorrhagic areas as mentioned by Khalil [25]; Mahmoud and Abd El-Ghffar [19]; Okkay et al. [26]; Tanaka et al. [27]. The administration of *Cordia myxa* extract significantly mitigated the severity of aspirin-induced gastric ulcers in rats, as evidenced by a marked reduction in ulcer size and UI in ulcer & *Cordia myxa* compared to the untreated late ulcer group. These findings aligned with previous studies [18, 28]. The extract's antioxidant properties and ability to enhance mucin production are believed to contribute to its ulcer-healing properties [21]. Pantoprazole treatment in ulcer & Pantoprazole resulted in superficial punctate and minor hemorrhages with a significant decrease in the UI and increase in I% compared to the late ulcer group. This effectiveness is attributed to Pantoprazole's ability to prevent mucosal cell damage caused by NSAIDs and its cytoprotective effects, which inhibit oxidative injury and reduce gastric acid secretion [29, 30]. Consequently,

the synergistic effects of the combined treatment with *Cordia myxa* and Pantoprazole reduced the severity of the ulcerative lesions and promoted the healing of the gastric mucosa, as evidenced by the significant decrease in the ulcer index and high I% (89.14%). Hydrochloric acid produced by gastric parietal cells creates the highly acidic conditions in the stomach lumen $\text{pH} < 2$. This acidic environment serves several important functions as bacterial elimination which present in food, aiding in the digestion of food, and enhancing the absorption of minerals such as phosphate, calcium and iron. However, excessive acid secretion can also pose a risk to the integrity of the gastric mucosa [31]. In the present study, pH was significantly decreased in Aspirin treated groups as early ulcer and late ulcer groups in comparison to control. This in agreement with El-Kerdasy et al. [32]. *Cordia myxa* extract significantly increased gastric pH in the ulcer & *Cordia myxa* group compared to late ulcer group, suggesting potent anti-secretory properties that may protect the stomach lining from acid-induced damage. These findings align with those of [18]. Also, the Pantoprazole treatment elevated the gastric pH in ulcer & Pantoprazole in comparison to late ulcer group. Our results were in accordance with Awan et al. [33, 11, 34, 35]. works by blocking the stomach's H^+/K^+ ATPase proton pumps, reducing the production of stomach acid by stomach parietal cells leading to an increase in intragastric pH. In this work, pH was elevated in ulcer, *Cordia myxa* & Pantoprazole as compared to late ulcer group. This was due to synergistic effect of *Cordia myxa* and pantoprazole in decreasing acid output by *Cordia myxa* extract and Pantoprazole. Histopathological investigation is widely recognized as a crucial step in understanding the pathogenesis of various diseases [36]. The rat stomach has distinct glandular and non-glandular regions separated by a ridge. Its wall comprises mucosa, submucosa, muscularis and serosa layers. Gastric glands open into gastric pits within the mucosa [37, 27]. Our histopathological finding revealed

that single oral dose of Aspirin 500mg/kg in early ulcer group made ulceration and sloughing of epithelial cells of mucosa, severe congestion and edema in the submucosa as well as coagulative necrosis and edema in the gastric glands. These findings came in agreement with El-Kerdasy et al.[32, 38]. The current study demonstrated that the late ulcer group revealed acute ulceration after 14 days, with significant gastric mucosal damage. This damage involved distended and detached epithelial cells, disrupting the mucosal integrity. Our findings are also in agreement with Mahmoud and Abd El-Ghffar [19], who gave 500mg/kg bw. Also, these findings aligned with the observations reported by Abdelatif et al.[39], which investigated the oral dosage of 300 mg/kg of Aspirin diluted in 3 mL of 1% carboxymethyl cellulose showed ulceration, desquamation, and exfoliation of the surface epithelial cells. Where the pathogenesis of Aspirin inducing gastric ulcer is due to inhibition of cyclooxygenase enzymes, which are involved in the production of prostaglandins [40]. This inhibition of cyclooxygenase activity, results in reduced mucus and bicarbonate secretion, mucosal blood flow reduction, neutrophil infiltration, modification of microvascular architecture, and elevation of acid and pepsinogen secretion [9]. Furthermore, Aspirin lyses phospholipids in mucosal epithelial cells, leading to increased permeability and inflammation [19]. In the present study, histopathological gastric sections of ulcer & Cordia myxa group showed congestion in the blood vessels of the submucosa, while the stomach lining was restored to a simple columnar epithelium with slight erosion in the epithelium. Similar observations were reported by Mahmood et al.[41]. The rat stomach in ulcer & Pantoprazole group exhibited well-preserved gastric architecture and minimal inflammation. These findings aligned with the established role of Pantoprazole in preventing gastric damage induced by various NSAIDs [29]. Additionally, Abd-Alla et al. [42] mentioned that Pantoprazole promotes the healing of gastric tissues by reducing gastric

acid secretion and increasing mucus production, creating a more favorable environment for mucosal recovery . The ulcer, Cordia myxa & Pantoprazole group revealed a combined treatment of Cordia myxa and Pantoprazole was found to result in nearly normal histological structures of the gastric epithelium, with intact mucosa, submucosa, and muscularis layers. This indicated a superior ulcer healing effect compared to the individual treatments, demonstrating the synergistic benefits of the combined approach. In summary, the synergistic gastroprotective effects of Cordia myxa and pantoprazole can be attributed to the complementary mechanisms of action, where cordia myxa's cytoprotective properties work in conjunction with pantoprazole's acid-suppressing ability to promote more effective healing of the gastric ulcerative lesions.

Conclusion

The current research illustrates the potential of Cordia myxa fruit extract in protecting the stomach from ulcers caused by aspirin. When used in combination with Pantoprazole, Cordia myxa showed improved histopathological outcomes compared to either treatment alone. Moreover, the co-administration of Cordia myxa and Pantoprazole further enhanced their protective effects on the stomach. These findings suggest that the combined use of Cordia myxa extract and Pantoprazole could be a promising therapeutic approach for treating gastric ulcers. The results validate the traditional use of Cordia myxa and indicate the need for further investigation into its mechanisms of action and potential clinical applications.

References

- [1] N. Shahzad, I. Ibrahim, A. Alzahrani, S. Al-Ghamdi, I. Alanazi, M. Ahmad, A. Singh, M. Alruqi, I. Shahid and A. Equbal, *J. Umm Al-Qura Univ. Appl. Sci.*, 2024, 1–16.
- [2] S. Shams and R. Eissa, *Heliyon*, 2022, **8**, year.
- [3] S. Kumar, V. Sharma and M. Devi, *J. Pharm. Res. Int.*, 2023, **35**, 49–58.
- [4] A. Sayed, N. Mahmoud, O. Mohawed and H. Ahmed, *Inflammopharmacology*, 2024, **32**, 1961–1982.
- [5] I. Ahmed, M. Elkablawy, D. El-Agamy, A. Bazarbay and N. Ahmed, *Hum. Exp. Toxicol.*, 2020, **39**, 1257–1267.
- [6] J. Petersen, J. Møller Hansen, O. Muckadell, M. Dall and J. Hallas, *Basic Clin. Pharmacol. Toxicol.*, 2020, **126**, 437–443.
- [7] G. García-Rayado, M. Navarro and A. Lanás, *Expert Rev. Clin. Pharmacol.*, 2018, **11**, 1031–1043.
- [8] L. McEvoy, D. Carr and M. Pirmohamed, *Front. Pharmacol.*, 2021, **12**, 1–15.
- [9] V. Cuevas, Y. Calzado, Y. Guerra, A. Yera, S. Despaigne, R. Ferreira and D. Quintana, *Adv. Pharmacol. Sci.*, 2011, 1–6.
- [10] M. Beiranvand, S. Bahramikia and O. Dezfoulian, *Inflammopharmacology*, 2021, **29**, 1503–1518.
- [11] I. Sawaid and A. Samson, *J. Clin. Med.*, 2024, **13**, year.
- [12] H.-M. Lien, Y.-Y. Wang, M.-Z. Huang, H.-Y. Wu, C.-L. Huang, C.-C. Chen, S.-W. Hung and Chen, *Antioxidants*, 2022, **11**, 2327.
- [13] M. Matcheme, B. Dabolé, D. Moussa, J. Nyemb, T. Emmanuel, S. Laurent, C. Henoumont and A. Venditti, *Nat. Prod. Res.*, 2023, 1–9.
- [14] H. Ardalani, A. Hadipanah and A. Sahebkar, *Mini Rev. Med. Chem.*, 2020, **20**, 662–702.
- [15] M. Al-Musawi, K. Ibrahim and S. Albukhaty, *Iran. J. Microbiol.*, 2022, **14**, 97–103.
- [16] K. El-Massry, A. Farouk, K. Mahmoud, A. El-Ghorab, S. M. A. Musa, E. Mostafa, M. Ghoneim, I. Naguib and M. Abdelgawad, *Saudi J. Biol. Sci.*, 2021, **28**, 5349–5358.
- [17] W. Elkot, H. Ismail and A. Rayan, *Egypt. J. Food Sci.*, 2017, **45**, 125–134.
- [18] I. Abdallah, H. Khattab and G. Heeba, *Life Sci. J.*, 2011, **8**, 433–445.
- [19] Y. Mahmoud and E. Abd El-Ghffar, *Biomed. & amp; Pharmacother.*, 2019, **109**, 314–321.
- [20] H. Mabrok and M. Mohamed, *Mol. Biol. Rep.*, 2019, **46**, 4213–4224.
- [21] M. Oza and Y. Kulkarni, *J. Pharm. Pharmacol.*, 2017, **69**, 755–789.
- [22] A. Mohamed, S. Abd-Elghaffar, R. Mousa, Kamel and A.A., *Assiut Vet. Med. J.*, 2023, **69**, 196–208.
- [23] A. Mohamed, S. Abd-Elghaffar, R. Mousa and A. Kamel, *Mol. Biol. Rep.*, 2024, **51**, 401.
- [24] W. Abu El Hammed, H. Soufy, A. El-Shemy, A. Fotouh, S. M. Nasr and M. I. Dessouky, *Egyptian Journal of Chemistry*, 2022, **65**, 269–282.
- [25] M. Khalil, *Histol Histopathol.*, 2015, **30**, 10.
- [26] I. Okkay, U. Okkay and O. Karatas, *Dicle Tip Derg.*, 2021, **48**, 732–739.
- [27] T. Tanaka, K. Morito, M. Kinoshita, M. Ohmoto, M. Urikura, K. Satouchi and A. Tokumura, *Dig. Dis. Sci.*, 2013, **58**, 950–958.
- [28] A. Wani, N. Kousar and S. Pundir, *Comput. Algorithms Numer. Dimens.*, 2024, **2**, 186–194.
- [29] M. Fornai, R. Colucci, L. Antonioli, N. Ghisu, M. Tuccori, C. Blandizzi and M. Del Tacca, *Naunyn-Schmiedeberg's Arch. Pharmacol.*, 2009, **379**, 305–313.
- [30] H. Lee, Y. Han, E. Kim, Y. Kim and K. Hahm, *BMC Gastroenterol.*, 2012, **12**, year.
- [31] A. Engevik, I. Kaji and J. Goldenring, *Physiol. Rev.*, 2020, **100**, 573–602.
- [32] H. El-Kerdasy, H. Mousa, H. Elkerdasy and H. Mousa, *Egypt. J. Histol.*, 2021, **44**, 993–1006.
- [33] T. Awan, B. Aslam, I. Javed, T. Khaliq, A. Ali and Z. Sindhu, *Pakistan J. Agric. Sci.*, 2015, **52**, 563–568.
- [34] G.-D. Shams, M. Kamel and A. Afifi, *Benha Vet. Med. J.*, 2019, **36**, 418–428.
- [35] A. Fotouh, H. Soufy, M. El-Begawey and S. Nasr, *J Adv Vet Anim Res.*, 2020, **8**, 590–600.
- [36] N. Nasreldin, S. Swilam, S. M. Abd-Elrahman, A. El-ghaffar and S. Khaleel, *New Valley Veterinary Journal*, 2022, **2**, 16–27.
- [37] G. Chandana, P. Kishore, N. Raju, M. Sreenu and G. Srinivasa Rao, *Indian J. Vet. Anat.*, 2013, **25**, 107–108.
- [38] N. Sultana, M. Khan, N. Ahmed, M. Akhter and A. Momtaz, *Delta Med. Coll. J.*, 2016, **4**, 61–66.
- [39] B. Abdelatif, F.-N. El-Safty, A. Zolfakar and A. Essawy, *J. Clin. Diagnostic Res.*, 2019, **13**, year.
- [40] J. Vane and R. Botting, *Thromb. Res.*, 2003, **110**, 255–258.
- [41] H. Mahmood, G. Dawood and A. Bargooth, *Medico-Legal Updat.*, 2020, **20**, 453–456.
- [42] H. Abd-Alla, G. Ibrahim Fouad, K. Ahmed and K. Shaker, *Biomarkers*, 2022, **27**, 727–742.