

The Ototoxic Potential of Digoxin in Laboratory Animals

Amira M. Elkhawaga^{*1}, Shirley R. Henry², Hebatalla I. Ahmed³ and Mohamed R. Hamed⁴

¹Central Administration of Drug Control (CADC), Egyptian Drug Authority (EDA), Giza, Egypt.

²Department of Histology, Egyptian Drug Authority (EDA), Giza, Egypt.

³Department of Pharmacology and Toxicology, Faculty of Pharmacy (Girls), Al- Azhar University, Cairo, Egypt.

⁴Department of Developmental pharmacology, National Organization of Drug control and Research (NODCAR), Giza, Egypt

* Correspondence: e-mail: Amira_elkhawaga@yahoo.com

Article history: Received 14-03- 2024

Revised 10-05-2024

Accepted 11-06-2024

Abstract: The present study aimed to investigate the possible ototoxic interaction between digoxin (DX) and each of sodium salicylate (SS) and furosemide (FS). Preyer's reflex (hearing test) was performed in rats and guinea pigs. Each of Na⁺/k⁺/ATPase activity, outer hair cells (OHCs) count, inner hair cells (IHCs) count and histopathological examination of cochlea were evaluated in guinea pigs. The utilized animals included 230 Sprague-Dawley rats and 75 guinea pigs. Experiments were done on two phases. In phase I, single treatment of different dose levels of each SS, FS and DX was tested. In phase II, combined treatments were applied where one dose of SS or FS was administered in combination with two dose levels of DX. In rats, combined treatment of SS and DX didn't significantly affect Preyer's reflex score. On the other hand, combined treatment of FS (100 mg/kg) and DX (30 mg/kg) significantly increased Preyer's reflex score. In guinea pigs, combined treatment of DX with each of SS or FS didn't significantly affect Na⁺/k⁺/ATPase activity. Combined treatment of DX (0.2 mg/kg or 0.3 mg/kg) with SS (200 mg/kg) decreased OHCs count. However, the combined treatment with 0.3 mg/kg of DX significantly increased IHCs. On the other side, combined treatment of FS and DX didn't significantly affect OHCs or IHCs count. In parallel, histopathological examination of cochlea indicated similar findings. The obtained results may indicate that co-administration of DX with SS or FS possesses ototoxic potential.

Keywords: Ototoxicity, Sodium salicylate, furosemide, OHCs, IHCs

This is an open access article distributed under the CC BY-NC-ND license
<https://creativecommons.org/licenses/by/4.0/>

1. INTRODUCTION

Digoxin (DX) has been used globally to treat a wide range of cardiac conditions, such as different forms of arrhythmia and cases of variable-etiology cardiac insufficiency. LD50 in guinea pigs was reported as 0.60 ± 0.04 (P < 0.01)¹. One of the main problems with DX's medical use is from its rather limited therapeutic index. The most common side effects include anorexia, vomiting, diarrhea, nausea, and potentially fatal changes in heart rhythm (tachycardia or bradycardia)². High concentrations of DX are associated with neurological problems as color vision, headache, dizziness (vertigo), fatigue and disorientation. Preclinical research is controversial, and the mechanisms underlying the observed ototoxicity are still mostly unclear³⁻⁵.

Excessive amounts of sodium salicylate (SS) have been shown to injury the inner ear over time, reducing peripheral system neuronal output and possibly up-regulating the superoxide radical in an odd way, which causes apoptosis of SGN⁶. Furthermore, SS competitively suppresses the binding of chloride to anion binding sites on the motor protein prestin, which lowers the electromotility of OHCs and blocks potassium currents on cochlear sensory cells. These effects of SS on the cochlea include a reduction in OHC electromotility and potassium currents⁷. The finding that self-reported hearing loss precedes tinnitus experience could suggest that the brain is more

Cite this article: Elkhawaga, A., Henry, S., Ahmed, H. and Hamed, M. The Ototoxic Potential of Digoxin in Laboratory Animals. Azhar International Journal of Pharmaceutical and Medical Sciences, 2025; Vol 5 (1): 263-277.
[doi: 10.21608/ajpms.2024.276765.1264.10](https://doi.org/10.21608/ajpms.2024.276765.1264.10)

DOI : [10.21608/ajpms.2024.276765.1264.10](https://doi.org/10.21608/ajpms.2024.276765.1264.10).

susceptible to salicylate than the cochlea, as salicylate is transported to both the perilymph and cerebrospinal fluid. Moreover, it has been discovered that salicylate directly affects inhibitory neurotransmission in the brain, a finding that could speed up the rate at which phantom sound appears after systemic drug treatment⁸.

According to animal research, furosemide (FS) produces a dose-dependent, transitory loss of hearing through a reversible decrease in the endocochlear potential. It reversibly inhibits the Na-K-Cl cotransporter in the loop of Henle's thick ascending limb. Comparable transporters are also found in the inner ear, where they control mechanical transduction and the ionic content of the endolymph. Furthermore, the injection of FS momentarily reduces blood flow, which compromises the endothelium's barrier function and makes it easier for other ototoxic medications, such as aminoglycosides and cisplatin, to enter the inner ear. As a result, FS makes aminoglycosides and cisplatin more ototoxic⁹. Another method involves the interference of Na-K-Cl cotransporter inhibition, which is expressed at the base of the marginal and dark cells of the stria vascularis of the cochlea, with fluid and electrolyte balance. In light of the fact, these cells secrete endolymph, the endolymphatic potential subsequently decreases¹⁰. Accordingly, the purpose of this study is to explore any potential ototoxic interactions that may exist between DX and each of SS or FS.

2. MATERIAL

2.1. Drugs

Sodium salicylate was obtained as a raw material from Al-Gomgoria Company for medicines and medical supplies. On the other hand, FS was purchased from Huzhou Tophope Trade Co., Ltd while DX was obtained as a raw material from Acros Organic Company. For dosages administration SS was dissolved in saline⁶, FX was dissolved in 0.25 M sodium bicarbonate while DX was dissolved in 1% Tween80.

2.2. Kits used

The activity of Na⁺/K⁺ ATPase was evaluated by using Na⁺ /K⁺/ATPase Microplate Assay Kit which was purchased from My Biosource Company catalog number MBS8243226.

2.3. Experimental animals

The Ethics Committee of the Faculty of Pharmacy, Al-Azhar University, granted approval for this study (No: 181) based on the NIH Guide for the Principles

of Laboratory Animal Care (Publications No. 85-23, revised 2011), which contains standard recommendations.

Regarding Guinea Pigs, 75 adult animals (both sexes) weighting 300-500 gm were utilized (5 animal per group). They were obtained from a private commercial animal house. They were housed in an animal house with a 12-hour light-dark cycle, three animals per cage, relative humidity, and unlimited access to food and water. The animals were housed for two weeks prior to the commencement of the experiment.

As for rats, 230 adult male Sprague-Dawley albino rats were utilized weighting 250-300 gram (10 rats per group). Animals were acquired from the National Organization for Drug Control and Research's (NODCAR) breeding colony. They were caged as five per cage and maintained in the animal house, with 12-h light-dark cycle with unrestricted availability of food and water ad libitum. They were allowed for one-week accommodation before starting the experiment.

2.4. Experimental protocol

2.4.1. Experimental groups

They are divided into Guinea pig and rat groups.

2.4.1.1. Guinea pigs groups

These are divided into single treatment groups which were denoted as phase one treatment, and combined treatment groups, which were denoted as phase two treatment. The single treatment groups were subjected to three kinds of treatments, namely treatment by SS, FS and DX. As for SS, it was IP administered in single dose level of 200 and 300 mg/kg, in addition to saline as a vehicle group. Regarding to FS, it was IP administered in single dose levels of 100 and 150 mg/kg, and 0.25 M NaHCO₃ as a vehicle group. Concerning DX, it was subcutaneously injected in single dose levels of 0.2 and 0.3 mg/kg, and 1% Tween 80, as a vehicle group.

The combined treatment groups, that are phase two groups, they included six groups as following: Two vehicle groups the first of which was administered by saline + 1% Tween 80, as a vehicle for SS+ DX, while the second one was administered 0.25 M NaHCO₃ + 1% Tween 80, as a vehicle group for FS+DX. The rest of the combined treatment groups were treated as following: Two groups were administered by SS and DX as following; 200 mg/kg of SS + 0.2 mg/kg or 0.3 mg/kg of DX. The other two groups were administered by FS and DX as following: 100 mg/kg of FS + 0.2 mg/kg or 0.3

mg/kg of DX. For Preyer's reflex (hearing test), it was performed after sixty minutes of administration in case of single and combined treatment of SS and DX. On the other hand, in case of single and combined administration of FS the test was performed after 90 minutes. In combined treatment of FX and DX, DX was administered 30 minutes after FS administration. In all Preyer's reflex test groups, animals were anesthetized with 50 mg/kg IP thiopental then sacrificed. For assay of $\text{Na}^+/\text{k}^+/\text{ATPase}$, cochlea of both ears were isolated, the right cochleas were frozen at -80°C , while the left cochlea was fixed in 10% neutral formalin for histopathological examination, outer hair cells and inner hair cells count.

2.4.1.2. Rats groups

The rat groups are divided into single treatment groups which were represented as phase one treatment, and combined treatment groups which were represented as phase two treatment.

The single treatment groups were distributed among 3 kinds of treatments; namely treatment by SS, FS and DX. Regarding to SS, it was IP injected in single dose levels 150 mg/kg, 250 mg/kg, 400 mg/kg, 550 mg/kg and 700 mg/kg, in addition to saline as a vehicle group. As for FS, it was administered IP single dose levels of 100 mg/kg, 200 mg/kg, 250 mg/kg, 300 mg/kg, 400 mg/kg, and 0.25 M of NaHCO_3 as the vehicle group. Concerning DX, it was injected as subcutaneous single dose levels 30 mg/kg, 90 mg/kg, 150 mg/kg, 200 mg/kg, and 1% Tween 80 as a vehicle group.

The combined treatment, that's phase two groups, included six groups. Two vehicle groups as mentioned before in guinea pig groups.

The rest of combined treatment groups were treated as following: Two groups were administered by SS and DX as following 150 mg/kg of SS + 30 mg/kg or 90 mg/kg of DX. The two other groups were administered by FS and DX as following 100 mg/kg of FS+30 mg/kg or 90 mg/kg of DX.

For Preyer's reflex (hearing test), the administration sequence of the signal and combined treatments was similar to that followed in the experiment groups as previously mentioned before.

2.5. Estimation of hearing by Preyer's reflex test

This test was performed as a modification of the original procedure of Jero *et al.*, 2001¹¹. The full details are available in the supplementary file.

2.6. Estimation of $\text{Na}^+/\text{k}^+/\text{ATPase}$ activity

By using $\text{Na}^+/\text{K}^+/\text{ATPase}$ Microplate Assay Kit purchased from My Biosource Company catalog number MBS8243226.

2.7. Histopathological method

The cochlea was extracted and decalcified according to (Bassily, 1989)¹². On the other hand the preparation for histopathological examination was done according to (Bancroft *et al.*, 1996)¹³ and (Bancroft *et al.*, 2008)¹⁴. The complete information as stated in the supplementary file. The histopathological examination is followed by OHCs and IHCs count.

2.8. Outer hair cells and inner hair cells count

After staining of cochlea, OHCs and IHCs were counted by using Image pro plus version 5 for image analysis.

2.9. Statistical analysis

The Kruskal-Wallis test and the Mann-Witney U test were used to examine the data. A fixed significance level of $p \leq 0.05$ was applied. The SPSS 20 software was used for all statistical operations. Version 5 of GraphPad Prism (ISI®, USA) software was used for all statistical analyses.

3. RESULTS

3.1. Single treatments

3.1.1. Effect of sodium salicylate, furosemide and digoxin on Preyer's reflex test in male rats

Figure (1A) presents the effect of different doses of SS on Preyer's reflex test, it shows that high dose levels of SS (400, 550 and 700) mg/kg significantly increased Preyer's reflex score by 48%, 67% and 100% respectively as compared to the saline group. In addition, figure (1B) shows that FS dose levels that significantly decreased Preyer's reflex score by 100%, as compared to control group, are 250, 300 and 400 mg/kg. As for, figure (1C) it displayed that the only dose of DX that significantly increases Preyer's reflex score is 200 mg/kg by 67% as compared to the Tween80 group.

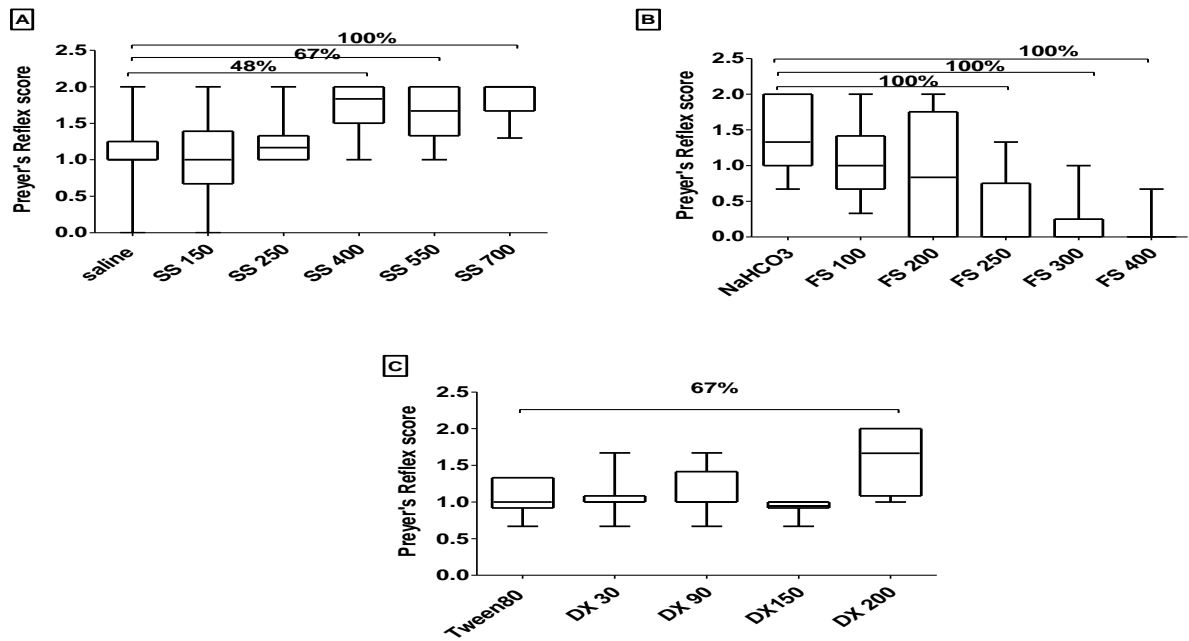


Figure 1. Effect of sodium salicylate, furosemide and digoxin on Preyer’s reflex test in male rat.

SS, sodium salicylate; FS, furosemide; DX, digoxin. Data are expressed as median ± range. Statistical analysis was carried out using Kruskal-Wallis followed by Mann-Whitney U test

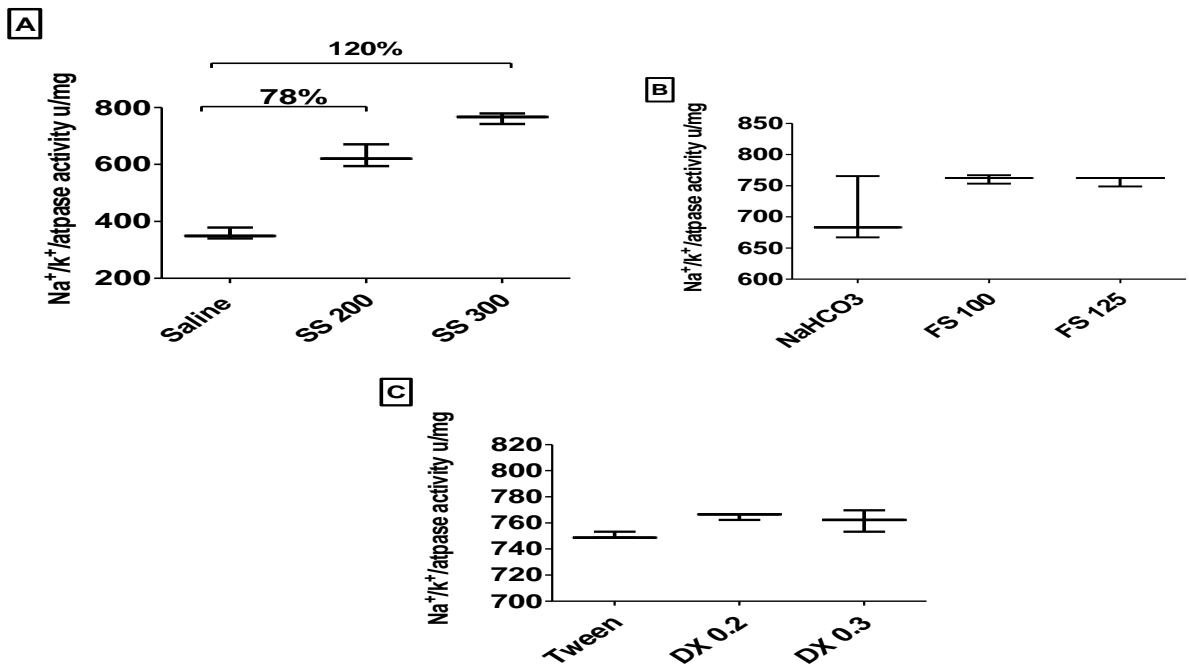


Figure 2. Effect of sodium salicylate, furosemide and digoxin on Na⁺/k⁺/atpase activity in cochlea of guinea pigs’ inner ears.

SS, sodium salicylate; FS, furosemide; DX, digoxin, Data are expressed as median ± range. Statistical analysis was carried out using Kruskal-Wallis followed by Mann-Whitney U test

3.1.2. Effect of sodium salicylate, furosemide and digoxin on Preyer's reflex test in guinea pigs

According to the results obtained from Preyer's reflex test, the given dose levels of SS (200 mg/kg and 300 mg/kg) and DX (0.2 mg/kg and 0.3 mg/kg) displayed negative results. On the other hand, dose levels of (100 mg/kg and 125 mg/kg) of FS resulted in only one positive response.

3.1.3. Effect of sodium salicylate, furosemide and digoxin on $\text{Na}^+/\text{k}^+/\text{ATPase}$ activity in cochlea of guinea pigs' inner ear

The data epitomized in figure (2A) presented that SS 200 mg/kg significantly increased $\text{Na}^+/\text{k}^+/\text{ATPase}$ activity by 78% as compared to saline group. Similarly SS 300 mg/kg significantly increased $\text{Na}^+/\text{k}^+/\text{ATPase}$ activity by 120 % as compared to saline group.

3.1.4. Effect of sodium salicylate, furosemide and digoxin on outer hair cell count of guinea pigs' ear

Statistical analysis represented in figure (3 B) showed that FS in dose of 125 mg/kg significantly decreased OHC count by 27% as compared to control group.

and (C) cells, while the tectorial membrane appeared atrophied, thin, degenerated and redundant.

3.1.5. - For DX treated groups, the organ of Corti showed widely spaced vacuolar OHCs and IHCs, with pyknotic or absent nuclei in about 30% of the

Effect of sodium salicylate, furosemide and digoxin on inner hair cell count of guinea pigs' ear

The results showed in figure (4B) indicated that FS in dose of 100 mg/kg and 125 mg/kg, significantly decreased IHC count of left ear by 33%, 39%, respectively, as compared to the control.

In addition, the results shown in figure (4C) showed that DX in dose of 0.2 mg/kg and 0.3 mg/kg significantly decreased IHC count of left ear by 34% and 51%, respectively, as compared to Tween80 group.

3.1.6. Histopathological examination of sodium salicylate, furosemide and digoxin groups

- As illustrated in figure (5) groups of animals treated by vehicle control saline, 0.25 M sodium bicarbonate

and 1% Tween80, showed normal histological architecture.

-For the groups administered SS as single dose levels, the number of OHCs were within normal but widely spaced in case of treatment by 200 mg/kg. In addition, the supporting cells, Hensen cells (H) and Claudius cells (C), were seen normally in the animals treated by SS 200 mg/kg. On the other hand, animals treated by 300 mg/kg of SS showed an increase in the number of (C) cells only. Cells of spiral ganglia were seen widely separated with large nuclei, where the cytoplasm possessed a smaller number of Nissl' s granule in case of group given 200 mg/kg SS, while in the group administered 300 mg/kg of SS the cytoplasm is studded with Nissl' s granules.

-For animals treated by 100 mg/kg FS the organ of Corti showed widely spaced vacuolar degeneration of OHCs and IHCs with a decrease in number.

Normal inner and outer pillar cells were observed. Cells of spiral ganglia were seen degenerated with decreased number, vacuolar degeneration in the nuclei and the cytoplasm were empty with small number of Nissl' s granules .On the other hand, the organ of Corti in group given 125 mg/kg of FS showed severely vacuolar degeneration in OHCs and IHCs with reduction in number of cells. Outer and inner pillar cells showed mildly vacuolar degeneration .Cells of spiral ganglia were seen severely degenerated or absent in many occasions, with atrophied degenerated nuclei and pale cytoplasm. Furthermore, both doses showed vacuolar degeneration in supporting, cells (H) cells examined specimens and a decrease in only number in case of treatment by DX 0.3 mg/kg .Furthermore, the two doses of DX (0.2 and 0.3 mg/kg) showed degeneration of outer and inner pillar cells outlining the tunnel of Corti while absent in about 30 % of the examined specimens. In regard to supporting cells (H) and (C) cells, degeneration were observed but pyknotic nuclei in all sections were seen in DX 0.3 mg/kg only .The tectorial membrane appeared heterogeneous in structure hanging over the hair cell in both doses but the membrane was irregular and ruptured in some areas in case of DX 0.3 mg/kg only. Additionally, Cells of spiral ganglia in the group treated by 0.2 mg/kg showed small pale nuclei and pale cytoplasm with disappearance of Nissl' s granules, where the group given 0.3 mg/kg showed a decrease in the number of spiral ganglia, thus illustrating severe degeneration with widely spaced, small pale nuclei and degenerated pale cytoplasm with absent of Nissl' s granules.

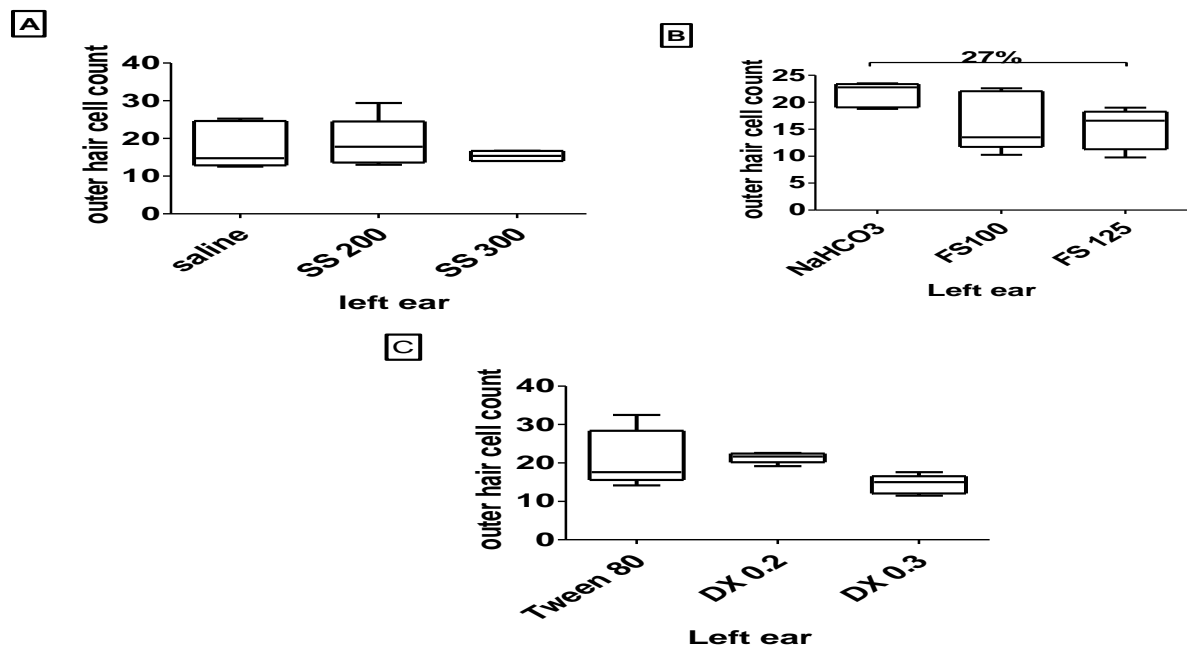


Figure 3. Effect of sodium salicylate, furosemide and digoxin on outer hair cell count of guinea pigs' ear. SS, sodium salicylate; FS, furosemide; DX, digoxin, Data are expressed as median \pm range. Statistical analysis was carried out using Kruskal-Wallis followed by Mann-Whitney U test

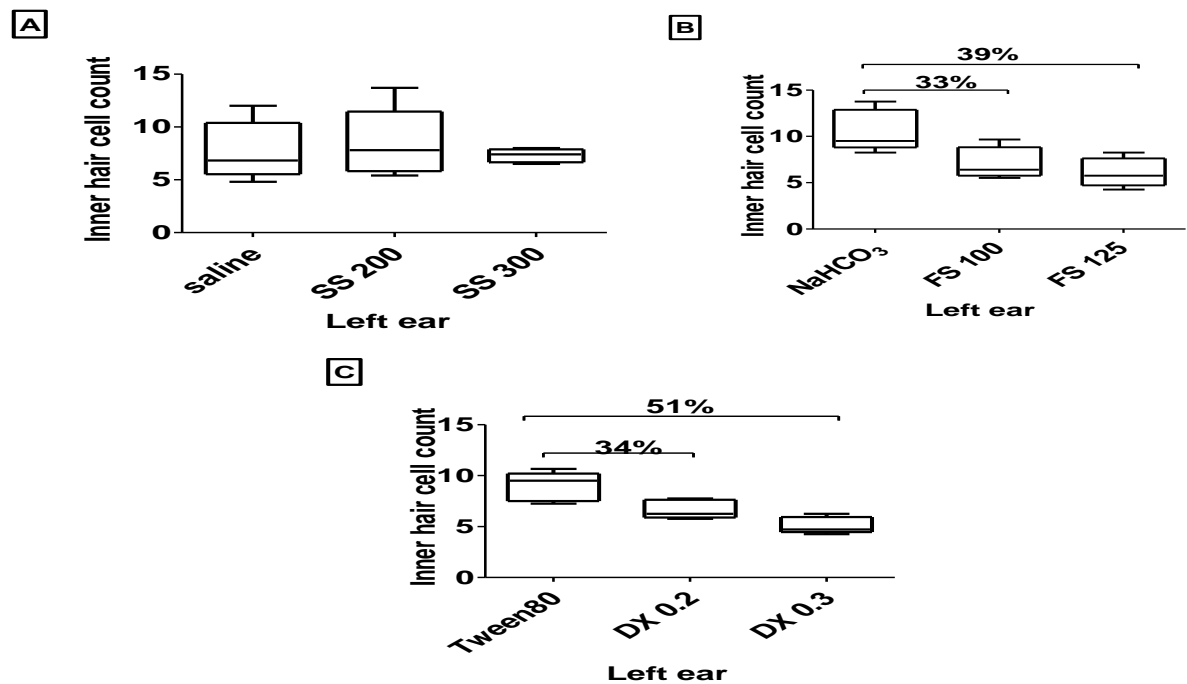


Figure 4. Effect of sodium salicylate, furosemide and digoxin on inner hair cell count of guinea pigs' ear. SS, sodium salicylate; FS, furosemide; DX, digoxin, Data are expressed as median \pm range. Statistical analysis was carried out using Kruskal-Wallis followed by Mann-Whitney U test

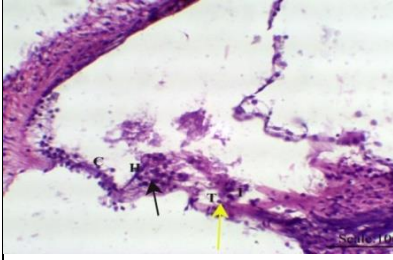
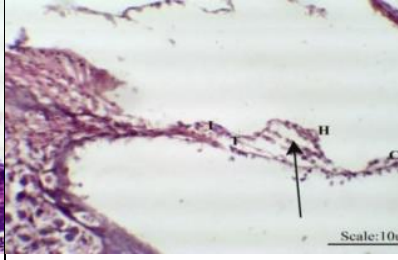
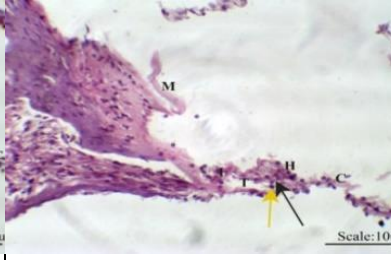
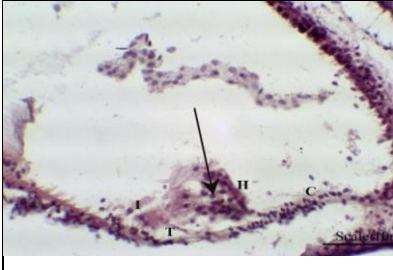

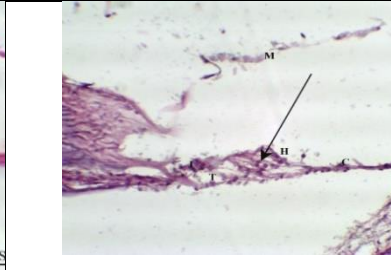
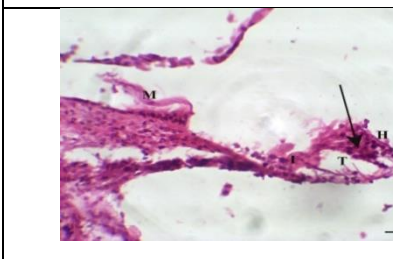
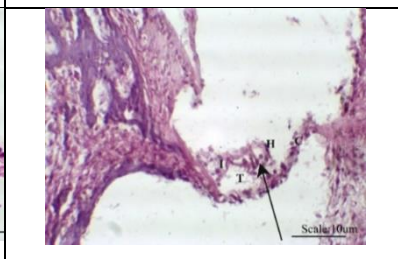
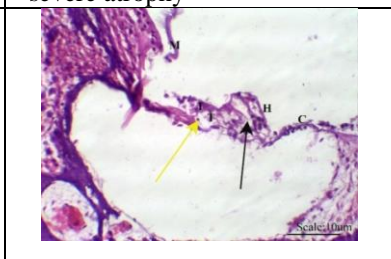
		
<p>Saline group Saline group showed normal histological architecture</p>	<p>SS 200 mg/kg This group showed widely spaced OHCs</p>	<p>SS 300 mg/kg The group showed increase number of C cells and the cytoplasm is studded with Nissl's granules</p>
		
<p>NaHCO₃ group NaHCO₃ group showed normal histological features</p>	<p>FS 100 mg/kg The group showed vacuolar degeneration of OHCs, (H) cells and (C) cells and IHCs. OHC count was decreased</p>	<p>FS 125 mg/kg Such group showed severe vacuolar degeneration in OHCs, and IHCs, (H) cells and (C) cells with decreased number in OHCs and IHCs. (M) membrane showed severe atrophy</p>
		
<p>Tween 80 group Tween group showed normal histological features</p>	<p>DX 0.2 mg/kg This group showed widely spaced and vacuolar degeneration of OHCs, IHCs. The (M) membrane was heterogeneous in structure</p>	<p>DX 0.3 mg/k DX in dose 0.3 mg/kg showed widely spaced vacuolar degeneration of OHC and IHC, with decreased in number of cells, (C) and (H) cells. The (M) membrane was heterogeneous in structure, irregular and ruptured in some areas.</p>

Figure 5. Histopathological examination of sodium salicylate, furosemide and digoxin groups.

DX, digoxin; SS, sodium salicylate; FS, furosemide; OHC, outer hair cell; IHC, inner hair cell, Outer hair cells (black arrow), inner hair cells (I), Hensen cells (H), cells of Claudius (C), tunnel of corti (T), pillar cells (yellow arrow), Tectorial membrane (M).

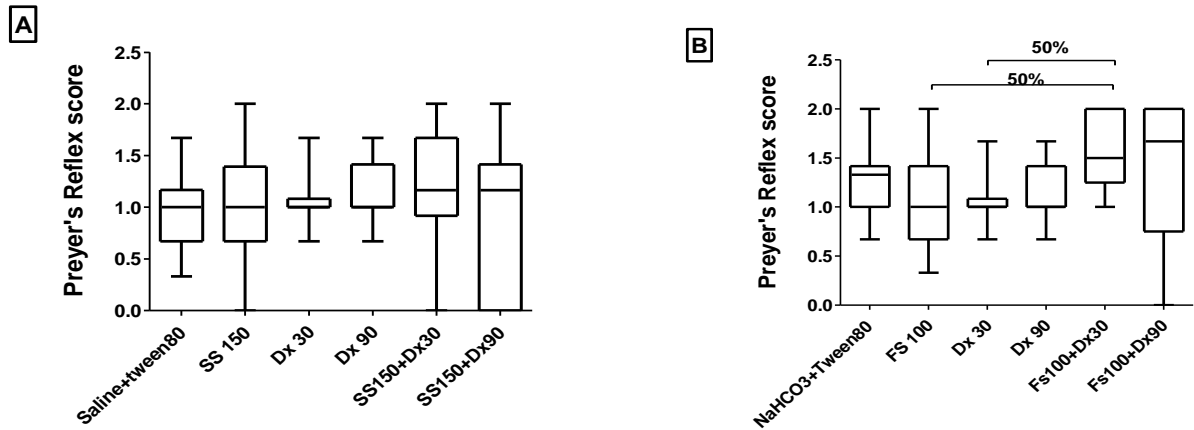


Figure 6. Effect of combined treatments of either sodium salicylate or furosemide with digoxin on Preyer's reflex.

SS, sodium salicylate; FS, furosemide; DX, digoxin Data are expressed as median ± range. Statistical analysis was carried out using Kruskal-Wallis followed by Mann-Whitney U test

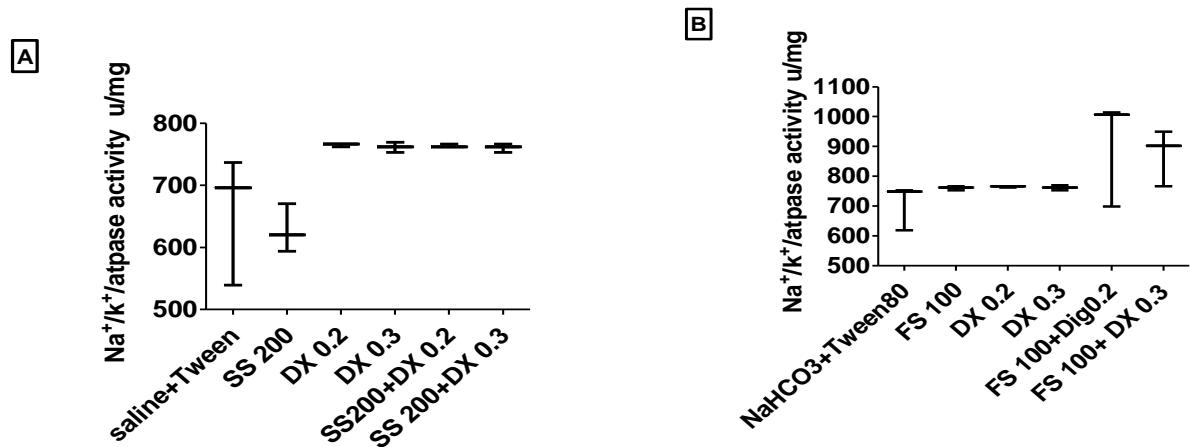


Figure 7. Effect of combined treatment of either sodium salicylate or furosemide with digoxin on Na⁺/K⁺ ATPase activity in cochlea of guinea pigs' inner ears.

SS, sodium salicylate; FS, furosemide; DX, digoxin. Data are expressed as median ± range. Statistical analysis was carried out using Kruskal-Wallis followed by Mann-Whitney U test

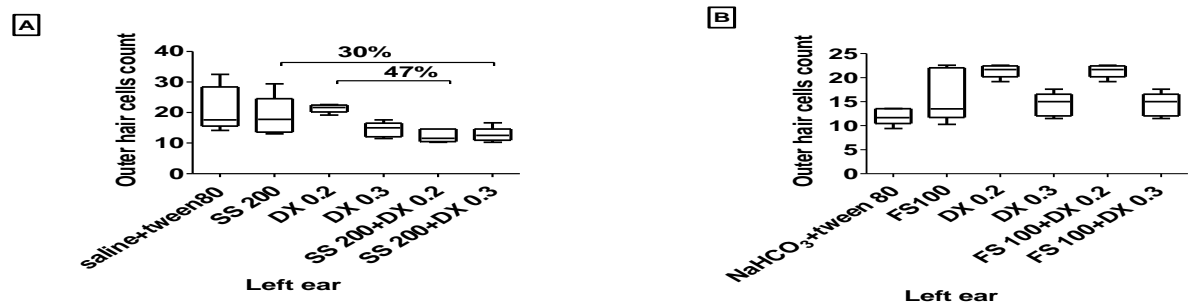


Figure 8. Effect of combined treatment of either sodium salicylate or furosemide with digoxin on outer hair cell count in guinea pigs' left ear.

SS, sodium salicylate; FS, furosemide; DX, digoxin, Data are expressed as median ± range. Statistical analysis was carried out using Kruskal-Wallis followed by Mann-Whitney U test

3.2. Combined treatments

3.2.1. *Effect of combined treatments of either sodium salicylate or furosemide with digoxin on Preyer's reflex in rats*

Figure (6B) showed that combined treatment (FS100 mg/kg + DX 30 mg/kg) significantly increased Preyer's reflex score by 50 %, as compared to groups treated by 100 mg/kg of FS or 30 mg/kg of DX.

3.2.2. *Effect of combined treatments of either sodium salicylate or furosemide with digoxin on Preyer's reflex test in guinea pigs*

The obtained results indicated that combined treatments (SS 200 mg/kg + DX 0.2 mg/kg) and (SS 200 mg/kg +DX 0.3 mg/kg) had no positive reflex. On the other hand, combined treatments (FS 100 mg/kg + DX 0.2 mg/kg) and (FS 100 mg/kg + DX 0.3 mg/kg) displayed only one positive reflex in each group.

3.2.3. *Effect of combined treatment of either sodium salicylate or furosemide with digoxin on Na⁺/k⁺/ATPase activity in cochlea of guinea pigs' inner ears*

According to the effect of combined treatment of either SS or FS with DX on Na⁺/k⁺/ATPase activity, illustrated in figure (7) in cochlea of guinea pigs' inner ears, the data showed no significant change.

3.2.4. *Effect of combined treatment of either sodium salicylate or furosemide with digoxin on outer hair cell count in the guinea pigs' left ear*

The data represented in figure (8A) showed that combined treatments (SS 200 mg/kg + DX 0.2 mg/kg) and (SS150 mg/kg+ DX 0.3 mg/kg) significantly decreased OHC of left ear by 47% and 30 % as compared to treatment by 0.2 mg/kg of DX and 200 mg/kg of SS respectively.

3.2.5. *Effect of combined treatment of either sodium salicylate or furosemide with digoxin on inner hair cell count in guinea pigs' left ear*

As shown in figure (9A) the combined treatments (SS 200 mg/kg + DX 0.3 mg/kg) resulted in significant increase of IHC count by 40% as compared to group treated by 0.3 mg/kg of DX.

3.2.6. *Histopathological examination of combined treatment of either sodium salicylate or furosemide and digoxin*

-The vehicles treated groups showed normal structure.

-For combined treatment of SS and 0.2 mg/kg of DX, the organ of Corti was showing widely spaced OHCs and IHCs, with acidophilic slight vacuolar cytoplasm and basophilic nuclei with rare pyknotic nuclei . Outer and inner pillar cells outlining the tunnel of Corti showed normal features .Supporting cells, (H) and (C) cells, was slightly atrophied. The tectorial membrane was seen homogenous in structure and hanging over the hair cells. Cells of spiral ganglia were noticed slightly spaced, decreased in number, with atrophy in about 20% of the examined specimens.

The combined group treated by SS and 0.3 mg/kg showed vacuolar degeneration and rarely pyknotic nuclei of organ of Corti of OHCs and IHCs. Additionally, outer and inner pillar cells were absent in many sections. Supporting cell, (H) and (C) cells showed degeneration while tectorial membrane was heterogeneous and irregular in structure. As well, cells of spiral ganglia were seen having small and /or irregular pale nuclei and pale cytoplasm in many specimens.

-For combined treatment of FS and DX, the organ of Corti rarely showed vacuolar degeneration in OHCs and IHCs following administration of FS and 0.2 mg/kg DX where it was associated with pyknotic nuclei. The severity of degeneration was increase in the group given FS and 0.3 mg/kg DX. On the other hand, Outer and inner pillar cells outlined the tunnel of Corti were absent in both groups .Additionally, degeneration of supporting cells was detected in low dose combined group and the severity of degeneration was increased in the high dose combined group. As well, the tectorial membrane was heterogeneous in structure and irregular in both groups.

The discontinuation of the membrane was only seen in group treated by FS and 0.3 mg/kg DX. In addition, cells of spiral ganglia possessed small and/or irregular pale nuclei and pale cytoplasm following administration of both dose,where, small pyknotic nuclei was only seen in the group treated by FS and 0.3 mg/kg of DX.

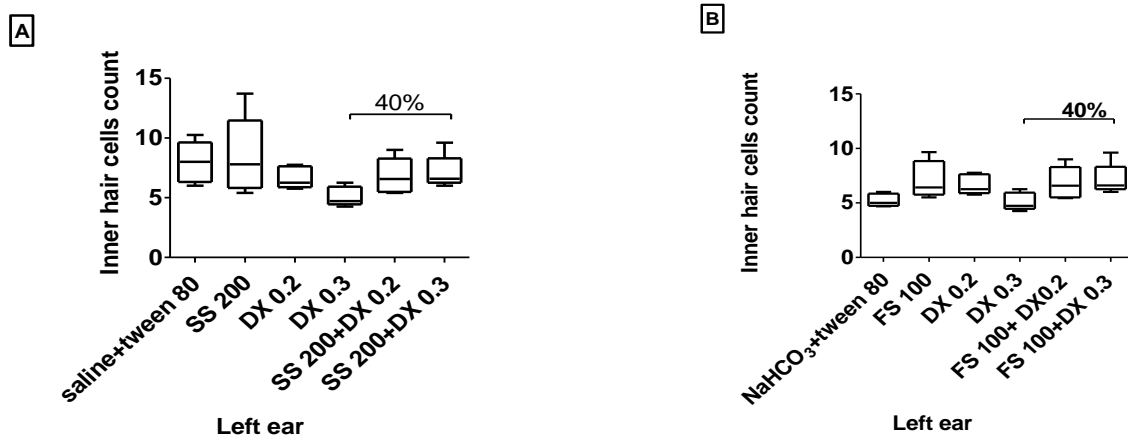


Figure 9. Effect of combined treatment of either sodium salicylate or furosemide with digoxin on inner hair cell count in guinea pigs' left ear

SS: sodium salicylate, FS: furosemide, DX: digoxin. Data are expressed as median ± range. Statistical analysis was carried out using Kruskal-Wallis followed by Mann-Whitney U test

<p>Saline + tween 80 Control group showed normal features</p>	<p>SS 200 mg/kg+DX 0.2 mg The specimen showed widely spaced OHCs. (H) cells and (C) cells showed slightly atrophy</p>	<p>SS 200 mg/kg +DX 0.3 mg/kg The group showed vacuolar degeneration of OHCs and IHCs, (H) and (C) cells and (M) membrane was heterogenous and irregular in structure</p>
<p>NaHCO₃ + tween 80 Showed normal histopathological structure</p>	<p>FS 100 mg/kg + DX 0.2 mg/kg Vacuolar degeneration of OHCs, (H) and (C) cells. (M) membrane appeared irregular and heterogeneous in structure</p>	<p>FS 100 mg/kg + DX 0.3 mg/kg The group showed severes vacuolar degeneration of OHC, IHC, (H) cell and (C) cells. (M) Membrane appeared heterogeneous, thin and discontinued in many areas</p>

Figure 10. Histopathological examination of combined group of either sodium salicylate or furosemide and digoxin.

FS, furosemide; DX, digoxin; SS, sodium salicylate; OHC, outer hair cell; IHC, inner hair cell, Outer hair cells (black arrow), Hensen cells (H), cells of Claudius (C), tunnel of corti (T), pillar cells (yellow arrow), Tectorial membrane(M).

4. DISCUSSION

The primary application of the Preyer's reflex has been to identify deaf or sound-responsive animals. In actuality, it was among the first techniques to evaluate guinea pigs' hearing. It has since been extensively employed in research on hearing in a variety of different animal species¹¹.

In the current study, 200 mg/kg of DX significantly increased preyer's reflex score, the finding which contradicts with Lee *et al.* (2016)¹⁵ where female Mongolian gerbils treated locally with 1 mM ouabain, by application on the round window, showed increased ABR threshold after seven days.

This increase may be due to loss of auditory function that resulted from SGN injury and a reduction in the density of synaptic puncta. Also, our finding is in contradiction with Li *et al.* (2018)¹⁶ who reported that the application of 2 mM of ouabain to the round window of the C57BL/6 male mouse cochlea shows a two week latent increase in the ABR threshold.

Such effect may be due to the loss of type I of SGN. On the other hand, the increase in preyer's reflex score in the present work despite of the decreased number of IHC, as will be pointed later on, may be due to as a result of many neuroplastic alterations in the central auditory pathway, that may be triggered to compensate for the reduced neural output from the damaged cochlea¹⁷.

Thus as Salvi *et al.* (2017)¹⁷ mentioned, The reason mild to moderate IHC and/or SGN loss has so little effect on auditory thresholds and, in some situations, increased auditory perception could be that an increase in the amplitude of a weak signal would facilitate the auditory cortex's ability to identify sounds.

According to the obtained results, the three administered dose levels of 400, 550 and 700 mg/kg of SS significantly increased the score of Preyer's reflex in rats, the finding which contradicts with that of Zhang *et al.* (2020)¹⁸ who found that adult male Wistar rats, injected intraperitoneally, with 200 mg/kg SS once daily for 10 days, showed signs of tinnitus. Such effect as suggested by the author¹⁸ may be due to the ability of high doses of SS in both patients and animals, to induce reversible tinnitus via raising hyper-excitability in areas along the central auditory pathway and lowering cochlear output¹⁸.

On the other hand, our results are consistent with Sun *et al.* (2009)¹⁹ who showed that adult male Sprague–

Dawley rats injected intraperitoneally by 250 mg/kg of SS enhanced the amplitude of the startle response. This might be the result of amplified auditory evoked potential observed in cochlear hearing loss brought on by SS²⁰. Furthermore, the exaggerated startle responses could possibly correlate with collapsed sound tolerance or hyperacusis. Hyperacusis is an unusually high response to loud noises²¹. It is frequently observed in people who have tinnitus and sensorineural hearing loss.

Consistently with this view, bilateral auditory cortex lesions were found to temporarily enhance the magnitude of the startle reflex response elicited by high-intensity sounds, supporting this theory and demonstrating the auditory cortex's ability to modify brainstem circuits regulating the startle response²². However, the combined treated group of each of DX dose levels with SS didn't result in significant change.

In the current study, FS in dose levels 250, 300 and 400 mg/kg significantly decreased preyer's reflex score. These results are consistent with Li *et al.* (2011)²³ who reported an increase in the ABR test threshold, in CBA/CAJ mice injected intraperitoneally with FS in dose of 200 and 400 mg/kg.

Besides, the present results are consistent with that of Pienkowski and Ulfendahl, (2011)²⁴ who reported that pigmented adult guinea pigs showed decreased ABR amplitudes at high SPLs (70 dB SPL) after intravenous injection of 100 mg/kg FS. This may be the result of edema of the stria vascularis brought on by FS, which impairs the blood–ear barrier and lowers endocochlear potential²⁵.

In the current study, combined treatment group of FS (100 mg/kg) and DX (0.2 mg/kg) significantly increased preyer's reflex score as compared to single treatment of either FS or DX groups. Such effect may be due to DX as previously pointed, where a series of neuroplastic alterations in the central auditory system might be triggered in order to compensate for the reduced neural output from the damaged cochlea.

The reason mild to moderate IHC and/or SGN loss has so little effect on auditory thresholds and in some cases enhanced auditory perception could be that an increase in the magnitude of a weak signal would make it simpler for the auditory cortex to detect sounds as explained by Salvi *et al.* (2017)¹⁷.

The preyer's reflex finding is supported by a decrease in IHC number, which is cleared in histopathological examination even though the decrease isn't significant¹⁷.

Na⁺/K⁺/ATPase is a crucial ion channel that uses ATP to pump K⁺ ions into cells and Na⁺ ions out of them. The endocochlear potential and the high potassium concentration of endolymph, which are critical for inner ear sensory function, are derived from adequate Na⁺/K⁺/ATPase^{26,27}.

In the present study, the obtained results showed that two dose levels of SS significantly increase Na⁺/K⁺/ATPase activity. However, to our knowledge, no previous research work did reported the effect of SS on Na⁺/K⁺/ATPase in the cochlea. On the other hand, Modi & Merchant, (2003)²⁸ reported significant increase of Na⁺/K⁺/ATPase activity in

Erythrocytes. Such increase may be due to the ability of the cells to counteract the ion loss that is induced due to SS. Also, salicylates act through adrenal cortex where they possess direct corticosteroids-like effects on tissues²⁹. Increased blood levels of glucocorticoids correspond with increased Na⁺/K⁺/ATPase in the lateral wall, suggesting that glucocorticoids regulate the activity of Na⁺/K⁺/ATPase. Glucocorticoids have a direct influence on Na⁺/K⁺/ATPase expression²⁶. However, in the present work combined treatment of each of SS and FS with DX didn't have significant change.

The inner and outer hair cell types in the mammalian cochlea each have different roles. The electrical impulses of IHCs are virtually mainly responsible for transmitting the acoustic waves to the auditory nerve fibers, while OHCs primarily function to increase the stimulation by physically amplifying the vibrations of the cochlear partition caused by sound³⁰.

According to our results, DX in the dose levels of 0.2 and 0.3 mg/kg significantly decrease the number of IHC. This effect seems to contradict with Qu *et al.* (2012)³¹ who reported no significant damage in the IHCs and OHCs of the cochleae in male Mongolian gerbils treated locally with ouabain 1 mmol/L as applied in the round window membrane. Such effect is consistence with that reported by Fu *et al.* (2012)³² where OHC and IHC were extensively lost over a

large portion of the cochlea in the inner ears of female SASCO Sprague Dawley rats treated with 10 mM ouabain administered to the round window membrane, with the exception of the most apical regions.

According to Fu *et al.* (2013)³³ the reduction in IHCs might be the result of ouabain-induced death in cochlear hair cells and SGNs, which are particularly associated with (or distinguished by) apoptosis. Cochlear HCs undergo dose- and time-dependent degeneration when exposed to ouabain, and the damage they sustain follows a typical pattern that starts at the base of the cochlea and moves up toward the apex. Remarkably, compared to OHCs, IHCs were more vulnerable to ouabain toxicity³³. According to our findings, such effect is consistent with histopathological examination that showed that the organ of Corti contained widely spaced vacuolar OHCs and IHCs where some showed pyknotic nuclei with decrease in number of cells in case of guinea pigs treated with 0.3 mg of DX.

In the present study, combined treatment of (SS 200 mg/kg) with either 0.2 or 0.3 mg/kg of DX significantly decrease OHC count as compared to single treatment. This effect may, according to Feng *et al.*, 2010³⁴, be interpreted that the administration of both SS and Ouabain (as a cardiac glycoside) can activate caspase-3 pathway, thus leading to degeneration of cochlear OHCs and SGNs in a dose and time dependent manner, resulting in the dose- and time-dependent degeneration of cochlear OHCs and SGNs, although the damage to SGNs happened sooner and was more severe than that to cochlear hair cells^{33, 34}. Such effect is histopathologically illustrated in the present work where OHCs in combined treatment groups (SS plus DX) showed slightly separated vacuolar cytoplasm and rarely pyknotic nuclei with decreased number.

On the other hand, the combined treatment group of SS (200 mg/kg) and DX (0.3 mg/kg) showed significant increase in IHC count as compared to DX (0.3 mg/kg). Such increase may be due to the SS induced an increase in arachidonic acid levels³⁵. This increase may enable the activation of N-methyl-D-aspartate receptors (NMDAR) at the IHC ribbons, while, microscopy images reveal a normal morphological structure, which may induce abnormal spontaneous activity of auditory nerve fibers, thus possibly leading to the induction of tinnitus³⁵. Such effect isn't demonstrated in OHCs, probably because the action of salicylates at the OHCs does not involve NMDAR receptors³⁶. In the present study both dose levels 100 and 125 mg/kg of FS, significantly decrease OHC and IHC

number. This finding contradicts with that of Liu *et al.* (1996)³⁷ who reported no damage in hair cells of pigmented guinea pigs treated with 25 and 50 mg/kg, the matter which may be due to the difference in dose levels. In addition, our results contradict with Whitworth *et al.* (1999)³⁸ who reported that Adult Sprague-Dawley rats administered intraperitoneally with 100 mg/kg FS showed normal appearances for both IHCs and OHCs, and no hair cell loss was visible in the apical, middle, basal, or hook areas.

Thus, our finding may be interpreted that FS has direct interaction with the stereocilia, or cochlear sensory cells. However, there is strong evidence that a decrease in the endocochlear potential is the primary cause of other electrophysiological effects of FS, such as alterations in cochlear microphonics and auditory-nerve responses³⁹. Enzymes like adenylate cyclase and carbonic anhydrase, as well as glycolysis, are known to be blocked by FS. When taken in large quantities, it will inhibit the activity of Na⁺/K⁺/ATPase, resulting in low [K⁺] and high [Na⁺] concentrations in the scala media fluid. This will cause irreversible functional damage to the stereocilia⁴⁰.

Similar morphological alterations could also happen to other auxiliary structures, such the cupul. The previously pointed effect on stereocilia implicated in mechanoelectric transduction and in some hair bundles these are elongated or fractured⁴⁰. Our results are consistent with the histopathological examination that showed vacuolar degeneration of OHCs and IHCs with decreased in number in OHCs following administration of 100 mg/kg FS. In addition, FX in dose of 125 mg/kg causes severely vacuolar degeneration in OHCs and IHCs, with reduction in number of both cells. However, combined group of FS and each dose level of DX didn't possess significant change.

5. CONCLUSION

The present study declares the ototoxic potential of Digoxin in guinea pigs as indicated by decreasing the Inner Hair cells count as well as the accompanied histopathological changes. Each of Sodium Salicylate and Furosemide was shown to potentiate the ototoxic effect of Digoxin.

Funding: This research did not receive any specific grant from funding agencies in the public, commercial, or not-for-profit sectors.

Acknowledgments: Not applicable

Conflicts of Interest: None of the authors has conflicts of interest to declare.

Ethical Statement: The Ethics Committee of the Faculty of Pharmacy at Al-Azhar University in Egypt (permission number: 203/2019) governed all aspects of the techniques used on the animals. Animals were not subjected to undue stress or difficult maneuvers.

Author Contribution: M. Raouf Hamed and Hebatalla I. Ahmed shared developing the research idea, designed the experiments, supervised the experiments performance, executed data analysis, guided and revised the manuscript. Amira M. Elkhawaga performed the experiments, collected the data, carried out the graphical and statistical analysis and wrote the manuscript. Shirley R. Henry performed Histopathological part.

List of abbreviations

ANOVA, analysis of variance; SS, sodium salicylate; FS, furosemide; DX, digoxin; NaHCO₃, sodium bicarbonate; OHCs outer hair cells; IHCs, inner hair cells; IP, intra-peritoneal; SC, subcutaneous; (H), Hensen cells; (C), Claudius cells; (T), tunnel of corti; (M), Tectorial membrane; SGN, spiral ganglion neurons; NKCC2, sodium-potassium-chloride co-transporter; LD 50, median lethal dose; NODCAR, National Organization for Drug Control and Research; NMDAR, N-methyl-D-aspartate receptors; ATP, adenosine triphosphate; I.P, interaperotinal; ABR, auditory brainstem response; SPL, sound pressure level.

REFERENCES

1. Weinhouse E, Kaplanski J, Posner J. Comparison of digoxin-induced cardiac toxicity in resistant and sensitive species. *Journal of pharmacy and pharmacology*. 1983;35(9):580–3.
2. Menger L, Vacchelli E, Kepp O, Eggermont A, Tartour E, Zitvogel L, et al. Trial watch: Cardiac glycosides and cancer therapy. *Oncoimmunology*. 2013;2(2):e23082.
3. Lelievre LG, Lechat P. Mechanisms, manifestations, and management of digoxin toxicity. *Heart Metab*. 2007;35:9–11.

4. Kirilmaz B, Saygi S, Gungor H, Turk UO, Alioğlu E, Akyuz S, et al. Digoxin intoxication: An old enemy in modern era. *Journal of Geriatric Cardiology: JGC*. 2012;9(3):237.
5. Moatassim S, Touleimat S, Hazelzet T, Brasseur M, Diguët A, Durand I, et al. Maternal complications induced by digoxin treatment of fetal tachycardia: A retrospective series of 18 cases. *Journal of Gynecology Obstetrics and Human Reproduction*. 2018;47(2):35–8.
6. Sheppard A, Hayes S, Chen GD, Ralli M, Salvi R. Review of salicylate-induced hearing loss, neurotoxicity, tinnitus and neuropathophysiology. *Acta Otorhinolaryngologica Italica*. 2014;34(2):79.
7. Sheppard AM, Chen GD, Salvi R. Potassium ion channel openers, Maxipost and Retigabine, protect against peripheral salicylate ototoxicity in rats. *Hearing research*. 2015;327:1–8.
8. Stolzberg D, Salvi RJ, Allman BL. Salicylate toxicity model of tinnitus. *Frontiers in systems neuroscience*. 2012;6:28.
9. Lanvers-Kaminsky C, Zehnhoff-Dinnesen A, Parfitt R, Ciarimboli G. Drug-induced ototoxicity: mechanisms, pharmacogenetics, and protective strategies. *Clinical pharmacology & therapeutics*. 2017;101(4):491–500.
10. Cannizzaro E, Cannizzaro C, Plescia F, Martines F, Soleo L, Pira E, et al. Exposure to ototoxic agents and hearing loss: A review of current knowledge. *Hearing, Balance and Communication*. 2014;12(4):166–75.
11. Jero DEC Anil K Lalwani, Jussi. The use of Preyer's reflex in evaluation of hearing in mice. *Acta oto-laryngologica*. 2001;121(5):585–9.
12. Bassily NS, 1989. The effect of various antibiotics on the pathology of the auditory system in experimental animals, 1989. PHD faculty of medicine Zagazig university.
13. Bancroft JD, Stevens A, Turner DR. (1996): *Theory and practice of histological techniques*, (ed. London, UK: Churchill Livingstone).
14. Bancroft JD, Gamble M, editors. *Theory and practice of histological techniques*. Elsevier health sciences; 2008.
15. Lee MY, Bae SH, Chang SY, Lee JH, Kim SH, Ahn JC, et al. Photobiomodulation by laser therapy rescued auditory neuropathy induced by ouabain. *Neuroscience Letters*. 2016;633:165–73.
16. Li J, Chen Y, Zeng S, Lai C, Zhang Y, Zhang L, Shi Y, Zhang T, Li H, Dai P. Contralateral suppression of DPOAEs in mice after ouabain treatment. *Neural plasticity*. 2018 Oct;2018.
17. Salvi R, Sun W, Ding D, Chen GD, Lobarinas E, Wang J, et al. Inner hair cell loss disrupts hearing and cochlear function leading to sensory deprivation and enhanced central auditory gain. *Frontiers in neuroscience*. 2017;10:621.
18. Zhang W, Zhe P, Shukui Y, Qing-Ling S, Teng-Fei Q, Ke L, et al. Exposure to sodium salicylate disrupts VGLUT3 expression in cochlear inner hair cells and contributes to tinnitus. *Physiological Research*. 2020;69(1):181.
19. Sun W, Lu J, Stolzberg D, Gray L, Deng A, Lobarinas E, et al. Salicylate increases the gain of the central auditory system. *Neuroscience*. 2009;159(1):325–34.
20. Lu J, Lobarinas E, Deng A, Goodey R, Stolzberg D, Salvi RJ, et al. GABAergic neural activity involved in salicylate-induced auditory cortex gain enhancement. *Neuroscience*. 2011;189:187–98.
21. Anari M, Axelsson A, Eliasson A, Magnusson L. Hypersensitivity to sound: questionnaire data, audiometry and classification. *Scandinavian audiology*. 1999;28(4):219–30.
22. Hunter KP, Willott JF. Effects of bilateral lesions of auditory cortex in mice on the acoustic startle response. *Physiology & behavior*. 1993;54(6):1133–9.
23. Li Y, Ding D, Jiang H, Fu Y, Salvi R. Co-administration of cisplatin and furosemide causes rapid and massive loss of cochlear hair cells in

- mice. *Neurotoxicity research*. 2011 Nov;20:307-19.
24. Pienkowski M, Ulfendahl M. Differential Effects of Salicylate, Quinine, and Furosemide on Guinea Pig Inner and Outer Hair Cell Function Revealed by the Input–Output Relation of the Auditory Brainstem Response. *Journal of the American Academy of Audiology*. 2011;22(02):104–12.
25. Ding D, Jiang H, McFadden SL, Salvi R. Ethacrynic acid is the key for opening of the blood-labyrinth barrier. *Chin J Otol*. 2004;2(1):42–7.
26. Peeleman N, Verdoodt D, Ponsaerts P, Van Rompaey V. On the role of fibrocytes and the extracellular matrix in the physiology and pathophysiology of the spiral ligament. *Frontiers in Neurology*. 2020;11:580639.
27. Ciuman R. Stria vascularis and vestibular dark cells: characterisation of main structures responsible for inner-ear homeostasis, and their pathophysiological relations. *The Journal of Laryngology & Otology*. 2009;123(2):151–62.
28. Modi D, Merchant M. In vitro effects of aspirin and salicylate on erythrocytes: size and Na⁺/K⁺ ATPase activity. *Indian J Pharmacol*. 2003;35:27–31.
29. Smith M. Salicylates and the adrenal cortex. *Annals of the Rheumatic Diseases*. 1959;18(4):298.
30. Fettiplace R. Hair cell transduction, tuning, and synaptic transmission in the mammalian cochlea. *Comprehensive Physiology*. 2011;7(4):1197–227.
31. Qu J, Gan Y na, Xie K liang, Liu W bo, Wang Y fei, Hei R yi, et al. Inhalation of hydrogen gas attenuates ouabain-induced auditory neuropathy in gerbils. *Acta Pharmacologica Sinica*. 2012;33(4):445–51.
32. Fu Y, Ding D, Jiang H, Salvi R. Ouabain-induced cochlear degeneration in rat. *Neurotoxicity research*. 2012;22:158–69.
33. Fu Y, Ding D, Wei L, Jiang H, Salvi R. Ouabain-induced apoptosis in cochlear hair cells and spiral ganglion neurons in vitro. *BioMed research international*. 2013;2013.
34. Feng H, Yin SH, Tang AZ, Cai HW, Chen P, Tan SH, et al. Caspase-3 activation in the guinea pig cochlea exposed to salicylate. *Neuroscience letters*. 2010;479(1):34–9.
35. Cui W, Wang H, Cheng Y, Ma X, Lei Y, Ruan X, et al. Long-term treatment with salicylate enables NMDA receptors and impairs AMPA receptors in C57BL/6J mice inner hair cell ribbon synapse. *Molecular Medicine Reports*. 2019;19(1):51–8.
36. Ruel J, Chabbert C, Nouvian R, Bendris R, Eybalin M, Leger CL, et al. Salicylate enables cochlear arachidonic-acid-sensitive NMDA receptor responses. *Journal of Neuroscience*. 2008;28(29):7313–23.
37. Liu J, Zhou X, Yuan Y. Effects of furosemide on intracochlear oxygen tension in the guinea pig. *European archives of oto-rhino-laryngology*. 1996;253:367–70.
38. Whitworth CA, Hudson TE, Rybak LP. The effect of combined administration of cadmium and furosemide on auditory function in the rat. *Hearing research*. 1999;129(1–2):61–70.
39. Ruggero MA, Rich NC. Furosemide alters organ of corti mechanics: evidence for feedback of outer hair cells upon the basilar membrane. *Journal of Neuroscience*. 1991 Apr 1;11(4):1057-67.
40. Comis S, Osborne M, Jeffries D. Effect of furosemide upon morphology of hair bundles in guinea pig cochlear hair cells. *Acta otolaryngologica*. 1990;109(1–2):49–56.