

Corneal Endothelial Changes Following Refractive Lens Exchange

Mohamed Z. Eid, Sayed M. Elsayed, Mohamed A. Yousef

Department of Ophthalmology, Faculty of Medicine, Al-Azhar University, Cairo – Egypt

Corresponding Author: Mohamed A. Yousef; Mobile: 01004467987

E-mail: Mohamed Abdelbaset.967@g-mail.com

ABSTRACT

Background: clear lens extraction (CLE) by phacoemulsification and posterior chamber intraocular lens (PC IOL) implantation in a series of highly myopic and hyperopic eyes was effective and had an acceptable predictability and a low rate of complications especially on corneal endothelium.

Aim of the work: to study corneal endothelium changes (number and morphology) following phaco-aspiration in refractive lens exchange procedure (1 month and 6 months postoperatively)

Subjects and methods: a non-randomized prospective study was carried out from October 2018 to May 2019 on twenty five eyes of 14 subjects with age (38-48) years old with high myope > 8 D and high hyperopia > 6 D; these patients were not candidate for corneal refractive surgery or phakic IOL procedure. They were selected from outpatient Ophthalmology Clinics of Al-Azhar University Hospitals in Cairo. The patients were examined by specular microscopy before and after refractive lens exchange procedure (1 month and 6 months postoperatively)

Results: Log MAR BCVA improved from (0.47) preoperatively to (0.5904) at the end of the 6th month with P-value 0.35. Changes in endothelial cell count from (2.650) cells/mm² before surgery to (2.372) cells/mm² 1 month after surgery to (2.358) cells/mm² 6 months after surgery with P-value <0.001. Error of refraction improved from (-14.94) in myope and (7.98) in hyperope preoperatively to (-1.42) in both groups at the end of the 6th month after surgery with p-value <0.001.

Conclusion: CLE surgery by phaco-aspiration technique is less harmful to the corneal endothelium because it uses no phaco power.

Keywords: Refractive Lens Exchange, Corneal Endothelium.

INTRODUCTION

Ideal candidates for refractive surgery are people with healthy eyes who are not satisfied with wearing eye glasses or contact lenses (CL). So, the goal of any refractive surgery is to decrease dependence on eye glasses or CL⁽¹⁾. In lens based refractive surgery, refractive surgery is done either by altering the natural crystalline lens i.e. clear lens extraction (CLE)⁽²⁾, or by placing an intraocular lens inside the eye in front of patient's natural lens i.e. phakic IOLs (PIOLs)⁽³⁾. Clear lens replacement is a viable procedure for both myopia and hyperopia with possible intraocular correction of astigmatism using toric IOLs⁽⁴⁾. CLE is similar to phacoemulsification surgery, however less ultrasound power is needed⁽⁵⁾. Surgeons have often reported that the corneal endothelium experiences various kinds of surgical trauma during phacoemulsification and intraocular lens (IOL) implantation⁽⁶⁾. Specular microscopy is a non-invasive technique to access the structure and function of the corneal endothelium⁽⁷⁾.

AIM OF THE WORK

The aim of the work is to study corneal endothelial cell changes (number and morphology) following phaco-aspiration in refractive lens exchange procedure (1 month and 6 months postoperatively).

SUBJECTS AND METHODS

A non-randomized prospective study included 25 eyes of 14 subjects with high refractive errors that were not candidate for corneal refractive surgery or phakic IOL procedure at Al-Azhar University Hospitals at Cairo from October 2018 to May 2019.

They were examined by specular microscopy before and after (at 1 and 6 months). Clear lens extraction by phaco-aspiration technique was performed to study changes of corneal endothelium.

Ethical approval:

The study protocol was adhered to the tenets of the declaration of Helsinki and was approved by the ethical board of Al-Azhar University. All subjects had informed about the details and the risk of the procedure and signed an informed written consent.

Patient selection:

* Inclusion criteria

Age group: (38 –48) years old.

Myopic errors over 8 D, not candidate for corneal refractive surgery or phakic IOL procedure.

Hyperopia over 6 D, not candidate for corneal refractive surgery or phakic IOL procedure.

*Exclusion criteria:

Previous ocular disease or trauma affecting the corneal endothelium or with corneal scar.

Any form of clinically significant cataract.

Previous corneal or intraocular surgery.

Pre-existing macular degeneration or macular pathology.

Retinal holes or tears or subclinical retinal detachment.

Preoperative evaluation:

History taking:

Onset, course and duration of diminution of vision.

- History of ocular trauma, ocular surgery, systemic disorder and drug intake.

Preoperative ophthalmological examination:

- Uncorrected visual acuity (UCVA) were evaluated by landolt C optotype using Snellen`s chart which was translated into decimal resolution system.
- Pupil reaction.
- Refraction using automated refractometer.
- Best corrected visual acuity (BCVA).
- Slit lamp biomicroscopy to assess corneal clarity, depth of anterior chamber, state of pupil dilatation, lens morphology.
- Intraocular pressure (IOP) by Goldmann applanation tonometer.
- Fundus examination: slit lamp biomicroscopy using non-contact Volk 90 Diopter lens, direct and indirect ophthalmoscopy.
- Assessment of ocular motility in all direction of gaze.

Preoperative investigation:

- Axial length measurement and calculation of IOL power.
- Specular microscopy: the central endothelial cell density (cells per square millimeter), variation in size of endothelial cells, percentage of hexagonal cells, and CCT were analyzed using a noncontact specular microscope (Fig. 1).



Fig.(1) :Specular microscopy (Topcon SP- 1P, Topcon Medical Inc., Japan), Azhar University Hospitals.

Before surgery, pupillary dilatation was achieved by 1% tropicamide and 1% cyclopentolate eye drops.

Operative procedure

1-Local Anesthesia:

Topical anesthesia was instilled into the conjunctival sac, then peribulbar block through the skin or conjunctiva with a needle.

2- Surgical procedure: (Fig. 2, 3, 4, 5, 6).

After speculum insertion, anterior limbal incision was made using keratome, two side ports was

made by MVR, formation of the anterior chamber by viscoelastic (Hydroxypropyl methylcellulose ophthalmic solution USP 2%, Aurolab, Madurai, India), anterior continuous circular curvilinear capsulorhexis was performed followed by hydrodissection and hydrodelineation .

The phaco-hand piece (Infiniti, ALCON, USA) was inserted to engage the superficial cortex, epinucleus, and nucleus by vacuum of (300-350 mmHg), then pulled centrally and aspirated.

The surgeon prepared dynamic measurements on the phaco-machine by placing the irrigation bottle at the highest level, the aspiration flow rate was between 25-30 ml/min as well as the phaco-power was 0% (usually aspiration alone was sufficient to remove the lens).

After that, irrigation aspiration step was preformed to remove the remnants cortical lens matter. Then, capsular bag was filled with viscoelastic. A loaded injector cartridge was introduced through the main incision and the foldable IOL (ACRYLIC UV, Egypt) was slowly injected and unrolled inside the capsular bag.

Prior to or following IOL rotation, the viscoelastic was aspirated. Finally, the side port incisions and the main wound were sealed with corneal stromal hydration. As a prophylactic measure, a sub-conjunctival injection of antibiotics and steroids was done at end of surgery.

After the operation all patients received the same standard medication for 4 weeks, consisting of 15 mg prednisolone acetate ophthalmic suspension 1% five times/day with gradual tapering over one month, gatifloxacin eye drops five times daily for one month and tobramycin 0.3% dexamethasone 0.1% eye ointment at bed time for one month.

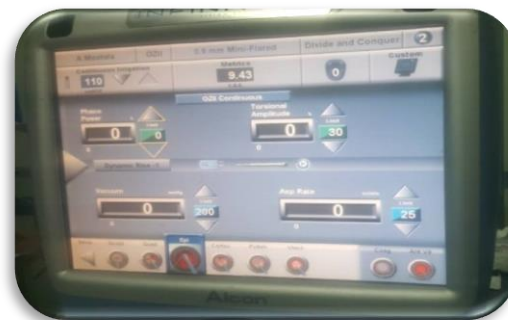

Fig. (2): Phaco-dynamics of Infiniti Alcon machine.

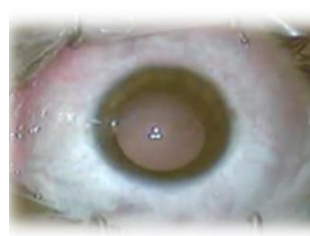

Fig. (3): speculum insertion

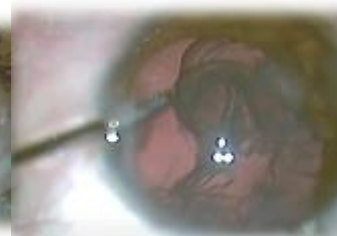

Fig. (4): lens is easily removed by phaco tip

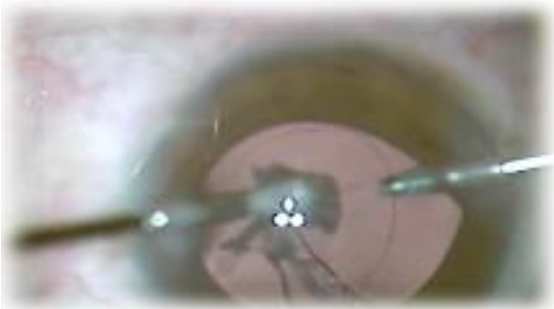

Fig. (5): cortical lens matter is pulled centrally and aspirated.

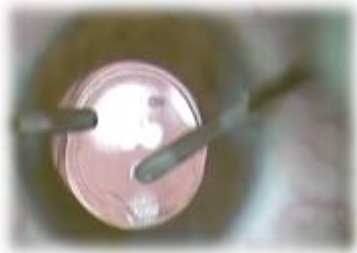

Fig. (6): foldable IOL inside the capsular bag.

Postoperative examinations:

One day after surgery:

Slit lamp biomicroscopy for:

- State of main incision.
- Cornea for clarity, edema and ulcers.
- Anterior chamber (depth and contents).
- Any iris abnormality
- Intraocular lens regarding its position and any deposits on its surface.

One week after surgery:

- Best corrected visual acuity (BCVA).
- Slit lamp biomicroscopy.
- Intraocular pressure (IOP).
- Fundus examination: slit lamp biomicroscopy using non-contact Volk 90 Diopter lens, direct and indirect ophthalmoscopy.

One month and six months:

- Best corrected visual acuity (BCVA).
- Slit lamp biomicroscopy.
- Intraocular pressure (IOP).
- Fundus examination.
- Specular microscopy: The central endothelial cell density (cells per square millimeter), variation in size of endothelial cells, percentage of hexagonal cells, and CCT were analyzed using a noncontact specular microscope, and central corneal endothelial photographs were taken at 1 and 6 months postoperatively.

Statistical analysis

Recorded data were analyzed using the statistical package for social sciences, version 20.0 (SPSS Inc., Chicago, Illinois, USA). Quantitative data were expressed as mean± standard deviation (SD). Qualitative data were expressed as frequency and percentage.

The following tests were done:

- Paired sample t-test of significance was used when comparing between related samples.
- Percentage change%: to calculate the percent of after intervention. It equals the difference between 2nd reading (after 6 months) - 1st reading (preoperative)/1st reading x 100.
- The confidence interval was set to 95% and the margin of error accepted was set to 5%. So, P-value <0.05 was considered significant.

RESULTS

25 eyes of 14 subjects were included in the study (their age range from 38 to 48 years)

Age distribution:

The mean age of the patients was (43.26) ranging from (38 – 46) years (table 1).

Table (1): Age distribution

	Number	Minimum	Maximum	Mean	SD
Age	14	38	46	43.26	3.89

Sex distribution:

There were 11 female (78.5%) and 3 males (21.4%) (Table 2).

Table (2): Sex distribution

		Count	%
Sex	Male	3	21.4
	Female	11	78.5
	Total	14	100

Indication for surgery:

This study included 25 eyes of 14 patients (22 eyes with high myopia and 3 eyes with high hyperopia) (Table 3).

Table (3): Indication for surgery

	Number of patients	%
Hyperopia	3	21.4
High myopia	11	78.5
Total	14	100

Operated eye:

Out of the 25 eyes underwent surgery there were 13 right eyes and 12 left eyes (Table 4).

Table (4): Laterality distribution

Side of the eye	number	%
Right eye	13	52
Left eye	12	48
Total	25	100

The Preoperative error of refraction:

Table (5): Preoperative error of refraction D (SE) for high myopic subjects

	Number	Minimum	Maximum	Mean	SD
Refraction-Pre	22	-8.5	-20.5	-14.94	3.84

Table (6): Preoperative error of refraction D (SE) for high hyperopic patients

	Number	Minimum	Maximum	Mean	SD
Refraction-Pre	3	6.5	9.0	7.98	1.52

Table (7): Preoperative uncorrected visual acuity (LOG MAR)

	Number	Minimum	Maximum	Mean	SD
UCVA- Pre	25	1.0	1.5	1.368	0.1492

Table (8): Preoperative best corrected visual acuity (LOG MAR)

	Number	Minimum	Maximum	Mean	SD
BCVA-Pre	25	0.3	0.8	0.47	0.11

Table (9): Preoperative endothelial cell counts (cells/mm²)

	Number	Minimum	Maximum	Mean	SD
End cell- count pre	25	2,003	3,131	2,651.64	319.192

Intraoperative procedural details:1. **Type of anesthesia:**

Local anesthesia was used in all patients.

The phaco machine parameters:

Table (10): Phaco machine parameters

	N	Minimum	Maximum	Mean	SD
Phaco-2 horizontal (linear) (power)	25	0	5	2.58	0.49
Vacuum (mmHg)	25	350	380	363.60	9.074
Aspiration flow rate (cc/min)	25	23	30	25.16	1.625
Bottle high (cm)	25	80	95	85.40	4.770

2. **Intraoperative complications:**

In all patients there were no any intraoperative complications.

Postoperative results:

The procedure was completed successfully and the patients had coapted wound with no leakage, fine stromal edema, IOP was in normal range and the posterior chamber IOL was in place.

Table (11): Error of refraction D (SE) six months after surgery

	Number	Minimum	Maximum	Mean	SD
Refraction-post	25	-0.5	-2.25	-1.42	0.27

Table (12): Best corrected visual acuity (LOG MAR) six months after surgery

	Number	Minimum	Maximum	Mean	SD
BCVA-Post		0	8	904	5364

Table (13): Endothelial cell counts (cells/mm²) one month after surgery

	Number	Minimum	Maximum	Mean	SD
End cell- count 1w	25	1,214	2,932	2,372.84	383.222

Table (14). Endothelial cell counts (cells/ mm²) six months after surgery

	Number	Minimum	Maximum	Mean	SD
End cell- count 6m	25	1,404	2,905	2,358.84	351.434

The percentage changes in (pre –six month postoperative endothelial cell counts) were 11.04%.

Table (15): The mean of endothelial cell counts (cells/ mm²) changes

	Preoperative	1 month after surgery	6 months after surgery
Endothelial cell- count	2,651.64	2,372.84	2,358.84

Table (16): Percentage change% I endothelial cell, BCVA, and error of refraction from pre to postoperative values

	Mean	SD	P-value
Changes in endothelial cell 6 m after surgery.	292.800	356.858	<0.001**
Changes of BCVA 6 m after surgery	0.129	0.093	0.036*
Changes in the error of refraction 6 m after surgery	13.520	5.137	<0.001**

Examples:

Figures (7, 8, and 9) show endothelial counts of myopic patient who had RLE procedure with phaco-aspiration (preoperative and one and six months postoperatively)




Fig. (7): preoperative specular microscope of 42 years old myopic patient.




Fig. (8): 1 month postoperative specular microscope of same patient in previous figure.




Fig. (9): 6 month postoperative specular microscope of same patient in the previous two figures.

Figures (10, 11, and 12) show endothelial counts of hyperopic patient who had RLE procedure with phaco-aspiration (preoperative and one and six months postoperatively)

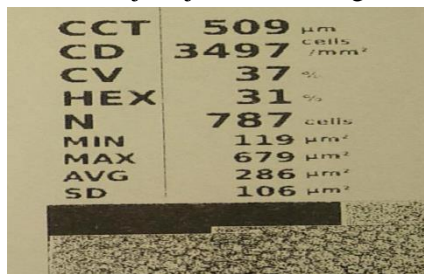


Fig. (10): preoperative specular microscope of 45 years old hyperopic patient.



Fig. (11): one month postoperative specular microscope of the same patient in the previous figure



Fig. (12): Six month postoperative specular microscope of the same patient in the previous two figures.

DISCUSSION

Despite the introduction of surgical improvements for corneal excimer laser surgery such as use of femtosecond laser flap creation and the technology of global eye wave front-guided and topography-guided ablations, the limitations of corneal refractive surgery related to corneal thickness, corneal topography irregularities, and the induction of abnormal levels of corneal aberrations, especially in high refractive errors constitute a real limit for corneal refractive procedures⁽⁸⁾.

Clear lens extraction (CLE) or refractive lens exchange (RLE), is the refractive procedure that involves the removal of a non-cataractous natural lens of the eye with or without intraocular lens placement⁽⁴⁾.

The human corneal endothelial cell is a non-regenerating predominantly hexagonal cell which covers the posterior surface of descemet's membrane and faces the anterior chamber of the eye. Corneal endothelium is metabolically active and plays an imperative role in maintaining the corneal transparency⁽⁹⁾.

We used specular microscopy (SM) as a non-invasive photographic technique that allows the visualization and analysis of the corneal endothelium.⁽¹⁰⁾

Netto et al.⁽¹¹⁾ said that the correction of high myopia was of great interest for many years. Laser assisted in situ keratomileusis (LASIK) and Photorefractive keratectomy (PRK) are the most frequently used techniques because of their good predictability and efficacy. However, the possibility of complications remains; for example, under correction, regression, and corneal haze can occur after PRK.

Gris et al.⁽¹²⁾ stated that following CLE mean endothelial cell loss was 2.6% during the first postoperative year. Best corrected visual acuity was 6/12 or better in 69.4% of eyes preoperatively and in 88.5% postoperatively. Mean cycloplegic refraction was -16.05

diopters (D) preoperatively; the residual cycloplegic refraction was within 1.00 D in 48.4% of eyes and within 2.00 D in 92.5% postoperatively.

Jiménez-Alfaro et al.⁽¹³⁾ found that following CLE uncorrected visual acuity improved in all cases, with 80.77% of eyes achieving 20/100 or better and 42.30%, 20/40 or better. Best spectacle-corrected visual acuity (BSCVA) improved in 23 eyes (88.46%). The percentage of eyes achieving a BSCVA of 20/100 or better increased from 73.07% preoperatively to 92.30% postoperatively and the percentage achieving 20/40 or better, from 23.07 to 73.07%. Of the 26 eyes, 76.91% were within 1.00

diopter (D) of refractive error and 96.16% were within 2.00 D. No intraoperative complications occurred.

It is inevitable that endothelial cell damage will occur during the phacoemulsification procedure. Many factors for postoperative endothelial cell loss were evaluated after phacoemulsification, including cataract density, surgery time, phacoemulsification time, and ultrasound power. In addition, IOL contact, instrument-related trauma, incision size, irrigation solution turbulence, type of IOL, and type of OVD⁽¹⁴⁾.

Reuschel et al.⁽¹⁵⁾ found a median postoperative endothelial cell loss of 6.9% (4.5 -7.9%) 3 months after cataract surgery.

CONCLUSION

Clear lens extraction by phaco-aspiration and PC IOL implantation in highly myopic eyes and highly hyperopic eyes was effective and had an acceptable predictability and a low rate of complications and less harmful to the corneal endothelium because it uses no phaco power.

REFERENCES

1. **Weiss JS and Carr J(2019):**Patient Evaluation for Refractive Surgery.Refractive Surgery E-Book. <https://www.elsevier.com/books/refractive-surgery/azar/978-0-323-54769-7>
2. **Ferromi C(2008):** Refractive surgery in the third millennium. Highlights of Ophthalmol.,36(5): 11-13.
3. **Galvis V, Tello A and Carreño N(2008):** Phakic IOLs, Types and preferred technique. Highlights of Ophthalmol., 36(5): 2-5.
4. **Fan Y Y, Sun C C, Chen H C et al. (2018):** Photorefractive keratectomy for correcting residual refractive error following cataract surgery with premium intraocular lens implantation. Taiwan Jof Ophthalmol., 8(3): 149.
5. **Srinivasan B, Leung H Y, Cao H et al. (2016):** Modern phacoemulsification and intraocular lens implantation (Refractive lens exchange) is safe and effective in treating high myopia. The Asia-Pacific Jof Ophthalmol.,5(6): 438-444.
6. **Paulsen S, Norregaard JC, Ahmed S et al.(2008):**Endothelial cell damage after cataract surgery;divide-and-conquer versus phaco-chop technique.JCataract Refract Surg.,34(6): 996-1000.
7. **McCarey BE, Edelhauser HF and Lynn MJ (2008):** Review of corneal endothelial specular microscopy for FDA clinical trials of refractive procedures, surgical devices and new intraocular drugs and solutions. Cornea, 27(1): 1.
8. **Alio' JL and Toffaha BT (2013):**Refractive Surgery With Phakic Intraocular Lenses. An Update International Ophthalmology Clinics, 53(1): 91–110.
9. **Van Schaick WB, Van Dooren and Mulder PG et al.(2005):**Validity of endothelial cell analysis methods and recommendations for calibration in Topcon SP-2000P specular microscopy. Cornea, 24(5); 538-44.
10. **Gasser L, Reinhard T andBöhringer D(2015):** Comparison of corneal endothelial cell measurements by two non-contact specular microscopes. BMC Ophthalmol., 15: 87-91.
11. **Netto MV, Mohan RR, Sinha S et al.(2006):** stromal haze , myofibroblasts, and surface irregularity after PRK.Exp Eye Res., 82 (5): 788-797.
12. **Gris O, Güell JL, Manero F et al.(1996):**Clear lens extraction to correct high myopia. J Cataract Refract Surg., 22(6):686-689.
13. **Jiménez-Alfaro I, Miguélez S, Bueno JL et al. (1998):** Clear lens extraction and implantation of negative-power posterior chamber intraocular lenses to correct extreme myopia J Cataract Refract Surg., 24(10):1310-1316.
14. **Cho YK,Change HS andKim MS(2010):**Risk factors for endothelial cell loss after phaco:comparison in different anterior chamber depth groups. Korean J of Ophthalmol., 24 (1):10-15.
- Reuschel A, Bogatsch H, Barth T et al.(2010):** Comparison of endothelial changes and power settings between torsional and longitudinal phacoemulsification. J Cataract Refract Surg., 36 (11): 1855-1861.