

Original Article	Anatomical study of the superficial temporal artery
	<i>Abeer Gaber Ahmed, Miriam Ramzy</i> <i>Department of Anatomy and Embryology, Faculty of Medicine, Alexandria University</i>

ABSTRACT

Background: The temporoparietal, parieto-occipital flaps or the forehead flaps that are used in reconstructive surgery are prepared on the superficial temporal artery (STA) and its branches. For a successful surgery and a suitable flap design, adequate anatomical knowledge is needed.

Aim of the work: To study superficial temporal artery as regard its branches both frontal and parietal, their presence or absence, diameters, also relation of superficial temporal artery and its branches to important anatomical landmarks like zygomatic arch, tragus, lateral canthus of the eye also.

Materials and Methods: the red colored latex solution was injected into the external carotid artery; the STA and its branches were dissected in 28 specimens and investigated, diameters of superficial temporal artery and its branches were measured ,also its relation to important anatomical landmarks as zygomatic arch was investigated.

Results: The mean diameter of the STA at the zygomatic arch was determined as 2.75 ± 0.53 mm. It was determined as 2.16 ± 0.56 mm for the frontal branch, and as 1.83 ± 0.47 mm for the parietal branch.. There were no significant differences between the vessel diameters of the right and left sides in any subject ($P > 0.05$). The diameters of the frontal branch were bigger than those of the parietal branch in 15 samples out of 28 (53,57%) .The diameters of both the frontal and parietal branches were equal in 12 samples out of 28 (42,85%) .In one specimen(3,57%),The diameter of the parietal branch were bigger than those of the frontal and parietal branches in comparison with other specimens. In addition ,the frontal branch was absent in this specimen .In 7 out 28(25%), the diameters of the parietal branch were thinner than 1.5 mm. The samples with a diameter of less 1.5 mm were defined as thin parietal branches. Three of these 7 samples were observed on the left side, and the other 4 on the right side. In 4 samples out of 28 (14,28%), thin frontal branch was encountered. Thin STA was observed in 2 specimens. In 20 samples out of 28 (71.42%), the bifurcation points of the STA were over the zygomatic arch .In 7 specimens out of 28(25%), the bifurcation points of the superficial temporal artery were above the zygomatic arch .In only one sample (3,57%), bifurcation was not observed, and the STA continued only as a parietal branch (absence of frontal branch). The absence of the parietal branch was not observed. In one sample (3,57%), parietal branch bifurcates into 2 branches were encountered. the parietal branch went forward to the parietal tuber as the continuation of the STA. Anastomotic branches arise from the posterior aspect of this parietal branch to join similar anastomotic branches from the occipital artery .The frontal branch run forward to the forehead, parallel to the upper corner of the orbicularis oculi muscle. While it run to the frontal muscle, it came back to galea. Its perforating branches passed the deep fascia and the frontal muscle .In all samples,the zygomatico-orbital artery was absent, in these samples, many small subbranches of the frontal branch directed to the lateral region of the orbit .The anterior auricular arteries had a diameter of 1 mm or less. These branches running to the helix and tragus were observed in all samples.

Conclusions: The present study confirms the well-known variability of the superficial temporal arterial branches and the relation to the pericranial region. Knowledge concerning the arterial features of the lateral forehead region is important for the aesthetic surgeon. STA and its branches have been found to be suitable for use in microvascular anastomoses. A better understanding of the midline forehead vascularity should allow modification of reconstructive techniques and reduce postoperative complications.

Received: 01 April 2017, **Accepted:** 15 April 2017

Key Words: Anatomical study, superficial temporal artery

Corresponding Author: Abeer Ahmed, Anatomy Department, Faculty of Medicine, Alexandria University, Egypt, **Tel.:** +20 1100699943, **E-mail:** abeerahmed01244@yahoo.com

The Egyptian Journal of Anatomy, ISSN: 0013-2446, Vol. 41, No. 1

INTRODUCTION

The temporoparietal, parieto-occipital flaps or the forehead flaps that are used in reconstructive surgery are prepared on the superficial temporal artery (STA) or its branches. It has been reported that these flaps are used for the treatment of baldness and for the recovery of the defect of face and scalp (Chang et al 2003 & Har-Shai et al 1992 & Nakajima et al 1995 & Ter Konda & Sykes 1997).

Superficial temporal artery possesses an important source of extracranial-to-intracranial bypass procedures for different ischemic disorders of brain (Ricbourg et al 1975 & Sahinoglu et al 1994 & Sakai et al 1990 & Strauch et al 1993). Yasargil's report anastomosis between the superficial temporal artery and the middle cerebral artery (MCA) which can be beneficial for treatment of cerebral ischaemia (Hamada et al 2002 & Pinar & Govsa 2006), this procedure has become increasingly popular. The microvascular anatomy of the MCA has already been reported (Chang et al 2003 & Pinar & Govsa 2006). On the other hand detailed anatomy of the STA needs more detailed studies to investigate to what extent the STA is suitable for STA-MCA anastomosis with particular reference to its length and diameter. Superficial temporal artery (STA) flaps are used for the reconstruction of various facial defects resulting in relatively low donor-site morbidity. Hairy skin, ear cartilage, temporoparietalis fascia, temporalis muscle, and parietal bone may be elevated either alone or as a composite flap based on the superficial temporal vessels (Pinar & Govsa 2006 & Takeuchi et al 1997 & Kajikawa & Ueada 2003).

Large vessel size, long pedicle, and ease of dissection make it an alternative free flap. In addition, the STA is involved in aesthetic procedures such as conventional or endoscopic face lift and brow lift operations (Abul-Hassan et al 1986 & Buyukmumcu et al 2004 & Chen et al 1999 & Czerwinski 1992).

The course of the STA and its relations with certain anatomic landmarks and temporal branch of the facial nerve (TBFN) would be useful in a great variety of procedures both reconstructive and aesthetic (Volkan et al 2010).

The superficial temporal artery (STA) is one of the terminal branches of the external carotid artery. It begins in the parotid gland behind the neck of mandible and crosses the posterior root of the zygomatic process of the temporal bone (Abul-Hassan et al 1986 & Chen et al 1999 &

Lang 1995 & Marano et al 1985 & Sahinoglu et al 1994). Then, above the zygomatic process, it divides into an anterior frontal and a posterior parietal branches (Czerwinski 1992 & Ricbourg et al 1975 & Strauch et al 1993 & Stock et al 1980). The STA supplies the face and scalp together with some branches of the external carotid artery. As the face is an aesthetic region, its deformation should be repaired with the most suitable tissue. The scalp is popular because it is suitable and near the face (Abul-Hassan et al 1986 & Chang et al 2003 & Kajikawa A, Ueada 2003 & Lopez et al 2003). For this reason, knowing that the STA and its branches supply the scalp and anastomose with the other arteries is important.

It is necessary to be familiar with the variations in the course of the STA and its branches for the evaluation and treatment of certain aesthetic problems, especially those of flap surgery on the lateral forehead region.

MATERIALS AND METHODS

A total of 14 adult formalin preserved cadavers (12 males and 2 females) that had been fixed in a 10% formalin solution, with 28 superficial temporal arteries were dissected at the Department of Anatomy, Faculty of Medicine, Alexandria University. The age range of the cadavers was 43–75 years. After the red colored latex solution was injected into the external carotid artery, the STA and its branches were dissected. Soft tissues were removed to expose the STA, which was then traced in reference to the surrounding landmarks, including the tragus, zygomatic arch and lateral canthus.

The superficial temporal artery was dissected from the zygoma and followed distally until its branches narrowed to an outside diameter of 1mm. To facilitate accurate measurements of arterial length a piece of thread suture was placed along the course of the artery and subsequently measured it against a centimeter ruler. The position of the bifurcation of the superficial temporal artery into its two terminal branches in relation to the zygomatic arch was noted. The branching pattern of the STA was examined and documented. The point of origin of the terminal branches of the STA in relation to the zygomatic arch was noted as being above, at, or below the arch.

In the course of the dissection of each region, the arteries encountered as well as their origin, position, branches, course, anatomical relations were carefully noted. The diameters of the STA

at the level of the zygomatic arch, and the diameters of the terminal branches at the point 1 cm from bifurcation were measured. The caliber of the STA, the frontal branch, and the parietal branch were measured.

Some landmarks were chosen on the head: the middle point to the bony lateral canthus (A), the tragus (B), the superior attachment of the ear to the head (C), and the point 2 cm directly above this attachment (D). These points were joined to the bony lateral canthus by straight lines: AB, AC, and AD. The DF line, which takes Juri's original flap as a base, begins at the point 2 cm above the ear, and is directed anterosuperiorly 45° above the AD line to the anterior hair line. The F point was over the anterior hairline. It was checked whether the parietal branch passed the DF line. According to Juri's design, the DF line builds the base of parietooccipital flaps. The STA was then observed where it crossed all these lines.

RESULTS

The diameters of the STA at the level of the zygomatic arch and the diameters of the terminal branches at the point 1 cm distal to its bifurcation were measured. The mean diameter of the STA at the zygomatic arch was determined as 2.75 ± 0.53 mm. It was determined as 2.16 ± 0.56 mm for the frontal branch, and as 1.83 ± 0.47 mm for the parietal branch. The measurements of STA and its branches have been given in Table 1. There were no significant differences between the vessel diameters of the right and left sides in any subject ($P > 0.05$).

The diameters of the frontal branch were bigger than those of the parietal branch in 15 samples out of 28 (53,57%) (Fig. 1).

The diameters of both the frontal and parietal branches were equal in 12 samples out of 28 (42,85%) (Fig. 2).

In one specimen (3,57%), the diameter of the parietal branch was bigger than those of the frontal and parietal branches in comparison with other specimens, in addition the frontal branch was absent in this specimen (Fig. 3).

In 7 specimens out of 28 (25%), the diameters of the parietal branch were thinner than 1.5 mm. The samples with a diameter of less than 1.5 mm were defined as thin parietal branches. Three of these 7 samples were observed on the left side, and the other 4 on the right side.

In 4 samples out of 28 (14,28%), thin frontal branch was encountered. Thin STA was observed in 2 specimens.

In 20 samples out of 28 (71.42%), the bifurcation points of the STA were over the zygomatic arch (Figs. 2,4,5).

In 7 specimens out of 28 (25%), the bifurcation points of the superficial temporal artery were above the zygomatic arch (Fig. 1).

In only one sample (3,57%), bifurcation was not observed, and the STA continued only as a parietal branch (Fig. 3,6) (absence of frontal branch). The absence of the parietal branch was not observed.

In one sample ((3,57%), %), parietal branch bifurcated into 2 branches (Fig. 7,8) were encountered. The parietal branch ran forward to the parietal tuber as continuation of the STA. (Fig. 7,8). Anastomotic branches arose from the posterior aspect of this parietal branch to join similar anastomotic branches arising from the occipital artery (Fig. 8).

The frontal branch directed forward to the forehead, parallel to the upper corner of the orbicularis oculi muscle. While it supplied the frontal belly of occipitofrontalis muscle, it curved back toward the galea. Its perforating branches pierced the deep fascia and the frontal belly of occipitofrontalis muscle (Fig. 4,5).

In all samples, the zygomaticoorbital artery was absent. In these samples, many small subbranches of the frontal branch came to the lateral region of the orbit (Fig. 9).

The anterior auricular arteries had a diameter of 1 mm or less in all specimens; these branches ran to the helix and tragus (Fig. 1,2).

A-B line (Fig. 10)

A-B line measured a mean of 80.08 ± 5.15 mm, 80.39 ± 4.10 mm on the right, and 79.75 ± 6.24 mm on the left. The STA was 16.69 ± 0.36 mm at the front of the B point on A-B line, it measured 16.86 ± 3.35 mm on the right, and 16.51 ± 3.53 mm on the left (I point). In other words, the STA measured 16.69 ± 0.36 mm at the front of the tragus at the level of arch (I-B line). Table 1. There were no significant differences between the lengths of the right and left sides in any subject ($P > 0.05$).

A-C line (Fig. 10)

A-C line measured a mean of 81.77 ± 5.30 mm in all samples, 81.96 ± 5.45 mm on the right, and 81.57 ± 5.38 mm on the left. Table 1. There were no significant differences between the lengths of the right and left sides in any subject ($P > 0.05$).

II-C line (Fig. 10)

II-C line was 20.03 ± 0.56 mm in all samples. The course of the STA was determined according to I-B ve II-C distances (Fig. 10). Table 1. There were no significant differences between the lengths of the right and left sides in any subject ($P > 0.05$).

A-D line (Fig. 10)

A-D line was measured a mean of 83.64 ± 4.67 mm, 85.18 ± 3.48 mm on the right, and 82.04 ± 5.34 mm on the left. Juri's design to STA and the terminal branches had been given in Table 1. There were no significant differences between the lengths of the right and left sides in any subject ($P > 0.05$). The parietal branch was 11.05 ± 7.76 mm at the front of the D point over the DF line in 22 samples out of 28 (11.66 ± 8.32 mm on the right, and, 10.44 ± 7.44 mm on the left) (Fig. 1). There were no significant differences between the lengths of the right and left sides in any subject ($P > 0.05$).

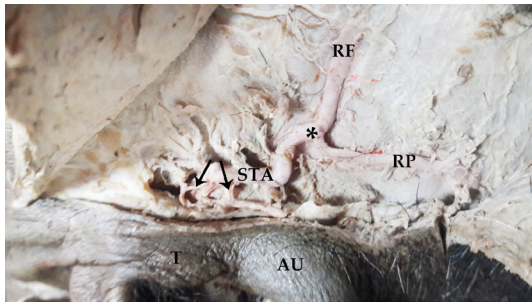


Fig. 1: Photograph of cadaveric temporal region of the head showing the superficial temporal artery (STA) and its bifurcation (*) above the zygomatic arch. The diameter of the frontal branch(RF) was bigger than that of the parietal branch(RP). Notice:anterior auricular arteries(black arrows), auricle(AU), Tragus(T)

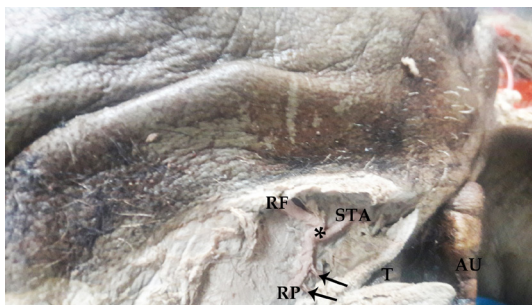


Fig. 2: Photograph of cadaveric temporal region of the head showing the superficial temporal artery (STA) and its bifurcation (*)over the zygomatic arch. The diameters of the frontal branch(RF) and that of the parietal branch(RP), are equal .notice:Anterior auricular arteries(black arrows), Auricle(AU),Tragus(T)

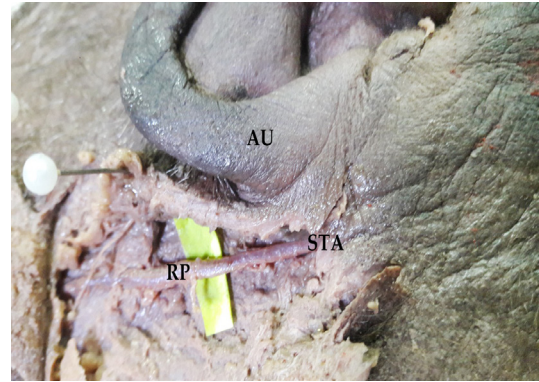


Fig. 3: Photograph of cadaveric temporal region of the head showing the superficial temporal artery (STA), and its continuation as parietal branch (RP), with no bifurcation of the superficial temporal artery.

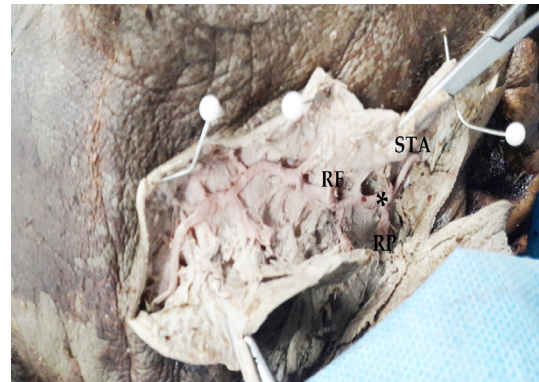


Fig. 4: Photograph of cadaveric temporal region of the head showing the superficial temporal artery (STA) and its bifurcation (*) over the zygomatic arch into two branches the frontal (RF) and the parietal (RP).

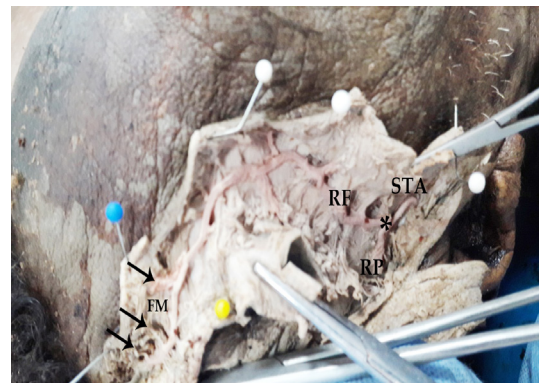


Fig. 5: Photograph of the same specimen in the previous figure with more dissection showing the superficial temporal artery (STA) and its bifurcation (*)over the zygomatic arch. The diameters of the frontal branch(RF) and that of the parietal branch(RP),are equal The frontal branch went forward to the front of the head,. Its perforating branches (black arrows) passed the deep fascia and the frontal muscle (FM).

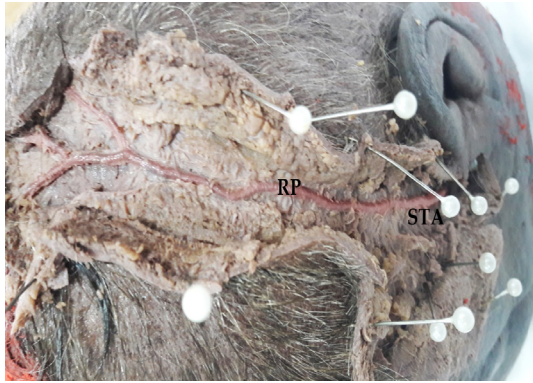


Fig. 6: Photograph of superior view of the head and temporal region showing the superficial temporal artery (STA), the parietal branch (RP) went to the parietal tuber as the continuation of the STA.

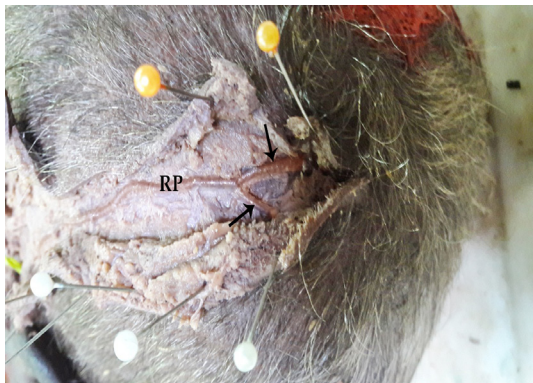

Fig. 7: Photograph of the same specimen in the previous figure with more dissection showing, the parietal branch (RP) bifurcates into 2 branches (black arrows).

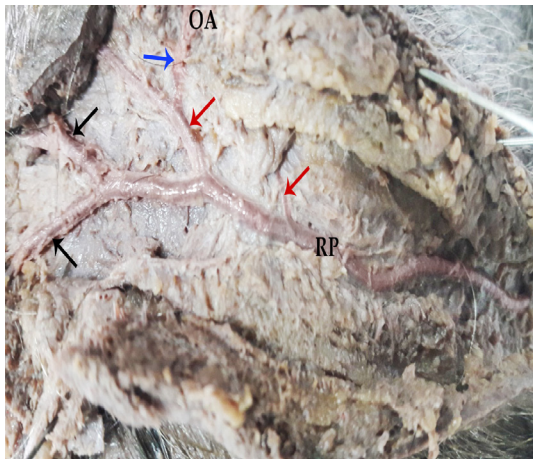


Fig. 8: Photograph of the same specimen in the previous figure with more dissection showing, the parietal branch (RP) bifurcates into 2 branches (black arrows), also anastomotic branches (red arrows) arise from it anastomosing with similar anastomotic branch (blue arrow) arising from occipital artery (OA).



Fig. 9: Photograph of cadaveric temporal region of the head showing the superficial temporal artery (STA) and its bifurcation (*) over the zygomatic arch. The diameters of the frontal branch (RF) and that of the parietal branch (RP) are equal, many small subbranches of the frontal branch came to the lateral region of the orbit (arrow heads) these branches rereplace zygomaticoorbital artery.

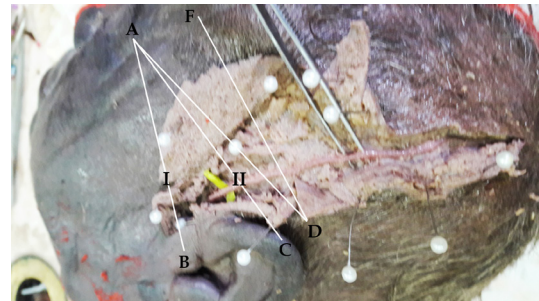


Fig. 10: The course of the superficial temporal artery and its branches. We used some landmarks on the head (A, B, C, D, F points). Straight lines joined these points (AB, AC and AD). Line DF, according to Juri's original flap, begins at the point 2 cm above the ear, and is directed anterosuperiorly 45° above line AD to the anterior hairline. The F point was over the anterior hairline. The course of the STA and its branches were defined according to these lines and points

Table 1: Measurements of STA and its branches ($P > 0.005$)

	Mean (extremes)	Right side	Left side
Diameter STA	2.75±0.53 mm (1.84–3.72)	2.68±0.59	2.71±0.45 mm
Diameter frontal branch	2.16±0.56 mm (1.22–3.72)	2.15±0.59 mm	2.15±0.55 mm
Diameter parietal branch	1.83±0.47 mm (1.3–2.77)	1.78±0.54 mm	1.87±0.43 mm
Line A–B	80.08±5.15 mm (65–87)	80.39±4.10 mm	79.75±6.24 mm
Line A–C	81.77±5.30 mm (66,5–89)	81.96±5.45 mm	81.57±5.38 mm
Line II–C	20.03±0.56 mm		
Line A–D	83.64±4.67 mm (73–91)	85.18±3.48 mm	82.04±5.34 mm
Line D–F	11.05±7.76 mm (3–33.4)	11.66±8.32 mm	10.44±7.44 mm

DISCUSSION

Hairy skin, ear cartilage, temporalis muscle, temporoparietalis fascia and parietal bone may be elevated either alone or as a composite flap based on the superficial temporal vessel superficial temporal artery (STA) flaps are used for the reconstruction of various facial defects resulting in relatively low donor-site morbidity (*Abul-Hassan et al 1986 & Buyukmumcu et al 2004*).

Large vessel size, long pedicle, and ease of dissection make it an alternative free flap. In addition, the STA is involved in aesthetic procedures such as conventional or endoscopic face lift and brow lift operations (*Michlits et al 2004 Sakai et al 1990*).

Many authors have published anatomical studies of the STA and its distribution area (*Abul-Hassan et al 1986 & Chen et al 1999 & Lang 1995 & Marano et al 1985 & Ricbourg et al 1975 & Stock et al 1980*). For a successful surgery and a suitable flap design, adequate anatomical knowledge about superficial temporal artery is necessary. When the flap is raised at the temporoparietal area, the aesthetic defect is minimized. Therefore, it is suitable as a donor site for flap, and preferred by surgeons (*Chang et al 2003 & Kajikawa & Ueada 2003 & Nakajima et al 1995 & Ter Konda & Sykes 1997*).

The STA is very important by itself. It supplies blood to half of the parotid gland, the posterior half of the temporo-maxillary joint, the entire horizontal portion of the scalp and the entire upper lateral half of the face. It has been reported that the diameters of the vessels measured a mean of 2.03–2.14 mm for the STA (*Abul-Hassan et al 1986 & Chen et al 1999 & Lang 1995 & Magden & Arman 1995 & Stock et al 1980*), the frontal branch mean 1.61–2.1 mm (*Chen et al 1999 & Lang 1995 & Magden & Arman 1995*), and the parietal branch mean 1.44–2.1 mm (*Chen et al 1999 & Lang 1995 & Magden & Arman 1995*).

In various researchers' studying the bifurcation point of the STA observed above the zygomatic arch it ranged between in 61% and 88% of the cases (*Abul-Hassan et al 1986 & Chen et al 1999 & Magden & Arman 1995 & Nakajima et al 1995*), directly over the arch it measured 3.8% and 26% (*Chen et al 1999 & Czerwinski 1992 & Magden & Arman 1995 & Sahinoglu 1994 & Stock et al 1980*), and below the arch it measured 7% and 11.5% (*Chen et al 1999 & Czerwinski 1992 & Magden & Arman 1995 & Sahinoglu 1994*).

According to Marano, the diameters less than 1 mm are accepted as atrophic. The atrophic frontal branch is present in 2%, either the parietal branch or the frontal branch was atrophic in 4%, the atrophic STA was present in 2%, and the double parietal branches were present in 4% (*Marano et al 1985*).

Stock et al. (Stock et al. 1980) used Juri's design (*Sheldon et al 1979*) to define the STA and its terminal branches. They found the IB distance as 0.94 cm, IIC distance as 1.39 cm and the, D-parietal branch distance as 1.54 cm (*Stock et al 1980*). The distances according to Juri's flap design were found as: AB line, 82.40±1.09 mm, CB line, 81.8±1.34 mm, and D-parietal branch distance 13.5±0.22 mm (*Chen et al 1999*). Later, *Stock et al.* improved Juri's flap design. They made a rotation to the flap to include the parietal branch according to the anterior hair line and the course of the parietal branch. As to their opinion, the flexible flap was much more sensible than the routine design (*Stock et al 1980*).

Chang et al. performed total upper lip reconstruction with a free temporal scalp flap. They marked the STA using light palpation at the preoperation stage (*Chang et al 2003*). *Lopez et al. (Ricbourg et al 1975)* used the temporal fasciocutaneous island flap, which was supplied by the parietal branch, for oncologic oral and facial reconstruction. *Ricbourg et al.* investigated the zygomatico-orbital artery. According to their definition, the zygomatico-orbital artery branched as type I, out of the STA in 80% of the cases and it branched as type II, out of the frontal branch where bifurcation point of the STA was over the arch in 20%. *Atmaz Pinar et al* also investigated the zygomatico-orbital artery. According to their definition, the zygomatico-orbital artery was observed to be coursing towards the face, parallel to the zygomatic arch in 77.77% of the cases. In the present study in all samples the zygomatico-orbital artery was not observed. In these samples, many small subbranches of the frontal branch directed to the lateral region of the orbit.

The results of the present study have been compared with those of the other researchers in Tables 2 and 3. It has been observed that findings of the present study are generally compatible with those of the others. In the present study, specimens were studied to determine the suitability of the superficial temporal artery for use in microvascular anastomoses. The mean diameter of the STA at the zygomatic arch was determined

as 2.75 ± 0.53 mm. It was determined as 2.16 ± 0.56 mm for the frontal branch, and as 1.83 ± 0.47 mm for the parietal branch.

There were no significant differences between the vessel diameters of the right and left sides in any subject ($P > 0.05$). In the present study, the diameters of the frontal branch were bigger than those of the parietal branch in 15 samples out of 28 (53,57%). The diameters of both the frontal and parietal branches were equal in 12 samples out of 28 (42,85%). In one specimen (3,57%), the diameter of the parietal branch was bigger than those of the frontal and parietal branches in comparison with other specimens in addition, the frontal branch was absent in this specimen. In 7 out of 28 (25%), the diameters of the parietal branch were thinner than 1.5 mm. The samples with a diameter of less than 1.5 mm were defined as thin parietal branches. Three of these 7 samples were observed on the left side, and the other 4 on the right side. In 4 samples out of 28 (14,28%), thin frontal branch was encountered. Thin STA was observed in 2 specimens. In 20 samples out of 28 (71.42%), the bifurcation points of the STA were over the zygomatic arch, on contrary to Amataz et al., bifurcation points of the STA were above the zygomatic arch in 74.07% specimens. One specimen (3.7%) had no bifurcation. In 7 specimens out of 28 (25%), the bifurcation points of the superficial temporal artery were above the zygomatic arch. In only one sample (3,57%), bifurcation was absent in the present study, and this was in accordance with Amataz et al. In the present study the STA continued only as a parietal branch (absence of frontal branch). The absence of the parietal branch was not observed. On contrary to Marano et al. where this parietal branch was absent in one of his samples (3,57%),

In one sample in the present study (3,57%), the parietal branch bifurcated into 2 branches. The parietal branch ran forward towards the parietal tubercle as the continuation of the STA. Anastomotic branches arose from the posterior aspect of this parietal branch to join similar anastomotic branches of the occipital artery.

The anterior auricular arteries had a diameter of 1 mm or less. These branches run to the helix and tragus were observed in all samples in the present study, this was in accordance with Amataz et al.

In the present study bifurcation points of the STA were above the zygomatic arch in 74.07% specimens. In one specimen (3.7%) no bifurcation

was observed, and in 67% had at least one branch, which was ≥ 1.5 mm in the frontal or parietal distribution.

In the present study a suitable frontal branch (i.e., ≥ 1 mm in diameter) was found in 90% of the specimens and a suitable parietal branch was found in 80%. Although one specimen (3.7%) had a bifurcated parietal branch, the diameters of all branches were of suitable size.

Table 2: Position of the bifurcation point of the STA according to authors.

Authors	Above the zygomatic arch (%)	Over the zygomatic arch (%)	Below the zygomatic arch (%)
<i>Stock et al (1980)</i>	60	32	8
<i>Marano et al (1995)</i>	88	4	4
<i>Abul-Hassan et al (1986)</i>	80	-	-
<i>Czerwinski et al (1992)</i>	62.5	26	11.5
<i>Chen et al (1999)</i>	86.5	3.8	9.6
<i>Magden et al (1995)</i>	80	10	8
<i>Sahinoglu et al (1994)</i>	61	14	7
<i>Strauch et al (1993)</i>	80	-	-
<i>Atamaz Pinar et al (2006)</i>	74.07	22	22

Table 3: Diameters of the STA, frontal branch and parietal in mm:

Authors	STA	Frontal branch	Parietal branch
<i>Stock et al (1980) (anatomically)</i>	1.89 ± 0.68	1.38 ± 0.4	1.29 ± 0.5
<i>Stock et al (1980) (radiologically)</i>	2.03 ± 0.33	1.74 ± 0.5	1.83 ± 0.34
<i>Marano et al (1995)</i>	2. (1-5)	-	-
<i>Abul-Hassan et al (1986)</i>	1.8-2.7	-	-
<i>Chen et al (1999)</i>	2.14 ± 0.45	1.61 ± 0.19	1.68 ± 0.21
<i>Magden et al (1995)</i>	2.9 (2-4.1)	2.1 (0.8-3.1)	2.1 (0.9-3.1)
<i>Strauch et al (1993)</i>	1.8-2.7	-	-
<i>Atamaz Pinar et al (2006)</i>	2.73 ± 0.51 (1.82-3.7)	2.14 ± 0.54 (1.2-3.7)	1.81 ± 0.45 (1.1-2.75)

CONCLUSION

The present study confirms the well-known variability of the STA and its arterial branches, and their relation to the pericranial region. Their arterial distribution is clinically important. The advancement of new methods provides increased possibilities for studying the arterial circulations in the temporoparietal and parieto-occipital regions, thus emphasizing the importance of detailed knowledge about the anatomical variations in these areas. Operations on the lateral forehead region can severely damage some of the branches as well as the main trunk of the STA. Since variations in blood supplies of the lateral forehead region have been observed during the present cadaveric study, It can be reported that the existence and course of the STA and its branches should be preoperatively confirmed by Doppler examination, and during dissection, great care should be taken so as not to damage the vascular pedicle the diameters of all branches were of suitable size. The successful usage of the forehead and parieto-occipital flap depends on the anatomical features of the pedicles of the parietal and frontal branches contained.

REFERENCES

- Abul-Hassan, H.S., Ascher, G.D., Acland, R.D. 1986.** Surgical anatomy and blood supply of the fascial layers of the temporal region. *Plastic and Reconstructive Surgery*, 77: 7–28.
- Buyukmumcu, M., Guney, O., Ustun, M.E., Uysal, I.I., Seker, M. 2004.** Proximal superficial temporal artery to proximal middle cerebral artery bypass using a radial artery graft: an anatomic approach. *Neurosurgical Review*, 27: 185–188.
- Chang, K.P., Lai, C.S., Tsai, C.C., Lin, T.M., Lin, S.D. 2003.** Total upper lip reconstruction with a free temporal scalp flap: longterm follow-up. *Head Neck*, 25: 602–605.
- Chen, T.H., Chen, C.H., Shyu, J.F., Wu, C.W., Lui, W.Y., Liu, J.C. 1999.** Distribution of the superficial temporal artery in the Chinese adults. *Plastic and Reconstructive Surgery*, 104: 1276–1279.
- Czerwinski, F. 1992.** Variability in the course of the superficial temporal artery in man. *Folia Morphologica*, 51: 49–54.
- Hamada, J., Todaka, T., Yano, S. 2002.** Vertebral artery–posterior inferior cerebellar artery bypass with a superficial temporal artery graft to treat aneurysms involving the posterior inferior cerebellar artery. *Journal of Neurosurgery*, 96: 867–871.
- Har-Shai, Y., Fukuta, K., Collares, M.V. 1992.** The vascular anatomy of the galeal flap in the interparietal and midline regions. *Plastic and Reconstructive Surgery*, 89: 64–69.
- Kajikawa, A., Ueada, K. 2003.** Bilateral eyebrow reconstruction using a unilateral extended superficial temporal artery flap. *Annals of Plastic Surgery*, 50: 416–419.
- Lang, J. 1995.** Skull base and related structures, atlas of clinical anatomy. New York: Schattauer Stuttgart; pp 118–112.
- Lopez, R., Dekeister, C., Sleiman, Z., Paoli, J.R. 2003.** The temporal fasciocutaneous island flap for oncologic oral and facial reconstruction. *Journal of Oral and Maxillofacial Surgery*, 61: 1150–1155.
- Magden, O., Arman, C. 1995.** Arteria temporalis superficialis'in anatomik varyasyonları. *Dokuz Eylul Universitesi Tip Fakultesi Dergisi*, 95: 15.
- Marano, S.R., Fischer, D.W., Gaines, C., Sonntag, V.K.H. 1985.** Anatomical study of the superficial temporal artery. *Neurosurgery*, 16: 786–789.
- Michlits, W., Papp, C., Hormann, M., Aharinejad, S. 2004.** Nose reconstruction by chondrocutaneous preauricular free flaps: anatomical basis and clinical results. *Plastic and Reconstructive Surgery*, 113: 839–844.
- Nakajima, H., Imanishi, N., Minabe, T. 1995.** The arterial anatomy of the temporal region and the vascular basis of various temporal flaps. *British Journal of Plastic Surgery*, 48: 439–450.
- Pinar, Y.A., Govsa, F. 2006.** Anatomy of the superficial temporal artery and its branches: its importance for surgery. *Surgical and Radiologic Anatomy*, 28: 248–253.
- Ricbourg, B., Mitz, V., Lassau, J.P. 1975.** Artere temporal superficiale. *Annales De Chirurgie Plastique Et Esthetique*, 2: 197–213.

Sahinoglu, K., Koldas, T., Gorgun, B., Ari, Z., Usta, A. 1994. Arteria temporalis superficialis ve arteria temporalis media anatomisi. *Istanbul Tip Fakultesi Dergisi*, 57: 40–42

Sakai, S., Soeda, S., Ishii, Y. 1990. Avulsion of the scalp: which one is the best artery for anastomosis? *Annals of Plastic Surgery*, 24: 350–353.

Sheldon S. Kabaker, 1979 Juri Flap Procedure for the Treatment of Baldness. *Arch Otolaryngol* 105:509-514.

Stock, A.L., Collins, H.P., Davidson, T.M. 1980. Anatomy of the superficial temporal artery. *Head and Neck Surgery*, 2: 466–469.

Strauch, B., Yu, H-L., Chen, Z-W., Liebling, R. 1993. Atlas of microvascular surgery,

anatomy and operative approaches. New York: Thieme Medical Publishers; pp 526–537.

Takeuchi, S., Koike, T., Tanaka, R. 1997. Anastomosis of the superficial temporal artery to the middle cerebral artery with the interposed occipital artery graft in moyamoya disease: case report. *Surgical Neurology*, 48: 615–619.

Tayfur, V., Edizer, M., Magden, O. 2010. Anatomic Bases of Superficial Temporal Artery and Temporal Branch of Facial Nerve. *Journal of Craniofacial Surgery*, 21: 1945-1947.

Ter Konda, R.P., Sykes, J.M. 1997. Concepts in scalp and forehead reconstruction. *Head Neck Reconstruction*, 30: 519–539.

دراسة تشريحية من الشريان الصدغي السطحي

عبير أحمد ومiriam رمزي

قسم التشريح وعلم الأجنة، كلية الطب، جامعة الإسكندرية

ملخص البحث

خلفية البحث: يتم إعداد اللوحات الصدغية الجدارية، الجدارية القذالية أو اللوحات الجبهة المستخدمة في جراحة اعاده البناء معتمده على الشريان الصدغي السطحي وفروعه. هناك حاجة إلى المعرفة التشريحية الكافية لعمل وتصميم لوحه مناسبة، لعملية جراحية ناجحة

الهدف من العمل: دراسة الشريان الصدغي السطحي وفروعه لأمامي والجداري، ودراسه وجودها أو عدم وجودها وقطرها، وأيضا علاقة الشريان الصدغي السطحي وفروعه للمعالم التشريحية الهامة مثل القوس الوجني، الزنمة، اللحاظ الوحشي للعين أيضا

المواد والطرق: تم حقن اللانكس الأحمر اللون في الشريان السباتي الخارجي. تم تشريح الشريان السطحي الصدغي وفروعه في 28 عينه وتم فحصها، و تم قياس قطر الشريان الصدغي السطحي وفروعه أيضا ودراسه علاقته بالمعالم التشريحية الهامة مثل القوس الوجني

النتائج: وجد إن متوسط قطر الشريان السطحي الصدغي في القوس الوجني هو 75 ± 53 و 65 ± 0 ملم للفرع الأمامي، و 74 و 38 و 1 ± 0 ملم للفرع الجداري. لا توجد فروق ذات دلالة إحصائية بين الأقطار في الجانبين الأيمن والأيسر.

وكانت قطر الفرع الأمامي أكبر من الجداري في 15 عينة من أصل 28 (53،57%)

وكان قطر كل من الفرع الأمامي والجداري متساوية في 12 عينة من أصل 28 (42،85%) وفي عينة واحدة (3،57%) كان قطر الفرع الجداري أكبر من جميع الفروع الامامية و الجدارية بكل العينات المدروسة، بالإضافة الى ذلك كان الفرع الأمامي غائب في 7 عينات من أصل 28 (25%)، وكانت أقطار الفرع الجداري أرق من 1.5 مم. وقد تم تحديد العينات التي يبلغ قطرها أقل 1.5 ملم على انها فرع جداري رقيق . وقد لوحظت هذه الظاهرة في ثلاثة من هذه العينات السبعة على الجانب الأيسر، و 4 على الجانب الأيمن.

ووجد في 4 عينات من أصل 28 (14،28%)، الفرع الأمامي رقيق. و في 2 من العينات وجد ان الشريان الصدغي رقيق.

في 20 عينة من أصل 28 (71.42%)، وكانت نقطة التشعب من الشريان السطحي الصدغي على القوس الوجني في

في 7 عينات من أصل 28 (25%)، وكانت نقطة التشعب من الشريان الصدغي السطحي فوق القوس. و في عينة واحدة فقط (3،57%)، لوحظ غياب التشعب و لم يلاحظ غياب الفرع الجداري، حيث يواصل الفرع الجداري مسار الشريان السطحي الصدغي (في حالة غياب فرع الأمامي). في عينة واحدة (3 و 75%) انقسم الفرع الجداري الى فرعين حيث اتجه. الفرع الجداري قدما إلى درنة الجدارية باعتبارها استمرارا للشريان السطحي الصدغي. ونشأت من هذا الفرع الجداري فروع. تفرع من الخلف للانضمام للفروع المفاغرة المماثلة من الشريان القذالي . و جرى الفرع الأمامي إلى الأمام إلى الجزء الأمامي من الرأس، موازية إلى الزاوية العليا من العضلات الدويرية للعين. في حين أنه ذهب إلى العضلات الأمامية، فإنه عاد إلى الخوذة. مرت فروعها تنقيب اللقافة العميقة والعضلات الأمامية. في 27 عينة من أصل 28 (96،42%)، لم يكن لوحظ الشريان الوجني المداري في هذه العينات، وجاءت العديد من الفروع الفرعية الصغيرة من الفرع الأمامي إلى المنطقة الجانبية من المدار. و كانت الشرايين الأذنية الأمامية يبلغ قطرها 1 مم أو أقل. وقد لوحظت هذه الفروع تعمل على الحلزون والزنمة في جميع العينات.

الاستنتاجات: هذا البحث يؤكد الاختلافات في منطقة الجبين الجانبية مهم للجراحات التجميلية تم العثور على الشريان السطحي الصدغي وفروعه لتكون مناسبة للاستخدام في مفاغرة الاوعية الدموية الدقيقة. فهم أفضل لخط الوسط الجبيني والأوعية الدموية يجب أن تسمح تعديل تقنيات الترميمية والحد من مضاعفات ما بعد الجراحة.