

Original Article	An Anatomical Study of the Length of the Neural Pedicle after the Bifurcation of the Thoracodorsal Nerve <i>Abeer Ahmed¹ and Yasser El Sheikh²</i> ¹ <i>Department of Anatomy and Embryology, Faculty of Medicine, Alexandria University.</i> ² <i>Department of Plastic Surgery, Faculty of Medicine, Menofia University</i>
-------------------------	---

ABSTRACT

Background: Latissimus dorsi muscle is considered as a key stone most important muscle in plastic surgery used for many reconstructive surgical procedures varying from facial reanimation and breast reconstruction to lower limb reconstruction. it is essential to have knowledge about The branching pattern and length of the thoracodorsal nerve which is the nerve supply of this precious latissimus dorsi distal to the splitting of this nerve. For innervated functional muscle transplant procedures, the length of nerve pedicles available for nerve anastomosis is crucial

Aim of the Work: Is to investigate the topography and branching pattern of the thoracodorsal and also measure its length distal to its splitting.

Materials and Methods: Sixteen latissimus dorsi muscles were dissected in eight adult embalmed human specimens in Anatomy department Faculty of medicine Alexandria university. The thoracodorsal neurovascular bundle was dissected and the pattern of branching of the thoracodorsal nerve was identified The branches were dissected up to the latissimus dorsi muscle and further intramuscularly. All lengths were measured using a vernier caliber. Surgically, in total, 10 patients with recurrent squamous cell carcinoma were undergone surgery permitting simultaneous cancer resection and harvesting of latissimus dorsi flap in Plastic surgery department, Faculty of medicine, Menofia University, Informed written individual consent was obtained for all the patients.

Results: The median length of the medial branch was 3.45 cm (range, 1.80 to 5.5 cm; mean, 3.60 cm; SD, 1.04 cm). As regard the branching pattern of the thoracodorsal nerve distal to its splitting it varied from three branches pattern in 75%, two branches pattern in 23% of the specimens and in one case continued as one branch on the lateral border of latissimus dorsi muscle In one other specimen thoracodorsal nerve distal to its split gave many branches and in this specimen abreast mass was noticed on the corresponding side of this thoraco dorsal nerve. The veins and arteries showed a similar pattern, with a median length that is similar to that of the thoracodorsal nerve.

The median length of the middle branch was 3.50 cm (range, 2.4 5 to 4.65 cm; mean 3.45 cm; SD, 0.88 cm), The lateral branch showed a median length of 3.99 cm (range, 2.5 5 to 5.95 cm; mean, 3.85 cm; SD, 0.95 cm). The mean length of the thoracodorsal nerve measured from the posterior root to the split was 12.5 cm. Surgically, by surface area the latissimus dorsi is the largest muscle in the body. It can be as large as 20 x 40cms, enabling latissimus dorsi flaps to cover very large defects after resection of squamous cell carcinoma in head and neck region especially in temporal and scalp regions.

Conclusions: The separate neurovascular branches and its minimal pedicle length make the latissimus dorsi muscle very suitable for single functional free muscle transfer, using only the lateral part of the latissimus dorsi muscle, and double functional free muscle transfer using only one vascular pedicle. This suggests the possibility of a multiple, segmentally innervated latissimus dorsi muscle transfer. And actually this is facilitated by this branching pattern of the thoracodorsal nerve. There may be association between the multiple branch pattern of the thoracodorsal nerve and presence of breast mass, an issue which need more research. From surgical points of view, there is strong need for preoperative diagnostic tools to predict the pattern of branching of neuro vascular bundle of latissimus muscle, to help preoperative planning especially in cases as facial reanimation, also in cases that we need more than one muscular functional units, also in cases that we might need to leave portion of muscle for better esthetics and better function of limb movements.

Received: 06 April 2017, **Accepted:** 05 May 2017

Key Words: Anatomical study, Thoracodorsal nerve, pedicle

Corresponding Author: Abeer Ahmed, Anatomy Department, Faculty of Medicine, Alexandria University, Egypt, **Tel.:** +20 1100699943, **E-mail:** abeerahmed01244@yahoo.com

The Egyptian Journal of Anatomy, ISSN: 0013-2446, Vol. 41 No. 1

INTRODUCTION

The latissimus dorsi muscle is used for many reconstructive surgical procedures varying from breast reconstruction and lower limb reconstruction to facial reanimation (*Iwasawa et al. 2002 and White et al. 2006*). Its thoracodorsal neurovascular pedicle adequate length is crucially important (*Standing et al. 2008 and Saddler et al. 2006 and Muthoka et al. 2011 and Lu, W et al. 2008*)

Various surgical procedures for the facial paralysis have been carried out until now, such as muscle flap transplantation in 2 stages following nerve graft, (*Harii et al. 1998*) nonvascularized free muscle transplantation (*Wei et al. 1999*), and nerve grafting (*Takushima et al. 2006*). However, a new method using vascularized muscle transplantation with nerve in a single stage has become the mainstream. In these reconstruction methods, LD muscle (*Harii et al. 1998 and Wei et al. 1999 and Takushima et al. 2006 and Koshima et al. 1997*), rectus abdominis muscle (*Koshima et al. 1994*), abductor hallucis muscle (*Jiang et al. 1995*), internal oblique muscle (*Wang et al. 2002*), biceps femoris muscle (*Hayashi and Maruyama 2005*), and smaller pectoral muscle (*Terzis 1989*) have been used; however, the Latissimus dorsi muscle flap, which comprises long nerves and vascular pedicles, is the most commonly used (*Iwasawa et al. 2002 and White et al. 2006*), also masseter (*Biglioli et al. 2011*), and anterolateral thigh flap (*Iida et al. 2006*), are also used.

Facial reanimation surgery using a free muscle flap for facial paralysis, in which gracilis muscle flap was used, was first reported by Harii (*Harii et al. 1998*) Subsequently, many muscle flaps for the surgery have been reported. In Asian countries, the LD muscle flap is the most commonly used among these muscle flaps, because it has a long vascular pedicle and nerve (*Koshima et al. 1994 and Wang et al. 2002 and Hayashi et al. 2005*).

Split thoracodorsal nerve funicular graft combined with functional latissimus dorsi musculocutaneous flap used recently for immediate facial reanimation after tumor ablation recently used (*Iwasawa et al. 2002 and Li, B.H. et al. 2012*).

The authors believe that the two funicles of the thoracodorsal nerve can be used independently for two purposes: one for functional segmental muscle transfer and the other for nerve grafting in defects of branches of the facial nerve. This concept makes it possible to reconstruct multiple facial movements with minimizing donor site morbidity by means of immediate facial reanimation (*White Matthew et al. 2006 Biglioli et al. 2009 and Biglioli et al. 2012 Lee et al. 2008*).

The advantages of being able to split the muscle into a medial and lateral flap are; that only the lateral part of the muscle can be harvested leaving the medial flap in situ, providing strength in the donor limb, benefitting certain patients, or that the flap is used for two transfers (*Wong et al. 2007 and Schwabegger et al. 2003*).

For innervated functional muscle transplant procedures, however, it is essential to have knowledge about the length of the nerve pedicles available to each of the segments of the latissimus dorsi muscle to preoperatively plan the donor nerve (*Mu and Sanders 2000 and Liu 1997 and Theeuwes et al. 2011 and Peker et al. 2006 Gülekon et al. 2007 Wong et al. 2007*).

It was previously described that 3 cm of nerve was essential, but with current microsurgical techniques, 1 cm is sufficient for muscle transplant procedures (*Meyer et al. 2001 and Wilkman et al. 2014*).

Until now, the precise length of the two funicles, to be more exact, the length of the thoracodorsal nerve distal to the point of the nerve split, has never been described (*Lu, W et al. 2008*).

The lateral branch of the thoracodorsal nerve (LBTN) is used for nerve transfer in facial, musculocutaneous, axillary nerve injuries, and for irreparable C5, C6 spinal nerve lesions, and accessory nerve defects (*Schultes et al. 1999*). For a successful surgical outcome, the nerve to be used in nerve transfer should be of adequate length and thickness for nerve coaptation (*Theeuwes et al. 2011 and Wong et al. 2007 and Gülekon et al. 2007 and Lee et al. 2008 and Mu and Sanders 2010*).

This anatomical article describes the branching and length of the thoracodorsal nerve distal to the point of nerve splitting (i.e., from splitting point to its end into the muscle).

PATIENTS, HUMAN CADAVERS AND METHODS:

(A) ANATOMICALLY

In total, 16 axillae were dissected, derived from 8 adult formaline embalmed human anatomic cadavers in Anatomy department, Faculty of medicine, Alexandria University. The thoracodorsal neurovascular bundle was dissected, and the pattern of branching of the thoracodorsal nerve was identified, the branches were dissected up to the latissimus dorsi muscle, and further intramuscularly. All lengths were measured using a vernier caliper. Dissection was performed with the cadavers in prone position. The skin and overlying fat was removed and the latissimus dorsi muscle dissected. The neurovascular bundle was carefully dissected with removal of fat, and surrounding connective tissue before the actual distances were measured.

The distances from split of the thoracodorsal nerve to the end of the nerve in the latissimus dorsi muscle was measured by using vernier caliper

(B) Operative procedures

In total, 10 patients with recurrent squamous cell carcinoma Figs (A and B) were undergone surgery permitting simultaneous cancer resection and harvesting of latissimus dorsi flap in Plastic surgery department, Faculty of medicine, Menoufia University, Informed written individual consent was obtained for all the patients.

The patient is placed in the lateral decubitus position on a beanbag, with an axillary roll placed in the dependent axilla. The ipsilateral arm is prepped completely and left in the operative field, allowing it to be freely moved about the field. For most of the procedure it is kept abducted and resting on a well padded sterile stand placed anterosuperiorly to the patient. The latissimus border is outlined with a marking pen. The incision is then marked extending from the axilla or the posterior axillary fold, then inferiorly and medially over the latissimus muscle Fig (C1). The length of muscle needed will dictate the incision length. Alternatively, if a skin paddle is necessary, it is marked over the flap. A pencil Doppler can be used to ensure the presence of a perforator in the skin paddle. Anterior and posterior flaps are raised

superficial to the muscle to expose the latissimus. A small amount of muscular fascia can be left on the latissimus, but this is not necessary. Any comfortable plane for the surgeon is adequate. The skin and fat flaps are elevated to the extent of the pocket necessary for adequate muscle size harvest Fig (C2). Smaller muscle can be taken if the entirety of the muscle is not needed.

The superior edge of the latissimus is identified at the inferior angle of the scapula. The serratus muscle can be identified easily with this approach. The alternate approach from distal to proximal can often lead to confusion and unnecessary elevation of the serratus muscle since the distal serratus latissimus plane is less apparent. When elevating the flap from inferior to superior it is important not to dissect underneath the serratus.

The superior edge of the latissimus, below the inferior angle of the scapula is then elevated Fig (C3). This areolar plane is easy to dissect, and any large caliber perforators can be ligated and divided. The dissection is then directed toward the midline, and the insertions of the muscle near the midline of the back is divided. The dissection proceeds inferiorly freeing the medial muscle insertion Fig. (C3andC4)

When the inferior portion of the muscle is reached, the attachment plane here is not clear and muscle be created with the electrocautery. After the medial and inferior muscle is released, the dissection proceed underneath the muscle toward the axilla. The plane becomes very thin and areolar and easy to dissect. Fig. (C4)

The vessels to the latissimus and serratus become clear as the axilla is neared Fig. (C5). The branch to serratus is ligated and the circumflex scapular branch can be if more length is needed. The nerve is divided and the artery and vein can be ligated and divided when the recipient area is ready. The wound is closed with a deep and superficial layer. Two suction drains are placed.

Postoperative Care

We allow the patient to use the ipsilateral arm postoperatively and no special dressings are required. The donor area should be inspected daily for hematoma formation. This donor area often forms a seroma, necessitating the use of drains for often more than a week. We often leave them in for 2 weeks or longer until the output is diminished. Seromas should be aspirated through the anterior skin flap.

RESULTS

The thoracodorsal nerve, which mainly derives from C7 and a small contribution from C6 and C8 accompanied by thoracodorsal blood vessels (Fig 1,2,3), thoracodorsal nerve divided into three branches: medial, middle and lateral different branches (75 percent of specimens) fig (3,4) or it splitted into two branches (23 percent of the specimens) fig (5,6,7,8) one medial branch and other lateral. In one specimen thoracodorsal nerve continued as a single branch along the lateral border of the latissimus dorsi muscle fig (9,10), while on the other axilla of the same cadaver the thoracodorsal nerve splitted into three branches Fig. (11).

In almost all specimens there was no difference in pattern of branching of the thoracodorsal nerve on the two sides, except in one specimen there was a difference in the pattern of branching of the thoracodorsal nerve, on the right side thoracodorsal nerve divided into many small branches, also it must be mentioned that on this side a breast mass was noticed Figs. (12,13) with enlarged axillary lymph nodes Fig (14), in addition to many arterial branches arised from thoracodorsal artery accompanying this Rt thoracodorsal nerve multiple nerve branches Figs. (14,15), on contrary to what was found on this right axilla, on the Lt axilla of this same cadaver thoracodorsal nerve divided into three branches namely medial, middle and lateral branches Fig. (16).

The median length of the medial branch was 3.45 cm (range, 1.80 to 5.5 cm; mean, 3.60 cm; SD, 1.04 cm).

The median length of the middle branch was 3.50 cm (range, 2.4 5 to 4.65 cm; mean 3.45 cm; SD, 0.88 cm).

The lateral branch showed a median length of 3.99 cm (range, 2.5 5 to 5.95 cm; mean, 3.85 cm; SD, 0.95 cm).

The mean length of the thoracodorsal nerve measured from the posterior root to the split was 12.5 cm

Thoracodorsal Blood vessels, both artery and vein followed the same pattern of split of their accompanying thoracodorsal nerves Fig (1,2).

The thoracodorsal artery also splitted into two or three different branches in 25 percent and 75 percent, respectively Fig(1,2), from the distance between the point of split and the point of muscle insertion The median length of the medial, middle

and lateral branches of the thoracodorsal artery were as their accompanying nerves.

The thoracodorsal vein, just as the nerve and artery, splits into two or three different branches, in 25 percent and 75percent of the dissected latissimus dorsi muscles, respectively Fig (1,2).

Operative results

By surface area the latissimus dorsi is the largest muscle in the body. It can be as large as 20 x 40cms, enabling latissimus dorsi flaps to cover very large defects Figs (18and19) after resection of squamous cell carcinomain head and neck region especially in temporal and scalp regions. as in Fig (AandB). Latissimus dorsi flap was chosen for its many advantages as it is the easiest flap to harvest, .Large thin muscle that can cover very large defects Figs (18and19), long (5-15cm) vascular pedicle if dissected up to the subscapular artery Fig (20and21), the subscapular artery has a diameter of 2-5mm, minimal long-term donor site morbidity, can be harvested as a muscle flap or with a skin paddle Figs (22and23), and can be harvested as a chimeric flap (multiple otherwise independent flaps that each have an independent vascular supply with all pedicles linked to a common source vessel) along with other flaps based on a singular subscapular artery.

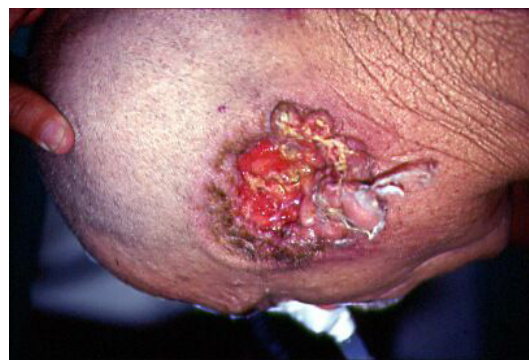

Fig. A: Photograph showing recurrent squamous cell carcinoma of left temporal region

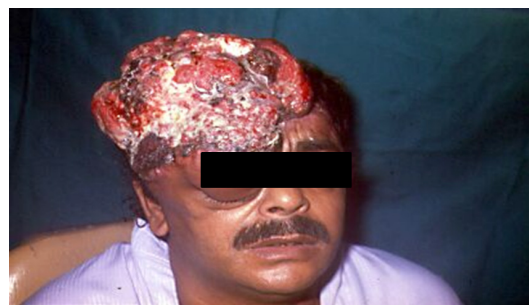

Fig. B: Photograph of recurrent squamous cell carcinoma of the scalp on the right side

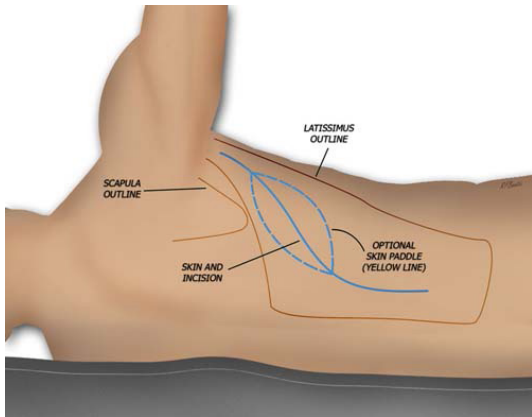


Fig. C-1: Photograph showing after positioning the patient determination of the outlines of flap and feeding vessels and also important landmarks.

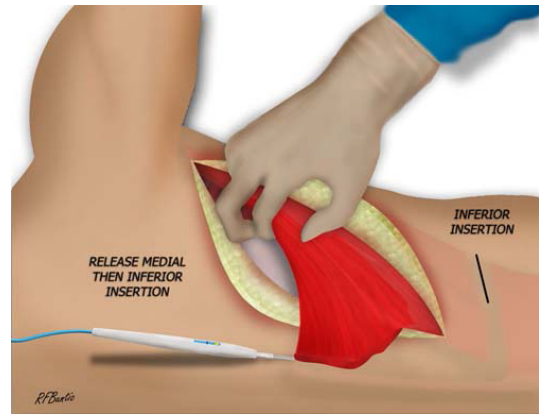


Fig. C-4: Photograph showing the way of dissection of latissimus dorsi muscle flap, release of medial then inferior insertion of latissimus dorsi muscle.

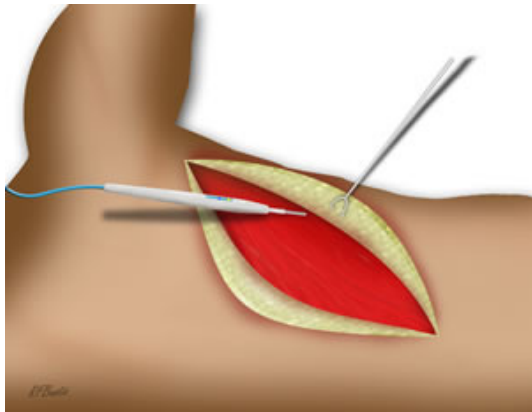


Fig. C-2: Photograph showing after making incision in the preplanned position elevation of skin flaps in suprafacial plane to expose LD muscle.

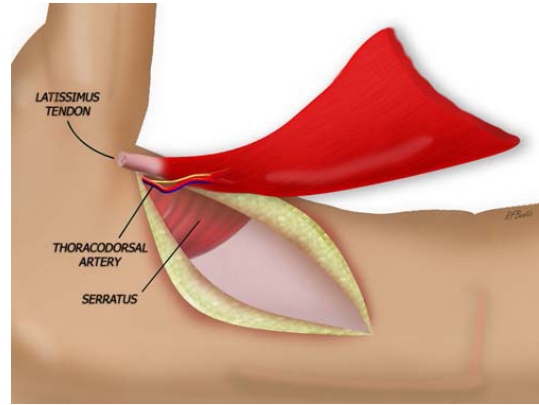


Fig. C-5: Photograph showing disinsertion of latissimus dorsi muscle. Hanging only on its vascular pedicle (Thoracodorsal artery) (Atlas of microsurgery techniques and principles 2001-2007 Rudolf Buntic et al.)

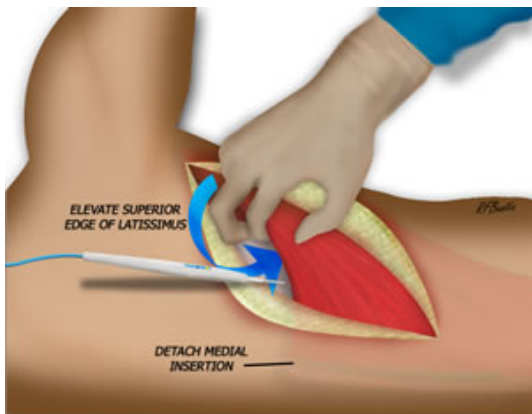


Fig. C-3: Photograph showing starting to elevate LD muscle flap superiorly at the inferior angle of scapula superiorly.

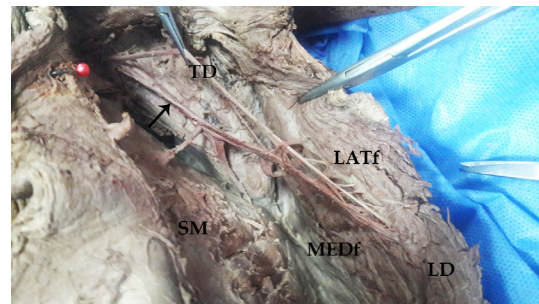


Fig. 1: Dissected cadaveric axilla showing latissimus dorsi (LD), supplied by thoracodorsal nerve (TD), accompanied by thoracodorsal blood vessels (Black arrow) formed of two flaps, medial flap (MEDf) and lateral (LATf), serratus anterior muscle (SM).

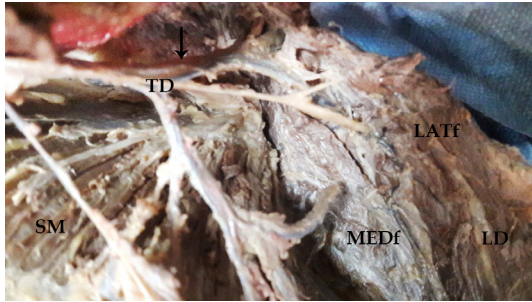


Fig. 2: Photograph of dissected cadaveric axilla showing latissimus dorsi (LD) formed of two flaps lateral flap (LATf) and medial flap (MEDf), supplied by thoracodorsal nerve (TD) which is accompanied by thoracodorsal blood vessels (Black arrow), serratus anterior muscle is (SM).

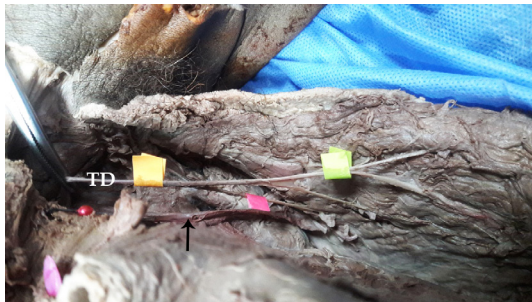


Fig. 3: The same specimen in Fig 1, with retraction of the thoracodorsal blood vessels (black arrow) to show thoracodorsal nerve (TD).

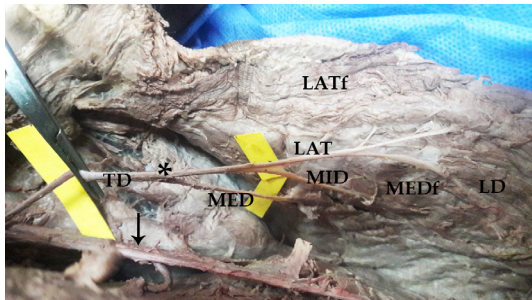


Fig. 4: Photograph of the same specimen in the previous figure with more dissection and retraction of the thoracodorsal blood vessels (Black arrow) to show thoracodorsal nerve (TD) splitting (*) where it is splitted into three branches: lateral (LAT), medial (MED) and middle (MID) branches (LD) latissimus dorsi, (LATf) lateral flap, (MEDf) medial flap.

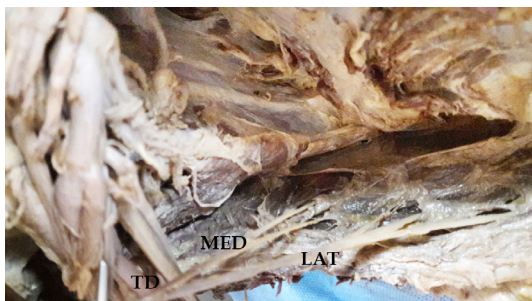


Fig. 5: Photograph of dissected cadaveric axilla showing thoracodorsal nerve (TD) splitted into two branches medial (MED), and (LAT).

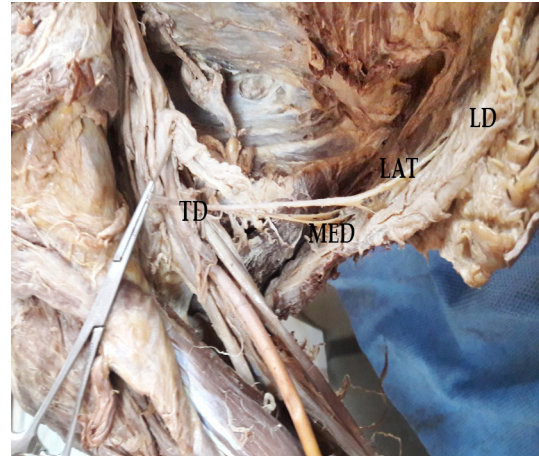


Fig. 6: Same specimen in figure 5 with more dissection, (LD) latissimus dorsi (TD) thoracodorsal nerve splitted into medial (MED) and lateral (LAT) branches.

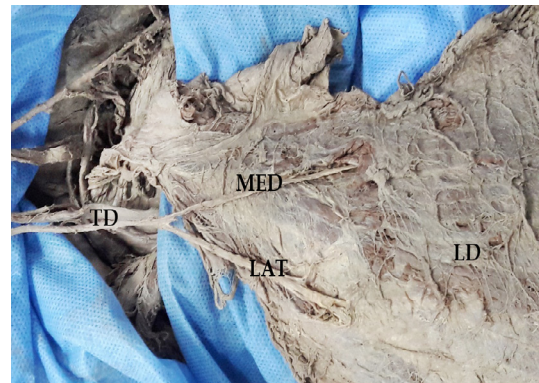


Fig. 7: Photograph of dissected cadaveric axilla showing latissimus dorsi (LD), thoracodorsal nerve (TD) is splitted into two branches medial (MED) and lateral (LAT).

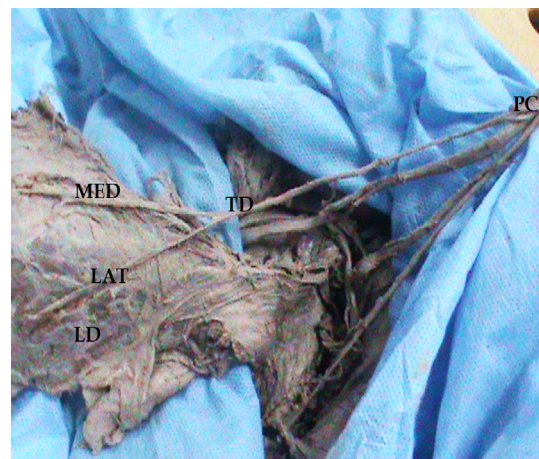


Fig. 8: Photograph of dissected cadaveric axilla showing latissimus dorsi muscle (LD) supplied by thoracodorsal nerve (TD), with two branches pattern of distribution divided into medial (MED) and lateral (LAT) branches. Notice: the origin of the thoracodorsal nerve from posterior cord of brachial plexus (PC).

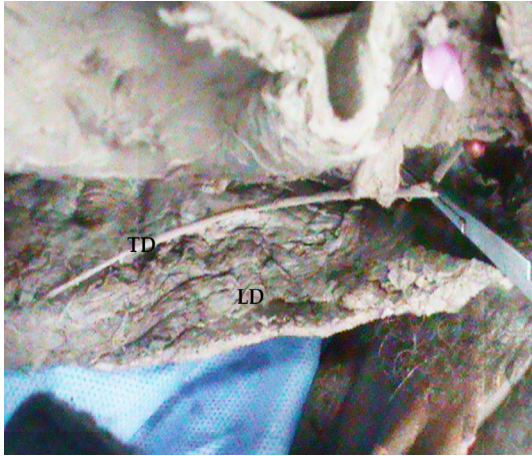


Fig. 9: Photograph of dissected cadaveric axilla right side showing latissimus dorsi muscle (LD), supplied by thoracodorsal nerve (TD).

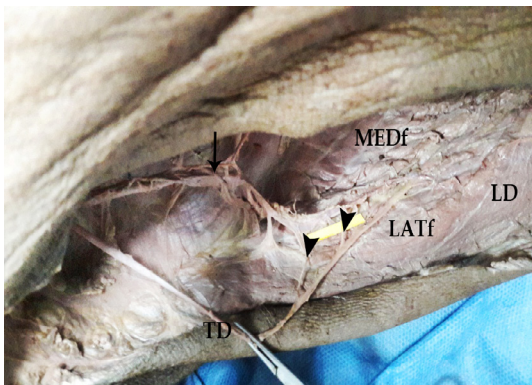


Fig. 10: Same specimen in the previous figure with more dissection showing latissimus dorsi muscle (LD) supplied by thoracodorsal nerve (TD) which continues on the lateral flap (LATf) as one nerve without splitting, thoracodorsal nerve is accompanied by thoracodorsal blood vessels (Black arrow). Notice: Small branches from thoracodorsal nerve (Black arrow head) crossing thoracodorsal blood vessels to supply medial flap (MEDf).

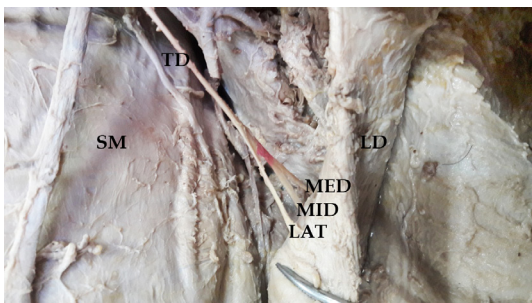


Fig. 11: Photograph of dissected axilla of the same cadaver in previous fig 10 but on the left side axilla showing latissimus dorsi muscle (LD) supplied by thoracodorsal nerve (TD) with three branches pattern, namely, medial (MED), lateral (LAT) and middle (MID) branches. Notice: Serratus anterior muscle (SM).

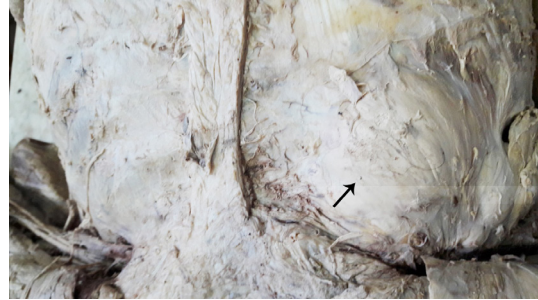


Fig. 12: Photograph of cadaveric right side chest showing enlarged mass (Black arrow).

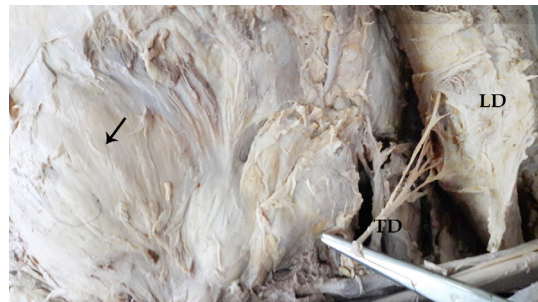


Fig. 13: Photograph of the same specimen in the previous figure with dissection of the right side axilla showing latissimus dorsi muscle (LD) supplied by thoracodorsal nerve (TD), chest mass (Black arrow).

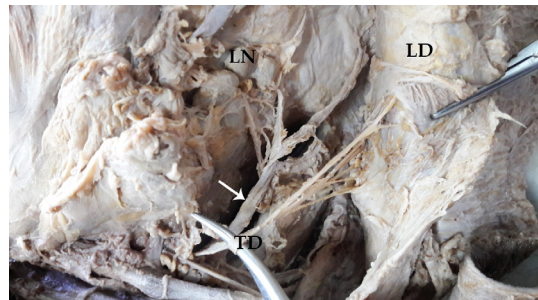


Fig. 14: Photograph of the same specimen in previous figure with more dissection of right axilla showing enlarged axillary lymph nodes (LN), latissimus dorsi muscle (LD) supplied by thoracodorsal nerve (TD) accompanied by thoracodorsal blood vessels (white arrow).

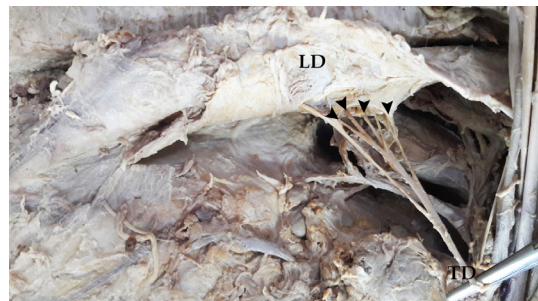


Fig. 15: Photograph of the same right axilla in the previous figure with more dissection showing thoracodorsal nerve (TD) splitted into many branches (Black arrow head) latissimus dorsi (LD).

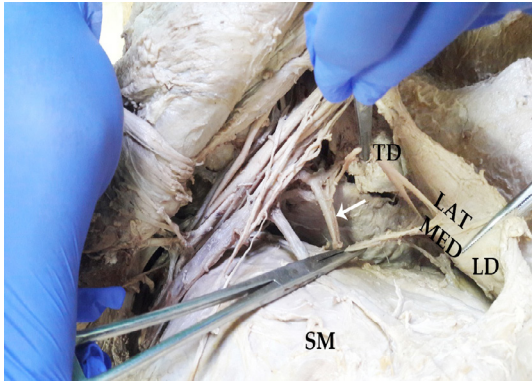


Fig. 16: Photograph of the same cadaver in the previous figure with dissected left side axilla showing latissimus dorsi muscle (LD) supplied by thoracodorsal nerve which is splitted into two branches medial (MED) and lateral (LAT) thoracodorsal blood vessels (white arrow) retracted to show thoracodorsal nerve (TD) clearly, serratus anterior muscle (SM).

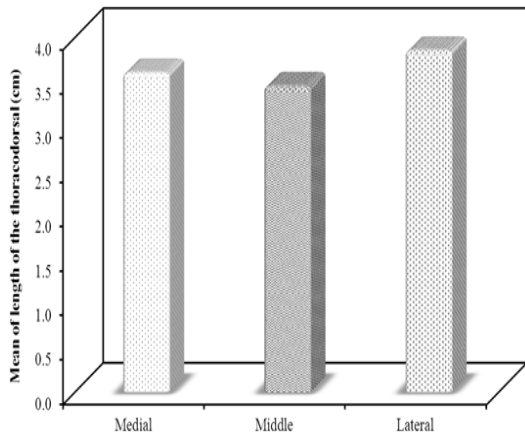


Fig. 17: Comparison between the lengths of the three studied branches of the thoracodorsal n (cm).

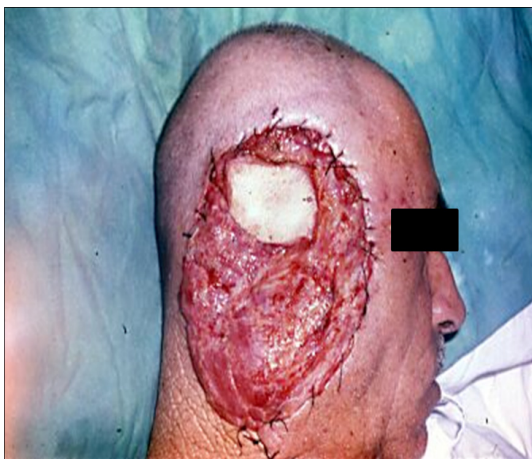

Fig. 18: Photograph showing harvesting large LD flap with dissection of long pedicure to cover raw area after resection of recurrent squamous cell carcinoma in left temporal region

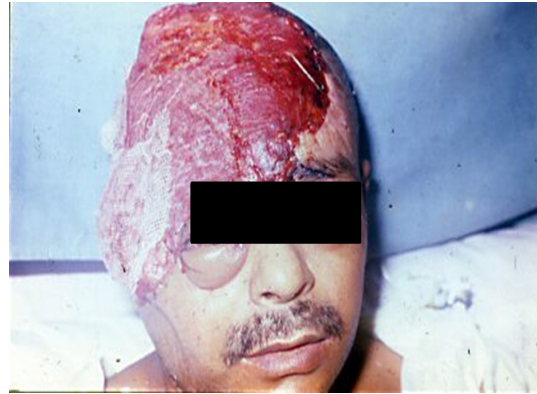

Fig. 19: Photograph showing harvesting large LD flap with dissection of long pedicure to cover raw area after resection of recurrent squamous cell carcinoma in scalp region

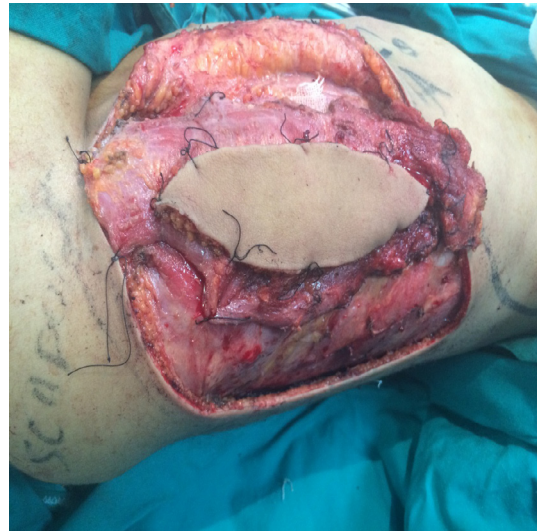

Fig. 20: Photograph showing tacking sutures taken to prevent shearing between muscle and skin paddle

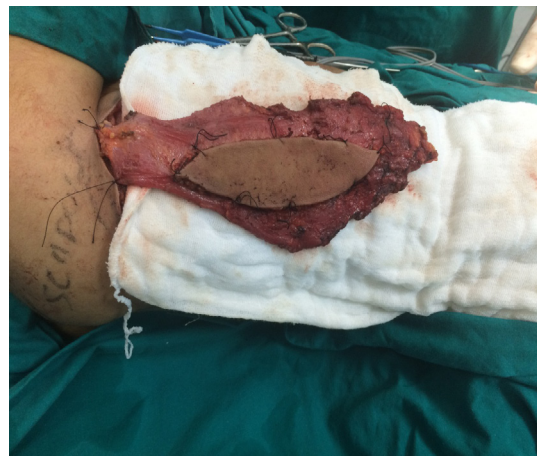


Fig. 21: Photograph showing dissection is completed with pedicle which is marked by silk suture at 12 o'clock

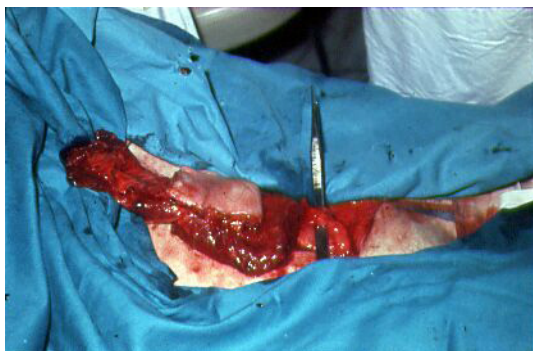


Fig. 22: Photograph showing neurovascular pedicle of latissimus dorsi flap is marked by forceps

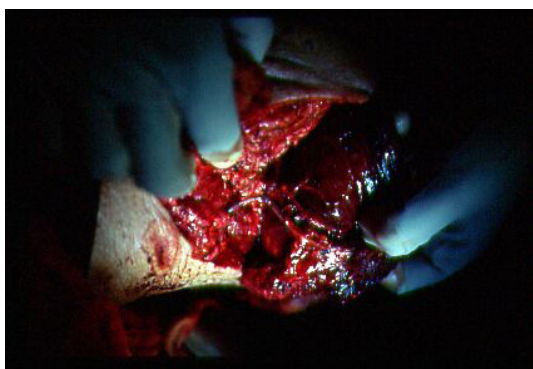


Fig. 23: Photograph showing more individual dissection of neurovascular pedicle of latissimus dorsi flap

Table 1: Comparison between the lengths of the three studied branches of the thoracodorsal n (cm)

	Medial (n = 16)	Middle (n = 16)	Lateral (n = 16)	P
Length of the thoracodorsal (cm)	3.60 ± 1.04	3.45 ± 0.88	3.85 ± 0.95	0.497

Normally quantitative data was expressed in mean ± SD and was compared using F test (ANOVA)

DISCUSSION

Anatomical studies performed in the 1980s (Wong et al. 2007 and Tobin et al. 1981) still is the important source of the Current anatomical knowledge about the latissimus dorsi muscle flap. All of these studies describe only anatomical variations of the latissimus dorsi muscle both externally and internally (Lee KS 2007 and Schwabegger et al. 2003 Wei, et al. 1999).

In addition, most studies concerning the neurovascular pedicle of latissimus dorsi focus on the proximal part of this pedicle from origin till point of splitting. None of these studies, however, report the length of the neuro-vascular pedicle from the splitting point to the point of entrance into the muscle fibers and actually this length is a

major factor influencing the degree of flexibility and more importantly the degree of freedom in reconstructive surgery, using the latissimus dorsi muscle (Meyer 2001).

According to the present study, each part of the muscle can be harvested with approximately 3.5 cm of nerve. Because the medial part of the latissimus dorsi muscle remains innervated and vascularized by the paravertebral perforators. Clinically it would be possible to harvest the lateral part of the latissimus dorsi muscle, with the thoracodorsal artery and vein, and taking 3.5 cm of nerve, without compromising the function of the remaining part of the muscle (Schultes et al. 1999).

Furthermore, sparing of the medial part of the latissimus dorsi muscle thus not only showed a 25 percent increase in patient satisfaction and aesthetic results but also resulted in less reduction of muscle power, mainly at elevation above 90 degrees, abduction, and medial rotation (Ishida et al. 1999).

Furthermore, when taking the whole flap on the thoracodorsal artery and vein, the muscle can be split, and both parts can potentially be innervated by different nerves. Theoretically, a pedicled lateral part of the latissimus dorsi muscle could also be used for biceps reconstruction and innervated by the ulnar nerve (similar to the Oberlin procedure). (Oberlin et al. 1994) to prevent co-contraction between the remaining latissimus dorsi muscle and the neo-biceps.

As the average length of the neurovascular pedicle from split to point of muscle insertion of the lateral flap is about 3 cm. This would give sufficient length for innervated reconstruction and this actually other important reason also for harvesting the lateral part of the latissimus dorsi muscle with less technical difficulties during reconstructive surgery using latissimus dorsi muscle.

The distance from the subscapular artery and vein to the distal split was not measured in this study, although work from Tobin et al. reports an average distance of 8.9 cm (male and female) and 9.1 cm was reported in Bartlett et al.'s study (Bartlett et al. 1981 and Tobin et al. 1981).

The mean length of the thoracodorsal nerve measured from the posterior root to the split was 12.5 cm while 12.3 reported in Bartlett et al. study.

In the present study most of specimens 75%

exhibited three branches pattern of the thoracodorsal nerve in the form medial, lateral and middle branches while *Theeuwes, et al.* study this pattern represented (73 percent).

While the two branches pattern distribution of the thoracodorsal nerve in the form of medial and lateral branches account for 25% of the specimen of the present study while (27 percent) in *Theeuwes, et al.* study.

The one branch pattern found in one specimen and this was in correspondence with *Theeuwes et al.*

In all cases approximately there was no difference in the pattern of distribution of the thoracodorsal nerve on both sides except in one case in which the left thoracodorsal nerve showed the ordinary three branches which is the most common pattern of distribution of thoracodorsal nerve, while on the other side the right thoracodorsal nerve showed many small branches and on this side there was also many branches of the blood vessels, on this side the right one breast mass with enlarged lymph nodes was noticed, this variation in the pattern of distribution might be due to the presence of this pathology on this right side but mechanism and correlation between the presence of breast mass and variation of the distribution pattern of the thoracodorsal nerve and blood vessels needs more study. Different variations of the flap can be considered.

In the present study, the latissimus flap can be done as a chimeric flap as part of the subscapular system, in combination with tissue based on circumflex scapular vessel or serratus branches or can be raised alone. The flap can be tailored to the needs of the recipient defect. The flap can be harvested as a whole or partial muscle. The flap can be harvested as a myocutaneous flap with overlying skin. The flap can even be harvested as a bony flap with underlying 9th or 10th rib. Great care then needs to be taken to not injure underlying pleura or transect the muscular attachments to the rib that supply periosteal blood supply to the harvested rib. These operative findings were in accordance with other researchers (*Wilkman et al. 2014*).

CONCLUSION

The separate neurovascular branches and its minimal pedicle length make the latissimus dorsi muscle very suitable for single functional free muscle transfer, using only the lateral part of the

latissimus dorsi muscle, and double functional free muscle transfer using only one vascular pedicle. In other words the lateral part of the muscle can be used leaving medial part to support the function. Also the most common pattern was three branches make transplantation more easier, there may be correlation between presence of breast mass and variability in the pattern of distribution of the thoracodorsal nerve and accompanying blood vessels.

From surgical points of view, there is strong need for preoperative diagnostic tools to predict the pattern of branching of neuro vascular bundle of latissimus muscle, to help preoperative planning especially in cases as facial reanimation, also in cases that we need more than one muscular functional units, also in cases that we might need to leave portion of muscle for better esthetics and better function of limb movements.

REFERENCES

- Agostini, T., Lazzeri, D., Spinelli, G. 2013.** Anterolateral thigh flap: systematic literature review of specific donor-site complications and their management. *Journal of Cranio-Maxillofacial Surgery*, 41: 15–21.
- Biglioli, F., Frigerio, A., Colombo, V., Colletti, G., Rabbiosi, D., Mortini, P. et al. 2012.** Masseteric-facial nerve anastomosis for early facial reanimation. *Journal of Cranio-Maxillofacial Surgery*, 40: 149-55.
- Biglioli, F., Frigerio, A., Rabbiosi, D., Brusati, R. 2009.** Single-stage facial reanimation in the surgical treatment of unilateral established facial paralysis. *Plastic and Reconstructive Surgery*, 124: 124–133.
- Biglioli, F., Pedrazzoli, M., Rabbiosi, D., Colletti, G., Colombo, V., Frigerio, A. et al. 2013.** Reconstruction of complex defects of the parotid region using a lateral thoracic wall donor site. *Journal of Cranio-Maxillofacial Surgery*, 41: 265-269.
- Buntic, R. Atlas of microsurgery techniques and principles 2001-2007.**
- Gülekon, N., Peker, T., Turgut, H.B., Anil, A., Karaköse, M. 2007.** Qualitative comparison of anatomical microdissection, Sihler's staining and computerized reconstruction methods for visualizing intramuscular nerve branches. *Surgical and Radiologic Anatomy*, 29: 373–378.

- Harii, K., Asato, H., Yoshimura, K., Sugawara, Y., Nakatsuka, T., Ueda, K. 1998.** One-stage transfer of the latissimus dorsi muscle for reanimation of a paralyzed face: a new alternative. *Plastic and Reconstructive Surgery*, 102: 941–951.
- Hayashi, A., Maruyama, Y. 2005.** Neurovascularized free short head of the biceps femoris muscle transfer for one-stage reanimation of facial paralysis. *Plastic and Reconstructive Surgery*, 115: 394–405.
- Iida, T., Nakagawa, M., Asano, T., Fukushima, C., Tachi, K. 2006.** Free vascularized lateral femoral cutaneous nerve graft with anterolateral thigh flap for reconstruction of facial nerve defects. *Journal of Reconstructive Microsurgery*, 22: 343–348.
- Ishida, A., Schmidt, A., Fromberg, G., Muckley, I. 1999.** Donor site morbidity: Standard versus partial latissimus dorsi free flap. *Annals of Plastic Surgery*, 22: 362–365
- Iwasawa, M., Kitazawa, T., Narimatsu, I. 2002.** Split thoracodorsal nerve funicular graft combined with functional latissimus dorsi musculocutaneous flap transfer for immediate facial reanimation after tumor ablation. *Annals of Plastic Surgery*, 48: 428–430.
- Jiang, H., Guo, E.T., Ji, Z.L., Zhang, M.L., Lu, V. 1995.** One-stage microneurovascular free abductor hallucis muscle transplantation for reanimation of facial paralysis. *Plastic and Reconstructive Surgery*, 96: 78–85.
- Koshima, I., Moriguchi, T., Soeda, S., Hamanaka, T., Tanaka, H., Ohta, S. 1994.** Free rectus femoris muscle transfer for one-stage reconstruction of established facial paralysis. *Plastic and Reconstructive Surgery*, 94: 421–430.
- Koshima, I., Nanba, Y., Tsutsui, T., Takahashi, Y., Itoh, S. 2004.** New one-stage nerve pedicle grafting technique using the great auricular nerve for reconstruction of facial nerve defects. *Journal of Reconstructive Microsurgery*, 20: 357–361.
- Koshima, I., Tsuda, K., Hamanaka, T., Moriguchi, T. 1997.** One-stage reconstruction of established facial paralysis using a rectus abdominis muscle transfer. *Plastic and Reconstructive Surgery*, 99: 234–238.
- Lee, K.S. 2007.** Variation of the spinal nerve compositions of thoracodorsal nerve. *Clinical Anatomy*, 20: 660–662.
- Lee, S.J., Lim, A.Y., Lim, I.J., Lim, T.C., Pho, R.W. 2008.** Innervation of the face studied using modifications to Sihler's technique in a primate model. *Plastic and Reconstructive Surgery*, 121: 1188–1205.
- Li, B.H., Jung, H.J., Choi, S.W., Kim, S.M., Kim, M.J., Lee, J.H. 2012.** Latissimus dorsi (LD) free flap and reconstruction plate used for extensive maxillo-mandibular reconstruction after tumour ablation. *Journal of Reconstructive Microsurgery*, 39: e293–e300
- Lu, W., Xu, J.G., Wang, D.P., Gu, Y.D. 2008.** Microanatomical study on the functional origin and direction of the thoracodorsal nerve from the trunks of brachial plexus. *Clinical Anatomy*, 21: 509–513.
- Meyer, R.A. 2001.** Nerve harvesting procedures. *Atlas of Oral and Maxillofacial Surgery Clinics of North America*, 9: 77–91.
- Muthoka, J.M., Sinkeet, S.R., Shahbal, S.H., Matakwa, L.C., Ogeng'o, J.A. 2011.** Variations in branching of the posterior cord of brachial plexus in a Kenyan population. *Journal of Brachial Plexus and Peripheral Nerve Injury*, 6: 1.
- Oberlin, C., Be' al, D., Leechavengvongs, S., Salon, A., Dauge, M.C., Sarcy, J.J. et al. 1994.** Nerve transfer to biceps muscle using a part of ulnar nerve for C5 C6 avulsion of the brachial plexus: Anatomical study and report of 4 cases. *Journal of Hand Surgery*. 19: 232–237.
- Peker, T., Gülekon, N., Turgut, B.H., Anil, A., Karaköse, M., Mungan, T., et al. 2006.** Observation of the relationship between the shape of skeletal muscles and their nerve distribution patterns: a transparent and microanatomic study. *Plastic and Reconstructive Surgery*, 117: 165–176.
- Saddler, T.W. 2006.** Brachial plexus. In: Saddler TW, eds. *Langman's Medical Embryology*. 10th ed. Philadelphia: Lippincott Williams and Wilkins; pp 146-147.

- Schultes, G., Gaggi, A., Kärcher, H. 1999.** Reconstruction of accessory nerve defects with vascularized long thoracic vs. non-vascularized thoracodorsal nerve. *Journal of Reconstructive Microsurgery*, 15: 265–270.
- Schwabegger, A.H., Harpf, C., Rainer, C. 2003.** Muscle-sparing latissimus dorsi myocutaneous flap with maintenance of muscle innervation, function, and aesthetic appearance of the donor site. *Plastic and Reconstructive Surgery*, 111: 1407–1411.
- Standring, S. 2008.** Brachial plexus. In: Standring S, eds. *Gray's anatomy. The Anatomical Basis Of Clinical Practice*. 40th ed. London: Elsevier Churchill Livingstone; pp 821–822.
- Takushima, A., Harii, K., Asato, H., Momosawa, A., Okazaki, M. 2006.** One-stage reconstruction of facial paralysis associated with skin/soft tissue defects using latissimus dorsi compound flap. *Journal of Plastic, Reconstructive and Aesthetic Surgery*, 59: 465–473.
- Takushima, A., Harii, K., Asato, H., Ueda, K., Yamada, A. 2004.** Neurovascular free-muscle transfer for the treatment of established facial paralysis following ablative surgery in the parotid region. *Plastic and Reconstructive Surgery*, 113: 1563–1572.
- Terzis, J.K. 1989.** Pectoralis minor: a unique muscle for correction of facial palsy. *Plastic and Reconstructive Surgery*, 83: 767–776.
- Theeuwes, H.P., Gosselink, M.P., Bruynzeel, H., Kleinrensink, G.J., Walbeehm, E.T. 2011.** An anatomical study of the length of the neural pedicle after the bifurcation of the thoracodorsal nerve: implications for innervated free partial latissimus dorsi flaps. *Plastic and Reconstructive Surgery*, 127: 210–214.
- Tobin, G.R., Schusterman, M., Peterson, G.H., Nichols, G., Bland, K.I. 1981.** The intramuscular neurovascular anatomy of the latissimus dorsi muscle: The basis for splitting the flap. *Plastic and Reconstructive Surgery*, 67: 637–641.
- Wang, W., Qi, Z., Lin, X., Hu, Q., Dong, J., Zhou, L., et al. 2002.** Neurovascular musculus obliquus internus abdominis flap free transfer for facial reanimation in a single stage. *Plastic and Reconstructive Surgery*, 110: 1430–1440.
- Wei, W., Zuoliang, Q., Xiaoxi, L., Jiasheng, D., Chuan, Y., Hussain, K., et al. 1999.** Free split and segmental latissimus dorsi muscle transfer in one stage for facial reanimation. *Plastic and Reconstructive Surgery*, 103: 473–480.
- White, W.M., McKenna, M.J., Deschler, D.G. 2006.** Use of the thoracodorsal nerve for facial nerve grafting in the setting of pedicled latissimus dorsi reconstruction. *Otolaryngology-Head and Neck Surgery*, 135: 962–964.
- Wilkman, T., Suominen, S., Back, L., Vuola, J., Lassus, P. 2014.** The pedicled latissimus dorsi flap in head and neck reconstruction: an old method revisited. *Journal of Reconstructive Microsurgery*, 30: 163–170.
- Wong, M.T., Lim, A.Y., Coninck, C.D., Kumar, P.V. 2007.** Functional units within the latissimus dorsi muscle based on Sihler technique. *Annals of Plastic Surgery*, 59: 152–155.

دراسة تشريحية لطول العنق العصبى للعضب الصدرى الظهرانى بعد انقسامه

عبير أحمد^١، ياسر الشيخ^٢

اقسم التشريح وعلم الأجنة، كلية الطب، جامعة الإسكندرية
اقسم جراحه التجميل ، كلية الطب، جامعة المنوفية

ملخص البحث

الخلفية البحث: تعتبر العضلة الظهرية العريضة حجر الأساس والعضلة الأكثر أهمية في الجراحة التجميلية المستخدمة في العديد من الخطوات الجراحية الترميمية المولية متفاوتة من اعاده تشكيل الوجه و ترميم الثدي كذلك ترميم الاطراف الخلفية. انه من الضروري ان يكون عندك معرفه عن نمط تفرع التوزيعات وطول العصب الصدرى الظهرانى من بعد انقسامه الذي هو العصب المغذى للعضلة الظهرية العريضة الثمينه. للحصول على اجراءات زرع العضلات الوظيفيه المغذاه عصبيا، وطول السويقات العصبية المتاحة للمفاغرة العصبية أمر بالغ الأهمية.

الهدف من العمل: التحقيق في تضاريس و نمط تفرع العصب الصدرى الظهرى، وكذلك قياس طوله بعد انقسامه

المواد والطرق: ستة عشر من العضلات الظهرية العريضة تم تشريحها فى ثمان جثث ادميه بالغه فى قسم التشريح بكلية الطب جدامعه الاسكندريه و الحزمه العصبية الدمويه الصدرية الظهرانية تم تشريحها و نمط تفرعها تم اكتشافه و تم شريح التفرعات وصولا الى الضله الظهرية العريضة و ايضا داخلها و كل الاطوال تم قياسها بمقياس فرنيه.

النتائج: كان متوسط طول الفرع الانسى هو ٣,٤٥ سم (المدى، ١,٨٠ و ٥,٥ سم، متوسط، ٣,٦٠ سم، SD، ١,٠٤ و ١,٠٤ سم). كان متوسط طول الفرع الوسطى ٣,٥٠ سم (المدى ٢,٤-٥,٦٥ سم؛ متوسط ٣,٤٥ سم، SD، ٠,٨٨ و ٠,٨٨ سم)، أظهر الفرع الوحشى متوسط طول ٣,٩٩ سم (المدى ٢,٥-٥,٩٥ سم، متوسط، ٣,٨٥ سم، SD، ٠,٩٥ و ٠,٩٥ سم)

وكان متوسط طول العصب الصدرى الظهرى مقاسا من الجذر الخلفى للانقسام ١٢,٥ سم و بالنسبه لنمط تفرع العصب الصدرى الظهرانى اختلف ما بين نمط ثلاثة فروع فى 75%، نمط فرعين فى 23% من العينات وفى حالة واحدة كما فرع واحد على الحدود الجانبية للعضلة العريضة الظهرية فى عينة واحدة أخرى أعطى العصب الظهرى الصدرى العديد من الفروع وفى هذه العينة لوحظ وجود ورم فى منطقه الثدي على نفس الجانب لهذا العصب الصدرى الظهرانى.

وأظهرت الأوردة والشرايين نمطا مماثلا للتفرعات، و متوسط طولها مشابه لتلك التي فى العصب الصدرى الظهرانى.
الاستنتاجات: التفرعات العصبية الدمويه والحد الأدنى لطول العنق العصبى يجعل العضله الظهرية العريضة مناسبه جدا للنقل الحر المنفرد للعضله الوظيفيه مستخدما الجزء الوحشى فقط من العضله الظهرية العريضة و النقل الحر المضاعف للعضله الوظيفيه مستخدمين فقط عنق دموى واحد و هذا يرجح نقل العضله الظهرية العريضة المغذاه عصبيا المتعدد وقد سهل هذا نمط تفرع العصب الصدرى الظهرى . و من المحتمل وجود علاقه بين نمط تفرع العصب الصدرى الظهرانى ووجود كتله فى منطقه الثدي وهذا يحتاج الى مزيد من البحث. و من وجهة النظر الجراحية هناك حاجة قوية لأدوات التشخيص قبل الجراحة للتنبؤ بنمط متفرعة من الحزمة العصبية الوعائية للعضلة الظهرية العريضة، للمساعدة فى التخطيط قبل الجراحة وخاصة فى حالات إعادة الوجه، وأيضا فى الحالات التي نحن بحاجة إلى أكثر من وظيفة واحدة لوحدات العضلات ، وأيضا فى الحالات التي قد نحتاج إلى ترك جزء من العضلات للحصول على جماليات أفضل و وظيفة أفضل من حركات الأطراف