

<b>Original Article</b>	<b>Effects of 4-tert-octylphenol on the kidney and the liver of the adult male albino rat: A histological and biochemical study</b>
	<b>Lobna F. Wahman<sup>1,2</sup>, Abeer A. Elsiddig<sup>3</sup>, Maha K. Desouky<sup>4,5</sup> and Madeha A. El-Sawaf<sup>6</sup></b>

<sup>1</sup>Department of Physiology; National Organization for Drug Control and Research (NODCAR)  
<sup>2</sup>Department of Physiology; Faculty of Medicine; Taibah University  
<sup>3</sup>Department of Pathology, Faculty of Medicine; Taibah University  
<sup>4</sup>Department of Human Anatomy and Embryology, Faculty of Medicine; Taibah University  
<sup>5</sup>Department of Human Anatomy and Embryology, Faculty of Medicine, Alminia University  
<sup>6</sup>National Organization for Drug Control and Research (NODCAR)

#### ABSTRACT

**Background:** Bisphenol A (BPA) and Octylphenol (OP) have been shown to increase the oxidative stress in the body by upsetting the ratio balance of prooxidant and antioxidant in the cells. Reactive oxygen species (ROS) are cytotoxic agents that caused damage of nucleic acid bases, lipids and proteins, in turn lead to cell death. So the current work aimed to investigate the potential toxic effects of 4-tert-octylphenol (OP) exposure on liver, kidney, reactive oxygen species (ROS) and hematologic parameters of adult male albino rats.

**Material and Methods:** The total number of the animals used was 36 rats. The age of the used rats was 60-75 days. The groups were divided into; 12 control rats, 24 rats received the treatment; half of them had the low dose and the other 12 had the high dose treatment. The rats were treated with 4-OP in orally low dose (10 µg/kg/day) and high dose (450 mg/kg/b.w.daily). (b.w. means the body weight). After 4 weeks of treatment blood samples were withdrawn for biochemical and hematological analysis. Also the liver and kidney were investigated histopathologically.

**Results:** The administration of OP resulted in a significant elevation in serum urea and creatinine and blood urea nitrogen (BUN) level after administration of both low and high doses. The obtained data revealed a significant increase in liver function Aspartate Aminotransferase (ASAT) & Alanine Aminotransferase (ALAT) as well as reduction in total protein content in target tissues of all treated groups and this confirmed by the histopathological study. Significant elevation of malondialdehyde (MDA) levels with a reduction in tissues reduced superoxide dismutase (SOD) in the kidney and liver tissue. The total blood count and other blood parameters showed significant variations after 4-OP administration. The liver and the kidney deteriorated with the increasing doses and the duration of the treatment, showing glomerular lobulation, mild interstitial fibrosis and tubular cytoplasmic degeneration in the kidney, while the liver showed mild venous and sinusoidal congestion along with bile duct proliferation and mild fatty change.

**Conclusion:** The findings of the present study raise the possibility of hepatic, renal and hematological effects exerted by 4-OP.

**Received:** 01 May 2017, **Accepted:** 01 June 2017

**Key Words:** Blood count, Kidney, liver, male albino rat, Octylphenol, ROS

**Corresponding Author:** Lobna F. Wahman, Associate Professor of Physiology, National Organization for Drug Control and Research (NODCAR), **Tel.:** +9 66538290160, **E-mail:** Lobo2003@hotmail.com

**The Egyptian Journal of Anatomy, ISSN:** 0013-2446, Vol. 41. No. 1

#### INTRODUCTION

Alkylphenol ethoxylates (APEOs) are widely used as non-ionic surfactants which added to detergents, toiletries, herbicides, and many other every-day use products. These products degraded into alkylphenols (APs) during wastewater

treatment (Hernandez-Rodriguez et al., 2006).

Nonylphenol (NP) and 4-octylphenol (4OP), have been described in sewage effluent, groundwater and drinking waters (Céspedes et al., 2008 and Lavado et al., 2005). Many studies considered APs as xenoestrogens and endocrine

disruptors because of their capacity to affect reproductive development in humans

Alkylphenols (APs) and their metabolites are lipophilic substances exerting apparent estrogenic action in vitro and in vivo testing systems. With the widespread industrial use of alkylphenols, these are disseminated in the environment with sewage sludge. There is evidence showing that alkylphenols can accumulate in vivo, at least in the fish. Domestic animals and human are likely to be exposed via the food chain (Bian et al., 2006).

Among APs, 4-tert-octylphenol (OP), 4-nonphenol (NP) and bisphenol A (BPA) deserve particular attention because of their estrogenic activity (Blake et al. 2004, Lee and Peart 2002, Meeesters and Schröder 2002). 4-tertiary-octylphenol (4-tert-OP) is an alkylphenol that affects human health by stimulating free radical production resulting in oxidative deterioration of lipids, proteins and DNA, and many pathological conditions in humans and animals. Moreover, it has been shown that, both in vivo and in cultured hepatocytes, in parallel to liver damage, octylphenol may also cause a detectable fragmentation of nuclear DNA and karyolysis (Kim et al. 2006 and Saleh, 2012).

Octylphenol (OP) is an important intermediate in the production of a number of commercial materials. The major use of OP is for the production of alkylphenol ethoxylates (OPE), a class of nonionic surfactants with a wide range of applications (Pocar et al. 2003).

Finally, exposure to 4-tert-octylphenol may result in effects that relevantly influence ecosystems with respect to the community structure and function. Comparable to other estrogens, 4tert-octylphenol influences reproduction parameters as well as sexual development and growth. So this study aimed to investigate the nephrotoxicity and hepatotoxicity as well as the hematological effect of 4-tert-octylphenol (OP) in male albino rats.

## **MATERIAL AND METHODS:**

### **MATERIALS:**

#### **I- Biological Study Materials**

##### **1- Experimental Animals**

Adult male albino rats weighing 200-250 were used in this study. The animals' acclimatization took one week before the experimentation. The

animals were fed on standard diet and water libitum.

#### **2-Doses under study**

There are two doses used in this work; high dose (450 mg/kg/day) (Qian Bian et al., 2006) and the low dose (10 µg/kg/b.w./day) (Bogh et al., 2001). The standard 4- tert-octylphenol was purchased from Sigma Aldrich. The substance was dissolved in corn oil and the concentration was adjusted to obtain desired concentration.

#### **3- Experimental Design**

The rats were classified into the following groups: Group 1: Negative control group): 12 rats received corn oil. Group 2 (Low dose treated-group): 12 rats were orally administered 10 µg/kg/day of 4-tert-octylphenol once daily for 4 weeks. Group 3 (High dose treated – group): 12 rats were orally administered 450 mg/kg/b.w./day of 4-tert-octylphenol once daily for 4 weeks.

#### **4- Blood sampling**

- The blood samples were withdrawn from the animals after 1, 2, 3 and 4 weeks of 4- tert-octylphenol treatment. The blood collected from retro- orbital plexuses according to method of Shermer (1968) and left to coagulate.
- At the end of experiment duration (4 weeks), the animals were sacrificed and the target organs (kidney and liver) were collected; weighted and divided into two parts one for tissue biochemical investigation and the other parts was kept in 10 % formalin and submitted for histopathological studies.

#### **5- Study Parameters**

1. The serum was separated for determination of liver function tests; Aspartate Aminotransferase (ASAT) and Alanine Aminotranseferase (ALAT) and Kidney functions tests (urea and creatinine ) and Blood Urea Nitrogen (BUN) and Total proteins .
2. Hematological analysis
3. Malondialdehyde (MDA) and Superoxide dismutase ( SOD)
4. Body and relative organs weight
5. Histopathology of liver and kidney

## METHODS

### 1-Biochemical and hematological Parameters:

The activity of both serum Aspartate and Alamine aminotransferase (ASAT and ALAT) were measured by using Reitman and Frankel (1957) method. Serum urea was measured using the colorimetric method of Fawcett and Soctt (1960), while creatinine measured by method of *Schirmeister et al. (1964)*. Blood Urea Nitrogen (BUN) was estimated by the modified Urease Berthelot method. Blood samples were collected and put in the tubes with EDTA and analyzed for hematologic parameters white blood cell counts, deferential leukocytes, red blood cell counts (RBCs), mean corpuscular volume (MCV), hematocrit (PCV), mean corpuscular hemoglobin (MCH), mean corpuscular hemoglobin concentration (MCHC), and platelets.

### 2-Processing of Tissues and Assays:

The liver was homogenated (10% w/v) in Tris-HCl (0.1M, pH 7.4). Homogenates were centrifuged at 1000×g for 10 minutes at 4°C. The supernatant was used for investigating total protein, activities of antioxidant enzymes, and markers of oxidative stress. Total protein concentration was estimated using bovine serum albumin as a standard (*Lowry et al. 1951*). Malondialdehyde (MDA) determined in kidneys and liver tissue homogenates according to the procedure described by *Ohkawa et al. (1979)*. Superoxide dismutase (SOD) activities were determined in kidneys and liver in tissue homogenates according to *Nishikimi et al. (1972)*.

### 3- Histopathological examination of tissues.:

The target organs (Kidney and liver) of both control and treated groups were freshly collected directly after dissection and immediately transferred to 10% formalin solution for fixation. After 24 hours, the specimens were washed, dehydrated in ascending grades of alcohol, cleared in xylene and embedded in paraffin. The paraffin blocks were cut into sections each of 6 microns thick, using microtome. For staining, the paraffin sections were deparaffinized in xylene, then hydrated. Staining was done by using hematoxyline and eosin. After staining the sections were dehydrated in alcohol, cleared in xylene and mounted with Canada balsam (*Culling, 1974*).

### 4 -Statistical Method:

The result were shown as mean ± (SE). Statistical analysis was performed using SPSS 9.0

for multiple comparisons; multi- way analysis of variance (ANOVA) was used. In cases ANOVA showed a significant difference, post hoc analysis was performed with least significant. P 0.05 was considered statistically significant.

## RESULTS

### I-Haematological and Biochemical Results

The total body weight after low dose of 4-OP treatment did not exhibits significant change as compared with initial body weight. On the other hand, the high dose induced significant reduction of the total body weight. Regarding the relative organ weight; the result showed a decrease in relative weight of kidney and liver after both of low and high dose administration (Table 1). As shown in (Table 2) and (Fig. 1); low and high dose of 4-OP revealed a highly significant increase in urea level during the all weeks of treatment ( $P<0.01$ ) as compared with the corresponding control. Looking to Creatinine and blood urea nitrogen (BUN) level, the two tested doses of OP showed highly significant increase ( $P<0.01$ ) in their levels throughout the treatment period. These biochemical results of urea and creatinine was confirmed by the changes observed in kidney renal tubules and glomerular tufts as described in histological (Figs. 6,7,8 & 9)

(Fig. 2) and (Table 3) illustrate the effect of the two tested doses of OP on ASAT and ALAT. The regimens used of OP showed significant increase ( $P<0.05$ ) in ALAT level especially throughout the third and fourth week of treatment. Similarly, the high dose of OP had stronger effect than the low dose because it resulted in highly significant elevation in the ASAT ( $p<0.01$ ) during all weeks. The low dose increased the ASAT significantly ( $p<0.05$ ) during the first and second weeks but the third and fourth weeks showed further significantly increment ( $P<0.01$ ). Total protein content in liver tissues was severely reduced in 4-OP treated groups as compared with control group (Table 4). This elevation in ASAT, ALAT and decreasing total protein were accompanied by obvious histopathological changes in form of hepatocyte necrosis, hyaline bodies formation and increased inflammatory infiltrate as shown in (Figs. 11,12,13,14,15).

Concerning the Tissue perioxdation product (MAD) and antioxidant defense system (SOD), the low and high doses of 4 - OP induced highly significant elevation in the level of the oxidative

stress marker MAD in kidney and liver tissue as compared with control. On the other hand as a consequence of 4- OP treatment; the generation of the antioxidant and free radical in kidney and liver tissue was affected and reduced significantly as compared with control (Table 4)

Hemoglobin as packed cell volume (hematocrit) percent showed highly significant decrease after prolonged administration of 4-OP. Similarly, MCV showed a highly significant reduction in its value after 30 days of low and high 4-OP administration while after 15 days there is novaluable changes (Table 5 and Fig. 3). Both low and high doses of OP did not affect the MCHC level throughout the treatment period. MCH level showed significant decrease after 30 days of high dose treatment but the low dose did not exhibit any changes as shown in (Table 5) and (Fig. 3).

Total erythrocytes count (RBCs) showed highly significant decrease after administration of both low and high dose of OP for 30 days as illustrated in fig ? and table (6). Meanwhile after 15 days of OP administration the high dose is the one who was affected. As shown in Table 6 and Fig. 4,, the monocytes recorded an observable elevation after treatment with a high dose of OP. On the other hand, the low OP did not cause a significant change after 15 days and a slight decrease after 30 days. Total leucocytes count significantly decreased post 15 and 30 days administration of a high dose OP, while the low dose did not exhibited any significant change. Lymphocytes and granulocytes count showed a highly significant elevation throughout the treatment period with both doses (Table 6 and Fig. 4). On the other hand platelets count significantly decreased after 15 and 30 days post low and high dose OP administration.

### II- Histopathological findings in the kidney

Light microscopic examination of the kidney of the control rats revealed normal glomerulus with thin glomerulus basement membrane,

normal cellularity and patent capsular space, the surrounding tubules (proximal and distal), interstitium and blood vessels were normal (Fig. 5). In the Low dose group, most of the kidney tissues from the animals revealed normal staining and morphological characters, however mild changes in form of mild congestion, and lobulation of some of glomerular tufts, widening of bowman's spaces in most of renal corpuscles, could be observed. Mild fibrosis in interstitial space could be detected. Occasional renal tubules showed cytoplasmic degenerative changes (Fig 6). On the other hand, high dose treatment showed mild to moderate pathological changes in the form of widening of many of the renal tubules, which were lined by flattened epithelium, and several of them contain dense eosinophilic casts. Glomerular tufts with a congestion and a mild mesangium cell proliferation could be detected. (Figs. 7 & 8 & 9)

### III- Histopathological findings in the liver

Sections of the control liver showed the central vein with radiating cords of liver cells. The liver cells had vesicular nuclei and granular cytoplasm. Blood sinusoids were evident between the cords of liver cells (Fig. 10). Histopathological examination of liver of (low dose-treated group), revealed normal liver architecture, however mild pathological effects were detected in the form of dilation of few central veins, few portal areas showed congested dilated portal veins, proliferated bile ducts and edema, along with congested sinusoids. Most of hepatocytes appear normal, however, some showed a cytoplasmic vacuolation in the periportal areas, with occasional hyaline body formation (Figs. 11 & 12). More toxic impact was observed in liver tissues of high dose-treated animals, beside the previous observation, fatty degenerative changes appear more prominent in many hepatocytes, proliferative van kupffer cells, aggregation of hyaline bodies could also be observed (Figs. 13, 14 &15)

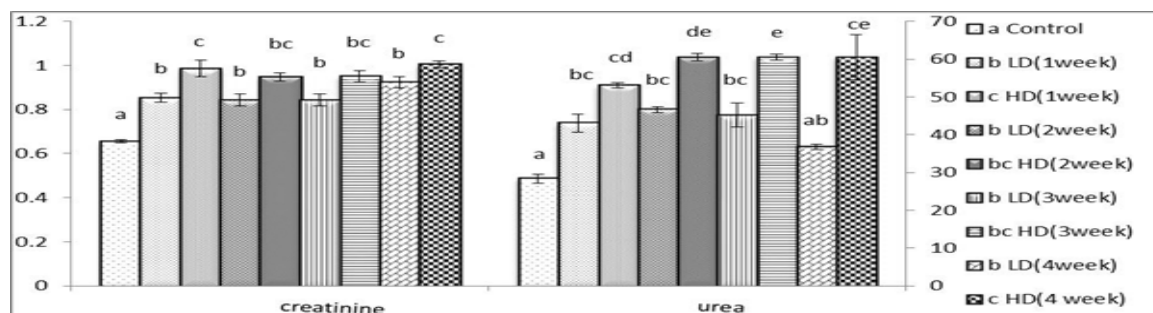


Fig. 1: A bar histogram showing the effect of daily administration of low and high doses of OP on the kidney function in male albino rats.

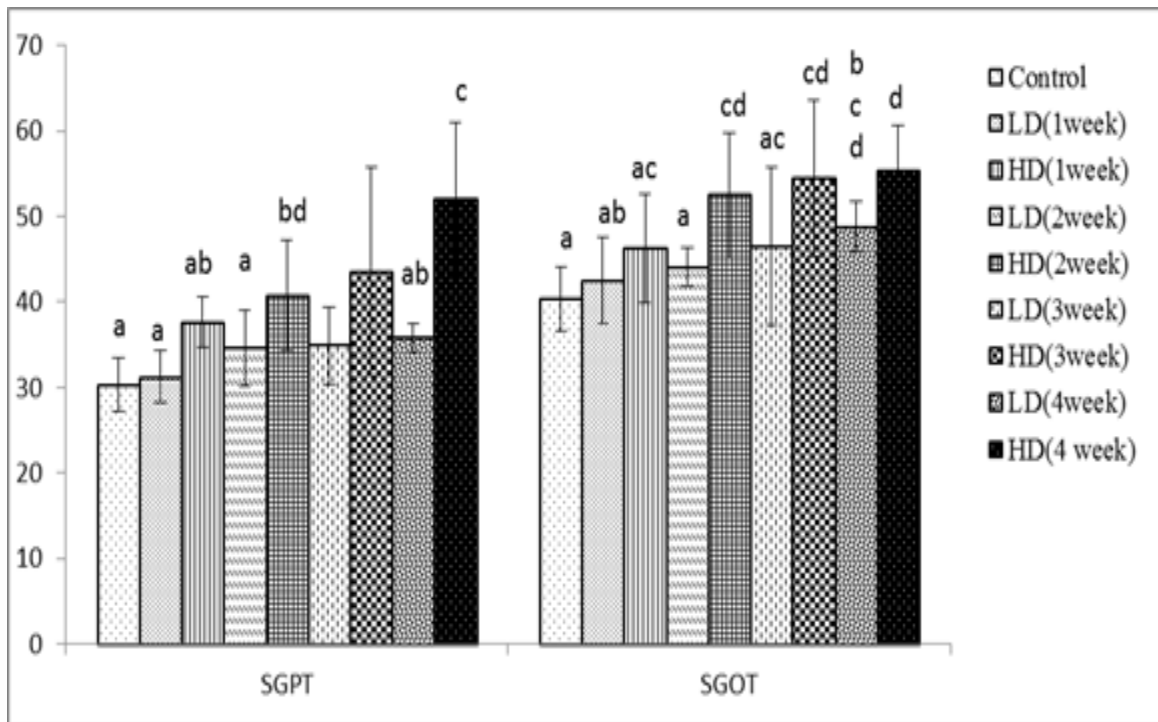


Fig. 2: A histogram showing the effect of daily administration of compound OP on liver function in the male albino rat for consecutive 4 weeks

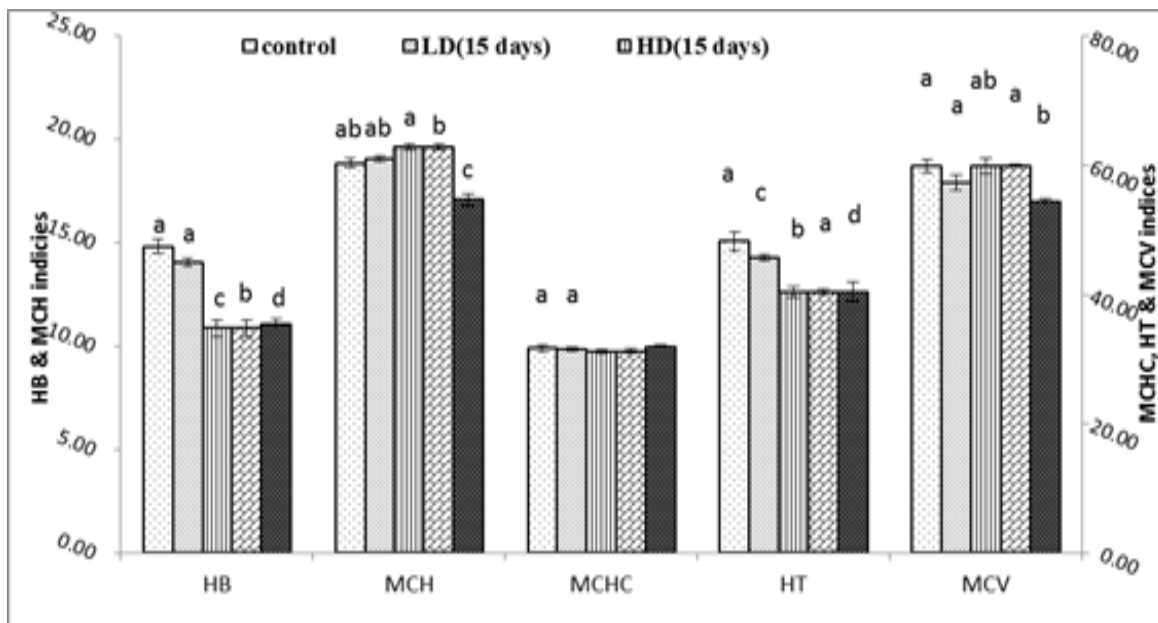


Fig. 3: A bar histogram showing the effect of daily administration of OP with low and high doses on the levels of hematological indices in the male albino rat during 15 and 30 days

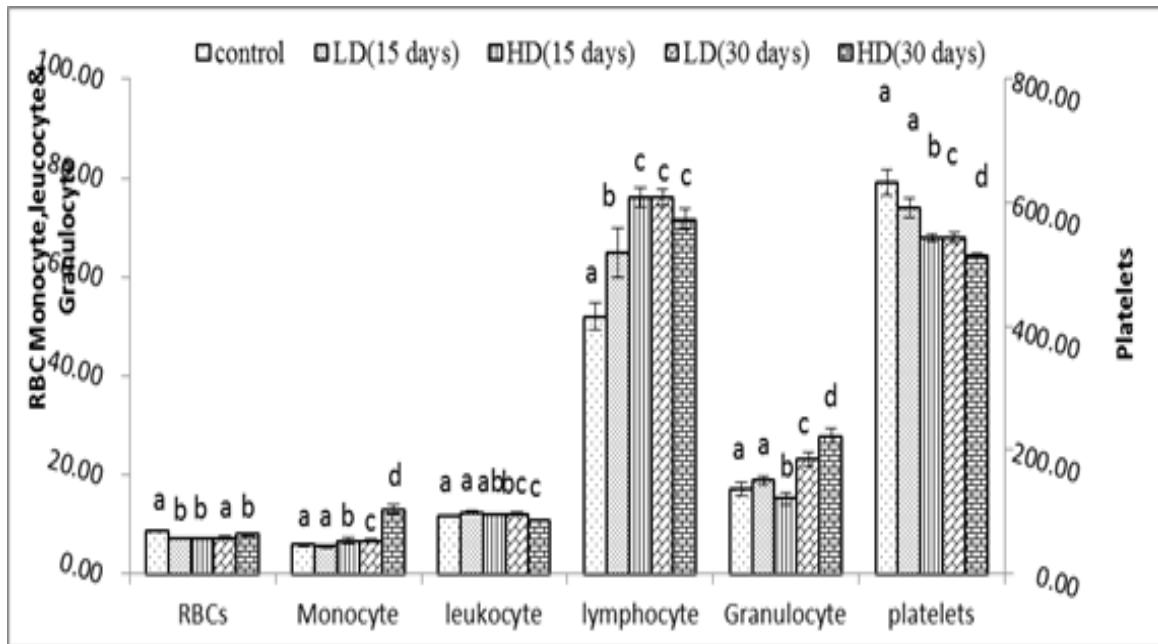


Fig. 4: A bar histogram showing the effect of the daily administration of OP with low and high doses on the levels of blood elements in the male albino rat during 15 and 30 days

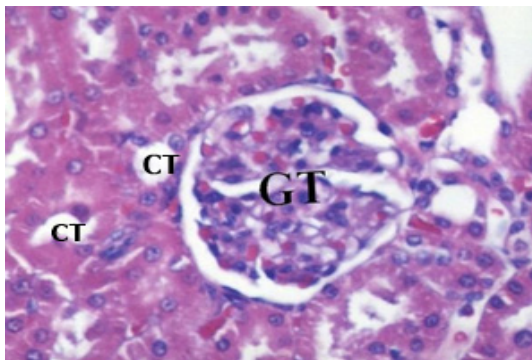


Fig: 5: A photomicrograph of the kidney tissue of the control-rat, showing intact glomerular tuft (GT) and normal convoluted tubule (CT) H&E, X 400

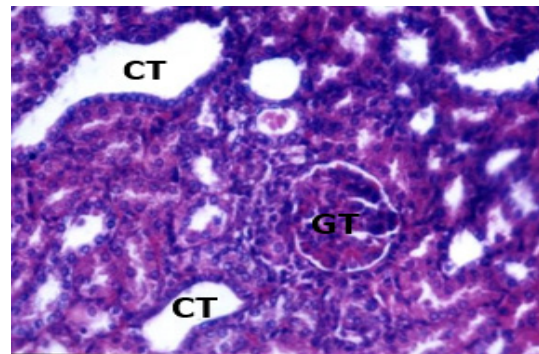


Fig 7: A photomicrograph of kidney tissue of a high dose-treated rat, showing congested and lobulated glomerular tuft (GT), convoluted tubule (CT) with atrophied cytoplasm and a widening of the lumen H&E, X:200

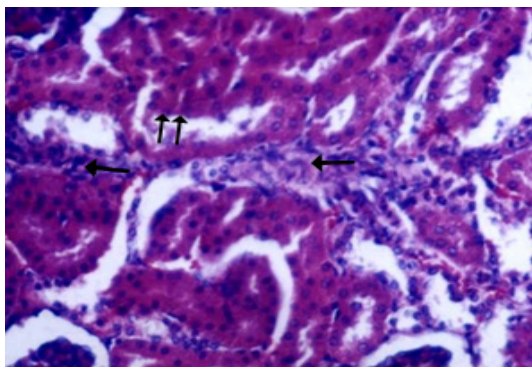


Fig: 6: A photomicrograph of the kidney tissue of a low dose-treated rat, showing focal mild fibrotic changes in interstitial spaces (arrow), flattened epithelial cell lining convoluted tubules (double arrow) H&E X:200

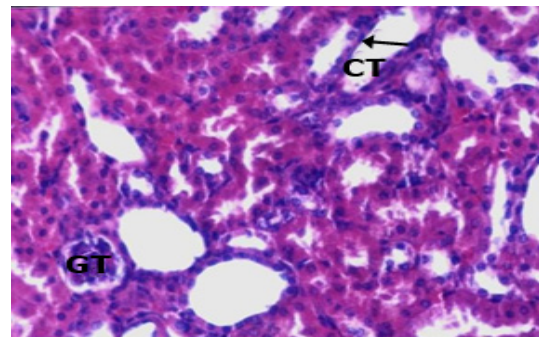
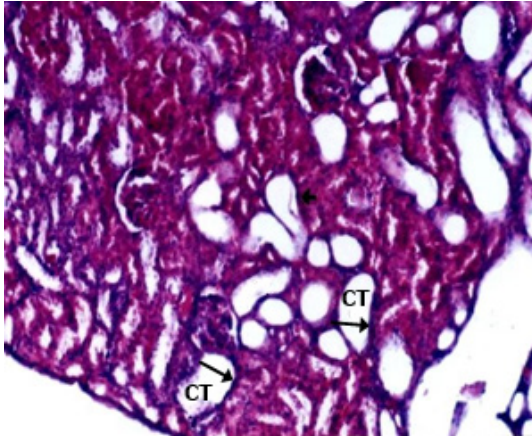
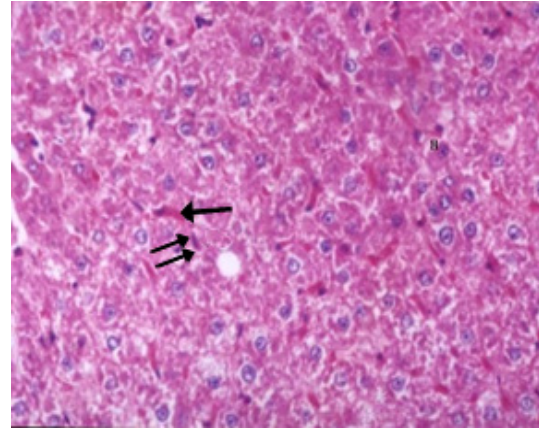


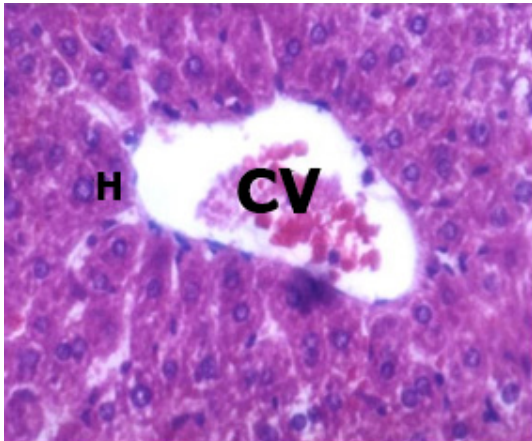
Fig 8: A photomicrograph of kidney tissue of the high dose-treated rat, demonstrating congested glomerular tuft (GT), widening of the lumen of convoluted tubule (CT) with flattened epithelial cell (arrow). H&E X:200



**Fig. 9:** A photomicrograph of the kidney tissue of the high dose-treated rat, demonstrating Many convoluted tubule (CT) with widening of the lumen, atrophied tubular lining (Arrow??) H&E X 200

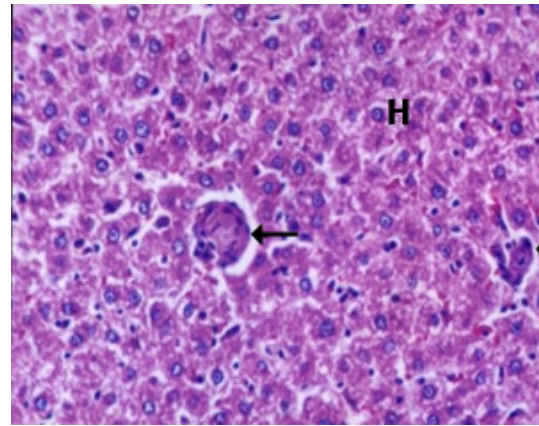


**Fig. 12:** A photomicrograph of the liver tissue of the low dose-treated rat, demonstrating congested Sinusoids (arrow), von Kupfer cell (double arrow??) H&E X:200



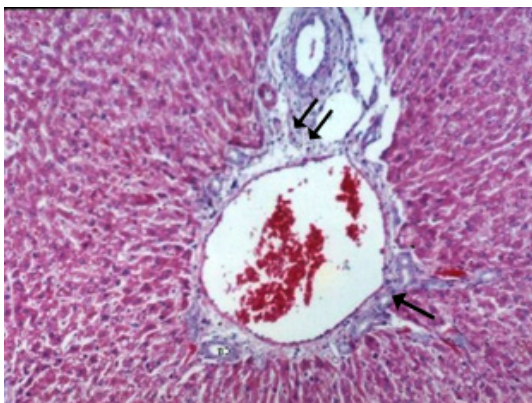
**Fig. 10:** A photomicrograph of the liver tissue of the control rat, showing central vein (CV), Intact hepatocytes (H)

H&E X:400



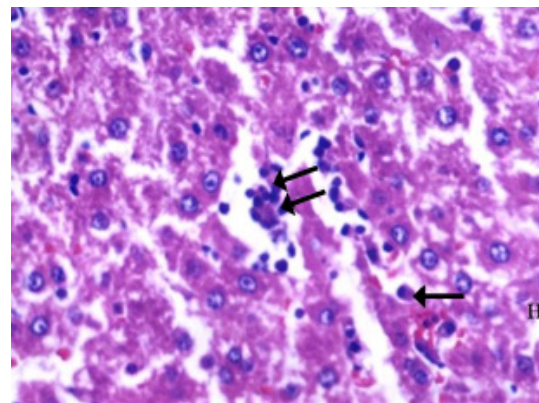
**Fig. 13:** A photomicrographic of the liver tissue of the high dose -treated rat showing focal necrosis ??, inflammatory areas (arrow), hepatocyte (H) with cytoplasmic vacuolation

H&E X:100



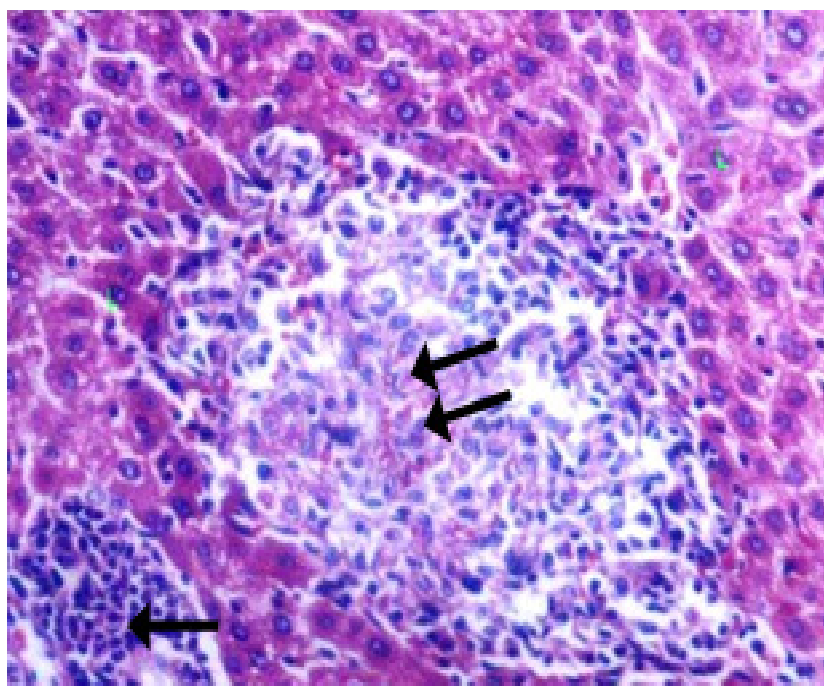
**Fig. 11:** A photomicrograph of the liver of the low dose treated rat , showing oedema in portal area (double arrow ?? where), proliferation of bile ducts (arrow) H&E X:200

H&E X:200



**Fig. 14:** A photomicrograph of a liver tissue of a high dose -treated rat, showing hyaline body (Arrow),Inflammatory aggregates (double arrow? ), H&E X 200

H&E X 200



**Fig. 15:** A photomicrograph of the liver tissue of the high dose -treated rat, demonstrating focal necrotic inflammatory area (double Arrow?), inflammatory cell aggregates (Arrow). H&E X:200

### I- Biochemical Results

**Table 1:** Total body weight and organ weight variation following the daily treatment with 4- tert- octylphenol

Groups	Total body wt.(gm)		Relative Kidney wt. (gm /100 g body wt)		Relative Liver wt. (gm /100 g body wt)	
	Initial wt. Mean ±SD	Final wt. Mean ±SD	Mean ± SD	Change %	Mean ± SD	Change %
Control	168.12±10.5	226.45±11.57 34.4 % *	0.69±0.05		3.22 ±0.14	
Low dose	152.9±5.98	141.33 ±5.65 -7.89% *	0.35±0.05	-52.1 % **	2.27±0.39	- 31.05% **
High dose	157.09 ±5.09	131.5±5.25 16.7 % *	0.26±0.017	- 62.3%**	2.02±0.40	-37.27%**

\* Percent change with respect to initial weight in the same treatment period.

\*\* Percent change with respect to control in the same treatment period



**Table 2:** kidney function variation in the male albino rat following the daily treatment with 4- tert- octylphenol

Groups	Creatinine(mg/dl)		Urea (mg/dl)		BUN (mg/dl)	
	Mean ± SD	Change %	Mean ± SD	Change %	Mean ± SD	Change %
Control	0.66 ±0.03 <sup>a</sup>		28.42±4.20 <sup>a</sup>		13.53±2.1 <sup>a</sup>	
1-week Low dose	0.85 ±0.07 <sup>b</sup>	23.13*	43.12±8.26 <sup>bc</sup>	34.09*	20.1±4.10 <sup>b</sup>	51.8*
High dose	0.99 ±0.09 <sup>c</sup>	33.45* 13.42**	53.08±11.04 <sup>cd</sup>	46.45* 18.76**	24.8 ±5.5 <sup>c</sup>	81.5*
2-week Low dose	0.84 ±0.13 <sup>b</sup>	22.15*	46.70±2.39 <sup>bc</sup>	39.14*	23.5 ±1.13 <sup>cd</sup>	74.07*
High dose	0.95 ±0.09 <sup>bc</sup>	30.81* 11.12**	60.54±2.70 <sup>de</sup>	53.05* 22.86**	30.13±1.3 <sup>e</sup>	125.9*
3- week Low dose	0.84 ±0.10 <sup>b</sup>	22.15*	45.17±2.77 <sup>bc</sup>	37.07*	21.02±1.34 <sup>b</sup>	59.3*
High dose	0.95 ±0.09 <sup>bc</sup>	30.99* 11.36**	60.54±2.70 <sup>e</sup>	53.05* 25.40**	31.2±1.4 <sup>e</sup>	131.1*
4-week Low dose	0.92 ±0.07 <sup>b</sup>	29.01*	36.79±3.64 <sup>ab</sup>	22.75*	18.56 ±1.37 <sup>b</sup>	37.0*
High dose	1.01 ±0.06 <sup>c</sup>	34.70* 8.01**	60.56±2.80 <sup>ce</sup>	53.07* 39.25**	32.31 ±1.5 <sup>e</sup>	139.3*
F ratio	19.73		20.59			
P value	0.001		0.001			

\* Percent change with respect to initial weight in the same treatment period.

\*\* Percent change with respect to control in the same treatment period

**Table 3:** Liver function variation in the male albino rat following the daily treatment with 4- tert- octylphenol

Groups	ALT		AST	
	Mean ± SD	Change %	Mean ± SD	Change %
Control	30.27±3.10 <sup>a</sup>		40.29± 3.77 <sup>a</sup>	
1-week Low dose	31.22 ± 3.03 <sup>a</sup>	3.01*	42.54± 5.11 <sup>ab</sup>	5.29*
High dose	37.62 ± 2.99 <sup>ab</sup>	19.52* 17.02**	46.30± 6.31 <sup>ac</sup>	12.98* 8.12**
2-week Low dose	34.62 ± 4.44 <sup>a</sup>	12.54*	44.10± 2.23 <sup>a</sup>	8.63*
High dose	40.71± 6.43 <sup>bd</sup>	25.64* 14.98**	52.53± 7.32 <sup>cd</sup>	23.30* 16.05**
3- week Low dose	34.90± 4.49 <sup>ad</sup>	13.24*	46.52± 9.19 <sup>as</sup>	13.39*
High dose	43.57± 12.17 <sup>b</sup>	30.52* 19.91**	54.47± 9.17 <sup>cd</sup>	26.02* 14.58**
4-week Low dose	35.83± 1.72 <sup>ab</sup>	15.51*	48.78± 2.95 <sup>bcd</sup>	17.39*
High dose	52.11± 8.84 <sup>c</sup>	41.90* 31.24**	55.34± 5.26 <sup>d</sup>	27.19* 11.86**
F ratio	14.71		8.90	
P value	0.001		0.001	

- Multi-way Analysis of Variance (MANOVA) was first applied.

- Bonferroni's test was used for multiple comparisons, P<0.05 is regarded as significant.

- Groups sharing the same letters are not significantly different.

\* Percent change with respect to control in the same treatment period

\*\* Percent change with respect to low dose treatment in the same period.

**Table 4:** The level of MDA and SOD in kidney and liver tissues as well as the liver total protein after daily administration of low and high doses of 4- tert- Octylphenol in the male albino rat

Groups	MDA in Kidney		MDA in Liver		SOD in Kidney		SOD in Liver		Total protein in liver (g/dl)	
	(Units /g tissue)		( Units/g tissue)		(mmol/g tissue)		(mmol/g tissue)			
	Mean ± SD	Change %	Mean ± SD	Change %	Mean ± SD	Change %	Mean ± SD	Change %	Mean ± SD	Change %
Control	45.12±0.85 <sup>a</sup>		16.58±4.51 <sup>a</sup>		610.12±4.61 <sup>a</sup>		59.54±1.40 <sup>a</sup>		8.22±1.4 <sup>a</sup>	
Low dose	46.5±0.65 <sup>a</sup>	+2.43% *	18.51±5.30 <sup>b</sup>	+12.06%*	595.12±4.51 <sup>a</sup>	-2.45%*	50.31±1.75 <sup>b</sup>	-18 %*	7.41±1.23 <sup>b</sup>	- 12%*
High dose	50.92±0.76 <sup>b</sup>	+12.85%*	23.08±7.06 <sup>c</sup>	+42.21%*	540.34±4.80 <sup>b</sup>	-11.4*	23.80±2.33 <sup>c</sup>	-60 %*	5.85±1.0 <sup>c</sup>	-28.8%*

\* Percent change with respect to control in the same treatment period

**Table 5:** Statistical significance of Hemoglobin, MCH, MCHC, Hematocrit and MCV after daily administration of low and high doses of compound OP for 15 and 30 days in the male albino rat

Groups	HB		MCH		MCHC		HT		MCV	
	Mean ± SD	Change %	Mean ± SD	Change %	Mean ± SD	Change %	Mean ± SD	Change %	Mean ± SD	Change %
Control	14.80±0.36 <sup>a</sup>		18.9±0.24 <sup>ab</sup>		31.7±0.57 <sup>a</sup>		48.30±1.42 <sup>a</sup>		59.9±1.09 <sup>a</sup>	
15-day -Low dose	14.07±0.74 <sup>b</sup>	-5.17	19.05±0.36 <sup>ab</sup>	0.97	1.52±0.81 <sup>a</sup>	-0.53	45.70±1.12 <sup>c</sup>	-5.28	57.32±2.83 <sup>a</sup>	-4.34
- High dose	10.87±0.54 <sup>c</sup>	-28.20 -29.45	19.67±0.76 <sup>a</sup>	4.24 3.14	31.20±0.60 <sup>a</sup>	-1.53 -1.01	40.43±1.25 <sup>b</sup>	-17.10 -13.03	59.97±2.91 <sup>ab</sup>	0.09 4.42
30-day -Low dose	13.68±0.71 <sup>b</sup>	-10.58	18.33±0.34 <sup>b</sup>	-2.83	2.80±0.91 <sup>a</sup>	3.52	40.37±1.29 <sup>c</sup>	- 16.5	56.62±0.46 <sup>a</sup>	-5.50
- High dose	10.05±0.33 <sup>d</sup>	-34.96 -36.15	17.10±0.71 <sup>c</sup>	-9.36 -7.21	31.98±0.64 <sup>a</sup>	0.95 -2.55	38.30±1.33 <sup>d</sup>	-20.57 -26.28	54.40±0.98 <sup>b</sup>	-9.74 -4.07
F- ratio	85.763		16.440		2.693		74.510		6.654	
P-value	.000		.000		.054		.0001		.001	

- Multi-way Analysis of Variance (MANOVA) was first applied.

- Bonferroni's test was used for multiple comparisons,  $P < 0.05$  is regarded as significant.

- Groups sharing the same letters are not significantly different.

\* Percent change with respect to control in the same treatment period.

\*\* Percent change with respect to low dose treatment in the same period.

**Table 6:** Statistical significance of RBCs, monocytes, leukocytes, lymphocytes, granulocytes and platelets counts after daily administration of low and high doses of OP for 15 and 30 days in the male albino rat.

Groups	RBCs		Monocyte		Leukocyte		Lymphocyte		Granulocyte		Platelets	
	Mean $\pm$ SD	Change %	Mean $\pm$ SD	Change %	Mean $\pm$ SD	Change %	Mean $\pm$ SD	Change %	Mean $\pm$ SD	Change %	Mean $\pm$ SD	Change %
Control	8.70 $\pm$ 0.21 <sup>a</sup>		5.83 $\pm$ 0.31 <sup>a</sup>		11.72 $\pm$ 0.22 <sup>a</sup>		52.00 $\pm$ 2.74 <sup>a</sup>		17.2 $\pm$ 1.30 <sup>a</sup>		633.0 $\pm$ 21.57 <sup>a</sup>	
15-day												
-Low dose	8.51 $\pm$ 0.43 <sup>a</sup>	-2.08	5.50 $\pm$ 0.55 <sup>a</sup>	-5.71	12.35 $\pm$ 0.57 <sup>a</sup>	5.41	64.83 $\pm$ 12.27 <sup>b</sup>	24.68	18.83 $\pm$ 2.23 <sup>a</sup>	9.71	592.17 $\pm$ 36.65 <sup>a</sup>	-6.45
-High dose	7.28 $\pm$ 0.29 <sup>b</sup>	-19.25	6.67 $\pm$ 1.63 <sup>b</sup>	15.15	12.03 $\pm$ 0.31 <sup>ab</sup>	2.56	76.17 $\pm$ 4.67 <sup>c</sup>	37.28	15.17 $\pm$ 2.86 <sup>b</sup>	-10.62	543.83 $\pm$ 15.88 <sup>b</sup>	-15.06
30-day												
-Low dose	6.87 $\pm$ 0.12 <sup>b</sup>	-16.95	3.67 $\pm$ 0.52 <sup>c</sup>	17.50	11.47 $\pm$ 0.69 <sup>bc</sup>	-2.63	73.50 $\pm$ 3.94 <sup>c</sup>	14.88	23.17 $\pm$ 3.54 <sup>c</sup>	-24.18	571.33 $\pm$ 19.04 <sup>c</sup>	-11.34
-High dose	6.58 $\pm$ 0.38 <sup>b</sup>	-24.46	13.00 $\pm$ 2.53 <sup>d</sup>	195.45	10.85 $\pm$ 0.50 <sup>c</sup>	-7.56	71.67 $\pm$ 5.13 <sup>c</sup>	28.23	27.83 $\pm$ 3.54 <sup>d</sup>	46.04	514.17 $\pm$ 11.21 <sup>d</sup>	-20.80
F-ratio	28.692	-29.33	37.85	71.79	10.32	-5.68	15.65	17.56	16.77	17.56	14.63	-11.12
P-value	0.0001		0.0001		0.0001		0.0001		0.0001		0.0001	

- Multi-way Analysis of Variance (MANOVA) was first applied.

- Bonferroni's test was used for multiple comparisons, P<0.05 is regarded as significant.

- Groups sharing the same letters have the same significance

\* Percent change with respect to control in the same treatment period.

\*\* Percent change with respect to low dose treatment in the same period.

## DISCUSSION

Many phenolic xenoestrogens as 4-tert-octylphenol (OP), 4-nonphenol and bisphenol A, have been found to simulator estrogenic effects harmfully affect the health of animals and human (*kamal et al., 2011*). OP is used as precursor in the manufacture of non ionic surfactants and is also degradation products of alkylphenol ethoxylate (APEOs), which are used in household detergents, pesticide formulations and others applications (Renner, 1997).

*Nomura et al. (2008)* showed that alkylphenols, having short alkyl chains and readily excreted into the bile from the liver, while 4-n-nonylphenol, having longer alkyl chains, remains as the alkylphenol's glucuronide in the tissue. The metabolism depend on the shape of the alkyl chains by comparing 4-n-octylphenol and 4-tert-octylphenols in a perfused rat liver. Both octylphenols were highly glucuronidated by the liver microsomal fractions (*Lee et al., 1996; Hanioka et al., 1999; Pedersen and Hill, 2000*) and it is well known that APs can amass in liver tissue (*Certa et al., 1996 and Daidoji et al., 2003*).

The present study focused on the toxic effects induced in rat liver and kidney by prolonged exposure to 4OP. Although, up to date, no authors has described in depth the hepatic effects of APs in longterm studies (*Chapin et al., 1999 and Tyl et al., 1999, 2006*)

Normal cellular function need a balance between the produced reactive oxygen species (ROS) and the antioxidant defense mechanisms. This equilibrium is troubled by the ROS surge that terminates in oxidative stress (Fidan and Dundar, 2008). ROS arise as by-products of normal cellular metabolism or as a consequence of exposure to certain chemicals (Krieger and Loch-Carusio 2001). These electrophilic metabolites can readily interact with essential DNA, proteins and lipids, leading to oxidative modification, henceforward, structural and functional modifications (*Fernandez et al. 2003 and Saleh, 2012*).

OP exposure in our study caused oxidative stress by disturbing the balance between ROS and antioxidant defenses system in kidney and liver of rats and this was confirmed by the histopathological study as stated in study of *Ashraf et al. (2014)*. In concordance with our results is the result of *Hassan et al. (2012)*; which stated that the cellular damage resulting from interaction

of ROS with lipid, protein and DNA molecules can be reduced with antioxidant.

SOD catalyze the conversion of O<sub>2</sub><sup>-</sup> to H<sub>2</sub>O<sub>2</sub> to protect tissues from oxidative stress and damage. The liberation of ROS in liver and kidney was assessed by the levels of enzymatic antioxidant (SOD). Oxidative stress mechanisms are involved in hepatotoxicity by bisphenol (BPA) exposure in animals as reported by *Ansoumane et al. (2015)* and this was evident in our study by the reduction in the total protein and abnormally increased ALAT and ASAT. In another study by the same author 2015; he provided an evidence that 4-NP affects gene expression related to liver hepatotoxicity expressed as hepatic steatosis. Additionally, 4OP and NP bring abnormal mitotic processes and cellular proliferation in immature hepatic tissue of male rat (*Zumbado et al., 2002*).

Result of *Hanioka et al. (2000)* suggested that OP toxicity in rat hepatic tissue arises from modify specific cytochrome P450 isoforms. Exposure to 4OP or NP showed an increase in intracellular liver glycogen content by means of an alteration of the Insulin/Glucagon ratio (*Youssef et al., 2003*). Even though the capability of NP and 4OP to induce glycogen accumulation in liver tissue refer to the estrogenic effect of these compounds, it must be highlighted that glycogen accumulation by hepatocytes could be considered an adaptive response against estrogenic or toxicity processes (*Hernandez-Rodríguez et al., 2007*).

Nephrotoxicity in our study was concluded from increased serum creatinine & urea as well as blood urea nitrogen levels in 4-tert-OP group as matched to control group and confirmed by histopathological changes in form of increased mesangial cellularity, lobulation and congestion along with focal interstitial fibrosis. Our results are supported by Saleh, 2012 findings. Consistent with our data is the study of *Vzquez & Nostró (2014)* which showed a significant response in the blood components of albino rats exposed to OP.

OP administration produced a significant decrease in RBC values. As a consequence, a decrease of Hb & Ht was observed. MCH & MCHC and MCV values did not differ significantly throughout the experimental period (*Mousavi and Yousefian;2012*).

The number of white blood cells can also be affected by physiological and environmental factors. One of the most common responses

seen after exposure to OP is an increase in the of the immune system can be observed with aquatic contaminants due to the great variety in terms of route of exposure, time of exposure, dose (Cuesta et al. 2011). In OP-exposed C. dimers, the total leukocyte count showed a slight increase in individuals treated with 150 µg/L OP, possibly due to the significant increase in the number of lymphocytes. This confirmed our study data that the leukocyte & granulocytes and lymphocytes count was increased with prolonged exposure of 4-Op.

## CONCLUSION

In summary the study highlighted the possible toxicity of 4-tert-octylphenol. This was evident by deteriorating of liver and renal function of the male albino rats and confirmed by the histopathological changes involving these organs. This material also resulted in alterations of blood components including elevation of WBC count and decreased in Hb and RBC count

## ABBREVIATIONS

BisphenolA: (BPA), Octylphenol: (OP), Nonylphenol (NP), Reactive oxygen species (ROS), Blood urea nitrogen (BUN), Aspartate Aminotransferase (ASAT), Alanine Aminotransferase (ALAT), Malondialdehyde (MDA), Superoxide dismutase (SOD), alkylphenol ethoxylates (OPE), Mean corpuscular volume (MCV), hematocrit (HT), mean corpuscular hemoglobin (MCH), mean corpuscular hemoglobin concentration (MCHC), red blood cell counts (RBCs), white blood cell (WBC).

## COMPETING INTERESTS

The authors declare that they have no competing interest.

## AUTHORS' CONTRIBUTIONS

LFW is responsible for experimental design; AAE and MKD responsible for histopathological study; LFW and MAE are carried the experimental and analytical part. MMR carried data analysis, LFW prepared the figures and drafted the manuscript; LFW, AAE, MKD edited the manuscript. All authors read and approved the final manuscript.

## ACKNOWLEDGMENT

The authors extend their appreciation for Prof. Dr. Kamal F. Shalaby at Biochemistry Department, Faculty of

Science, Ain-Shams University and Assistant Professor. Marwa M. Abd- Rabo at National Organization for Drug Control and Research for their effort and assistance in this study.

## REFERENCES

- Ansoumane, K., Chao, Q., Peng, D., Suqin, Q., Tingting Y., Yinan W., and Kedi Y. 2015.** Bisphenol A Induces Apoptosis in Liver Cells through Induction of ROS. *advances in Toxicology; Volume 2015 (2015)??*, Article ID 901983, 10 pages, Available on <http://dx.doi.org/10.1155/2015/901983>.
- Ashraf, M. M., Salah S. E., Badre E. E., and Nermeen B. E. 2014.** Studies on the potential protective effect of cinnamon against bisphenol A- and octylphenol-induced oxidative stress in male albino rats. *Toxicology Reports* 1: 92–101
- Bian, Q., Qian, J., Xu, L., Chen J., Song, L. & Wang, X. (2006).** The toxic effects of 4-tert-Octylphenol on the reproductive system of male rats. *Food & Chemical Toxicology*, 44:1355-1361.
- Blake, C.A., Boockfor, F.R. and Nair-Menon, J.U. 2004.** Effects of 4-tert-Octylphenol given in drinking water for 4 months on the male reproductive system of Fischer 344 rats. *Reproductive Toxicology*, 18: 43-51.
- Bøgh IB, Christensen P, Dantzer V, Groot M, Thøfner IC, Rasmussen RK, Schmidt M, Greve T. 2001.** Endocrine disrupting compounds: effect of octylphenol on reproduction over three generations. *Theriogenology*;55(1):131-150.
- Certa H, Fedtke N, Wiegand H, Muller A. 1996.** Toxicokinetics of ptert- octylphenol in male Wistar rats. *Arch Toxicol* 71:112–122
- Céspedes, R., Lacorte, S., Ginebreda, A., Barcel, D. 2008.** Occurrence and fate of alkylphenols and alkylphenol ethoxylates in sewage treatment plants and impact on receiving waters along the TerRiver (Catalonia, NE Spain). *Environmental Pollution*.;153(2):384-392.
- Chapin, R., Delaney, J., Lanning, L., Davis, B., Mintz, N., Wolfe, G. 1999.** The effects of 4-nonylphenol in rats: a multigeneration reproduction study. *Toxicol. Sci.* 52: 80–91.
- Cuesta A, Meseguer J, Esteban MA., 2011.** Immunotoxicological effects of environmental

contaminants in teleost fish reared for aquaculture. In: Stoytcheva M (ed) Pesticides in the modern world—risks and benefits, 3rd edn, pp. 571

**Culling, C.F.A. 1974.** Hand book of histopathological and histochemical techniques. Butter worth, Co.(Publishers) Ltd. Printed in Great Britain by Red Wood burn limited trowpridge and sher pp. 266268 11; 211-220.

**Daidoji, T., Inoue, H., Kato S. and Yokota, H. 2003.** Glucuronidation and excretion of nonylphenol in perfused rat liver. *Drug Metab Dis* 31:993–998

**Fernandez, V., Massa, L., Quinones, L., Simon-Giavarotti, K.A., Giavarotti, L., D'Almeida, V., Azzalis L.A., Junqueira, V.B. and Videla L.A. 2003:** Effects of gamma-hexachlorocyclohexane and L-3,3',5-triiodothyronine on rat liver cytochrome P450E1-dependent activity and content in relation to microsomal superoxide radical generation. *Biological Research*; 36(3-4):359-365.

**Fidan, A. F. and Dundar, Y. 2008.** The effects of *Yucca schidigera* and *Quillaja saponaria* on DNA damage, protein oxidation, lipid peroxidation and some biochemical parameters in streptozotocin-induced diabetic rats. *Journal of Diabetes and its complications*;22(5):348-356.

**V.quez, G. R. and Nothro, F. L. 2014.** Changes in Hematological Parameters of *Cichlasoma dimerus* (Teleostei, Perciformes) Exposed to Sublethal Concentrations of 4-tert-Octylphenol. *Archives of Environmental Contamination and Toxicology*. 66 (1): 1- 154

**Ohkawa, H., Ohishi, N. and Yagi, K. 1979.** Assay for lipid peroxides in animal tissues by thiobarbituric acid reaction. *Anal. Biochem*. 95:351–358.

**Hanioka, N., Jinno, H., Chung, Y.-S., Tanaka-Kagawa, T., Nishimura, T. and Ando, M., 1999.** Inhibition of rat hepatic cytochrome P450 activities by biodegradation products of 4-tert-octylphenol ethoxylate. *Xenobiotica* 29: 873–883.

**Hernández-Rodríguez G, Zumbado, M, and Luzardo OP, Monterde JG, Blanco A,**

**Boada LD. 2007.** Multigenerational study of the hepatic effects exerted by the consumption of nonylphenol- and 4-octylphenol-contaminated drinking water in Sprague–Dawley rats. *Environ Toxicol Pharm* 23:73–81

**Schirmeister, J. 1964.** Determination of creatinine level *Dtsch. Med. Wschr*;89:1940–1947

**Fawcett, J. K. and Soctt, J.E. 1960.** A rapid and precise method for the determination of urea, *J. Clin. Pathol*; 13: 156–159.

**Shalaby, K. F., Wahman, L. F. and El-Sisi, S. F.I. 2011.** The Possible Toxic Effect of 4tert-octylphenol-Polluted Water, on Male Reproductive Hormone of Rat. *Nature and Science*; 9(11):97-107

**Krieger, T.R. and Loch-Caruso, R. 2001.** Antioxidants prevent gamma-hexachlorocyclohexane-induced inhibition of rat myometrial gap functions and contractions. *Biology of Reproduction*.; 64(2):537547.

**Lavado, R., Ureña, R., Martin-Skilton, R., Torreblanca, A., del Ramo, J., Raldúa, D., Porte, C. 2005.** The combined use of chemical and biochemical markers to assess water quality along the Ebro River. *Environ. Poll.*; 139: 330–339.

**Lee, H. B. and Peart, T. E. 2002.** Organic contaminants in Canadian municipal sewage sludge. Part I: Toxic or endocrine disrupting phenolic compounds. *Water Quality Research. Journal of Canada*, 37 (4), 681–696.

**Lee, P., Patra, S.C., Stellow, C.T., Lee, W. and Struve, M. 1996.** Interaction of nonylphenol in hepatic CYP1A1 in rats. *Biochem. Pharmacol.*; 52:885–889.

**Lowry, O.H., Rosenbrough, N.J., Farr, A.L. and Randall, R.J. 1951.** Protein measurement with the folin phenol reagent. *J. Biol. Chem*. 193:265-272.

**Bradford, M. M. 1976.** A rapid and sensitive method for the quantitation of microgram quantities of protein utilizing the principle of protein dye binding. *Analytical Biochemistry*; 72(1-2): 248–254.

**Nishikimi, M., Roa, N.A. and Yagi, K. 1972.** The occurrence of superoxide anion in the

reaction of reduced phenazine methosulfate and molecularoxygen, *Biochem. Biophys. Res. Commun*; 46 :849–854

**Meesters, R.J.W. and Schröder, H.F.R. 2002.** Simultaneous determination of 4-nonylphenol and bisphenol A in sewage sludge. *Analytical Chemistry*, 74: 3566 – 3574.

**Mousavi, S. E. and Yousefian, M. 2012.** Effects of exogenous hormones on plasma cortisol, sex steroid hormone and glucose levels in male and female grass carp, *Ctenopharyngodon idellus*, during the spawning induction. *Afr J Biotechnol*; 11(36):8920–8927

**Nomura, S.; Daidoji, T.; Inoue, H.; Yokota, H. 2008.** Differential metabolism of 4-n- and 4 tertoctylphenols in perfused rat liver. *Life Sciences*; 83[5-6]: 223-228.

**Pedersen, R.T., Hill, E.M., 2000.** Identification of novel metabolites of the xenoestrogen 4tert-octylphenol in primary rat hepatocytes. *Chem. Biol. Interact.*128: 189–209.

**Pocar, P., Augustin, R., Gandolfi, F. and Fisher B. 2003.** Toxic effects of In Vitro Exposure to p-tert Octylphenol on Bovine Oocyte Maturation and Developmental Competence. *Biology of Reproduction*, 69:462-468.

**Reitman, S. and Frankel, S. 1957.** Colorimetric determination of GOT and GPT activity. *Amer. J. Clin. Path*; 28:56-63.

**Renner, R. 1997.** European Bans on surfactant trigger transatlantic debate. *Environmental Science. Technology*, 31, 316A–320A.

**Saleh, E. M. 2012.** Antioxidant effect of

aqueous extract of propolis on hepatotoxicity induced

**Shermer, S. 1968.** In: “The blood morphology of laboratory animals“, PBI .F.A. davis Co. ; Philadelphia , USA. pp:42

**Tyl, R., Myers, C., Marr, M., Brine, D., Fail, P., Seeley, J. and Van Miller, J.P. 1999:** .Two generation reproduction study with para-tert-octylphenol. *Reg. Toxicol. Pharmacol.* 30: 81–95.

**Tyl, R.W., Myers, C.B., Marr, M.C., Castillo, N.P., Seeley, J.C., Sloan, C.S., Veselica, M.M., Joiner, R.L., Van Miller, J.P. and Simon, G.S., 2006.** Three generation evaluation of dietary para-nonylphenol in CD (Sprague-Dawley) rats. *Toxicol. Sci.*; 92: 295–310.

**Youssef, J., Elbi, C., Warren, B., Yourtee, D., Nagarur, R., Molteni, A., Cunningham, M.L. and Badr, M. 2003.** Glucocorticoid-like effects of antihepatocarcinogen rotenone are mediated via enhanced serum corticosterone levels: molecular fitting and receptor activation studies. *J. Carcinog.* 2:2–10

**Hassan, Z. K., Elobeid, M. A., Virk, P., Omer, S. A., ElAmin, M., Daghestani, M. H. and Ebtisam, M. A. 2012.** Bisphenol A Induces Hepatotoxicity through Oxidative Stress in Rat Model. *Oxidative Medicine and Cellular Longevity* Volume 2012, Article ID 194829, 6 pages ?? (Revise)

**Zumbado, M., Boada, L. D, Torres, S, Monterde, J. G, Díaz-Chico, B. N., Afonso, J. L, Cabrera, J. J. and Blanco, A. 2002.** Evaluation of acute hepatotoxic effects exerted by environmental estrogens nonylphenol and 4-octylphenol in immature male rats. *Toxicology*; 175:49–62

## تأثير 4- ثلاثي الاوكثيل فينول على الكبد و الكلى : دراسة بيوكيميائية ونسجية

لبنى فاروق وهمان<sup>١</sup>، عبير عبدالله الصديق<sup>٢</sup>، مها خلف دسوقي<sup>٣</sup>، مديحه احمد الصواف<sup>٤</sup>

قسم الفسيولوجى بالهيئة القومية للرقابة و البحوث الدوائية<sup>١</sup>

قسم علم الامراض جامعه الخرطوم<sup>٢</sup>

كلية الطب جامعه المنيا<sup>٣</sup>

الهيئة القومية للرقابة و البحوث الدوائية<sup>٤</sup>

### ملخص البحث

تأثير الفورواكتيل فينول على الكلى و الكبد و فى ذكور الجرذان البيضاء البالغة: دراسته نسيجية وكيمياء حيوية .

يعتبر الفورواكتيل فينول احدى عوامل الاكسده التى تسبب اضرار خطيره للحمض النووى , بروتينات و دهون الخليه و بالتالى الى موتها . و قد اشير فى بحث سابق تم نشره فى عام 2011 ان مياه الشرب بترعه الاسماعيليه و هى احدى مصادر مياه الشرب فى مصر تحتوى على تركيزات عاليه من ماده الاوكثيل فينول .

ولهذا تهدف الدراسة الحالية الى التحقق من الآثار السامة المحتملة للتعرض لماده -الاوكثيل فينول على الكبد والكلى و مركبات الدم فى ذكور الجرذان البيضاء البالغة. تم حقن الفئران عن طريق الفم بجرعات منخفضة و عالية من 4 الاوكثيل فينول لمدة أربعة أسابيع. ثم تم ذبح الحيوانات و سحب عينات من الدم للتحليل البيوكيميائية و الدموية و جمعت الأنسجة ( الكلى و الكبد ) لتحليل الأنسجة.

اسفرت نتائج الدراسة ان تناول الاوكثيل فينول ادى الى ارتفاع كبير فى تركيز اليوريا، والكرياتينين واليوريا نيتروجين الدم (BUN) و مستوى وظائف الكبد (ASAT &ALAT). كشفت بيانات الدراسة ايضا زيادة كبيرة فى مستوى (malondialdehyde MDA) مع انخفاض فى محتوى البروتين الكلى و (superoxide dismutase (SOD فى انسجه الكبد والكلى فى جميع المجموعات المعالجة . و قد اتضح ايضا من الدراسة ان الخلل يصبح أسوأ مع زيادة الجرعات والمدة وأبرزت الدراسة ايضا إمكانية التأثير المدمر لشرب المياه الملوثة بالاوكثيل فينول على صحة البشر.