

Registration accuracy and surface marking of an electromagnetic navigation system for use in endoscopic sinus surgery

Original
Article

Zabrina Marnel Samarakkody¹, Harvinder Singh Sran², Norasnieda Md Shukri¹,
Baharudin Abdullah¹

¹Department of Otorhinolaryngology-Head & Neck Surgery, School of Medical Sciences,
Universiti Sains Malaysia, ²Department of Otorhinolaryngology, Hospital Raja Permaisuri
Bainun, Malaysia

ABSTRACT

Introduction: Since its introduction, surgical navigation systems have become integrated into surgical practices that include complex nasal endoscopic procedures to avoid serious complication such as injury to the optic nerve, the carotid artery, the dura mater and the brain parenchyma.

Objective: We aimed to determine the accuracy of image guided system (IGS) by using different timing interval of computed tomography scan of paranasal sinus and our experience in performing the surface marking.

Methods: A cross sectional study was done. Subjects were recruited from patients planned for endoscopic sinus surgery with IGS, who met the inclusion and exclusion criteria. The image guided navigation measurements were compared to the actual anatomical measurements of intercanthal distance of both eyes and the tangential line of inverted triangle to the philtrum. The estimated time to register the IGS was recorded. All measurements were done at the same time as the calibration of the IGS.

Results: The mean intercanthal distance measured by IGS was 38.17 mm (SD 3.34) whereas the actual intercanthal distance was 38.17 mm (SD 3.37 mm). The tangential line measured by IGS was 46.62 (SD 3.39) whereas the actual measurement of the tangential line was 46.47mm (SD 3.27). There was no significant difference in both measurements between IGS and actual anatomical measurements ($p=0.804$ and 0.496 , respectively).

Conclusions: Even with the different intervals there was not much deviation from the actual anatomical distance. The IGS is accurate and is applicable for use in Asian patients.

Key Words: Electromagnetic navigation system, endoscopic sinus surgery, registration accuracy, surface marking.

Received: 11 January 2019, **Accepted:** 5 June 2019

Corresponding Author: Baharudin Abdullah, PhD, Department of Otorhinolaryngology - Head and Neck Surgery, School of Medical Sciences, Universiti Sains Malaysia, Kelantan, Malaysia, **Tel.:** +6097676416, **E-mail:** profbaha@gmail.com

ISSN: 2090-0740, June 2019 Vol.20, No.2

INTRODUCTION

The advent of endoscopic sinus surgery in the 1980s has prompted the development of image guided systems (IGS) to assist the surgeon^[1]. Surgical navigation systems have become integrated into surgical practices^[2]. The use of IGS has markedly improved the field of endoscopic sinus surgery and its complication rate^[3]. There is a risk of serious complication due to anatomic proximity of the sinus cavities, the optic nerve, the carotid artery, the dura mater and the brain parenchyma that can be avoided by IGS use^[4,5].

The registration is done by which the position of the instrument or tracking pointer in the surgical field is correlated with the computed tomography (CT) images of the patient. The tracking probe is registered with respect to the CT images of the patient^[6]. The registration markers or anatomical markers are set by selecting bony prominences that are located directly beneath the skin. However, the

interval of CT prior to surgery and efficiency of surface marking have not been well studied. In this study, we aimed to determine the accuracy of navigation system in using different timing interval of CT and our experience in performing the surface marking in Asian patients.

METHODOLOGY

Subjects

This was cross sectional study to evaluate the accuracy in surface registration of patients undergoing endoscopic sinus surgery with image guided navigation system in a tertiary hospital in Malaysia. Subjects were recruited from those scheduled to undergo endoscopic sinus surgery with image guidance system. All measurements were done at the same time for calibration of the machine to the patient's anatomy. The image guidance system used was Storz NAVI Electromagnetic system. The inclusion criteria were age 18 years and above and scheduled for endoscopic

sinus surgery. Whereas the following exclusion criteria were used; previous surgery to paranasal sinuses and skull base with facial anomalies, facial trauma, chronic maxillary atelectasis with significant orbital changes, craniofacial abnormality, non-Malaysian and pregnancy. Subjects would be withdrawn if the investigator deemed that it was detrimental or risky for the subjects to continue. All withdrawn subjects would attend the final study visit and withdrawn subjects would be replaced.

Study Procedures

Patient was intubated with the normal surgery requirements with throat pack inserted and the endotracheal tube anchored at the left and the patient's eyes half exposed (chloramphenicol eye ointment applied). The strap of the IGS headpiece was strapped on the patient and the magnetic receiver fastened onto the operation table. The IGS machine and monitor was then set up with uploading the CT scan in DICOM format into the system. Once uploaded, the machine was calibrated, and the reference points confirmed. After the intercanthal distance and its tangential distance taken and recorded, the surgery began. The intercanthal distance between the right and the left eyes were measured together with the distance from the tangential line of the inverted triangle to the philtrum. A comparison was made between right and left intercanthal distance and measurements different between genders. Day to operation was categorized into two categories: less than 90 days and 90 days or more. The difference between IGS and actual measurement was computed as well for both intercanthal and tangential line.

Statistical analysis

Statistical calculation and evaluation were performed with SPSS software version 22.0. The sample size was calculated using Single Mean Formula and 2-Mean Formula. All data were anonymous and only accessible to the research team members. Data were presented as grouped data and the responders were not identified individually. All measurements were taken 3 times and the average was used in data analysis. When there was discordant opinion, further evaluation of the image was done by the specialists to obtain a mutual consensus. Mann Whitney U test was used to test where there is significant difference in outcome (IGS compared to actual for intercanthal distance and tangential line) between days to operation. Furthermore, Mann Whitney U test was applied again to test the difference in intercanthal distance and tangential line between gender for both measurements (IGS and actual) too. A p value less than 0.05 was considered statistically significant.

RESULTS

A total of 30 patients were recruited from those scheduled to undergo endoscopic sinus surgery with IGS (Table 1). Out of the 30 patients selected, 7 of them were female. The average age amongst the patients selected was 47 years old. The comparison of intercanthal distance and tangential line between IGS and actual measurements is shown in Table 2.

The mean intercanthal distance measured by IGS was 38.17 mm (SD 3.34) whereas the actual intercanthal

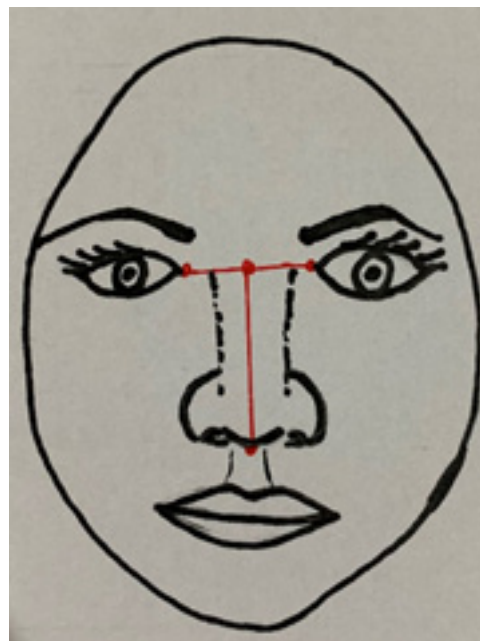


Fig. 1: Intercanthal distance between the eyes and the columnella. All represented by the red dots.

distance was 38.17 mm (SD 3.37 mm). The tangential line measured by IGS was 46.62 (SD 3.39) whereas actual measurement of the tangential line was 46.47 mm

(SD 3.27). There was no significant difference in both measurements between IGS and actual measurements ($p = 0.804$ and 0.496 , respectively).

Table 1: Characteristics of study population (n=30)

	Mean (SD)	Range	25 th Percentiles	(Median)	75 th Percentiles
Race ¹					
Malay	25 (83.3)				
Chinese	3(10.0)				
Indian	2 (6.7)				
IGS Intercanthal Distance (mm) ²	38.17 (3.34)	33.66 – 44.92	34.92	37.84	41.33
IGS Tangential Line (mm) ²	46.62 (3.39)	41.36 – 54.32	44.26	45.47	48.76
Actual Intercanthal Distance (mm) ²	38.17 (3.37)	34.00 – 44.00	35.00	37.00	41.00
Actual Tangential Line (mm) ²	46.47 (3.27)	41.00 – 54.00	44.00	45.50	48.50

SD: standard deviation

¹Frequency(percentage) ²Data were positively skewed.

Table 2: Comparison of intercanthal distance and tangential line between IGS and actual measurements (n=30).

	Mean (SD)	Median (IQR)	z-statistic	p value ¹
Intercanthal Distance (mm)				
IGS	38.17 (3.34)	37.84 (6.41)	-0.25	0.804
Actual	38.17 (3.37)	37.00 (6.00)		
Tangential Line (mm)				
IGS	46.62 (3.39)	45.47 (4.50)	-6.81	0.496
Actual	46.47 (3.27)	45.50 (5.00)		

SD = Standard deviation; IQR = Interquartile range

¹Wilcoxon signed ranks test was applied, normality of data distribution was not assumed.

Table 3: Correlation of intercanthal distance between IGS and actual measurements.

Variable	r	p value ¹
Intercanthal distance: IGS and Actual	0.974	<0.001
Tangential line: IGS and Actual	0.972	<0.001

¹Spearman correlation test was applied.

Table 3 revealed the correlation of intercanthal distance and tangential line between IGS and actual measurement. There was significant, positive and good correlation of intercanthal distance between IGS and actual measurement ($r = 0.974$; $p < 0.001$). Similarly, there was significant, positive and strong correlation between IGS and actual measurement of tangential line score ($r = 0.972$; $p < 0.001$).

There was no significant difference on the registration time

compared to the standard 15 minutes standard registration time ($p = 0.156$) (Table 4). There was no significant difference in median intercanthal distance and tangential line between days to operation (Table 5). There was no significant difference between gender for intercanthal distance for IGS ($p = 0.390$) and actual measurements ($p = 0.390$) and no significant difference for tangential line for IGS ($p = 0.390$) and actual measurements ($p > 0.950$) (Table 6).

Table 4: Difference of registration time from standard 15 minutes.

	Mean (SD)	Mean Difference (95%CI)	t stats (df)	p value
Registration time	15.93 (3.51)	0.93 (-0.38, 2.25)	1.46 (29)	0.156

One-Sample Test

Table 5: Difference in the difference in intercanthal distance and tangential line between days to operation.

	Median (IQR)		p value
	<90 days n = 17	≥90 days n = 13	
Difference in			
Intercanthal distance	0.00 (0.86)	-0.45 (1.08)	0.462
Tangential line	-0.12 (0.82)	0.21 (0.70)	>0.950

Mann Whitney U Test was applied, normality of data distribution was not assumed

Table 6: Difference in intercanthal distance and tangential line between gender.

	Mean (SD)		Median (IQR)		p value
	Female	Male	Female	Male	
Intercanthal distance					
IGS	39.69 (2.11)	37.71 (3.54)	40.76 (4.11)	35.78 (3.54)	0.390
Actual	39.29 (2.43)	37.83 (3.59)	40.00 (5.00)	36.00 (6.00)	0.390
Tangential line					
IGS	45.99 (3.74)	46.81 (3.34)	44.67 (6.02)	45.87 (4.01)	0.390
Actual	46.43 (3.82)	46.48 (3.17)	45.00 (7.00)	46.00 (4.00)	>0.950

Mann Whitney U Test was applied, normality of data distribution was not assumed

DISCUSSION

The use of IGS is generally perceived that it is critical to certain cases for verifying the location of vital structure surrounding the paranasal sinus and minimalizing the risk of injury^[7, 8]. The localization unit uses preoperative CT or MRI data to provide the surgeon with a real-time 3-D visual localization of the surgical instruments relative to the patient's anatomy during the image guided procedure^[8]. IGS does not display anatomical changes that occur during surgery because it relies on computed tomography (CT) scans obtained preoperatively^[9]. Image guidance systems were designed to identify surgical instruments, calculate the position of instrument tip in relation to the patient, and project the instrument location on the previously obtained imaging study^[10].

Registration accuracy was checked visually for every patient by repeatedly pin-pointing the anatomical landmarks. Registration errors can be caused by shifting, or unfavourable spatial distribution of the markers. Calibration using anatomic landmarks is not precise enough and could lead to 2 to 5 mm divergence^[11]. A drift in the accuracy of the system may develop during the procedure and frequent corroboration with known clinical landmarks is advised^[12].

While stereotaxic frames and bone implanted markers are rigidly attached to bone, skin markers and markers

implanted into soft tissue can move due to skin elasticity or soft tissue deformation^[13]. Virtual views have been designed to match a real model in terms of spatial cues and anatomical relationships^[14]. The problem of finding corresponding landmarks in 3D and 2D is avoided by curve-to-curve and surface-to-curve registration^[13].

Calibration systems involving surface scanning of the patient's face need to consider the soft tissue malleability. Hydration and tension differences in facial tissue between image acquisition when patient is awake and surgery under general anaesthesia can cause significant difference (up to 2mm) in the position points^[15, 16, 17]. Three anatomical markers are set by selecting bony prominences that are located beneath the skin and a triangular field is created by selecting this reference point. Two of the reference points are the lateral canthi of the right and left eye and the third point is the philtrum^[2].

The dominant characteristics of the Asian face were a wider intercanthal distance in relation to a shorter palpebral fissure, a much wider soft nose within wide facial contours, a smaller mouth width, and a lower face smaller than the forehead height, when compared to Caucasian face^[18].

Previous studies by Chang *et al*, regarding the three-dimensional analysis of the surface registration accuracy of electromagnetic navigation systems in live endoscopic

sinus surgery had the sample size of 40 (20 men and 20 women), of which there was no racial predisposing factor^[19]. The main objective of current study was to determine the estimate of each anatomical measurements instead of comparing the difference between them. Since the study had enrolled 30 subjects as planned, it was able to provide an estimate of the mean measurement with a margin of error not exceeding 1.00 mm at significance level of 0.05^[20].

Although facial analysis and proportions are well discussed in Caucasians and Africans, only a limited number of studies exist for Asians^[21]. Amongst landmarks were the intercanthal distance and nasal length. Most studies concluded that the distance in Asians are wider than Caucasians with the mean intercanthal difference of 5.1 and p value of < 0.001 and nasal length mean difference of 1.2 and p value of 0.01^[21]. Briellmann *et al.*, also noted the difference between Asians and Caucasian faces, noting the most obvious difference between the two races are the eye (intercanthal distance) and the length of nose by pointing out the point of fixations of gaze by 24 observers^[22, 23]. Rhee mentioned the percentage ratio of facial width to facial height was 74.4 % for Caucasians and 72.0 % for Asians which showed that the Asian face is wider^[24]. In terms of photogrammetric measurements, the intercanthal distance in Caucasian is 31.4 mm compared to 35.7 mm in Asians and the nose height is 45.3 mm in Caucasian compared to 49.3mm in Asians^[24].

In a review article by Gao *et al.*, East Asian have wider intercanthal distance and nose width compared to Caucasians (Italians)^[25]. In another article by Le, they have noted that intercanthal width is wider in Chinese (mean 37.1 mm) and Vietnamese (mean 36.7 mm) than in North Americans (mean 32.3 mm) but smaller in Thais (mean 36.6 mm). As for nose length the Chinese have a mean of 52.6 mm, the Thais have 50.5 mm and the Vietnamese have a mean of 51.3 mm compared to the North Americans 52.1 mm^[26]. In our patients, we have noticed that the IGS is accurate for Asians even though using the Caucasian template. The measurements are almost the same between the actual measurements and the IGS measurements.

The time lapse between the CT done prior to the surgery is the average of 87 days. The longest time lapse between surgery and the preoperative CT scan is 242 days and the shortest duration is 3 days. However, the measurements of the patients taken during the time of surgery and when it is compared in the IGS has proved that even after some time, the IGS is still accurate since we use the bony prominences as reference points. Thus, the bone is not influenced by edema and tissue fluctuations. There was no study done to determine any specific duration of preoperative CT should be used for IGS. However, all of them suggested preoperative CT scans should be obtained and used in the navigation system.

The duration of time taken for image registration of each individual patient was on the average about 15 minutes. This complies to the norm. Elishar *et al* with the optical navigation system initially began at 30 minutes duration but as their staff grew more confident, the registration time has dropped to 15 minutes^[15]. Koele *et. al* had taken 10 minutes with the magnetic navigation system^[13]. and Benoit *et al* found no correlation between surgeon and setup time^[27]. Garcia also stated that the setup up time took not more than 5 minutes to the preparation time of the surgery in the electromagnetic IGS setup. Metson *et al* mentioned a range between 10-20 minutes needed for the setup of the electromagnetic system^[5]. Kingdom *et al* also stated that their group took 15 minutes as well^[8].

In our study, we did not find any difference between males and females. Thus, in Asian faces, there are no difference in terms of intercanthal distance and the tangential line between it. However, in Nigeria, it is found that intercanthal distance in males are wider than in females^[28, 29, 30]. But, in India, it was noted that the intercanthal distance was less in males compared to females^[31]. As previously mentioned, the exact the interval of CT prior to surgery and efficiency of surface marking have not been well studied. Most studies mentioned preoperative CT scan was obtained but no mention of the interval between scan and the surgery^[1, 2, 13, 15, 19].

CONCLUSION

The IGS is indeed a valuable tool in endoscopic sinus surgery. In this study, we have determined that the navigation system is accurate even with the different timing interval of CT. We have found that even with the different intervals there was not much deviation from the actual anatomical distance. We also found that the IGS is accurate and is applicable for the use for Asian features.

CONFLICT OF INTEREST

The authors declare that they have no conflict of interest.

REFERENCES

1. Keschner D, Lee J. Use of surgical navigation during endoscopic skull base surgery. *Operative Techniques in Otolaryngology* (2010) 21, 44-50
2. Irugu DV, Stammberger HR. A note on the technical aspects and evaluation of the role of navigation system in endoscopic endonasal surgeries. *Indian J Otolaryngol Head Neck Surg* 2012; 66(Suppl 1):S307–S313.
3. Pruliere-Escabasse V, Coste A. Image Guided /sinus Surgery. *European Annals of Otorhinolaryngology, Head and Neck diseases* (2010) 127, 33—39.

4. Metsen R, Cosenza M. The Role of Image-guidance systems for Head and Neck Surgery. *Arch Otolaryngol Head Neck Surg.* 1999;125: 1100-1104.
5. Parikh SR, Cuellar H. Indications for image-guidance in pediatric sinonasal surgery. *International Journal of Pediatric Otorhinolaryngology* (2009) 73, 351—356
6. Lapeer RJ, *et al.* Using passive coordinate measurement arm for motion tracking of a rigid endoscope for augmented-reality image-guided surgery. *Int J Med Robotics Comput Assist Surg* 2014; 10: 65–77.
7. Dalgof DM, Sacks R. Image-Guided Surgery Influences Perioperative Morbidity from Endoscopic Sinus Surgery: A Systematic Review and Meta-Analysis. *Otolaryngology–Head and Neck Surgery* 149(1) 17–29 DOI: 10.1177/0194599813488519
8. Kingdom TT, Orlandi RR. Image-guided surgery of the sinuses: current technology and applications. *Otolaryngol Clin N Am* 37 (2004) 381–400
9. Wong WK, Matsuwaki Y. Role of intraoperative CT-updates during image-guided endoscopic sinus surgery for sinonasal fibro-osseous lesions. *Auris Nasus Larynx* 38 (2011) 628–631
10. Yu H, Shen G. Navigation-Guided Reduction and Orbital Floor Reconstruction in the Treatment of Zygomatic-Orbital-Maxillary Complex Fractures. *J Oral Maxillofac Surg* 68:28-34, 2010
11. Markelj P, Tomazevic D. A review of 3D/2D registration methods for image-guided interventions. *Medical Image Analysis* 16 (2012) 642–661
12. Dixon BJ, Chan H. The effect of augmented real-time image guidance on task workload during endoscopic sinus surgery. *International Forum of Allergy & Rhinology*, Vol. 2, No. 5, September/October 2012
13. Koele W, Stammberger H, Lackner A, Reittner P. Image guided surgery of paranasal sinuses and anterior skull base - Five years experience with the InstaTrak®-System. *Rhinology*, 40, 1–9, 2002.
14. Soteriou E, Grauvogel J, Laszig R, Grauvogel TD. Prospects and limitations of different registration modalities in electromagnetic ENT navigation. *Eur Arch Otorhinolaryngol* DOI 10.1007/s00405-016-4063-9
15. Eliashar R, Sichel JY, Gross M, Hocwald E, Dano I, Biron A, Ben-Yaacov A, Goldfarb A, Elidan J. Image Guided Navigation system – a new technology for complex endoscopic endonasal surgery. *Postgrad Med J* 2003;79:686-690
16. Ecke U, Luebben B, Maurer J, Boor S, Mann WJ. Comparison of different computer-aided surgery systems in skull base surgery. *Skull Base* 2003;13(1):43-50.
17. Kral F, Puschban EJ, Riechelmann H, Freysinger W. Comparison of optical and electromagnetic tracking for navigated lateral skull base surgery. *Int J Med Robotics Comput Assist Surg* 2013; 9: 247–252. DOI: 10.1002/rcs.1502
18. Thuy T, Leslie G. Proportionality in Asian and North American Caucasian Faces Using Neoclassical Facial Canons as Criteria Aesthetic Plastic Surgery January 2002, Volume 26, Issue 1, pp 64–69
19. Chih-Ming Chang, Kai-Min Fang, Tsung-Wei Huang, *et al* Three-dimensional analysis of the surface registration accuracy of electromagnetic navigation systems in live endoscopic sinus surgery *Rhinology* 51: 343 348, 2013 DOI:10.4193/Rhino12.165
20. Nonparametric statistical tests for the continuous data: the basic concept and the practical use. *Korean J Anesthesiol.* 2016;69(1):8-14.
21. Choe KS, Sclafani AP, Litner JA, *et al* The Korean American Woman’s Face. Anthropometric Measurements and Quantitative Analysis of Facial Aesthetics. *Arch Facial Plast Surg/Vol* 16, Jul/Aug 2004: 244-252
22. Brielmann AA, Bulthoff I, Armann R, Looking at faces from different angles: Europeans Fixate different Features in Asian and Caucasian faces. *Vision Research* 100 (2014) 105-112
23. Biller JA, Kim DW. A contemporary Assessment of Facial Aesthetic Preferences. *Arch Facial Plast Surg/* 2009; 11 (2): 91-97
24. Rhee SC. Difference between Caucasian and Asian attractive faces. *Skin Res Technol.* 2017;00:1-7.
25. Gao Y, *et al.*, Comparison of aesthetic facial criteria between Caucasian and East Asian female populations: An esthetic surgeon’s perspective, *Asian Journal of Surgery* (2016)xx, 1-8. <http://dx.doi.org/10.1016/j.asjsur.2016.07.007>

26. Le TT, Farkas LG, Ngim RCK *et al.*, Proportionality in Asian and North American Caucasian Faces Using Neoclassical Facial Canons as Criteria. *Aesth. Plast. Surg.* 26: 64-69, 2002 DOI: 10.1007/s00266-001-0033-7
27. Benoit MM, Silvera VM, Nichollas R *et al.* Image Guidance systems for minimally invasive sinus and skull base surgery in children. *IJPORL* 73 (2009) 1452-1457
28. Usman YM, Shugaba AI The interpupillary distance and the inner and outer intercanthal distances. *JoSciResearch* 3(1). Pp. 001-003, June, 2015
29. Egwu OA, Ewunonu EO, Eteudo AN, *et al.* Normal values of inner and outer intercanthal distances in a student population in southeast Nigeria. *Int. J. Boil. Chem. Sci.* 2 (3): 355-358, 2008
30. Ibraheem WA, Ibraheem AB, Bekibele CO. Association between gender, age and palpebral dimensions/exophthalmometric values among Nigerians of Ido local government area of Oyo State, Nigeria. *Afr J Med Health Sci* 2013; 12: 55-9.
31. Vasanthakumar P, Kumar P, Rao M. Anthropometric analysis of Palpebral Fissure Dimensions and its Position in South Indian Ethnic Adults. *OMJ* (2013) Vol. 28, No. 1:26-32