

Mitomycin-C Prevents Post-Operative Adhesions after Endoscopic Nasal Surgery

Original
Article

Ahmed A. Sadek, Osama G. Abdel-Naby and Mostafa M. Talaat

Otorhinolaryngology Dept., Faculty of Medicine, Minia University, Minia, Egypt.

ABSTRACT

Purpose: To assess the role of mitomycin-c (MMC) in preventing synechia formation and ostial stenosis following endoscopic nasal surgery.

Patients and methods: This is a prospective comparative study on a total of thirty patients of different ages including both sexes. Patients were divided in two groups (A and B, 15 each). Group (A) had FESS operation and group (B) had partial inferior turbinectomy. In Group (A) 15 primary FESS procedures were performed in 15 patients: nine patients had bilateral pansinusitis, and six cases had bilateral nasal polyposis. MMC was applied at the site of middle meatal antrostomy on one side and the contra-lateral side served as the control. In Group (B), 15 endoscopic bilateral partial inferior turbinectomy was performed in 15 patients. MMC was applied between residual of right inferior turbinate and the septum, while the contra-lateral side served as a control. The data were analyzed after two months of follow up.

Results: One patient (6.7%) had adhesion at Rt. Side and seven patients (46.7%) had adhesions at Lt. Side, while 14 patients (93.3%) had no adhesion at Rt. Side and eight patients (53.3%) had no adhesion on Lt. Side (P=0.013). In Group (B), three patients (20%) had adhesion at Rt. Side and nine patients (60%) had adhesions at Lt. Side, while 12 patients (80%) had no adhesion at Rt. Side and 6 patients (40%) had no adhesion on Lt. Side (P=0.025).

Conclusion: Topical use of MMC is safe and beneficial in decreasing adhesion formation after endoscopic nasal surgery.

Key Words: Endoscopic nasal surgery, FESS, mitomycin-C, turbinectomy.

Received: 29 July 2018, **Accepted:** 17 May 2019

Corresponding Author: Ahmed A. Sadek, MD, Otorhinolaryngology Dept., Faculty of Medicine, Minia University, Minia, Egypt, **Tel.:** +2 01018424884, **E-mail:** ahmedadel18101978@yahoo.com

ISSN: 2090-0740, July 2019 Vol.20, No.2

INTRODUCTION:

Endoscopic nasal surgery is one of the most frequently performed procedures in ENT practice. Endoscopic nasal surgeries include functional endoscopic sinus surgery, endoscopic turbinectomy and endoscopic lamellectomy. Despite its efficacy and safety, 7.6% to 38% of the patients' experience relapsing symptoms and undergo revision surgery^[1,2]. The causes of treatment failure of endoscopic nasal surgery include disturbed mucociliary clearance, immunodeficiency, sensitivity to acetylsalicylic acid, and anatomic obstruction. The most frequent events related to the latter cause are synechia and ostium stenosis (27% in maxillary sinuses and 25% in frontal sinuses)^[3,4]. Synechia and stenosis formation following endoscopic nasal surgery represents a potential cause of surgical failure. Mitomycin-c (MMC) has been used successfully in other fields to decrease post-operative scar formation due to its ability to suppress fibrosis and vascularity in both vivo and vitro. Initially isolated from *Streptomyces caespitosus* strain of actinomycetes for its antibacterial properties, MMC was used as a chemotherapeutic agent because of its ability to cross-link DNA and inhibit cellular mitosis. Studies of MMC on cultured fibroblast by Hu *et al.* have demonstrated

its antiproliferative effect. Study of effect of MMC on cultured human nasal mucosa by Hu *et al.* revealed that brief exposure of MMC inhibits fibroblast proliferation and increase fibroblast apoptosis^[5]. MMC was first used topically in 1963 as adjuvant therapy for pterygium, reducing relapse rates from 89% to 2.3%. In glaucoma surgery it has proven effective in preventing stenosis of the trabeculectomy drainage fistula. Additionally, it has improved the outcomes of dacryocistorhinostomy^[6,7,8]. MMC has been used more recently in ENT procedures such as laryngotracheal stenosis repairs, to maintain patency in myringotomy, and its use in sinus surgery has been successfully studied^[9,10].

PATIENTS AND METHODS:

The current study is a prospective comparative study performed at the department of Otorhinolaryngology, Minia University from February 2014 hospital to July 2015 to evaluate the effect of MMC in prevention of nasal adhesions after endoscopic nasal surgery. A total of thirty patients of different age groups and both sexes were involved in the study. We excluded from the study any patient with the following: 1-Patients with unilateral affection of nose

and paranasal sinuses. 2- Prior paranasal sinus surgery with nasal adhesion. 3- Patient has hemoglobin less 10 gm/dl. Transient exclusion until correction of anemia (more than 12 gm/dl). 4-Patient refuses to do the operation. To obtain a concentration of 0.5 mg/ml of MMC, the content of the 5 mg vial is dissolved, on the same day, into 10 ml of saline; this solution has a characteristic light violet colour and is effective for 2 weeks if kept in the refrigerator. If it is kept at room temperature (15° - 30°) it is effective for 7 days^[11]. Patients were divided in two groups (A and B), each group includes 15 patients. Informed consent was taken from each patient after

explanation of the procedure to them. In Group (A) Primary FESS procedures were performed in 15 patients 9 patients had bilateral pansinusitis, 6 cases had bilateral nasal polyposis. MMC was applied at the site of middle meatal antrostomy on one side only, while the contralateral side served as the control, so we had 15 MMC applied antrostomys & 15 control antrostomys. In Group (B) 15 Endoscopic bilateral partial inferior turbinectomy in 15 patients. MMC was applied between residual of right inferior turbinate and the septum, while the contralateral side served as the control, so we had 15 MMC applied in one cavity & 15 control side. In Group (A) all cases were subjected to Functional endoscopic sinus surgery, Misserklinger technique under hypotensive general anesthesia by staff members of E.N.T department, faculty of medicine, Minia University. Septoplasty was carried out when indicated. (Fig. 1). At the end of the surgical procedure a cotton pledges (2.0-cm²) of 0.5 mg/ml MMC solution were placed for 5 min at the site of right middle meatal antrostomy in all patients. In The contralateral side served as the control in all cases. No intranasal splints were used. In Group (B) all cases were subjected to Endoscopic Partial inferior turbinectomy (PIT) under hypotensive general anesthesia by staff members of E.N.T department, faculty of medicine, Minia University. At the end of the surgical procedure a cotton pledges (2.0-cm²) of 0.5 mg/ml MMC solution were placed for 5 min between the residual of right inferior turbinate and the septum in all patients. In The contralateral side served as the control all cases. No intranasal splints were used. The results were analyzed at 2 months follow up.

RESULTS:

The age of patients involved in the study ranged from 21 to 52 years with a mean of 32.53 ± 9.47 years in Group (A) & from 15-44 years with a mean of 32.93 ± 9.03 years in Group (B). The age distribution in both groups is depicted in (Table 1). As regard sex distribution, In group (A) 6 (40%) males and 9 (60%) females. In Group (B) 6 (40%) males and 9 (60%) females. The data is represented in (Table 2). In Group (A) one patient (6.7%) had adhesion at Rt. Side and 7 patients (46.7%) had adhesions at Lt.

Side, while 14 patients (93.3%) had no adhesion at Rt. Side and 8 patients (53.3%) had no adhesion on Lt. Side. The difference was statistically significant ($P = 0.013$) in group (A). The data of Group(A) is represented in (Table 3). In Group (B) 3 patients (20%) had adhesion at Rt. Side and 9 patients (60%) had adhesions at Lt. Side, while 12 patients (80%) had no adhesion at Rt. Side and 6 patients (40%) had no adhesion on Lt. Side. The difference was statistically significant ($P = 0.025$) in group (B). The data of Group (B) is represented in (Table 4). Comparison between the 2 groups of the study as regards adhesions is represented in (Table 5) and (Fig. 2). 8 patients (53.3%) had adhesions in group (A) while 11 patients (73.3%) had adhesions in group (B). 7 patients (46.7%) had no adhesions in group (A) while 4 patients (26.7%) had no adhesions in group (B). The difference was not statistically significant ($P = 0.256$).

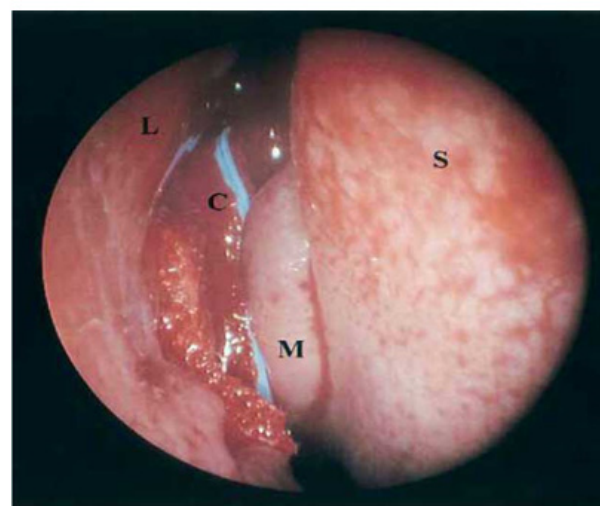


Fig. 1: Intraoperative view of mitomycin C application. Piece of gauze (C) saturated with mitomycin C is placed in the middle meatus (S, septum; L, lateral nasal wall; M, middle turbinate).

Table 1: Age Distribution of subjects

Age	Group (A) (FESS) N=15	Group (B) (Turbinectomy) N=15	<i>P</i> value
Range			
Mean ± SD	(21-52) 32.53 ± 9.47	(15-44) 32.93 ± 9.03	0.907

Table 2: Distribution of Patients According to Sex

Sex	Group (A) (FESS)	Group (B) (Turbinectomy)	<i>P</i> value
Male	6 (40%)	6 (40%)	1
Female	9 (60%)	9 (60%)	

Table 3: Comparison between adhesions in group (A)

Group (A) (FESS)	RT side	Lt side	<i>P</i> value
Adhesions	14 (93.3%)	8 (53.3%)	0.013
No	1 (6.7%)	7 (46.7%)	

Table 4: Comparison between adhesions in Group (B)

Group (B) (Turbinectomy)	RT side	Lt side	P value
Adhesions	12 (80%)	6 (40%)	0.025
No	3 (20%)	9 (60%)	

Table 5: Comparison in adhesion between group (A) and group (B)

	Group (A) (FESS) N=15	Group (B) (Turbinectomy) N=15	P value
Polyposis	9 (60%)	NA*	NA
No	6 (40%)		
Adhesions	7 (46.7%)	4 (26.7%)	0.256
No	8 (53.3%)	11 (73.3%)	

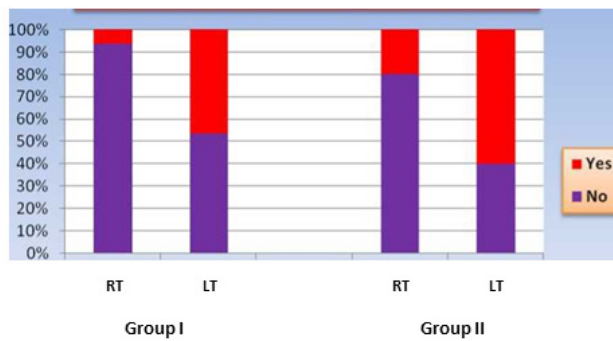


Fig. 2: Adhesions at Different Sides in Both Groups

DISCUSSION:

There are several reasons for endoscopic surgery failure such as abnormality of mucociliary transport, persistent disease and osteomeatal complex obstruction^[3,4]. The last one is of major importance and can be a result of adhesion formation and antrostomy stenosis. This is suggested by Musy and Kountakis^[12] who reported that the commonest anatomic finding in revision endoscopic surgery was an obstructed osteomeatal complex and specifically a stenosed middle meatal antrostomy in 39% of cases. Moreover, other authors suggested that the degree of antrostomy patency is directly related with the patient symptoms^[13].

Partial inferior turbinectomy is a procedure directed at relieving nasal obstruction by removing enlarged part of turbinate while leaving a portion of turbinate to continue its function of air conditioning. There are various studies which had shown that partial inferior turbinectomy is as effective procedure in relieving nasal obstruction as total inferior turbinectomy with success rate ranging from 70 to 80%^[14]. Partial inferior turbinectomy carry complications including hemorrhage, damage to surrounding structures, adhesions, dryness, crusting, nasal obstruction (Ball valve effect) and irritation as shown by various studies^[15].

Various measures have been tried to reduce adhesion formation. Malki D showed morbidity associated with

nasal splints does not justify their use in routine nasal surgery^[16]. Splints added significantly to post-operative discomfort in both groups, with no demonstrable benefit to the patient.

MMC is an antibiotic derived from the bacteria *S. caespitosus*. Its use as a topical agent is well established in ophthalmology in the treatment of pterygium, ocular surface squamous neoplasia and glaucoma surgeries^[17] in otolaryngological surgeries, it is used to reduce complications from post-operative scarring. It does so by inhibiting collagen deposition and fibroblast proliferation in wounds^[18]. In rhinology, its use is mainly in reducing the adhesions following endoscopic surgeries. Earlier animal studies by^[19] reported a delay in fibrosis which allowed re-epithelialization to take place before scar tissue forms, thus increasing the success rate of FESS^[19].

Gupta and Motwani, 2006 in a study of 30 patients who underwent functional endoscopic sinus surgery for CRS and at the completion of the operation, 1 ml of MMC in a concentration of 0.4 mg/ml was placed in either the right or left middle meatus randomly for 4 minutes and saline was placed in the contra lateral side so each patient acts as his own control, they found One patient showed adhesions on MMC Side and Eleven patients showed adhesions on Saline Side. So they found MMC may be topically applied in post-operative FESS cases to reduce adhesion formation and hence the need for revision surgery^[20]. This agrees with our result. Venkatraman *et al*, 2012 in prospective, randomized controlled trial involving 50 patients with chronic bilateral rhinosinusitis found that the routine use of topical MMC at the end of endoscopic surgery reduce the incidence of synechiae and also improve patients' symptoms score in the early post-operative period^[21]. This agrees with our result. Anil Harugop *et al*, 2014 in a prospective hospital based interventional study, 42 patients diagnosed to have chronic rhino sinusitis (CRS) underwent FESS. He found that 3.1% cases showed adhesions so Topical application of MMC at the conclusion of FESS/ESS has a role in prevention of adhesion formation^[22]. And this also agrees with our study. Also our study agrees with a study by Baradaranfar *et al*, 2011 on 37 patients was studied with follow up period 3-5 months (mean 3.5 month). In 19 patients (51.4%) MMC was placed on the right side and in 18 patients (48.6%) was placed on the left. Of total 14 adhesions occurred during follow up period (4 in MMC side and 10 occurred on control side). These results shown above indicate that MMC reduce postoperative adhesions and results were near significant (P=0.058)^[23]. Similarly, our study agrees with Chung *et al*, 2002 who studied 55 patients with resistant bilateral chronic rhinosinusitis. In the study by Chung *et al*, patients were followed for 4.1 months. Unilateral adhesions were observed in 10 patients (18%) (2 (3.6%) in sides treated with MMC and 8 in control side (14.5%)). The results were near significant (P = 0.058)^[24].

But a study by Anand *et al*, 2004 on 29 patients with chronic rhinosinusitis resistant to medical treatment, MMC impregnated mesh and saline impregnated mesh randomly were used for each side of nasal cavity at the end of the surgery show that the incidence of adhesion (9 cases of 29) between the two sides has no significant statistical difference^[25] and this disagree with our results. Also a study by Yamaoka and Gregorio, 2012 which done on 14 patients. in this study eight cases of unilateral synechia, one patient had synechia in the side treated with MMC and seven had it in the control side as (z test, p = 0.07). So, MMC was not effective in preventing middle meatus synechia, but reduced the probability of total synechia formation^[26] and this disagrees with our results.

CONCLUSIONS:

The results of this study demonstrate that the topical use of MMC is beneficial in decreasing adhesion formation after endoscopic nasal surgery, decrease incidence of middle meatal antrostomy stenosis after FESS operations. It also proved to be safe as regards local or general complications. Anyhow, MMC begins to have a wide range of application in the field of rhinology and in the future, it will play an important role after endoscopic sinus surgery based on further researches like our study.

FUNDING:

This study was supported by personal funds and funds from Minia University.

CONFLICT OF INTEREST:

There are no conflict of interest

REFERENCES:

1. Smith LF and Brindley PC. Indications, evaluation, complications, and results of functional endoscopic sinus surgery in 200 patients. *Otolaryngol Head Neck Surg* 1993; 108:688-96.
2. Matthews BL, Smith LE, Jones RJ, *et al*. Endoscopic sinus surgery: outcome in 155 cases. *Otolaryngol Head Neck Surg* 1991; 104:244-6.
3. Ramadan HH. Surgical causes of failure in endoscopic sinus surgery. *Laryngoscope*. 1999; 109: 27-29.
4. Chambers DW, Davis WE, Cook PR, *et al*. Long-term outcome analysis of functional endoscopic sinus surgery: correlation of symptoms with endoscopic examination findings and potential prognostic variables. *Laryngoscope*. 1997; 107: 504-510.
5. Hu D, Sires BS, Tong DC, *et al*. Effect of brief exposure to mitomycin C on cultured human nasal mucosa fibroblasts. *Ophthal Plast Reconstr Surg* 2000; 16:119-25.
6. Kao SC, Liao CL, Tseng JH, *et al*. Dacryocystorhinostomy with intraoperative mitomycin C. *Ophthalmology* 1997; 104:86-91.
7. Helal M, Messiha N, Amayem A, *et al*. Intraoperative mitomycin-c versus postoperative topical mitomycin-c drops for treatment of pterygium. *Ophthalmic Surg Lasers*. 1996; 27(8):674- 8.
8. Ugurbas SH, Zilelioglu G, Sargon MF, *et al*. Histopathologic effects of mitomycin-c on endoscopic transnasal dacryocystorhinostomy. *Ophthalmic Surg Lasers*. 1997; 28(4):300- 4.
9. Rahbar R, Valdez TA and Shapshay SM. Preliminary results of intraoperative mitomycin-C in the treatment and prevention of glottic and subglottic stenosis. *J Voice*. 2000; 14:282-6.
10. Estrem SA and Vanleeuwen RN. Use of mitomycin C for maintaining myringotomy patency. *Otolaryngol Head Neck Surg*. 2000; 122(1):8-10.
11. Parul Singh and Abhishek Singh. Mitomycin-C Use in Ophthalmology. *IOSR Journal of Pharmacy* 2013; Volume 3, Issue 1, PP 12-14.
12. Mucy PY and Kountakis SE. Anatomic findings in patients undergoing revision endoscopic sinus surgery. *Am J Otolaryngol*. 2004; 25: 418-422.
13. Salam MA and Wengraf C. Concho-antropexy or total inferior turbinectomy for hypertrophy of the inferior turbinates: a prospective randomized study. *J Laryngol Otol* 1993; 107:1125 8.
14. Ross DA and Nguyen DB. "Inferior turbinectomy in conjunction with septodermoplasty for patients with hereditary hemorrhagic telangiectasia" *Laryngoscope* 2004; April 114(4):779-81.
15. Garth RJ, Cox HJ and Thomas MR. Hemorrhage as a complication of inferior turbinectomy: a comparison of anterior and radical trimming. *Clin Otolaryngol* 1995; 20: 236-238.
16. Malki D and Quine SM. Nasal splints, revisited. *J Laryngol Otol* 1999; 113(8):725-727.
17. Abraham LM, Selva D, Casson R, *et al*. Mitomycin: clinical applications in ophthalmic practice. 2006; *Drugs* 66(3):321-340 (review).

18. Roh JL, Koo BS, Yoon YH, *et al.* Effect of topical mitomycin C on the healing of surgical and laser wounds: a hint on clinical application. *Otolaryngol Head Neck Surg* 2005; 133(6):851-856.
19. Ingrams DR, Volk MS, Biesman BS, *et al.* Sinus surgery: does mitomycin C reduce stenosis? *Laryngoscope* 1998; 108(6):883- 886.
20. Gupta M and Motwani G. Role of mitomycin C in reducing adhesion formation following endoscopic sinus surgery. *JLO* 2006; 120:921-3.
21. Venkatraman V, Balasubramanian D, Gopalkrishnan S, *et al.* Topical Mitomycin C in Functional endoscopic sinus surgery. *Eur Arch Otorhinolaryngol* 2012; 269:1791-1794 DOI 10.1007/s00405-011-1870-x.
22. Anil Harugop, Shailaja M. Hugar, *et al.* Effectiveness of mitomycin-c for prevention of adhesion formation after functional endoscopic sinus surgery (FESS/ESS) in cases of chronic rhinosinusitis: a prospective hospital based interventional study. *Journal of Evidence based Medicine and Healthcare* 2014; Volume 1, Issue 15, December 15, Page: 1901-1908.
23. Baradaranfar MH, Jalal Khadem, Shokooh Taghipoor Zahir, *et al.* Prevention of adhesion after endoscopic sinus surgery: role of Mitomycin C"; *Acta Med Iran*, 2011 Mar; 49 (3): 131-135.
24. Chung JH, Cosenza MJ, Rahbar R, *et al.* Mitomycin C for the prevention of adhesion formation after endoscopic sinus surgery: A randomized, controlled study. *Otolaryngol Head Neck Surg* 2002; 126:468-74.
25. Anand V. Epidemiology and economic impact of rhinosinusitis. *Ann otol rhinol laryngol* 2004; 113:3-5.
26. Yamaoka WY and Gregorio LC. The use of Mitomycin-C to reduce synechia in middle meatus in sinus surgery: preliminary results. *Braz J Otorhinolaryngol.* 2012;78(5):44-50.