

## Ranibizumab Versus Aflibercept for Treatment of Diabetic Macular Edema

Attia Mostafa Elsayed, Mostafa Mahmoud Mostafa, Ashraf Abdul-Ati Abdul-Moati Mohamed\*

Department of Ophthalmology, Faculty of Medicine, Al-Azhar University

\*Corresponding author: Ashraf Abdul-Ati Abdul-Moati Mohamed, Mobile: (+20)01111500934,

Email: abdelatyashraf35@gmail

### ABSTRACT

**Background:** Diabetic macular edema, a manifestation of diabetic retinopathy that impairs central vision, affects approximately 750,000 people in the United States and is a leading cause of vision loss. The increasing prevalence of diabetes worldwide highlights the importance of diabetic macular edema as a global health issue.

**Objective:** The aim of this study is to compare the clinical effects and complications of intravitreal injection of Ranibizumab and aflibercept as anti-VEGFs for treatment of patients with diabetic macular edema.

**Patients and methods:** This cross-sectional comparative study involved 40 eyes of 32 patients approved to have diabetic macular edema. All subjects had age and sex matched and they are collected from the Ophthalmology Department, Al-Agoza Police Hospital and Sayed Galal Hospital at the period of March 2017 to March 2019.

**Results:** Comparison between both groups I and II as regard UCVA and BCVA shows a statistically non-significant difference ( $P > 0.05$ ). Visual acuities before and after 6 months of injection in both groups were compared and showed a statistically significant difference as regard VA change ( $P < 0.05$ ) in Ranibizumab group (I) and highly statistically significant difference ( $P < 0.01$ ) in Aflibercept group (II). Although the effect of both groups in treatment seems to be comparable, significance of aflibercept was superior to ranibizumab as it showed more success in treatment of DME.

**Conclusion:** Our findings suggest a possible benefit of aflibercept over ranibizumab for treating DME. This study equally suggests better efficacy of aflibercept compared to ranibizumab, in patients with worse levels of initial visual acuity.

**Keywords:** Ranibizumab, Aflibercept, Diabetic Macular Edema.

### INTRODUCTION

Diabetic macular edema (DME) is one of the most common causes of vision reduction in patients with diabetic retinopathy<sup>(1)</sup>. More recent meta-analysis of 22,896 diabetic patients showed that the prevalence of DME was 6.81%. There are several therapies for DME such as focal/grid laser photocoagulation, corticosteroids, subthreshold micropulse diode laser photocoagulation, and pars plana vitrectomy<sup>(2)</sup>.

Diabetic macular edema, a manifestation of diabetic retinopathy that impairs central vision, affects approximately 750,000 people in the United States and is a leading cause of vision loss. The costs associated with visual disability and treatments of diabetic macular edema are high. The increasing prevalence of diabetes worldwide highlights the importance of diabetic macular edema as a global health issue<sup>(3)</sup>.

Intravitreal (IV) injections of vascular endothelial growth factor (VEGF) antibodies have become the gold standard therapy for DME worldwide. Several clinical trials strongly suggest that repeated intravitreal injections of anti-VEGF antibodies significantly improved the visual acuity of patients with DME<sup>(4)</sup>. However, frequent anti-VEGF injections are prohibitive for most patients because of the high costs of the anti-VEGF drugs<sup>(2)</sup>.

Vascular endothelial growth factor (VEGF) is an important mediator of abnormal vascular permeability in diabetic macular edema. Intravitreal injections of anti-VEGF agents have been shown to be superior to laser photocoagulation of the macula, the standard treatment for diabetic macular edema since the 1980s<sup>(5)</sup>. In 2013, an estimated 90% of retinal specialists in the United

States reported using anti-VEGF therapy for initial management of vision loss from diabetic macular edema involving the macular center<sup>(6)</sup>.

Two commonly used intravitreal VEGF inhibitors — aflibercept (Eylea, Regeneron Pharmaceuticals), and bevacizumab (Avastin, Genentech) have been shown to be beneficial and relatively safe for the treatment of diabetic macular edema. Of the anti-VEGFs only aflibercept and ranibizumab are approved by the Food and Drug Administration (FDA) for this indication<sup>(6,7)</sup>.

To provide comparative efficacy and safety data, the Diabetic Retinopathy Clinical Research Network (DRCR.net), sponsored by the National Institutes of Health, conducted a randomized clinical trial to compare intravitreal aflibercept and bevacizumab for the treatment of diabetic macular edema involving the center of the macula and causing vision impairment<sup>(8)</sup>.

### AIM OF THE WORK

The aim of this study is to compare the clinical effects and complications of intravitreal injection of Ranibizumab and aflibercept as anti-VEGFs for treatment of patients with diabetic macular edema.

### SUBJECTS AND METHODS

This cross-sectional comparative study involved 40 eyes of 32 patients approved to have diabetic macular edema. All subjects had age and sex matched and they are collected from the Ophthalmology Department, Al-Agoza Police Hospital and Sayed Galal Hospital at the period of March 2017 to March 2019.

**I- Study design:****1) Type of the study:**

The study represents a prospective non-randomized controlled study on forty eyes in which repeated intravitreal injections of both drugs equally used for treatment diabetic macular edema.

**2) Research questions:**

1. Is there a variation of macular thickness with diabetic macular edema and had intravitreal injection of A. Ranibizumab compared to eyes injected intravitreally by Aflibercept in regression of edema measured by OCT?
2. Is there a variation on local and systemic complications?
3. Recurrence rate
4. Number of injections.

**3) Subjects and Sample size:**

Forty eyes of 32 patients represent the target patients of this study; they are classified into two equal groups each of 20 eyes:

- Group (I): 20 eyes were treated by intravitreal injection of Ranibizumab (Lucentis).
- Group (II): 20 eyes were treated by intravitreal injection of Aflibercept (Eylea).

**II- Technical Design:**

All patients were subjected to the following:

- Personal history: name, age, sex, residence and occupation.
- Past history:
  - History of previous medical illness.
  - History of previous drug intake.
  - History of ocular illness and treatment.
- Full local examination including:
  - Uncorrected and best corrected visual acuity (BCVA) measured by standard decimal visual acuity.
  - Intraocular pressure measurement: Applanation tonometer.
  - Anterior segment examination by slit lamp biomicroscopy.
  - Posterior segment examination by indirect ophthalmoscopy and slit lamp biomicroscopy with non-contact +78D or +90 D lens.
  - OCT to measure the macular thickness.
  - Fundus fluorescein angiography (FFA).

**Protocol Approval by Ethical Committee:**

Before the beginning of the study and in accordance with the local regulation followed, the protocol and all corresponding documents were declared for Ethical and Research approval by the Ophthalmology Department, El-Agoza Police Hospital and Sayed Galal university, Al-Azhar university.

**Ethical issues:**

The study was approved by the Ethics Board of Al-Azhar University and an informed written consent was taken from each participant in the study.

**Intravitreal injection:**

For each agent, the injection volume was 0.05 ml in each drug. Injections were performed with the use of topical

anesthetic. A sterile lid speculum was used, and povidone-iodine was applied to the injection site. The use of pre injection and post injection antibiotics.

Patients were injected intravitreally by the selected drug according to their group, then injection repeated after one month and the third injection was performed after the 2<sup>nd</sup> month.

**Dosing:****A. Ranibizumab (Lucentis):**

Adult: 0.5 mg (0.05 mL of 10 mg/mL solution) intravitreal injection once per month (~q28 days) x3 months.

**B. Aflibercept (Eylea):**

The recommended dose for aflibercept is 2 mg (0.05 mL or 50 microliters) administered by intravitreal injection every 4 weeks (monthly) for the first 5 injections, followed by 2 mg (0.05 mL) via intravitreal injection once every 8 weeks (2 months).

**Procedure of injection:**

Intravitreal injections should be given in a clean room. Injections can be given in an operating theatre, but operating theatre protocols mean that it can take 15 minutes to prepare the patient and make the necessary checks, which may be an inefficient use of staff time. The patients should be lying flat on a comfortable couch or bed, which should be high enough to give the injections without bending over.

**Equipment**

- Anti-VEGF drug
- Syringe – usually 1 ml as only a very small volume (0.05–0.1 ml) is injected
- Large bore needle – for drawing up the drug
- 30g needle – for giving injection
- 5% (aqueous) povidone iodine solution for disinfection of skin and conjunctiva
- Local anesthetic drops
- Topical antibiotic drops
- Sterile cotton buds
- Sterile gloves
- Drapes
- Eyelid speculum
- Caliper or other measuring device

**Technique <sup>(9)</sup>:**

- First, the eye and eyelids are anesthetized using drops or gel so the injection doesn't hurt.
- The eye and the eyelids are then cleaned and sterilized usually using povidone-iodine, which is very effective at killing bacteria.
- Hands scrubbing and wearing sterile gloves, and wearing a sterile gown.
- An eyelid speculum is often used to keep the eyelids open during the procedure.
- The local anesthetic drug takes a few minutes to work, so drawing up the anti-VEGF while waiting. A sterile technique to draw up 0.1 ml into the 1 ml syringe, using a large bore needle. Empty the air from the syringe and fit the 30 G needle on the syringe.

Eject the surplus drug until there is 0.05 ml left in the syringe.

- Topical antibiotic drops are instilled.
- Using the measuring caliper or some other measuring device, measure a safe distance behind the limbus in the inferotemporal quadrant. In patients who have had cataract surgery, this is 3.5 mm. In patients who are phakic, it is 4 mm.
- Once the eye is prepared for injection, the patient will be asked to look in a particular direction depending on the location of the injection. The patient is warned that we are about to inject, insert the needle quickly and inject the drug through the pars plana, then remove the needle.
- Topical antibiotic drops, and check that the patient's vision is unaffected. Sometimes injection of even a small volume of fluid will cause a sharp rise in intraocular pressure. If this happens, the patients notice a transit loss of vision. An immediate paracentesis is done to release aqueous from the anterior chamber. If this is not possible, however, ocular massage will usually lower the IOP.
- Topical antibiotic drops are prescribed for 4 days after the injection.

**Follow-up:**

Complete ophthalmic examination was performed just after injection especially IOP measurement (paracentesis may be required to decrease the elevated IOP in some cases), and examination of anterior segment of the eye.

Patients were followed up after one day, 3 days, one week, one month and six months after last injection.

Each visit the visual acuity was determined and the central macular thickness was measured by OCT.

The visual acuity and macular thickness was recorded and comparison between pre and post-injection at the end of the follow-up period.

**Statistical analysis:**

Recorded data were analyzed using the statistical package for social sciences, version 20.0 (SPSS Inc., Chicago, Illinois, USA). Quantitative data were expressed as mean ± standard deviation (SD). Qualitative data were expressed as frequency and percentage.

**The following tests were done:**

- Independent-samples t-test of significance was used when comparing between two means.
- Chi-square ( $\chi^2$ ) test of significance was used in order to compare proportions between two qualitative parameters.
- The confidence interval was set to 95% and the margin of error accepted was set to 5%. The p-value was considered significant as the following:
  - Probability (P-value)
  - P-value <0.05 was considered significant.
  - P-value <0.001 was considered as highly significant.
  - P-value >0.05 was considered insignificant.

**RESULTS**

This study involved 40 eyes of 32 patients with diabetic macular edema (DME) classified into two groups; group (I): 20 eyes had intravitreal injection of Lucentis (Ranibizumab) and group (II): 20 eyes had intravitreal injection of Eylea (Aflibercept).

**Table (1):** shows that both age and sex were matched in both groups.

**Table (1):** Age and sex distribution of the studied groups (per eyes)

| Age (years) | Group (I)<br>N = 20 eye |       | Group (II)<br>N = 20 eye |      | Total<br>N = 40 eye |        |
|-------------|-------------------------|-------|--------------------------|------|---------------------|--------|
| Range       | 42 – 75                 |       | 45 – 76                  |      | 42 – 76             |        |
| Mean ± SD   | 59.3 ± 9.49             |       | 60.2 ± 10.78             |      | 59.8 ± 10.02        |        |
| Sex         | No.                     | %     | No.                      | %    | No.                 | %      |
| Males       | 9                       | 56.25 | 8                        | 50.0 | 17                  | 53.125 |
| Females     | 7                       | 43.75 | 8                        | 50.0 | 15                  | 46.875 |
| Total       | 16                      | 50.0  | 16                       | 50.0 | 32                  | 100    |

**Table (2):** shows uncorrected visual acuity (UCVA) and best corrected visual acuity (BCVA) between the two groups I and II. Comparison between both groups shows a statistically non-significant difference (P>0.05).

**Table (2):** Visual acuity (decimal values) of the studied groups before procedures

|      | Group (I)    | Group (II)   | $\chi^2$ | P value |
|------|--------------|--------------|----------|---------|
| UCVA | 0.158 ± 0.01 | 0.181 ± 0.02 | 0.1644   | 0.2446  |
| BCVA | 0.359 ± 0.2  | 0.398 ± 0.25 | 0.1818   | 0.3107  |

$\chi^2$  = Chi square, P > 0.05 = non-significant difference.

**Table (3):** shows visual acuity before and after 6 months of injection in both groups. Comparison between eyes before and after injection shows a statistically significant difference as regard VA change (P < 0.05) in Lucentis group (I) and highly statistically significant difference (P < 0.01) in Eylea group (II).

**Table (3):** Visual acuity before and after injection of both groups and the mean VA change after injection after 6 months of treatment

| Group      | Before       | After        | Change | $\chi^2$ | P value |
|------------|--------------|--------------|--------|----------|---------|
| Group (I)  | 0.359 ± 0.2  | 0.512 ± 0.32 | 0.153  | 0.4846   | 0.037*  |
| Group (II) | 0.398 ± 0.25 | 0.599 ± 0.38 | 0.201  | 0.6341   | 0.009*  |

\* P <0.05 = statistically significant, P <0.01 = highly significant.

**Table (4):** shows that there was a statistically highly significant difference between group I and group II after injection in all follow-up periods (P <0.01) while before injection, there was statistically non-significant difference (P >0.05) between both groups.

**Table (4):** Mean central macular thickness of the studied groups.

| Macular thickness          | Group (I) (□m)             | Group (II) (□m)            | $\chi^2$ | P value |
|----------------------------|----------------------------|----------------------------|----------|---------|
| Before injection           | 441.6 ± 133.1 <sup>#</sup> | 443.5 ± 142.8 <sup>#</sup> | 0.0144   | 0.1463  |
| One day after              | 425.8 ± 126.4              | 398.8 ± 85.12              | 0.6184   | 0.0007* |
| 1 month after              | 337.6 ± 70.28              | 302.7 ± 81.34              | 0.5633   | 0.0013* |
| 6 months after             | 303.4 ± 61.64 <sup>#</sup> | 287.6 ± 79.55 <sup>#</sup> | 0.5871   | 0.0017* |
| <sup>#</sup> paired t-test | 6.1281                     | 8.2315                     |          |         |
| P value                    | 0.003*                     | 0.001*                     |          |         |

\* P <0.01 = highly significant

Intergroup study showed a statistically highly significant difference between eyes before injection and 6 months after injection in both groups (P <0.01).

**Table (5):** shows that there was a statistically significant difference between group I and group II as regard changes in macular thickness after injection in all follow-up periods (P <0.05) while before injection, there was statistically non-significant difference (P >0.05) between both groups.

**Table (5):** Mean changes in macular thickness of the studied groups.

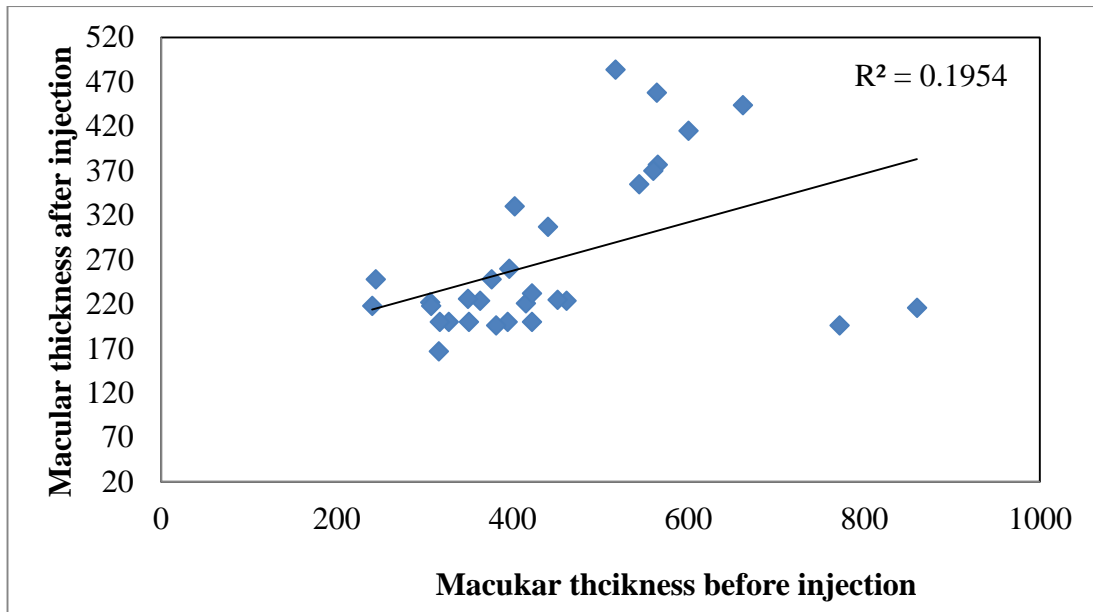
| Macular thickness          | Group (I) (□m)     | Group (II) (□m)    | Change (□m) | $\chi^2$ | P value |
|----------------------------|--------------------|--------------------|-------------|----------|---------|
| Before injection           | 441.6 <sup>#</sup> | 443.5 <sup>#</sup> | 1.9         | 0.1133   | 0.1463  |
| One day after              | 425.8              | 398.8              | -27.0       | 0.3442   | 0.017*  |
| 1 month after              | 337.6              | 302.7              | -34.9       | 0.3928   | 0.013*  |
| 6 months after             | 303.4 <sup>#</sup> | 267.6 <sup>#</sup> | -35.8       | 0.1987   | 0.05*   |
| <sup>#</sup> Change (□m)   | -138.2             | -175.9             |             |          |         |
| <sup>#</sup> paired t-test | 6.8771             | 9.3542             |             |          |         |
| P value                    | 0.000*             | 0.000*             |             |          |         |

\* P < 0.05 = statistically significant, P <0.01 = highly significant.

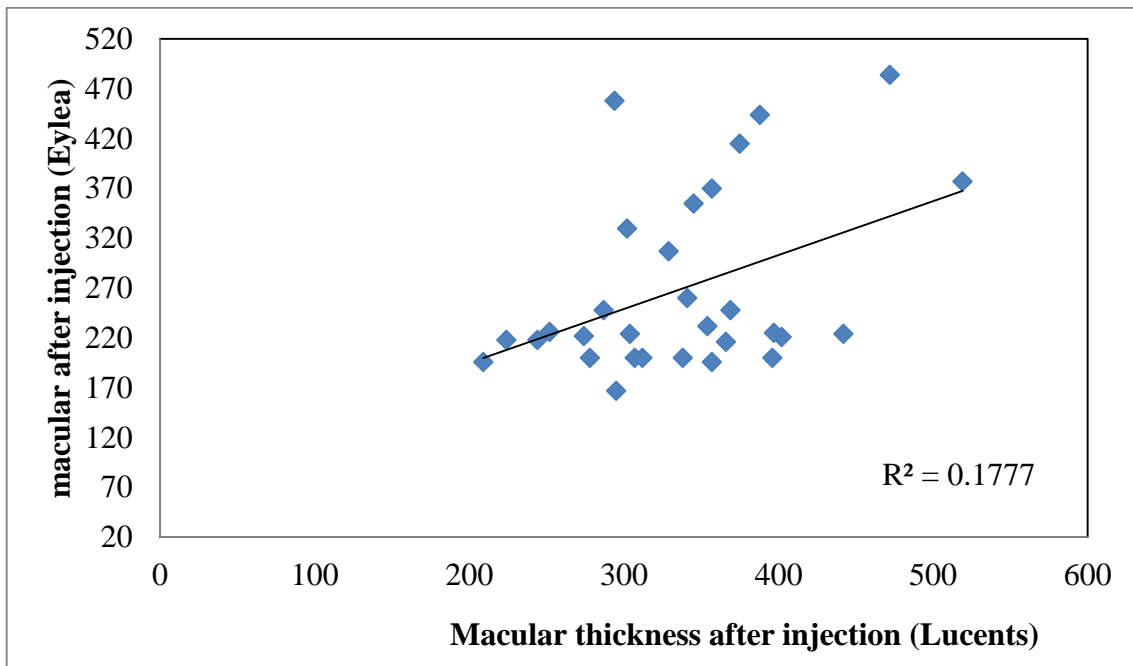
The minus sign (-) indicates decrease in macular thickness.

Intergroup study showed a statistically highly significant difference between eyes before injection and 6 months after injection in both groups as regard changes in macular thickness (P <0.01).

Linear regression curve showing the correlation coefficient (r) of macular thickness before and after injection by Eylea (group II). There is a statistically highly significant positive correlation presented in **Fig. (1)**.



**Fig. (1):** Linear regression curve showing the correlation coefficient (r) of macular thickness before and after injection by Eylea (group II). There is a statistically highly significant positive correlation ( $r = 0.442$ ,  $P < 0.001$ ). Linear regression curve comparing the correlation coefficient (r) of macular thickness after injection between Luents (group I) and Eylea (group II). There is a statistically highly significant positive correlation presented in **Fig. (2)**.



**Fig. (2):** Linear regression curve comparing the correlation coefficient (r) of macular thickness after injection between Luents (group I) and Eylea (group II). There is a statistically highly significant positive correlation ( $r = 0.4215$ ,  $P < 0.001$ ).

## DISCUSSION

The present study compares the clinical effects and complications of intravitreal injection of Ranibizumab and aflibercept as anti-VEGFs for treatment of patients with diabetic macular edema.

This study involved 40 eyes of 32 subjects with DME classified into two groups; group (I): 20 eyes had intravitreal injection of Lucentis (Ranibizumab) and group (II): 20 eyes had intravitreal injection of Eylea (Aflibercept). Both groups were age and sex matched.

Comparison between both groups I and II as regard UCVA and BCVA shows a statistically non-significant difference ( $P > 0.05$ ).

Visual acuity before and after 6 months of injection in both groups were compared and showed a statistically significant difference as regard VA change ( $P < 0.05$ ) in Ranibizumab group (I) and highly statistically significant difference ( $P < 0.01$ ) in Aflibercept group (II). Although the effect of both groups in treatment seems to be comparable, significance of aflibercept was superior to ranibizumab as it showed more success in treatment of DME.

Parallel to these results, **Pham *et al.*** <sup>(10)</sup> showed that, over 2 years of treatment, patients were as likely to attain vision gain with ranibizumab (37%) and aflibercept (39%). Aflibercept versus ranibizumab, showed statistically significant difference OR: 1.06 [95% CI = 0.82 to 1.37]. Over 2 years of treatment, approximately 98% of patients maintained their vision with the two drugs.

Patients with diabetic retinopathy have high vitreous levels of PIGF-1. Both aflibercept and ranibizumab effectively block vitreous VEGF-A, thereby inhibiting the activation of VEGF receptor 2. In addition, aflibercept, but not ranibizumab, blocks PIGF, thereby inhibiting the binding and activation of VEGF receptors 1 and 2 <sup>(11)</sup>.

As regard central macular thickness (CMT), there was a statistically highly significant difference between group I and group II after injection in all follow-up periods ( $P < 0.01$ ) while before injection, there was statistically non-significant difference ( $P > 0.05$ ) between both groups. Intergroup study showed a statistically highly significant difference between eyes before injection and 6 months after injection in both groups ( $P < 0.01$ ). The changes in macular thickness showed a statistically significant difference between group I and group II as regard changes in macular thickness after injection in all follow-up periods ( $P < 0.05$ ) while before injection, there was statistically non-significant difference ( $P > 0.05$ ) between both groups. Intergroup study showed a statistically highly significant difference between eyes before injection and 6 months after injection in both groups as regard changes in macular thickness ( $P < 0.01$ ).

Nine months after the approval of IVR, IVA was approved for on-label use for DME treatment in Japan.

Thus, **Shimizu *et al.*** <sup>(2)</sup> had a chance to examine the effectiveness of intravitreal injection of aflibercept (IVA) on DME eyes that were refractory to intravitreal injection of ranibizumab (IVR) treatment. They suggested that IVA may be effective in reducing the CMT in DM eyes refractory to IVR, as observed by our study. However, IVA did not improve the BCVA in eyes refractory to IVR injection.

Conversion to aflibercept resulted in significant reduction of central macular thickness; however, a trend toward improved visual acuity was observed without statistical significance <sup>(12)</sup>.

**Wood *et al.*** <sup>(13)</sup> prospectively recruited 14 diabetic eyes undergoing single aflibercept injection for macular edema refractory to prior ranibizumab and/or bevacizumab therapy. One month after intravitreal aflibercept, 79% (11 of 14 eyes) of patients had reduced macular thickness and significant anatomic improvement with a 23% decrease in average central subfield foveal thickness. However, 21% (3 of 14 eyes) had stable or worsening edema.

In the present study, only one eye in the aflibercept group and none in the ranibizumab group had no injections in the first 3 months after the initial three loading doses. This may suggest that a loading dose of three intravitreal injections may not be enough in those eyes. In protocol T <sup>(13)</sup>, there was no loading doses, and the treatment was given monthly as needed from the start, but the number of injections in the first 6 months was comparable. Many studies proved the efficacy and safety of ranibizumab intravitreal injection in the treatment of DME <sup>(14)</sup>.

**Wells *et al.*** <sup>(8)</sup> studied the effect of aflibercept, bevacizumab, and ranibizumab for DME. They concluded that the relative effect of these drugs depended on baseline visual acuity. When the initial visual acuity loss was mild, there were no apparent differences, on average, among the study groups. At worse levels of initial visual acuity, aflibercept was more effective at improving vision. In the present study, the baseline visual acuity was between 0.25 and 0.1, which is a common presenting visual acuity in parts of the world without a tight diabetic retinopathy screening program.

All eyes in **Fouda and Bahgat** <sup>(15)</sup> study were injected with anti-VEGF agents with the loading dose of three injections (with 1 month interval), then during the follow-up period, the anti-VEGF was re-injected when the macular edema was still present. The mean number of aflibercept was  $2.62 \pm 0.68$  and that of ranibizumab was  $3.03 \pm 0.95$  with significant difference between the two drugs ( $P = 0.02$ ), which coincides with our results.

**Sorour *et al.*** <sup>(16)</sup> measured the macular vessel density after intravitreal ranibizumab or aflibercept for treatment of DME and found no effect of vessel density prior to status post-injections. Anatomic response in relation to the presence of macular non-perfusion at

baseline, in which there were no significant differences in the efficacy of ranibizumab between patients with and without macular non-perfusion at baseline.

**Chen *et al.*** <sup>(12)</sup> stated that more than 1 line of visual loss and unchanged macular thickness were found in 20% of cases switched to intravitreal aflibercept. The authors also reported that pre-switch visual acuity and presence of epiretinal membrane were not related to aflibercept response.

**Wells *et al.*** <sup>(17)</sup> found rates of ocular adverse events, including endophthalmitis and post-injection inflammation, remained low through 2 years with all 3 agents. Systemic Anti-Platelet Trialists' Collaboration (APTC) rates were higher in the ranibizumab group, with a greater number of non-fatal strokes and vascular deaths in the ranibizumab group. Although the P-values increased slightly after adjusting for a history of prior stroke or myocardial infarction and other potential confounders, this did not substantially alter the results. These findings have not been demonstrated consistently in previously reported clinical trials.

**Chen *et al.*** <sup>(12)</sup> identified previous vitrectomy as the only risk factor associated with aflibercept non-responsiveness in the present study. This may be attributable to the rapid clearance of intravitreal aflibercept from the vitreous cavity, limitation of aflibercept exposure to the retina, and insufficient therapeutic levels of aflibercept in vitrectomized eyes. In vitrectomized human eyes with DME, intravitreal bevacizumab has been shown to result in incomplete responses in visual acuity and/or macular thickness after short-term follow-up <sup>(18)</sup>. Therefore, vitrectomized eyes may be at greater risk of being refractory to aflibercept in diabetic patients <sup>(12)</sup>.

Although in exudative age-related macular degeneration (AMD) the treatment efficacy of ranibizumab and aflibercept seems to be comparable <sup>(19)</sup>, there is possibly a treatment difference between the two drugs in DME. Aetiopathogenesis of macular edema in diabetes is not identical to that of exudative AMD. Although some aetiopathogenic mechanisms of DME are similar to those of macular edema in exudative AMD (e.g. increased ocular VEGF activity), other mechanisms are different (e.g. role of PIGF in DME) <sup>(20)</sup>.

**Vandekerckhove** <sup>(21)</sup> have a switch trial with aflibercept in poor responders to ranibizumab in the setting of exudative AMD and noted anatomical and functional benefits after switching patients to aflibercept. Still, in none of the 37 eyes of that study, the extent of the benefit of switching treatment to aflibercept came close to the dramatic aflibercept efficacy reported here. Unlike DME (shown in the present study), ranibizumab was as effective as aflibercept in patients with AMD <sup>(10)</sup>.

This study has several limitations. First, this was a prospective study on small numbers of eyes. In addition, the duration of this study was short. Thus, further studies

on a larger number of patients and for a longer period are needed to compare the efficacy of IVR and IVA in eyes with DME.

The small number samples used in this study did not give accurate data for statistical analysis and lack of DME classification to early and late DME and lack of different types of macular edema that give an idea about the effect of the two drugs on each type is considered the second limitation of this study.

No comment on early and late onset complications of the two drugs (during intravitreal injection, just after intravitreal injection, long-term complications) is considered another limitation of this study.

## CONCLUSIONS AND RECOMMENDATIONS

The results of this case study show that aflibercept can be used to effectively treat DME in eyes with resistance to ranibizumab. Our findings suggest a possible benefit of aflibercept over ranibizumab for treating DME. This study equally suggests better efficacy of aflibercept compared to ranibizumab, in patients with worse levels of initial visual acuity.

Still, the findings of this study are worthwhile in giving hints on differential effects of anti-VEGF agents in different retinal diseases and seem in line with those of the previous studies, a large head-to-head study between aflibercept and ranibizumab in patients with DME is supposed to be investigated in the future.

## REFERENCES

- O'Doherty M, Dooley I, and Hickey-Dwyer M (2008):** Interventions for diabetic macular edema: a systematic review of the literature. *British Journal of Ophthalmology*, 92: 1581–1590.
- Shimizu N, Oshitari T, Tatsumi T *et al.* (2017):** Comparisons of efficacy of intravitreal Aflibercept and Ranibizumab in Eyes with Diabetic Macular Edema. *Biomed Res Int.*, 12: 174-78.
- Varma R, Bressler NM, Doan QV *et al.* (2014):** Prevalence and risk factors for diabetic macular edema in the United States. *JAMA Ophthalmol.*, 132:1334–1340.
- Brown DM, Schmidt-Erfurth U, Do DV *et al.* (2015):** Intravitreal aflibercept for diabetic macular edema: 100-week results from the VISTA and VIVID studies. *Ophthalmology*, 122: 2044–2052.
- Nguyen QD, Brown DM, Marcus DM *et al.* (2012):** Ranibizumab for diabetic macular edema: results from 2 phase III randomized trials: RISE and RIDE. *Ophthalmology*, 119:789–801.
- Arevalo JF, Lasave AF, Wu L *et al.* (2013):** Intravitreal bevacizumab plus grid laser photocoagulation or intravitreal bevacizumab or grid laser photocoagulation for diffuse diabetic macular edema: results of the Pan-American Collaborative Retina Study Group at 24 months. *Retina*, 33:403–413.
- Korobelnik JF, Do DV, Schmidt-Erfurth U *et al.* (2014):** Intravitreal aflibercept for diabetic macular edema. *Ophthalmology*, 121: 2247–2254.

8. **Wells JA, Glassman AR, Ayala AR *et al.* (2015):** Aflibercept, bevacizumab, or ranibizumab for diabetic macular edema. *N Engl J Med.*, 372: 1193-1203.
9. **Yorston D (2014):** Intravitreal injection technique. *Community Eye Health*, 27: 47.
10. **Pham B, Thomas SM, Lillie E *et al.* (2019):** Anti-vascular endothelial growth factor treatment for retinal conditions: a systematic review and meta-analysis. *BMJ Open*, 9: e022031.
11. **Papadopoulos N, Martin J, Ruan Q *et al.* (2012):** Binding and neutralization of vascular endothelial growth factor (VEGF) and related ligands by VEGF Trap, ranibizumab and bevacizumab. *Angiogenesis*, 15:171–185.
12. **Chen YY, Chang PY, and Wang JK (2017):** Intravitreal Aflibercept for patients with diabetic macular edema refractory to Bevacizumab or Ranibizumab: analysis of response to Aflibercept. *Asia Pac J Ophthalmol (Phila)*, 6: 250-255.
13. **Wood EH, Karth PA, Moshfeghi DM *et al.* (2015):** Short-term outcomes of aflibercept therapy for diabetic macular edema in patients with incomplete response to ranibizumab and/or bevacizumab. *Ophthalmic Surg Lasers Imaging Retina*, 46:950-954.
14. **Egan C, Zhu H, Lee A *et al.* (2017):** The United Kingdom diabetic retinopathy electronic medical record users group, report 1: baseline characteristics and visual acuity outcomes in eyes treated with intravitreal injections of ranibizumab for diabetic macular oedema. *Br J Ophthalmol.*, 101: 75–80.
15. **Fouda SM and Bahgat AM (2017):** Intravitreal aflibercept versus intravitreal ranibizumab for the treatment of diabetic macular edema. *Clin Ophthalmol.*, 11: 567-571.
16. **Sorour OA, Sabrosa AS, Yasin Alibhai A *et al.* (2019):** Optical coherence tomography angiography analysis of macular vessel density before and after anti-VEGF therapy in eyes with diabetic retinopathy. <https://www.ncbi.nlm.nih.gov/pubmed/31119505>
17. **Wells JA, Glassman AR, Ayala AR *et al.* (2016):** Aflibercept, Bevacizumab, or Ranibizumab for diabetic macular edema: Two-Year Results from a comparative effectiveness randomized clinical trial. *Ophthalmology*, 123: 1351-1359.
18. **Okamoto Y, Okamoto F, Hiraoka T *et al.* (2014):** Vision-related quality of life and visual function following intravitreal bevacizumab injection for persistent diabetic macular edema after vitrectomy. *Jpn J Ophthalmol.*, 58:369-374.
19. **Schmidt-Erfurth U, Kaiser PK, Korobelnik JF *et al.* (2014):** Intravitreal aflibercept injection for neovascular age-related macular degeneration: ninety-six-week results of the VIEW studies. *Ophthalmology*, 121:193–201.
20. **Miller JW, Le Couter J, Strauss EC *et al.* (2013):** Vascular endothelial growth factor A in intraocular vascular disease. *Ophthalmology*, 120:106–114.
21. **Vandekerckhove KR (2015):** Aflibercept versus ranibizumab for treating persistent diabetic macular edema. *Int Ophthalmol.*, 35: 603-609.