

Clinical and radiographic evaluation of buccal pad of fat versus sandwiched Bio-Oss® bone graft in closure of oroantral communication

Original
Article

Salah ElAbbasy

Department of Oral and Maxillofacial Surgery, Faculty of Oral and Dental Medicine, Cairo University, Cairo, Egypt

ABSTRACT

Aim: Evaluation of buccal fat pad versus sandwiched Bio-Oss bone graft in the management of oroantral communication.

Materials and Methods: This study was carried out on 12 patients with oroantral communication. They were divided into 2 groups, 6 patients in each. In Group A, the patients were managed with sandwiched Bio-Oss bone graft technique, while in group B, the patients were treated with buccal fat pad technique.

Results: There was no significant difference between the two groups regarding pain, swelling and infection during different follow up periods. No recurrence for the oroantral communication was observed in all patients of both groups after one month postoperatively. Panoramic radiographs showed an evidence of bone formation in all the patients of Group A and in zero patients in Group B after 3 months postoperatively.

Conclusion: No recurrence for the oroantral communication was observed in all patients of both groups at the end of the clinical follow up period after 1 month. In group A, new bone formation was evident in the panoramic x-rays after 3 months postoperatively where this can allow implant placement at the site of closure. On the other hand, patients in group B didn't show any evidence of new bone formation and no implants can be placed unless further surgical procedures are carried out.

Key Words: Buccal fat pad, oroantral communication, sandwiched bone graft.

Received: 28 May 2019, **Accepted:** 17 June 2019

Corresponding Author: Salah ElAbbasy, Department of Oral and Maxillofacial Surgery, Faculty of Oral and Dental Medicine, Cairo University, **Tel.:** 01001408066, **E-mail:** drsalahosman@hotmail.com

ISSN: 2090-097X, January 2019, Vol. 10, No. 1

INTRODUCTION

Oroantral communication is one of the complications that may occur during extraction of maxillary posterior teeth, sinus lifting procedures or due to trauma^[1]. Communications of 2mm diameter and less can heal spontaneously while those larger than 2mm may require surgical intervention due to inflammation of the maxillary sinus and the periodontal region^[2,3].

Many surgical techniques have been introduced for the closure of oroantral communications including buccal advancement flaps, palatal rotational flaps and their modifications.⁴ The disadvantage of the buccal flap techniques include reduction of the vestibular sulcus that may require vestibuloplasty in a second surgery while the disadvantage of the palatal flap technique include denudation of the palate resulting in severe pain^[5, 6, 7].

Many materials have been used in closure of oroantral communications such as gold mesh^[8], hydroxyapatite blocks^[9] and freeze-dried collagen^[10]. Bio-gide collagen

membrane combined with bio-oss bone graft have shown excellent results in closure of oroantral communications specially when the bone is sandwiched between two layers of the membrane because the porous surface of the membrane allow the growth of bone forming cells. The Bio-Oss graft material is highly pure, didn't show any allergic reactions or infections and is nearly similar to human bone^[10].

Histological studies showed that the buccal pad of fat is able to transform into granulation tissue then epithelialize over a period of 3-4 weeks resulting in a great success in the closure of oroantral communications^[2, 4].

MATERIALS AND METHODS

Twelve patients (8 females and 4 males) with oroantral communications were selected from the Oral and Maxillofacial Surgery department, Faculty of Dentistry, Cairo University with an age range between 21 and 42 years. Patients suffering from systemic diseases were excluded from the study.

The patients were divided into two groups, six patients in each. In the first group (A), the closure of the oroantral communication was performed utilizing the sandwiched Bio-Oss bone graft technique while in the second group (B), the oroantral closure was managed utilizing buccal fat pad technique. Both techniques were performed under local anaesthesia 4% Articaine hydrochloride with epinephrine 1:100,000.

Sandwiched bone graft technique:

Two layers of collagen membrane were sutured together from three sides using 4-0 vicryl suture. The bio-oss graft material was inserted through the fourth side which was closed later in a similar manner like the previous three sides. A three line trapezoidal buccal mucoperiosteal flap was reflected and the sandwiched bone graft was inserted through the defect in a way to form a convex surface towards the sinus and a concave surface towards the alveolar ridge (Fig. 1) and further Bio-Oss graft was inserted to fill this concavity. Cutting through the periosteum was performed whenever required to provide tension-free suturing. The flap was repositioned and sutured in place.

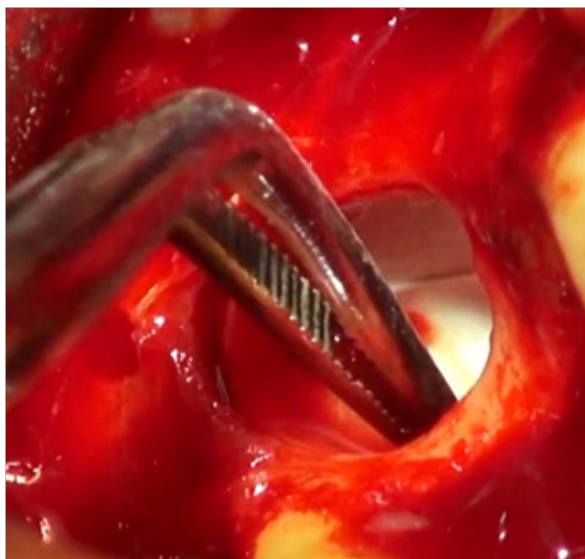


Fig. 1: Showing the sandwiched graft tucked inside the defect with concave side facing the alveolar ridge

Buccal Pad of fat technique:

A full thickness trapezoidal buccal mucoperiosteal flap was reflected. The buccal pad of fat was accessed through an incision performed in the inner side of the reflected periosteum posterior to the zygomatic buttress (Fig. 2). The buccal fat pad was advanced slowly over the

bony defect and sutured in place using 4-0 vicryl sutures (Fig. 3). The flap was repositioned to cover the fatty tissue and was sutured in place.

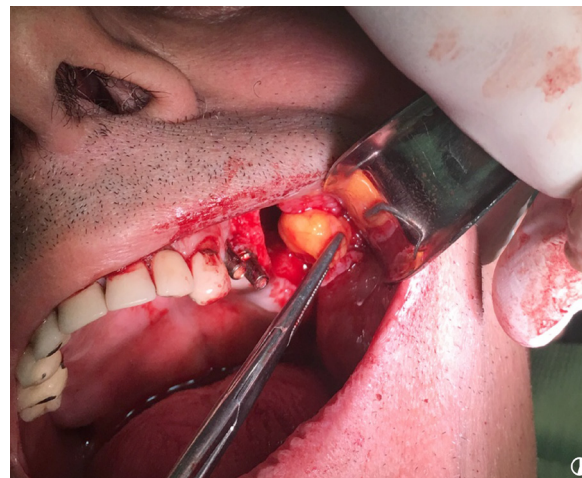

Fig. 2: Showing the buccal pad of fat accessed and advanced towards the defect.

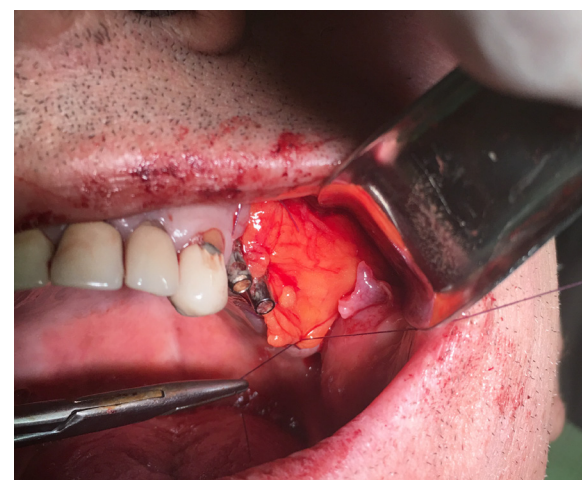

Fig. 3: Showing the buccal pad of fat covering the defect and sutured in place

RESULTS

Three patients in group A and 2 patients in group B were presented with an oroantral communication size of 4-6 mm². Two patients in both groups were presented with oroantral communication size of 6-9 mm². One patient in Group A and 2 patients in group B were presented with a communication size of more than 9 mm² (Table 1).

Table 1: Showing the size of the bony defect for group A and group B

Size (mm ²)	Group A		Group B	
	No.	%	No.	%
4-6	3	50	2	33.3
6-9	2	33.3	2	33.3
>9	1	16.6	2	33.3

The pain scores for each patient in both groups was recorded immediate postoperatively and 1, 3 and 10 days

as well as 1 month postoperatively and the mean scores for both groups were calculated (Table 2).

Table 2: Showing postoperative mean pain scores for group A and group B during the follow up period.

	Mean pain score for group A	Mean pain score for group B	<i>P</i>
Immediate post-operative	7 ± 0.65	7.5 ± 0.72	0.539
1 Day	3.5 ± 0.59	4.1 ± 1.08	0.597
3 Days	1.6 ± 1.11	2.1 ± 1.21	0.356
10 Days	0.5 ± 0.39	0.8 ± 0.89	0.922
1 Month	0.16 ± 0.67	0.16 ± 0.44	0.897

After 1 day, swelling was present in all the patients in both groups. After 3 days, swelling was present in 4 patients in group A and 5 patients in group B. After 10 days postoperatively, swelling

was present in only 2 patients in both groups. At the end of the follow up period, none of the patients in both groups were presented with swelling (Table 3).

Table 3: Showing the postoperative swelling present in group A and group B

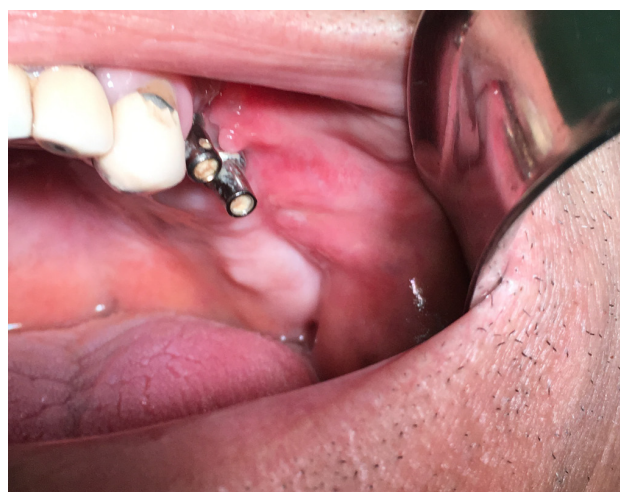	Swelling % in group A	Swelling % in group B
1 Day	100	100
3 Days	66.6	83.3
10 Days	33.3	33.3
1 Month	0	0

Infection was present in one patient (16.6%) in group A and 2 patients (33.3%) in group B after 1 day postoperatively. One patient in group A and zero patients in group B were presented with infections after 3 and 10 days postoperatively. After 1 month, no patients were

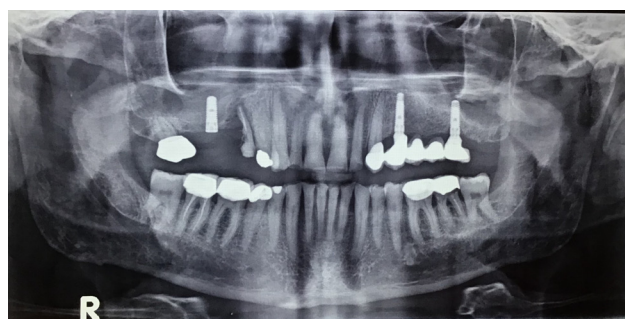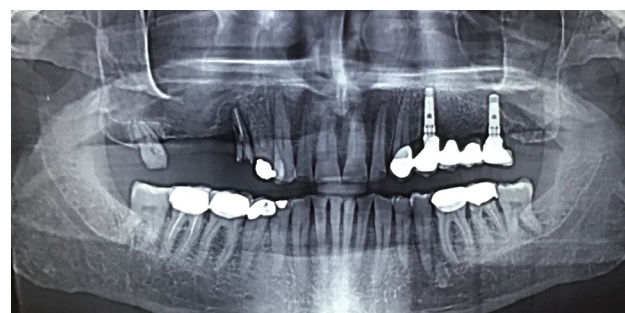presented with infection in both groups (Table 4). No recurrence for the oroantral communication was observed for all the patients in both groups at the end of the clinical follow up period after 1 month (Fig. 4).

Table 4: Showing the presence of postoperative infection in group A and group B.

	Infection % in group A	Infection % in group B
1 Day	16.6	33.3
3 Days	16.6	0
10 Days	16.6	0
1 Month	0	0

**Fig. 4:** Showing the healed surgical site after 1 month of closure utilizing buccal fat pad technique

Panoramic radiographs showed an evidence of bone formation in all the patients of group A and in zero patients in group B after 3 months postoperatively (Fig. 5, 6).

**Fig. 5:** Panoramic radiograph showing a failed dental implant perforating the maxillary sinus resulting in oroantral communication after removal**Fig. 6:** Panoramic radiograph showing evidence of bone formation after 3 months from placing the sandwiched graft and closing the oroantral communication

DISCUSSION

Growth of the maxillary sinus begins during the third month of intrauterine life and ends between 18-20 years of human life, However its size increases due to pneumatization after extraction of maxillary posterior teeth without implants insertion, so the risk of occurrence of oroantral communication is higher in adults than in children due to bigger size of the maxillary sinus. In our study the age range of the patients selected was from 21-42 years old which agrees with the study published by Guven^[1] who reported that oroantral communications most frequently occurs after the 3rd decade of life.

In the present study, the size of the oroantral communication in both groups were greater than 4 mm in diameter which correlates with the finding of Punwutikorn *et al.*^[1] reporting that oroantral communications having a diameter of 2 mm and less has a great possibility of spontaneous healing while bigger defects usually require surgical intervention due to increased risk of inflammation of the maxillary sinus associated with large bony defects. In our study, 66.6 % of the patients were

females while 33.3% of the patients were males and this agrees with the finding of Ehrh^[12], Skoglund *et al.*^[13] and Punwutikorn *et al.*^[1] who reported that females have larger sinuses than males and are more liable to sinus perforations.

Signs and symptoms were evaluated in this study according to previous investigation performed by Pappachan and Vasant^[14] and there were no significant difference between the 2 groups at any time interval regarding pain, swelling and infections.

Significant radiographic evidence of bone formation appeared in group A patients after 3 months postoperatively. Our results showed that Bio-Oss® exhibited good osteoconductive potential, this is in agreement with animal studies and clinical trials published by Zitzmann *et al.*^[15], Slotte *et al.*^[16], Norton *et al.*^[17] who reported that Bio-Oss® is a biocompatible substance that does not cause inflammation, allergies or any toxic reactions.

No evidence of new bone formation was observed in group B patients. This coincides with the results of Chien *et al.*^[18], Collela *et al.*^[19] and Adeyemo *et al.*^[20] who reported that the main disadvantage of the buccal fat pad technique is the lack of bone formation where the patients may require further surgical procedures if dental implants is to be considered at a later time.

CONCLUSION

Clinical outcomes concerning pain, swelling, recurrence and infections, showed no statistically significant difference between both groups. In group A, New bone formation was evident in the panoramic x-rays after 12 weeks postoperatively where this can allow implant placement at the site of closure. On the other hand, patients in group B didn't show any evidence of new bone formation and consequently no implants can be placed unless further surgical procedures are carried out.

CONFLICT OF INTEREST

There are no conflicts of interest.

REFERENCES

1. Punwutikorn J, Waikakul A, Pairuchvej V. Clinically significant oroantral communications--a study of incidence and site. *Int J Oral Maxillofac Surg* 23:19-21, 1994.
2. Killey HC, Kay LW. An analysis of 250 cases of Oro-antral fistula treated by the buccal flap operation. *Oral Surg Oral Med Oral Pathol* 24:726-39, 1967.
3. Yih WY, Merrill RG, Howerton DW. Secondary closure of oroantral and oronasal fistulas: A modification of existing techniques. *J Oral Maxillofac Surg* 46:357-64, 1988.
4. Kraut RA, Smith RV. Team approach for closure of oroantral and oronasal fistula. *Atlas Oral Maxillofac Surg Clin North Am* 8:55-75, 2000.
5. Ehrh PA. Oroantral communication: Epicritical study of 175 patients, with special concern to secondary operative closure. *Int J Oral Surg* 9:351-8, 1980.
6. Visscher SH, van Roon MR, Sluiter WJ, van Minnen B, Bos RR. Retrospective study on the treatment outcome of surgical closure of oroantral communications. *J Oral Maxillofac Surg* 69:2956-61, 2011.
7. Kitagawa Y, Sano K, Nakamura M, Ogasawara T. Use of third molar transplantation for closure of the oroantral communication after tooth extraction: A report of 2 cases. *Oral Surg Oral Med Oral Pathol Oral Radiol Endod*;95:409-15, 2003.
8. Abuabara, A., Cortez, A.L., Passeri, L.A. *et al.*, Evaluation of different treatments for oroantral/oronasal communications: experience of 112 cases. *Int J Oral Maxillofac Surg*. 35:155, 2006.
9. Zide MF, Karas ND. Hydroxylapatite block closure of oroantral fistulas: Report of cases. *J Oral Maxillofac Surg* 50:71-5, 1992.
10. Ogunsalu C. A new surgical management for oroantral communication: The resorbable guided tissue regeneration membrane--bone substitutes sandwich technique. *West Indian Med J* 54:261-3, 2005.
11. Güven O. A clinical study on oroantral fistulae. *J Craniomaxillofac Surg* 26:267-71, 1998.
12. Ehrh PA. OAC, epicritical study of 175 patients, with special concern to the secondary operative closure. *Int J Oral Surg* 9:35, 1980.
13. Skoglund LA, Pedersen SS, Holst E. Surgical management of 85 perforations to the maxillary sinus. *Int J Oral Surg* 12:1-5, 1983.
14. Pappachan B, Vasant R. Application of bilateral

- pedicled buccal fat pad in wide primary cleft palate. *Br J Oral Maxillofac Surg* 46:310-2, 2008.
15. Zitzmann, N. U., Scharer, P., Marinello, C. P., Schupbach, P., and Berglundh, T. Alveolar ridge augmentation with Bio-Oss: a histologic study in humans. *Int J Periodontics Restorative Dent*, 21(3); 288-295, 2001.
 16. Slotte, C., Lundgren, D., and Burgos, P. M. Placement of autogenic bone chips or bovine bone mineral in guided bone augmentation: a rabbit skull study. [Comparative Study Research Support, Non-U.S. Gov't]. *The International journal of oral and maxillofacial implants*, 18(6); 795-806, 2003.
 17. Norton, M. R., Odell, E. W., Thompson, I. D., and Cook, R. J. Efficacy of bovine bone mineral for alveolar augmentation: a human histologic study. *Clin Oral Implants Res* 14(6); 775-783, 2003.
 18. Chien CY, Hwang CF, Chuang HC, Jeng SF, Su CY. Comparison of radial forearm free flap, pedicled buccal fat pad flap and split-thickness skin graft in reconstruction of buccal mucosal defect. *Oral Oncol* 41:694-7, 2005.
 19. Colella G, Tartaro G, Giudice A. The buccal fat pad in oral reconstruction. *Br J Plast Surg* 57:326-9, 2004.
 20. Adeyemo WL, Ladeinde AL, Ogunlewe MO, Bamgbose BO. The use of buccal fat pad in oral reconstruction - a review. *Niger Postgrad Med J* 11:207-11, 2004.