Suez Canal University Medical Journal Vol. 16 (1), 2013
Pages 37-44

Interleukin-10 Protects Rat Liver from CCl4-induced Fibrogenesis *via* Inhibition of Hepatic Stellate Cells Activation

Wael A. Nasr El-Din[1*], Gamal M. Abdel-Rahman[1], Alaa El-Din S. Abdel El Hamed[2], Amr A. Kamel[3]

Departments of [1]Anatomy, [2]Clinical Pathology, and [3]Pathology, Faculty of Medicine, Suez Canal University, Egypt

Abstract

Background: **After liver injury, hepatic stellate cells (HSCs) lose vitamin A and transform into myofibroblasts (MFB), called activated HSCs, which express α-SMA and have the function of contractibility, proliferation, and fibrogenesis. IL-10 is active as an antifibrogenic drug able to reduce the α-SMA expression in ongoing fibrogenesis.** ***Aim:*** **To study the effect of interleukin-10 on the expression of α-smooth muscle actin (α-SMA), in hepatic stellate cells of experimental rats with hepatic fibrosis.** ***Materials and Methods:*** **one hundred and eight rats were divided equally into two groups: control and CCl_4-treated group, which subdivided into 3 subgroups, a group immediately puts into death after treatment, spontaneous recovery (SR) group, and IL-10-treated group. Each group included 27 rats. Serum alanine aminotransferase (ALT), aspartate aminotransferase (AST) and albumin were assessed. Livers were taken out and processed for the expression of tissue α-smooth muscle actin (α-SMA) by immunohistochemical assay.** ***Results:*** **serum ALT and AST were significantly higher in rats injected with CCl_4 (90.01±2.77 IU/L and 56.42±3.27 IU/L, $P < 0.05$ each), moderately reduced in the SR group (58.26±1.94 IU/L and 37.18±2.31IU/L, $P < 0.05$ each), and significantly reduced by administration of IL-10 (28.77±2.03IU/L and 37.18±2.31 IU/L, $p< 0.05$ each). The expression of α-SMA in the hepatic cells was strong in CCl_4-induced fibrosis group compared to the control group ($p< 0.05$). The expression was moderate in the spontaneous recovery group, but less than CCl_4-treated group and was significantly reduced in IL-10-treated group.** ***Conclusions:*** **IL-10 is an active antifibrogenic drug that reduces α-SMA expression in ongoing fibrogenesis.**

Keywords: Liver fibrosis, IL-10, α-SMA

Introduction

Hepatic fibrosis, a precursor of cirrhosis, is characterized by an excessive generation of extracellular matrix constituents (particularly collagens) that impair normal function with progression of liver disease to cirrhosis[(1)]. Liver fibrosis is a reversible wound-healing response to either acute or chronic cellular injury that reflects a balance between liver repair and scar formation. During acute injury, the changes in liver architecture are transient and reversible. With chronic injury, there is progressive substitution of the liver parenchyma by scar tissue[(2)]. The composition of liver fibrous scarring is similar to all lesions regardless of the cause of the lesion (hepatitis B or C viruses, schistosomiasis, drugs, alcohol, autoimmune or metabolic diseases such as hemochromatosis, Wilson's disease, etc.)[(3)]. In 1876, von Kupffer described liver *Sternzellen* (star-shaped cells).

**Corresponding Author: waelamin2010@yahoo.com*

The functions of these cells remained mysterious for 75 years until "Ito" observed lipid-containing perisinusoidal cells in human liver. In 1971, "Wake" demonstrated that the *Sternzellen* of von Kupffer and the fat-storing cells described by Ito were identical. Wake also established that these cells were important sites of vitamin A storage. In addition, they play a cardinal role in storage and release of retinoids[4]. Studies on the pathogenesis of hepatic fibrosis have shown that HSCs within the space of Disse experience a transform, in the wake of liver injuries by various causes. In normal liver, HSCs store vitamin A and show minimal proliferation and collagen synthesis. However, in an injured liver, HSCs lose vitamin A and transform into myofibroblasts (MFB), called activated HSCs, which express α-SMA and have the function of contractibility, proliferation, and fibrogenesis[5]. HSCs synthesize a number of collagens, and enzymes that inhibit degeneration of extracellular matrix (ECM), and some cytokines that promote fibrosis. Thus, the balance between the deposition and the degeneration of ECM is broken, leading to the startup and development of hepatic fibrosis[6].

Interleukin-10 (IL-10), initially discovered in 1989, is a cytokine synthesis inhibitory factor for T lymphocytes[7]. It has anti-inflammatory and immunomodulatory effects and can regulate production of inflammatory cytokines, such as interleukin-1, interferon- gamma and interleukin-2 from T cells. It is produced by other cells of the immune system, including the liver. Within the liver, production of IL-10 has been documented within hepatocytes, sinusoidal cells, kupffer cells, stellate cells and liver-associated[8]. It was reported that endogenous IL-10 can decrease intrahepatic inflammatory response and fibrosis in several models of liver injury[9]. Previous studies indicate that exogenous IL-10 down regulates collagen type I in cultured HSCs and hepatic fibrosis and up regulates metalloproteinase gene expression *in vitro*. It also exerts antifibrogenic effect by down regulating profibrogenic cytokines such as Transforming growth factor beta 1 (TGF-β1) and Tumor Necrosis Factor alpha (TNF-α)[10,11]. This study was carried out to investigate the effect of interleukin-10 on the expression of α-smooth muscle actin (α-SMA), in hepatic stellate cells of experimental rats with hepatic fibrosis.

Materials and Methods

Animals

One hundred and eight adult male albino rats used in this study weighing about 180-280 g. All animals received food and water ad libitum and were housed in spacious wire mesh cages at room temperature.

Experimental design

The animals were divided into four main groups: Group A: The control group, which was injected subcutaneously with saline (2 ml/kg) twice a week for nine weeks. Group B: The experimental group which was injected subcutaneously with 0.2 mL/100 g of CCl_4 (Algomhoria company, Egypt) (dissolved 1:1 in sterile olive oil) twice a week for nine weeks for induction of hepatic fibrosis. This group was subdivided into: *Group B1:* The experimental group was put immediately to death after induction of fibrosis by CCl_4. *Group B2:* The experimental group was left for spontaneous recovery for three weeks after induction of fibrosis by CCl_4 and then put to death. *Group B3:* The experimental group which was treated with IL-10 (4 µg/kg) subcutaneously three times a week for three weeks after induction of fibrosis by CCl_4 and then put to death[12].

Biochemical parameters

Activities of alanine transaminase (ALT),

aspartate aminotransferase (AST) and albumin in serum were measured by routine laboratory methods[13].

Immunohistochemical Techniques
Kits used:
1- Primary antibodies: *(Lab Vision Neomarker USA).* Anti-rat monoclonal antibody against α-SMA suitable for immunohistochemical staining of formalin-fixed paraffin-embedded sections. 2-Detection system: *(Lab Vision Neomarker USA* Streptavidin-Biotin amplification kit which reacts with rat primary antibodies, using Horse-radish Peroxidase enzyme (HRP) and diaminobenzidine (DAB) as a chromogen.

Staining protocol:
Paraffin embedded sections were cut at 5 um thickness and processed for the immunohistochemical staining using anti α-smooth muscle actin as follows[14]: 1- Paraffin sections were deparaffinized with xylene for one hour, and rehydrated in descending grades of ethanol, and then rinsed in distilled water. 2- Endogenous peroxide quenching was done by immersing slides in 30% hydrogen peroxide solution for five minutes to reduce non-specific background staining. 3- Slides were washed two times in phosphate buffered saline (PBS) for five minutes each. 4- Serum blocking solution (10% non- immune rabbit serum) were added to each slide, incubated in a humidity chamber for 30 minutes, then drained and blotted off the slides (but not rinsed) to block nonspecific background staining. 5- Two drops of monoclonal antibodies were applied to each section and incubated for one hour at room temperature. 6- Sections were washed three times in PBS two minutes each. 7- Two drops of biotinylated secondary antibody were applied to each section at room temperature for 15 minutes and rinsed well with PBS three times for two minutes each. 8- Two drops of streptavidin-peroxidase were applied to each section at room temperature for 15 minutes and rinsed well with PBS three times for two minutes each. 9- Two drops of DAB solution were applied to all sections for 15 minutes. 10- Sections were washed in distilled water, then counterstained with hematoxylin. 11- Sections were dehydrated in ascending grades of ethanol and cleared in xylene. Two drops of Histomount were added to each slide, and mounted with a clean cover slip.
Positive control:
Positive reaction to α-SMA was confirmed using a slide prepared from human leiomyoma.
Negative control:
The primary antibody was omitted and replaced by PBS followed by incubation with the streptavidin-biotin amplification reagents as usual. Absence of labeling was the indication of specific binding of the primary antibody.
Interpretation:
Cells positive for α–SMA showed cytoplasmic brown deposits. Nuclei were blue. The expression was evaluated semi-quantitatively based on the staining extent by determining the percentage of positive cells on a x100 magnification in at least 5 areas. The percentage of immunoreactive cells were grouped as follows: negative: up to 3%, mild: 3 - 33%, moderate: 34 - 66% and marked: more than 66% of cells in the examined area.

Statistical analysis
Student's t- test by using the mean and standard deviation and ANOVA were used for mean of liver enzymes measurement by using SPSS 16.0 software *(SPSS Inc., Chicago, IL, USA).* SPSS was also used for Chi-square test for analysis α-SMA expression. $P < 0.05$ was considered statistically significant.

Results

I. Biochemical parameters:

Biochemical analyses of serum enzymes were performed to verify the role of IL-10 in the protection of the liver from injury. As shown in Table (1) and Figure (1), compared with those in the normal controls (26.29± 1.93IU/L and 12.73±1.37 IU/L), the activities of serum ALT, and AST were significantly higher in rats injected with CCl4 (90.01±2.77 IU/L and 56.42±3.27 IU/L). The activities of serum ALT and AST were significantly reduced administration of IL-10 (28.77± 2.03IU/L and 37.18±2.31 IU/L). Regarding serum albumin, its level was (2.77±0.26 mg/dl) in the control group, decreased to (2.02±0.3 mg/dl, p< 0.05) in CCl_4 treated group, increased to (2.38±0.23 mg/dl) in spontaneous recovery group and to (2.68±0.19 mg/dl near normal level) in IL-10 treated group. (Table 1 & Figure 2).

Table 1: ALT & AST Liver enzymes mean in the studied groups

	ALT (IU/L) Mean ± SD	AST (IU/L) Mean ± SD	ALB (mg/dl) Mean ± SD
Group (A) (n=27)	26.29 ± 1.93	12.73 ± 1.37	2.77 ± 0.26
Group (B1) (n=27)	90.01 ± 2.77 [b,c,d]	56.42 ± 3.27 [b,c,d]	2.02 ± 0.3 [b,c,d]
Group (B2) (n=27)	58.26 ± 1.94 [b,e]	37.18 ± 2.31 [b,e]	2.38 ± 0.23 [b,e]
Group (B3) (n=27)	28.77 ± 2.03[a]	13.74 ± 1.62	2.68 ± 0.19

ALT: alanine aminotransferase; AST: aspartate aminotransferase; ALB: albumin
ANOVA test: a=P<0.01 compared to control group; B=P<0.000001 compared to control group; c-=P<0.00001 compared to IL-10 treated group; d=P<0.0001 compared to S.R. group; e-=P<0.00001 compared to IL-10-treated group.

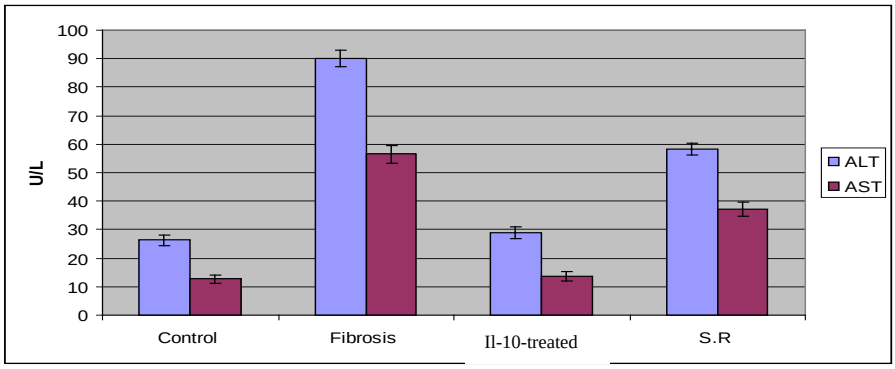

Figure 1: ALT & AST serum levels in the studied groups.

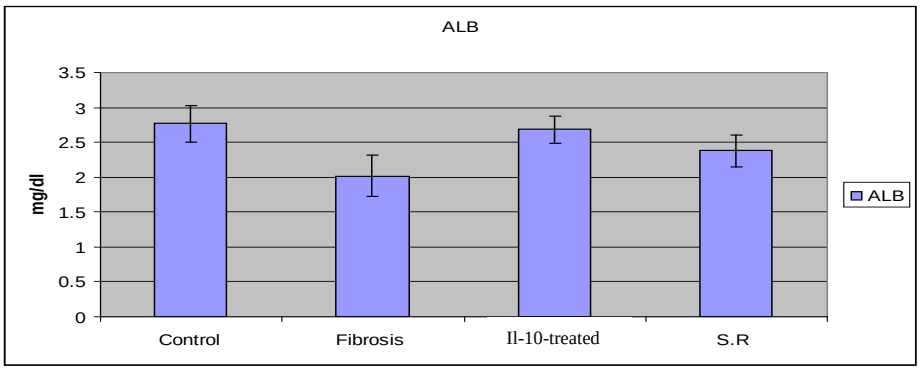

Figure 2: serum Albumin levels in the studied groups.

II. Immunohistochemical results

The experiment was performed to further evaluate the impact of IL-10 on regulating the expression of α-SMA, the marker of activated HSC. Liver sections from each group were immunolabeled with antibodies against α-SMA. The expression was evaluated semi-quantitatively based on the staining extent by determining the percentage of positive cells on a x100 magnification in at least 5 areas. The percentage of immunoreactive cells were grouped as follows: negative: up to 3%, mild: 3 - 33%, moderate: 34 - 66% and marked: more than 66% of cells in the examined area. As shown in Table (2), as expected, few cells in the liver sections of the normal group were recognized by antibodies against α-SMA, suggesting few activated HSC in the normal livers in the control rats (Figure 3A). Administration of CCl_4 caused a significant increase in the number of cells recognized by antibodies against α-SMA as compared to control group (marked immunoreactivity) (Figure 3B). In spontaneous recovery group there is a moderate number of cells recognized by antibodies against α-SMA (moderate immunoreactivity) (Figure 3B). IL-10 treatment significantly reduced the number of cells labeled with α-SMA antibodies as compared to CCl_4 treated group (Figure 3D), suggesting that IL-10 might suppress HSC activation in the rat model.

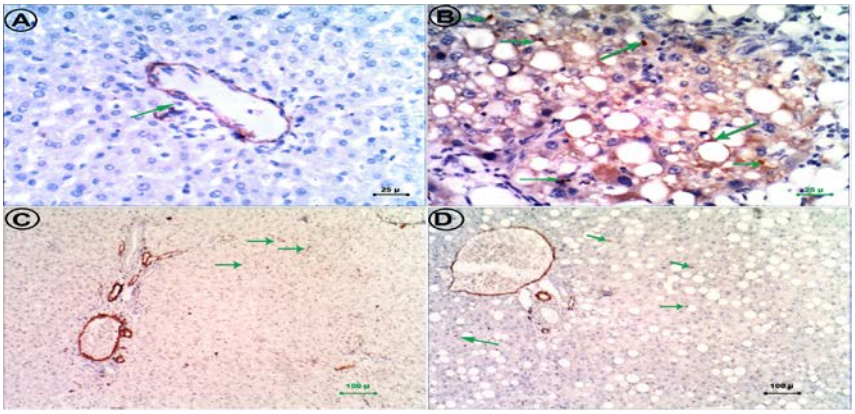

Figure 3A: a section of the liver of control group (A) showing faint reaction for α-SMA in the wall of a central vein. Note the absence of any observable reactivity to α-SMA in the hepatic lobule. (Immunostain 400X). **Figure 3B:** showing a section of the liver of a rat of CCl_4 treated group (B) showing Strong immunohistochemical staining for α-SMA antibody in between hepatic cords and individually encircling the degenerated vacuolated hepatocytes, indicated by arrows. (Immunostain 400X). **Figure 3C:** showing a section of the liver of a rat of group (C) showing moderate immunohistochemical staining for α-SMA antibody followed the bands of fibrous tissue between central veins and portal tracts indicated by arrows. (Immunostain, 100X). **Figure 3D:** showing a section of the liver of a rat of group (D) showing mild immunohistochemical staining for α-SMA antibody localized to the wall of central veins and portal tracts. A very few scattered brown deposits indicating α-SMA reactivity is seen throughout the hepatic lobules (Immunostain, 100X).

Table 2:"expression" of Alpha-smooth muscle actin (α-SMA) in the studied groups "liver sections

Group	The extension of α-SMA immunoreactivity			
	Neg.	Mild	Moderate	Marked
A (n=27)	27	0	0	0
B1 (n=27)	0	0	6	21
B2 (n=27)	0	2	8	17
B3 (n=27)	2	23	2	0

α-SMA= Alpha-smooth muscle actin; Neg=negative

Discussion

Hepatic fibrosis, which represents the wound healing response of the liver, is a common sequel of liver injury characterized by increased deposition and altered composition of the extracellular matrix (ECM)[15]. Hepatic stellate cells (HSCs) are the major source of ECM and regarded as the principal cell type in the development

of hepatic fibrosis[16]. In the present work, we have been using chemically induced fibrosis using a hepatotoxic agent. Carbon tetra-chloride (CCl_4) is the most commonly used liver-damaging agent to induce liver fibrosis. The administration of other several toxic compounds is used for induction of fibrosis, including dimethylnitrosamine, galactosamine, thioacetamide, and ethanol[21].

In the present study, the biochemical parameters were measured to verify the role of IL-10 in the protection of the liver from injury. ALT, AST and were within normal levels in the control group. These parameters were dramatically increased in CCl_4-induced fibrosis group. Also, these parameters were increased in the spontaneous recovery group, but less than the levels of CCl_4-induced fibrosis group. The activities of serum ALT and AST were significantly reduced by administration of IL-10 nearly close to the normal levels compared to control group. Dong, et al[13] reported that biochemical assay showed serum ALT activities and serum AST activities were markedly increased in rats injected with CCl_4 for 12 weeks, which are consistent with the histological observations. Dharancy et al[18] shown that IL-10 has no apparent antiviral activity, however, it normalizes serum ALT levels, improves liver histology, and reduces liver fibrosis in a large proportion (63–86%) of patients with chronic hepatitis C receiving treatment. Nelson et al [19] had treated 24 chronic hepatitis C patients with IL-10, they found that IL-10 normalized serum ALT levels, decreased hepatic inflammation, reduced liver fibrosis and was well tolerated in patients. This agrees with the results of the present work, not only in ameliorating the inflammatory response, but also in correction of the levels of liver enzymes. Regarding α-SMA expression, it was observed that the expression of α-SMA was negative in the control group, and marked in CCl_4-induced fibrosis group, moderate in the spontaneous recovery group. The administration of IL-10 in group D resulted in the improvement of the extension of α-SMA to show mild expression. A similar study was carried out by Zhang et al[16] and showed that α-SMA is expressed in activated hepatic stellate cells in the course of liver fibrosis. After the treatment with IL-10, the expression of α-SMA decreased, indicating that ectogenic IL-10 may release activated HSCs. Poonkhum et al[20] had confirmed that thioacetamide, like CCl4, is a potent inducer for four main fibrotic patterns of cirrhosis in rats, including bridging fibrosis and showed that α-SMA is expressed in activated hepatic stellate cells by immune-histochemical technique. Teixeira-Clerc, et al[21] investigated the consequences of cannabinoid 1 (CB1) receptor inactivation on progression of fibrosis in three experimental models: chronic CCl4 intoxication, chronic thioacetamide intoxication and bile duct ligation (BDL).

The number of liver fibrogenic cells was reduced in SR141716A-treated mice, as shown by decreased expression of α-SMA. These results show that genetic or pharmacological antagonism of CB1 receptors reduces the fibrogenic response associated with chronic liver injury, independent of the offending agent. From the findings briefly reviewed here, it seems that hepatic fibrosis, thought by many to be the activation of the satellite cells, can be much decreased by IL-10. Stellate cells must be studied from many points of view, its size, its strategic site, and its shape changes in different physiological conditions or pathological according to the use of pharmaceutical agents affecting these cells.

Conclusion

The present data provide evidence that IL-10 is active as an antifibrogenic drug able to

reduce the α-SMA expression in ongoing fibrogenesis.

References

1. Su LJ, Chang CC, Yang CH, Hsieh SJ, Wu YC, Lai JM, Tseng TL, Huang CY, Hsu SL. Graptopetalum Paraguayense ameliorates Chemical-Induced Rat Hepatic Fibrosis In Vivo and Inactivates Stellate Cells and Kupffer Cells In Vitro. PLoS ONE. 2013; 8 (1): e53988.
2. Friedman SL. Hepatic Fibrosis. In: Schiff ER, Sorrell MF, Maddrey WC, Eds. Sciff's Diseases of the Liver, Ninth Edition, Vol. 1. Philadelphia: Lippincott Williams &Wilkins 2003; p 409-427.
3. Hernandez P, David B, REGINO O, OVALLE WP, Luis F. Fibrogénesis hepática. Rev Col Gastroenterol 2010; vol.25, n.2, pp. 187-197.
4. Geerts A. History, Heterogeneity, Developmental Biology, and Functions of Quiescent Hepatic Stellate Cells. Semin Liver Dis. 2001; 21 (3):311-335.
5. Hellemans K, Rombouts K, Quartier E, Dittie AS, Knorr A, Michalik L, Rogiers V, Schuit F, Wahli W, Geerts A. PPARbeta regulates vitamin A metabolism-related gene expression in hepatic stellate cells undergoing activation. J Lipid Res. 2003; 44(2): 280-295.
6. Gallai M, Kovalszky I, Knittel T, Neubauer K, Armbrust T, Ramadori G. Expression of extracellular matrix proteoglycans perlecan, and decorin in carbon-tetrachloride- injured rat liver and in isolated liver cells. Am J Pathol. 1996; 148 (5); 1463-1471.
7. Fiorentino DF, Bond MW, Mosmann TR. Two types of mouse T helper cell. IV. Th2 clones secrete a factor that inhibits cytokine production by Th1 clones. J Exp Med 1989; 170 (6):2081-2095.
8. Le Moine O, Louis H, Sermon F, Goldman M, Deviere J. Interleukin-10 and liver diseases. Acta Gastroentrol Belg 1999; 62 (1): 1-8.
9. Louis H, Van Laethem JL, Wu W, Quertinmont E, Degraef C, Van den Berg K, Demols A, Goldman M, Le Moine O, Geerts A, Deviere, J. Interleukin-10 controls neutron-philic infiltration, hepatocyte proliferation, and liver fibrosis induced by carbon tetrachloride in mice. Hepatology 1998; 28 (6): 1607–1615.
10. Zheng WD, Zhang LJ, Shi MN, Chen ZX, Chen YX, Huang YH, Wang XZ. Expression of matrix metalloproteinase-2 and tissue inhibitor of metalloproteinase-1 in hepatic stellate cells during rat hepatic fibrosis and its intervention by IL-10. World J Gastroenterol 2005; 11 (12): 1753-1758.
11. Zhang LJ, Yu JP, Li D, Huang YH, Chen ZX, Wang XZ. Effects of cytokines on carbon tetrachloride-induced hepatic fibrogenesis in rats. World J Gastroentrol 2004; 10 (1):77-81.
12. Huang YH, Shi MN, Zheng WD, Zhang LJ, Chen ZX, Wang, XZ. Therapeutic effect of interleukin-10 on CCl4-induced hepatic fibrosis in rats. World J Gastroentrol 2006; 12 (9): 1386-1391.
13. Dong MX, Jia Y, Zhang YB, Li CC, Geng YT, Zhou L, Li XY, Liu JC, Niu YC. Emodin protects rat liver from CCl_4-induced fibrogenesis via inhibition of hepatic stellate cells activation. World J Gastroenterol 2009; 15 (38):4753-4762.
14. Shiga A, Shirota K, Ikeda T, Nomura Y. Morphological and Immunohistochemical Studies on Porcine Serum-Induced Rat Liver Fibrosis. J Vet Med Sci 1997; 59 (3):159-167.
15. Wang JY, Guo JS, Yang CQ. Expression of exogenous rat collagenase in vitro and in a rat model of liver fibrosis. World J Gastroenterol 2002; 8 (5): 901-907.
16. Bataller R, Brenner DA. Hepatic stellate cells as a target for the treatment of liver fibrosis. Semin Liver Dis 2001; 21 (3): 437-451.
17. French SW. Intragastric ethanol infusion model for cellular and molecular studies of alcoholic liver disease. J Biomed Sci 2001; 8 (1):20-27.
18. Dharancy S, Canva V, Gambiez L, Paris JC, Desreumaux P. Hepatic deficiency of IL-10 in chronic hepatitis C. Gastroenterology 2000; 119 (5):1411-1412.
19. Nelson DR, Lauwers GY, Lau JY, Davis GL. Interleukin 10 treatment reduces fibrosis in patients with chronic hepatitis C: a pilot trial of interferon nonresponders. Gastroenterology 2000; 118 (4):655-660.
20. Poonkhum R, Pradidarcheep W, Nilbu-Nga S, Chaunchaiyakul S. Distribution of hepatic

myofibroblasts and type I and III collagen in rat liver cirrhosis induced by thioacetamide. Int. J. Morphol 2011; 29:501-508.

21. Teixeira-Clerc F, Julien B, Grenard P, Tran Van Nhieu J, Deveaux V, Li L, Serriere-Lanneau V, Ledent C, Mallat A, Lotersztajn S.CB1 cannabinoid receptor antagonism: a new strategy for the treatment of liver fibrosis. Nat Med. 2006; 12 (6) :671-676.