

Protective Effect of L- Carnitine Against Formaldehyde-Induced Kidney, Liver and Testicular Damage in Rabbits, A Histopathological Study

Safaa M. George, Heba A. Yassa, Hassan A. Hussein, Abeer M. El Refaiy

ABSTRACT

KEYWORDS

Formaldehyde,
L-Carnitine,
Hepatotoxicity,
Nephrotoxicity.

Formaldehyde (dissolved in market milk) was given every day by gavage to male rabbits for 90 days and the histological changes in the liver, kidney and testicles were examined using paraffin method. This compound has caused hepatotoxicity which included portal inflammation and infiltration by mononuclear inflammatory cells of the hepatocytes. This compound has also caused nephrotoxicity which included tubular dilatation and hydropic degeneration of tubular epithelial cells. The effect on the testicles included atrophy of some seminiferous tubules with shedding of disintegrated epithelial cells into the lumina as well as decrease in the number of the sperms. When given to the formalin exposed rabbits, L-Carnitine caused recovery of the changes in the liver, kidneys and testicles i.e. it has been succeeded in playing a protective role against formalin hepatotoxicity, nephrotoxicity and testicular damage.

Introduction

Formaldehyde (FA) is a member of the aldehyde family and is one of the simplest organic molecules. It is an irritating, colorless gas that has a pungent smell (Yamato et al., 2005). It is rarely found in its original state because it has a short half-life in air and decomposes in light to form a toxic substance. Formaldehyde is highly soluble in water, as well as in most organic solvents, and is a highly reactive molecule that can irritate tissues through direct contact. Furthermore, FA causes cytotoxicity through the formation of strong Deoxyribonucleotide (DNA)-protein cross-

links, as well as cross-links with other molecules, e.g. amino acids (Gurel et al., 2005).

Formaldehyde is easily absorbed through the respiratory and gastrointestinal tracts, is metabolized to formic acid (formate) in the nasal mucosa, liver, and erythrocytes of living organisms, and is then excreted in the urine and feces, or is converted into carbon dioxide and exhaled. There are at least seven enzymes that catalyze the oxidation of FA in animal tissues, namely aldehyde dehydrogenase, xanthine oxidase, catalase, peroxidase, aldehyde oxidase, glyceraldehyde-3-phosphate dehydrogenase, and a specific nicotinamide adenine dinucleotide (NAD)-dependent formaldehyde dehydrogenase (FDH) (Gurel et al., 2005).

Formaldehyde exposure has toxic effects on respiratory system, gastrointestinal tract, hematopoietic tissue, eye, skin, testicles, and nervous system (Ozen et al., 2005).

Safaa M. George, Heba A. Yassa

Forensic and Clinical Toxicology Department, Assiut University

Hassan A. Hussein

Theriogenology Department, Faculty of Veterinary, Assiut University

Abeer M. El Refaiy

Pathology Department, Faculty of Medicine, Assiut University.

Reproductive and developmental effects are believed to be minima USEPA, 1997).

It was reported that formaldehyde causes severe urinary system impairment. However, there are few studies on histochemical and histopathological changes of kidney tissue caused by formaldehyde toxicity (Boj et al., 2003; Zararsiz et al., 2006).

Carnitine is biosynthesized primarily in the liver and kidneys from the amino acids lysine (via trimethyl-lysine) or methionine (Weast, 1981). Its name is derived from the fact that it was first isolated from meat (*carnus*) in 1905. Only the L-isomer of carnitine is biologically active (Robert et al., 2006). During growth, the requirement of carnitine might exceed its natural production (Günther et al., 2002).

The antioxidant effect of carnitine is due to different mechanisms: through its ability to enhance adenosine triphosphate (ATP) production that might improve the overall protein and thus antioxidant enzyme synthesis in the cells, also it can elevate glutathione levels (GSH) as the synthesis of this antioxidant agent is ATP dependent process (Rajasekar et al., 2005). Moreover, carnitine can protect these enzymes from further peroxidative damage by its ability to reduce peroxidation reactions (Sussanna et al., 2002).

The normal rate of L-carnitine biosynthesis in humans ranges from 0.16 to 0.48 mg/kg of body weight/day (Seim et al., 2001). Thus, a 70 kg person would synthesize between 11 and 34 mg of carnitine per day. This rate of synthesis combined with efficient (95%) L-carnitine reassertion by the kidneys is sufficient to prevent deficiency in generally healthy people, including strict vegetarians (Shikeet al., 1999).

The use of carnitine showed some promise in a controlled trial in selected cases of male infertility by improving sperm quality (Lenzi et al., 2003).

L-carnitine supplementation has also shown to have beneficial effects in the treatment of varicocele, a major cause of male infertility (Seo et al., 2010).

The most common form of milk adulteration has been adding water to milk which may be polluted with feces, microorganisms, harmful chemicals and poisonous substances. Formalin is a famous preservative for milk because it has the property of being in liquid form (Cords, 2001).

The present study aimed to determine the concentration of formaldehyde in different milk samples and to investigate the protective effects of L-Carnitine against formaldehyde toxicity on kidneys, liver and testicles of mature male rabbits.

Material and Methods

Chemicals and reagents

Milk after estimation of the level of formaldehyde by HPLC (High performance liquid chromatography) and L-Carnitine (Carnitine, Santa Farma) were used in this study.

Animals:

A total of twenty sexually mature male breed rabbits aged between 12 and 14 weeks were used. Animals were obtained from the Animal House of Faculty of Medicine, Assiut University. They were individually housed in cages in the experimental animal house, under natural climatic condition (temperature range, 15-25°C) with free access to food and water. Animals were fed libitum with commercial rabbit pellets (protein 15%, lipid 2.9% and fiber 12.30%). Food consumption and animals' weight were measured weekly throughout the experimental period.

Experimental design:

Animals in this study received formaldehyde orally through the intake of milk

which was adulterated by this chemical and used as a preservative. Selected organs (liver, kidneys and testicles) were examined histologically to discover the effect of this chemical on the selected organs.

The animals received market milk after estimation of the level of formaldehyde by high performance liquid chromatography (HPLC) which was 0.5 gm/L (concentration was 0.09 mg/Kg) and proved to have formaldehyde above the allowed level which should be less than 0.02 mg/Kg, daily then divided equally and randomly into four treatment groups (n = 5 for each). The control group (group I) received saline, the second group (group II) for 3 months as a subchronic study (Makowski et al., 2009), the dose of this milk was 9 ml given as two separate doses (4.5 ml in the morning and 4.5 ml in the afternoon). The third group (group III) received L-Carnitine which was given orally to rabbits daily for three months, carnitine dose was 250 mg/kg orally according to Stvolinsky and Dobrota (2000), and the fourth group (group IV) received the L-carnitine in combination with the milk containing formaldehyde in the same dose as group II for the same period.

Methods:

High performance liquid chromatography

Materials

Three types of milk in the market were studied and analyzed to detect the amount of formaldehyde in them by HPLC. All solvents were of HPLC grade, Merck (Darmstadt, Germany). Double distilled water was used for preparing solutions.

Chromatographic system and procedure

Instruments: According to Kaminski et al. (1993) and Li et al. (2007), the chromatographic system consisted of a Knauer HPLC system (Knauer, Berlin, Germany), which consisted of K-500 solvent delivery pump, injector valve with a 20 µl loop and K-

2500 UV variable wave length detector. The HPLC system control and data processing were performed by computer integration software (Euro Chrom 2000 Knauer).

Analytical procedure: The HPLC column was Aqua RP-C₁₈ column (250 x 4.6 mm, 5 µm), (phenomenex, USA) and a precolumn (guard column with C₁₈ precolumn inserts) (Waters, USA) was fitted just before the inlet junction of the analytical column.

The HPLC system control and data processing were performed by computer integration software (Thermo Scientific™ Dionex™ Chromeleon™ 7.2 Chromatography Data System (CDS) software).

High performance liquid chromatography method:

The mobile phase consisted of methanol-water (60:40, v/v). The mobile phase was filtered through a 0.45 mm membrane filter (Phenomenex, USA) using vacuum filtration unit (Phenomenex, USA) and was degassed in an ultrasonic cleaner (Cole-Parmer, Chicago, IL, USA) and delivered at flow rate 1 mL/min. The injection sample volume was 20 µL. The detector wave length was set at 355 nm. The chromatography was performed at room temperature. The peak area was used for quantitative calculation of formaldehyde.

Sample derivatization and extraction

One hundred micro liter of milk samples or formaldehyde calibrators was transferred into 1.5 ml Eppendorf tubes and 200 µL DNPH solutions (3.1 g/L) in 3.6 M HCl were added. The mixture was vortexed several times and placed in a water bath set at 60 °C for 15 min. Then 0.8 ml n-hexane was added and the mixture was vortexed again for 15 min. The mixture was centrifuged for 1 min at 2500 g; the n-hexane layer was transferred to new Eppendorf tubes and evaporated under a nitrogen stream. The residue was reconstituted in 100 µL of the mobile phase and a 20 µL

volume of this mixture was injected onto the column. For each sample three replicates were analyzed.

Calibration curve

Formaldehyde stock standard solution was prepared by dissolving formaldehyde in water to obtain a 100 µg/mL sample. Milk standards for the calibration curve were prepared by adding appropriate volumes from the stock standard solution to drug-free milk to obtain final concentrations equivalent to 0.5, 2, 5, 10 and 20 µg/mL and stored at -20 °C until assay. A 100 µL volume of each formaldehyde solution was derivatized and extracted according to the described procedure. Three injections of each standard solution were made. Peak areas with the corresponding formaldehyde concentrations were used to obtain the calibration curve.

Histopathology:

At the end of the experiment the animals were scarified and the testes, liver and kidneys were taken. The excised testes were fixed in Bouin's solution for 24 hours. Liver and kidney were fixed in 10% formalin and processed using standard laboratory procedures for histology. The tissue was embedded in paraffin blocks, sectioned, and stained routinely with hematoxylin and eosin. Stained sections were examined using light microscopy for detection of histopathological changes (Wanga et al., 2010).

Results

Chromatographic results:

Chromatograms of extracted milk samples showed the presence of formaldehyde at different concentrations; sample (1): 10.423 µg/ml, sample (2): 650.32 µg/ml and sample (3): 1.231 µg/ml.

Histopathological results:

Effect of formaldehyde on the testis:

Testis sections of rabbits in the control group were examined and showed normal histological appearance (Figure 2A). In rabbits exposed to formaldehyde, the testicular tissue showed atrophy of some seminiferous tubules and disintegrated epithelial cells that are shed into the lumina. (Figures 2 C, 2D). There is also decrease in the number of mature sperms compared to the control. However, the histopathological changes observed after the administration of formaldehyde, had disappeared in the rabbits treated with formaldehyde and L-Carnitine (Figure 2B).

Effect of formaldehyde on the liver:

Liver sections of rabbits in the control group were examined and showed normal histological appearance (Figure 3A). In rabbits exposed to formaldehyde, the tissue showed portal inflammation and infiltration by mononuclear inflammatory cells (Figures 3C & 3D). However the histopathological changes observed after the administration of formaldehyde, had disappeared in the rabbits treated with formaldehyde and L-Carnitine (Figure 3B).

Effect of formaldehyde on the kidney:

Kidney sections of rabbits in the control group were examined, and showed normal histological appearance (Figure 4A). In rabbits exposed to formaldehyde, the tissue showed tubular dilatation and hydropic degeneration of tubular epithelial cells (Figures 4C & 4D). However the histopathological changes observed after the administration of formaldehyde, had disappeared in the rabbits treated with formaldehyde and L-Carnitine (Figure 4B).

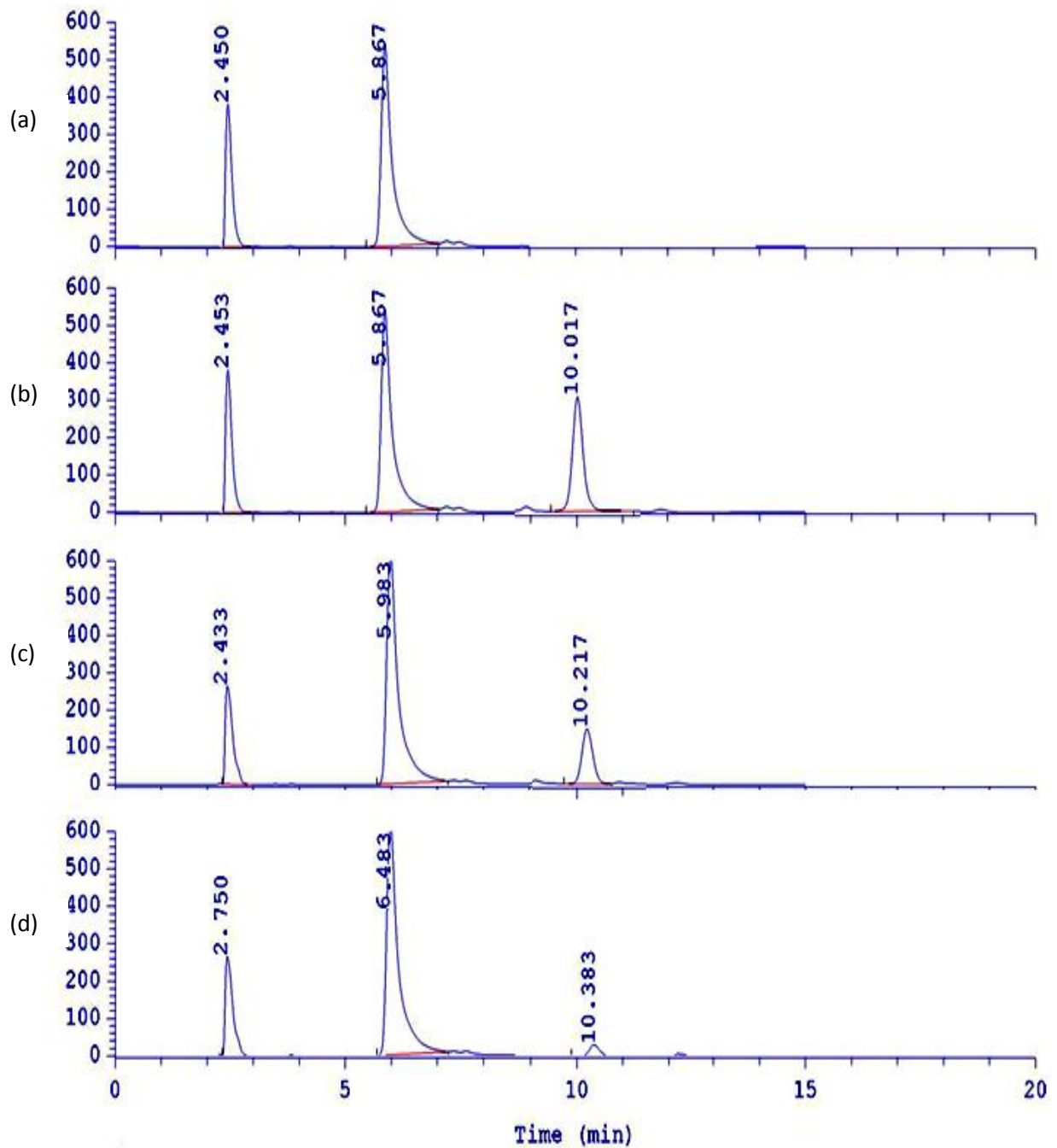


Fig. (1): Typical Chromatographs of different milk samples showing the presence of formaldehyde at different concentrations; (a): blank milk sample, (b): 1.231 µg/ml, (c): 650.32 µg/ml, (d): 10.423 µg/ml.

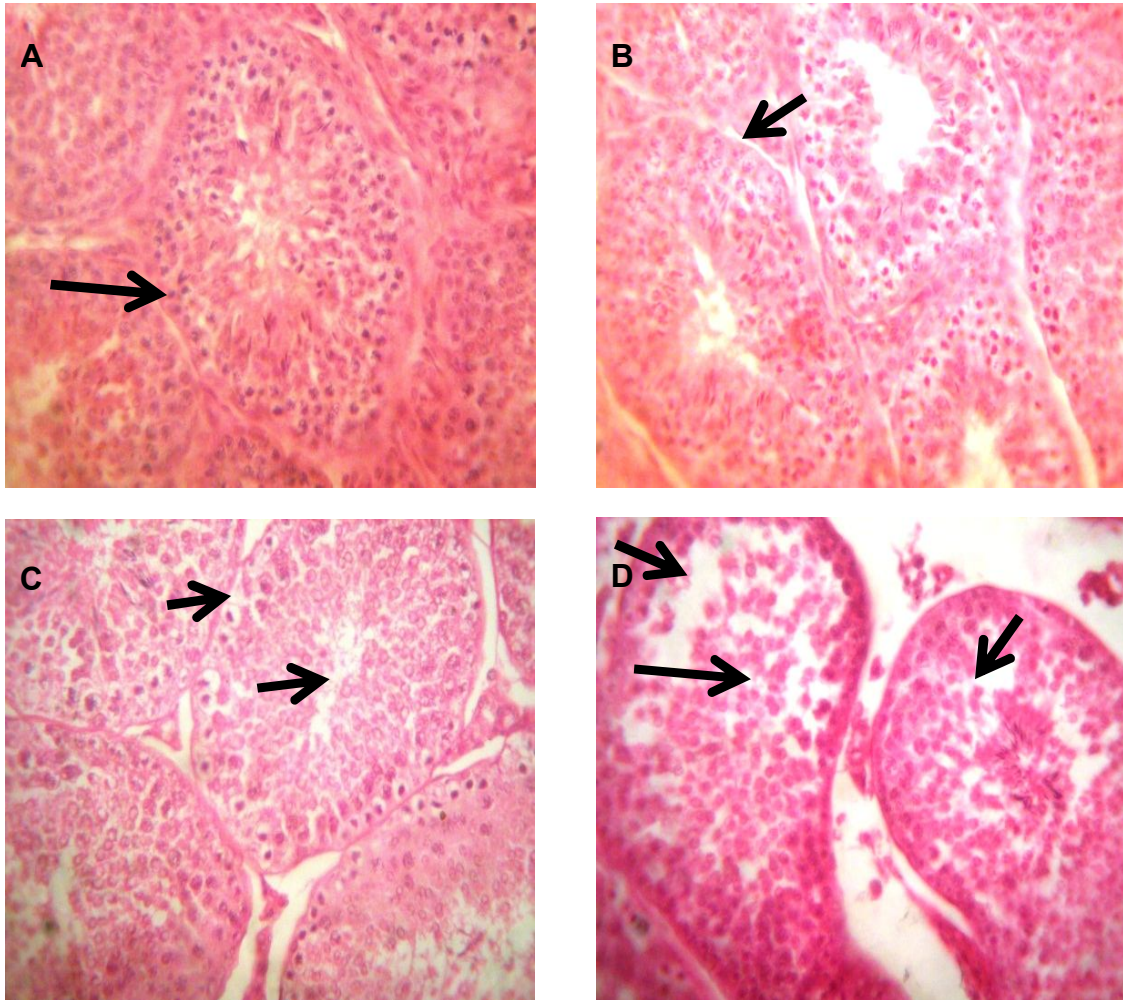


Fig. (2): Seminiferous tubules in control group (1A) and Carnitine-treated group (1B) showing no pathology. Formaldehyde treated group (1C&1D) showed atrophy of some seminiferous tubules and epithelial cells disintegrated and shed into the lumina. There is also decrease in the number of mature sperms compared to the control (H&Ex400).

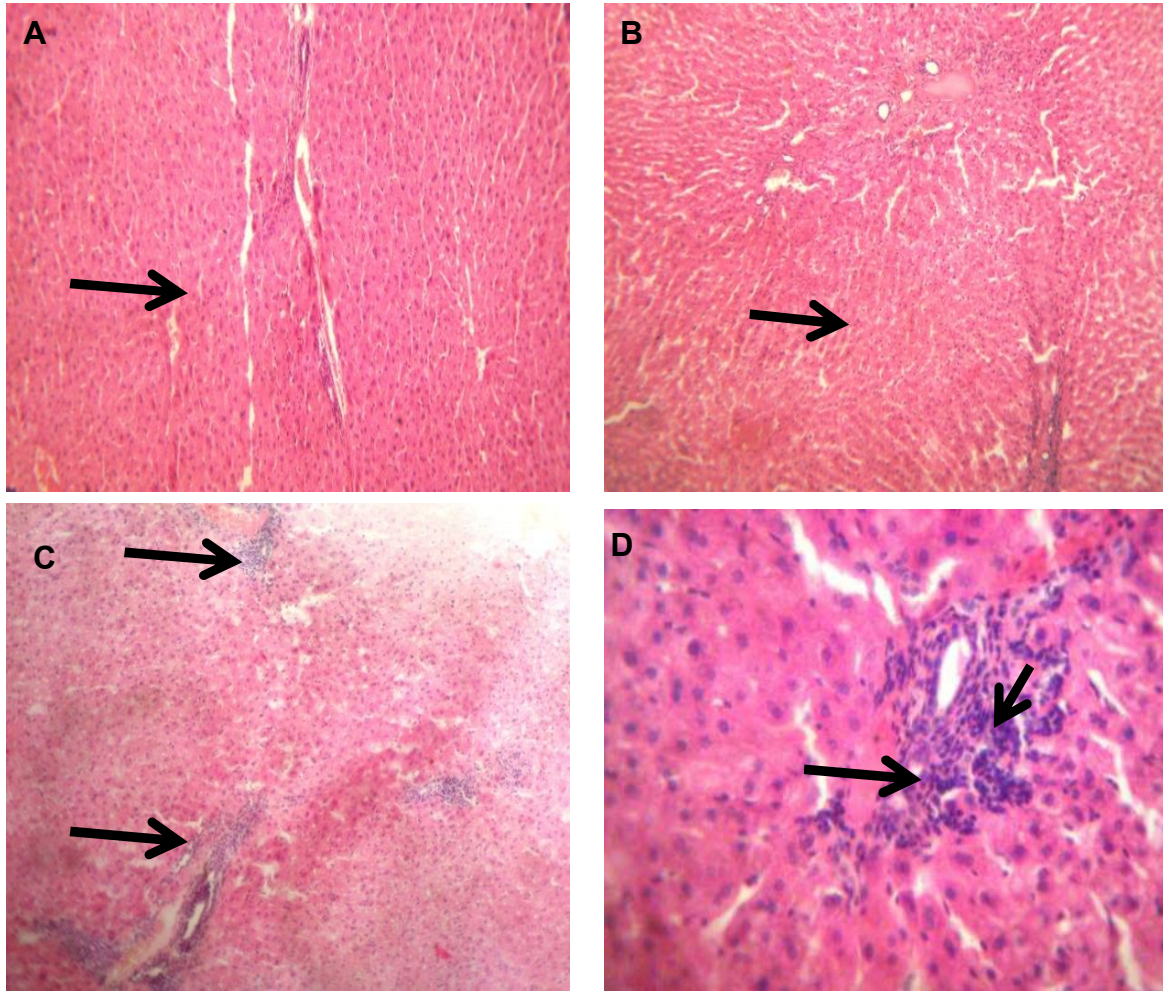


Fig. (3): Liver tissue in control group (2A) and carnitine treated group (2B) showing no pathologic changes. Formaldehyde treated group (2C & 2D) showed portal inflammation and infiltration by mononuclear inflammatory cells (H&Ex100, DX400).

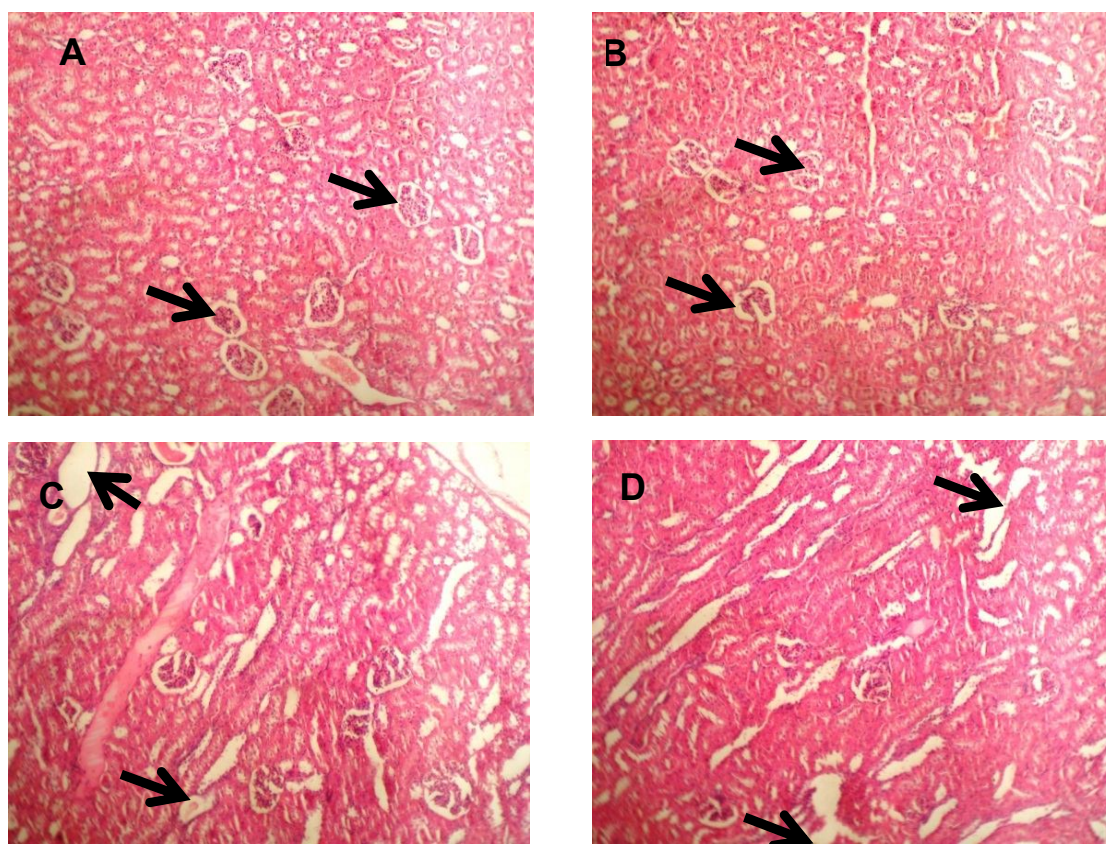


Fig. (4): Kidney tissue from control group (3A) and carnitine group (3B) showed no pathologic changes. Sections from formaldehyde group (3C & 3D) showed tubular dilatation and hydropic degeneration of tubular epithelial cells (H&Ex100).

Discussion

The present study revealed the pathological effects of formaldehyde added to milk as a preservative on liver, kidney and testicles and the possible protective role of L-carnitine to these effects.

Sufficient study by different workers has already been done on different animal (Cynomolgus monkeys, rats, and hamsters etc.) about the harmful effect of this culprit chemical through inhalation and dermal exposure and showed irritation of the eyes, nose, and throat, headaches, skin sensitization, dermatitis, hoarseness, congestion, and nasal squamous cell metaplasia (Rusch et al., 1983).

As regards the effect on testicles, Ozen et al. (2005) used FA in a subchronic study for

91 days at the doses of 5–10 ppm and determined significant reductions in the seminiferous tubular diameters.

Similarly, Gosalipour et al. (2007) used inhaled form of FA for 18 days in their study and suggested that FA causes atrophy and degeneration in the seminiferous tubule, which lead to reductions in sperm counts. Likewise, significant reduction was reported in the sperm motility as a result of damage to the Leydig cells. Henkel et al. (2005) demonstrated a direct correlation between sperm motility and testosterone expressed by Leydig cells. In the study by Tang et al. (2003) on rats, increased abnormal sperm counts were reported. In the same vein, Odeigah (1997) determined anomalies of the sperm head in rats that had been given intra-peritoneal FA. The findings

of the sperm analyses in another study are compatible with the findings of earlier studies (George et al., 2011).

In the present study kidneys of treated animals showed degenerated and shrinkage tissue with ruptured and deformed glomerulus. Formaldehyde disturbs the oxidant-antioxidant balance in various tissues and cause oxidative stress in parallel with tissue damage.

There are also several clinical studies reporting nephrotoxicity caused by different applications of formaldehyde. Roldan et al. (2003) evaluated patients with alcohol dependency and determined that formaldehyde and methanol metabolizing formic acid caused tubular necrosis development in the renal tissue, resulting in renal failure. Shimizu et al. (2003) reported a case of suicide attempt that involved formaldehyde (150 mL) consumption, resulting in acute renal failure following hypotension development.

Merimsky and Jossiphov (1980) and Sarnak et al. (1999) observed edematous obstruction and subsequent acute tubular necrosis causing acute renal failure in their patients with hemorrhagic cystitis treated with the use of intravesical formalin (37%). They reported that edematous obstruction could be due to intravesical formalin administration. In this study there was dilatation in the distal tubules and hydropic degeneration of tubular epithelial cells. These pathological changes together with glomerular damage observed could result in renal failure at later stages on more severe formaldehyde exposure. Similarly, Teng et al. (2001), in their experimental study on isolated rat hepatocytes showed that formaldehyde at low concentrations leads to oxidative stress. L-Carnatine is a potent antioxidant agent and exerts a protective effect against oxidative stress (Kanter et al., 2010). In this study, L-Carnatine was found to prevent the liver damage against HCHO intoxication. Considering the properties of L-carnatine and

the results of the present study, it is plausible that both its radical-scavenging and antioxidant actions are involved in preventing tissue damage.

Conclusion

Current study suggested that the use of formaldehyde is injurious to health and causes serious effect on liver, kidney and testicles of rabbit model, if they are consumed regularly. And in turn, L-carnatine showed a protective role against this effect in rat. Therefore, strict law needs to be formulated to prevent such unlawful act of adding formalin to the food stuffs.

References

- Boj, J.R.; Marco, I.; Cortes, O.; et al. (2003):** "The acute nephrotoxicity of systemically administered formaldehyde in rats". *Eur. J. Pediatr. Dent.*; 4: 16–20.
- Collins, J.J.; Lineker, G.A. (2004):** "A review and meta-analysis of formaldehyde exposure and leukemia". *Regul. Toxicol. Pharmacol.*; 40(2):81-91.
- Cords, B.R. (2001):** "Cleaning and sanitizing in milk production and processing." In: Marth, E.H.; Steele, J.L. *Applied Dairy Microbiology*, 2nded. New York: Marcel Dekker. P.P. 547-587.
- George, S.A.; Yassa, H.A.; Hussein, H.A.(2011):** "The protective effect of L-Carnatine against subchronic toxicity of formaldehyde on rabbit's testicular functions". *Mansoura J Forensic Med. Clin.Toxicol.*;21(2):27-42.
- Golalipour, M.; Mahjoubi, F.; Sanati, M.H. (2007):**"Gene dosage is not responsible for the up regulation of MRP1 gene expression in adult leukemia patients".

- Archives of Medical Research, 38(3): 297-304.
- Günther, R.; Walter, D.; Armin, O.G.; et al. (2002):** Formaldehyde. In: Ullmann's Encyclopedia of Industrial Chemistry, Wiley-VCH, Weinheim. Doi:10.1002/14356007.a11_619.
- Gurel, A.; Coskun, O.; Armutcu, F.; et al. (2005):** "Vitamin E against oxidative damage caused by formaldehyde in frontal cortex and hippocampus: Biochemical and histological studies". J. Chem. Neuroanat.; 29: 173–178.
- Henkel, R.; Kierspel, E.; Stalf, T.; et al. (2005):** "Effect of reactive oxygen species produced by spermatozoa and leukocytes on sperm functions in non-leukocyto-spermic patients". Fertil. Steril.; 83(3):635-642.
- Jianrong, L.I.; Junli, Z.H.; Lifang, Y.E.; et al. (2007):** "Determination of formaldehyde in squid by high performance liquid chromatography". Clin. Nutr.; 16 (Supple 1):127-130.
- Kaminski, J.; Atwal, A.; Mahadevan, S. (1993):** "Determination of formaldehyde in fresh and retail milk by liquid column chromatography". J. of the Association of Official Analytical Chemists International, 76(5):1010–1013.
- Kanter, M.; Topcu-Tarladacalisir, Y.; Parlar, S. (2010):** "Antiapoptotic effect of L-carnitine on testicular irradiation". J. Mol. Histol.; 41(2-3):121-128.
- Kim, K.; Kim, K.H.; Storey, M.K.; et al. (1999):** "Isolation and characterization of the *Saccharomyces cerevisiae* EK11 gene encoding ethanolamine kinase". J. Biol. Chem.; 274(21):14857-14866.
- Lenzi, A.; Lombardo, F.; Sgro, P.; et al. (2003):** "Use of carnitine therapy in selected cases of male factor infertility: a double-blind crossover trial. Fertility and Sterility; 79(2):292-300.
- Li, J.; Zhu, J.; Ye, L. (2007):** "Determination of formaldehyde in squid by high performance liquid chromatography". Asia Pac. J. Clin. Nutr.; 16 (1):127-130.
- Merimsky, E.; Jossiphov, J. (1980):** "Toxic effects on the kidney by endovesical instillations of formol. hematogenic diffusion or reflux". J. Urol.; 86: 527–529.
- Occupational Safety and Health Administration (OSHA) (2002):** "Formaldehyde fact sheet". US Department of Labor, J. Urol.; 86: 527–529
- Odeigah, P.G. (1997):** "Sperm head abnormalities and dominant lethal effects of formaldehyde in albino rats". Mutat. Res., 17;389(2-3):141-148.
- Ozen, O.A.; Akpolat, N.; Songur, A.; et al. (2005):** "Effect of formaldehyde inhalation on Hsp70 in seminiferous tubules of rat testes: an immunohistochemical study". Toxicology and Industrial Health; 21:249–254.
- Rajasekar, P.; Kaviarasan, S.; Carani, V. (2005):** "L-carnitine administration prevents oxidative stress in high fructose- fed insulin resistant rats". Diabetologia; 34(1):21-28.
- Robert, J. C.; Catharine, R.; Shils, M.E.; et al. (2006):** Modern nutrition in health and disease. 10th ed. by Philadelphia: Lippincott, Williams & Wilkins. P.P. 537-544.
- Roldan, J.; Frauca, C.; Duenas, A. (2003):** "Alcohol intoxication". An Sist. Sanit. Navar.; 26: 129–139.
- Rusch G.; McClary J.J.; Rinehart, W.E. et al. (1983):** "26-week inhalation toxicity study with formaldehyde in

- monkey, rat and hamster". *Toxicol. Appl. Pharmacol.*; 68:329-343.
- Saraj, A.; AL-Hubaity, A. (2003):** "Histological and histopathological changes of lung of rats during different periods of formaldehyde exposure". *Iraqi J. Vet. Sci.*; 17(2):111-121.
- Sarnak, M.J.; Long, J.; King, A.J. (1999):** "Intravesicular formaldehyde instillation and renal complications". *Clin. Nephrol.*; 51: 122–125.
- Seim, H.; Eichler, K.; Kleber, H. (2001):** L-Carnitine and its precursor, gamma-butyrobetaine. In: Kramer K, Hoppe P, Packer L, eds. *Nutraceuticals in Health and Disease Prevention*. New York: Marcel Dekker, Inc. P.P. 217-256.
- Seo, J.T.; Kim, K.T.; Moon, M.H.; et al. (2010):** "The significance of microsurgical varicocelectomy in the treatment of subclinical varicocele". *Fertil. Steril.* 93(6): 1907–1910.
- Shike, M.; Shils, M.E.; Olson, J.A. ;et al. (1999):** *Modern nutrition in health and disease*. 9th ed. Philadelphia: Lippincott, Williams & Wilkins. P.P. 505-512.
- Shimizu, K.; Sugita, M.; Yokote R.; et al. (2003):** "Intestinal edema caused by ingested formalin". *Chudoku. Kenkyu.*; 16: 447–451.
- Solomons, K.; Cochrane J.W. (1984):** "Formaldehyde toxicity. Part II. Review of acute and chronic effects on health". *S. Afr. Med. J.*; 66: 103–106.
- Susanna, I.; Maria, P.; Lilla L.; et al. (2002):** "Acetyl-L-carnitine supplementation differently influences nutrient partitioning, serum leptin concentration and skeletal muscle mitochondrial respiration in young and old rats". *J. Nutr.*;132:636-642.
- Tang, M.; Xie, Y.; Yi, Y.; et al. (2003):** "Effects of formaldehyde on germ cells of male mice". *Wei. Sheng Yan. Jiu.*; 32: 544-548.
- Teng, S.; Beard, K.; Pourahmad, J.E.; et al. (2001):** "The formaldehyde metabolic detoxification enzyme systems and molecular cytotoxic mechanism in isolated rat hepatocytes". *Chemical Biological Interactions*;130:285 - 296.
- Thrasher, J.D.; Kilburn, K.H. (2001):** "Embryo toxicity and teratogenicity of formaldehyde". *Arch. Environ. Health*; 56(4):300-311.
- U.S. Environmental Protection Agency (USEPA) (1997):** "Formaldehyde EPA health effects notebook for hazardous air pollutants". Office of Air Quality Planning and Standard; No, 50-00-0.
- Wang, H.; Huang, P.; Lie, T.; et al. (2010):** "Reproductive toxicity of acrylamide-treated male rats". *Reprod. Toxicol.*; 29(2):225-230.
- Weast, R. C. (1981):** *CRC Handbook of Chemistry and Physics*. 62nd ed. Boca Raton, FL: CRC Press, P. C–301, E-61.
- Yamato, H.; Nakashima T.; Kikuta A.; et al. (2005):** "A novel local ventilation system to reduce the levels of formaldehyde exposure during a gross anatomy dissection course and its evaluation using real-time monitoring". *J. Occup. Health*; 47: 450–453.
- Zararsiz, I.; Sönmez, M.F.; Yilmaz, H.R.; et al. (2006):** "Effects of omega-3 essential fatty acids against formaldehyde induced nephropathy in rats". *Toxicology and Industrial Health*; 25: 223–229.

**الدور الوقائي للكارنتين ضد الفورمالدهيد المتسبب في تلف الكبد والكلية والخصية في الأرانب :
دراسة هستوباثولوجية**

صفاء ماهر جورج* ، هبة عطية يسى*، حسن عبد الصبور حسين، عيبر الرفاعي*****

* قسم الطب الشرعي والسموم الإكلينيكية - كلية الطب جامعة أسيوط

** قسم التناسليات كلية الطب البيطري

*** قسم الباثولوجي - كلية الطب جامعة أسيوط

يوجد الفورمالدهيد في منتجات عديدة حولنا. تهدف هذه الدراسة إلي فحص تأثيرات التعرض للفورمالدهيد علي وظائف الخصية في الأرانب والدور الوقائي كمضاد لهذه التأثيرات. أجريت هذه الدراسة لمدة ثلاثة شهور علي ٢٠ ذكراً من الأرانب البالغة و قد قسمت إلي أربع مجموعات (خمسة أرانب لكل مجموعة). المجموعة الأولى (المجموعة الضابطة)، المجموعة الثانية أعطيت الفورمالدهيد في اللبن بعد عمل تحليلاً لكروماتوجرافيا الطبيفية للعديد من الألبان في السوق المحلية، المجموعة الثالثة أعطيت الفورمالدهيد بالإضافة إلى الكارنتينين، و المجموعة الرابعة أعطيت الكارنتينين فقط كل يوم للأرانب لمدة ٩٠ يوماً. و قد تم فحص التغيرات السيتولوجية في الكبد والكلية والخصية في كل المجموعات.

واتضح أن الفورمالدهيد قد تسبب في تسمم كبدي في صورة التهاب الوريد البابي وغزو الخلايا الالتهابية لخلايا الكبد وقد تسبب أيضاً في تسمم كلوي اتضح في تمدد أنابيب الكلي واضمحلال في الخلايا الطلائية للأنابيب، أما تأثيره علي الخصية فكان في صورة ضمور لبعض أنابيب الخصية وظهور بعض الخلايا في تجويف الخصية مع قلة عدد الحيوانات المنوية.

وعندما أعطيت الحيوانات كارنتين تسبب في استرجاع التغيرات التي حدثت في الكبد والكلية والخصية. و قد خلصت هذه الدراسة إلي أنه من الممكن استخدام الكارنتينين للوقاية من التأثيرات الضارة للفورمالدهيد ضد تسمم الكبد و الكلية والخصية.