



Manuscript ID ZUMJ-1906-1280 (R2)  
DOI 10.21608/zumj.2019.14025.1280

**ORIGINAL ARTICLE**

**GUIDED GROWTH FOR GENU VALGUM DEFORMITY IN CHILDREN**

**Khaled Edris Abdel Rahman<sup>1</sup>, Riad Mansour Megahed<sup>2</sup>, Mohamed Abdel Fatah M. Sebai<sup>3</sup>, Mahmoud Omar Mahmoud Abdullah<sup>4</sup>**

*1 Faculty of Medicine, Zagazig University, Department of Orthopedic Surgery, Sharkia Egypt*

*2 Faculty of Medicine, Zagazig University, Department of Orthopedic Surgery, Sharkia Egypt*

*3 Faculty of Medicine, Zagazig University, Department of Orthopedic Surgery, Sharkia Egypt*

*4 Faculty of Medicine, Zagazig University, Department of Orthopedic Surgery, Sharkia Egypt*



**Corresponding author**

**Name : Mahmoud**

**Omar Mahmoud**

**Abdullah**

**E.mail :**

**dr.mood10@gmail.com**

Submit Date 2019-07-21

Revise Date 2019-08-21

Accept Date 2019-09-07

**ABSTRACT**

**Introduction:** Genu valgum that develops during the childhood years may contribute to anterior knee pain, patellofemoral instability, circumduction gait, and difficulty running. Lateralization of the mechanical axis places pathologic stresses on the anterior and lateral compartments of the knee, posing the risk of accelerated degenerative changes

**Objective:** To evaluate results of correction of genu valgum deformity in children by guided growth.

**Methods:** The prospective study was carried out in Orthopedic Surgery Department, Beni Suef General Hospital and Orthopedic Surgery Department at Zagazig University Hospital on 12 children with genu valgum attending for correction by guided growth using eight plate.

**Results:** In our study we evaluate 12 patients 3-14years old mean age  $7\pm 2.6$  years old, 41.7%, 58.3% female, 58.3% unilateral, 44.7% bilateral. These 12 patients prospectively followed up for 12-32 months with average 18.3 months.

**Conclusion:** The procedure is simple and effective for treating genu valgum for many children. The simplicity and cost-effectiveness of this minimally invasive technique make it an attractive alternative to more complex methods of limb deformity correction.

**Key words;** Guided Growth, Genu Valgum Deformity, proximal femur, Computed tomography, Knee Ankle Foot Orthosis

**INTRODUCTION**

**G**enu valgum that develops during the childhood years may contribute to anterior knee pain, patellofemoral instability, circumduction gait, and difficulty running. Lateralization of the mechanical axis places pathologic stresses on the anterior and lateral compartments of the knee, posing the risk of accelerated degenerative changes<sup>[1]</sup>.

The child with genu valgum typically presents with circumduction gait, anterior knee pain, and may have demonstrable patellofemoral instability. Several of the parents of patients were particularly adamant regarding early intervention for genu valgum. Although bracing may give some

symptomatic relief, it is ineffectual at changing knee alignment or stabilizing the patellofemoral joint<sup>[1]</sup>.

Treatment recommendations cover the spectrum ranging from restriction of activities and antiinflammatory medication to physical therapy and orthotics to epiphysiodesis or osteotomy. In the vast majority of cases, parents can expect that a child's genu valgum will resolve by age 8. For older children and adults with genu valgum, a course of physical therapy and exercises can help realign their knees. It can also strengthen surrounding muscles and avoid stress damage to other joints. If these efforts aren't successful, surgery may be performed to realign knees. In

time, untreated knee malalignment can cause pain and problems in functioning. Adults with genu valgum are at greater risk of developing osteoarthritis<sup>[2]</sup>.

## PATIENTS AND METHODS

### Site of the study:

The prospective study was carried out in Orthopedic Surgery Department, Beni Suef General Hospital and Orthopedic Surgery Department at Zagazig University Hospital on 12 children with genu valgum attending for guided growth using a flexible two-hole titanium plate. Written informed consent was obtained from all participants and the study was approved by the research ethical committee of faculty of medicine, Zagazig university. The work has been carried out in accordance with the code of Ethics of the world Medical Association (Declaration of Helsinki) for studies involving humans. In our study we evaluate 12 patients 3-14 years old mean age  $7 \pm 2.6$  years old, 41.7%, 58.3% female, 58.3% unilateral, 44.7% bilateral. These 12 patients prospectively followed up for 12-32 months with average 18.3 months.

### I. Inclusion Criteria:

- Patients > 18 months < 18 years.
- patients ranging from 12 kg to 200 kg.
- Pathological genu valgum.

### II. Exclusion Criteria:

- Patients < 18 months > 18 years.
- Patients < 12 kg > 200 kg.
- Physiological genu valgum.

### III. Method of treatment:

#### Operative technique:

A decision to offer surgical correction was based on absence of spontaneous improvement after observation for at least 12 months. A standing scanogram is done which measure the mechanical axis and femorotibial angles (figure 1,2).

The mechanical axis of the limb is abnormal if it crossed the knee joint outside the inner two quadrants of a six quadrant zone. In order to determine if there was sufficient growth remaining for correction by guided growth, a bone age was obtained in all patients. Those who were within six months of skeletal maturity, were considered unsuitable for the surgery.

The level of the physis on the relevant side and segment (distal femur or proximal tibia) was identified using fluoroscopy. Estimate the centre of physis by palpating the anterior and posterior margins of the femur or tibia and placing a 2 cm skin incision over this position. Devide the fascia lata longitudinally. Exposure the periosteal surface by blunt dissection, taking care not to injure this layer and the perichondrial ring.

The plate was placed over the physis and secured with a hypodermic needle through a small central hole in the plate. Confirm positioning by fluoroscopy. Guide wires were then driven through the centres of the two main holes of the plate, to keep the direction of these wires parallel to the physis. A cannulated drill and a self-tapping 4.5 mm titanium screw was passed over the guide wire. These wires were extracted before each screw was finally secured onto the plate and its position checked. A compression bandage was applied after wound closure.

Patients discharged after one day having safely mobilized partially weight-bearing. The compression bandage was reduced after three or four days and knee motion encouraged. Full weight-bearing was usually achieved after two weeks.

Clinical and radiological follow up is recommended. A standing scanogram was obtained to confirm correction. The desired correction was restoration of the mechanical axis to within the inner two zones of a six-zone division of an anteroposterior radiograph of the knee; when this occurs, Plate removal was undertaken as day surgery and the patients followed up for any complications as rebound deformity, and limb discrepancy till skeletal maturity.

### STATISTICAL ANALYSIS

Data were coded and entered using statistical package SPSS (statistical package for social sciences). Data was summarized using mean, standard deviation, median, minimum and maximum in quantitative data using frequency (count) and relative frequency (percentage) for categorical data. Comparisons between quantitative variables were done using the non-parametric Kruskal-Wallis and Mann Whitney tests. Correlations between quantitative variables

were done using Spearman coefficient P-values less than 0.05 were considered as statistically significant.

### RESULTS

The mean age of patients which was 7 years (3 to 14). There were 5 males and 7 females. There were 5 bilateral and 7 unilateral deformities. Mean deformity of genu valgum was  $10.9 \pm 6.1$  ranging from 3 to 25.(Table 1)

The rate of correction of femur  $0.84 \pm 0.28$  (0.4-1.5) and tibia  $0.48 \pm 0.28$  (0.1-1) with overall rate of correction  $1.32 \pm 0.5$  (0.7-2.5) (Table 2)

Two patients were complicated, there was plate and screw migration in the first and infection in the second. In the former, the surgery was re-do. In the latter, the plate was removed and a course of antibiotics for two

weeks was given to cure infection then anew plate was inserted without further complications.(Table 6)

One case had rebound deformity in a eight-year-old patient who had a bilateral genu valgus deformity. Plates were inserted over the medial distal femoral and proximal tibial physes

The 12 patients in the study had a mean follow-up of 18.3 months (12 to 32) after removal of the plate. The rate of correction was influenced by the physis treated and the age of the child. There was a mean rate of correction of  $0.7^\circ$  per month in the femur and of  $0.5^\circ$  per month in the tibia.(Table 5)

Case report: female patient 6 years old.bilateral genu valgum corrected by eight plate (figure 3,4)

**Table (1): Demographic data and some clinical data**

<b>Age (years)</b>	
Mean $\pm$ SD	7 $\pm$ 2.6
Range	3-14
<b>Puberty</b>	
Prepubertal (< 10)	9 (75%)
Postpubertal (> 10)	3 (25%)
<b>Gender</b>	
Male	5 (41.7%)
Female	7 (58.3%)
<b>Side of deformity</b>	
Unilateral	7 (58.3%)
Bilateral	5 (44.7%)
<b>Genu valgum</b>	
Mean $\pm$ SD	10.9 $\pm$ 6.1
Range	3-25

**Table (2): The rate of correction**

	Mean $\pm$ SD (range)
<b>Femur</b>	0.84 $\pm$ 0.28 (0.4-1.5)
<b>Tibia</b>	0.48 $\pm$ 0.28 (0.1-1)
<b>Overall</b>	1.32 $\pm$ 0.5 (0.7-2.5)

**Table (3): Relation between age and rate of correction**

Age (years)	Rate Mean $\pm$ SD (range)	p
< 10	1.3 $\pm$ 0.25 (1-1.5)	0.04 (S)
> 10	1 $\pm$ 0.16 (0.7-1.1)	

**Table (4): Correlation between age and correction**

	r	P
Age and rate of correction	-0.72	< 0.001 (HS)

**Table (5): Mean time for correction**

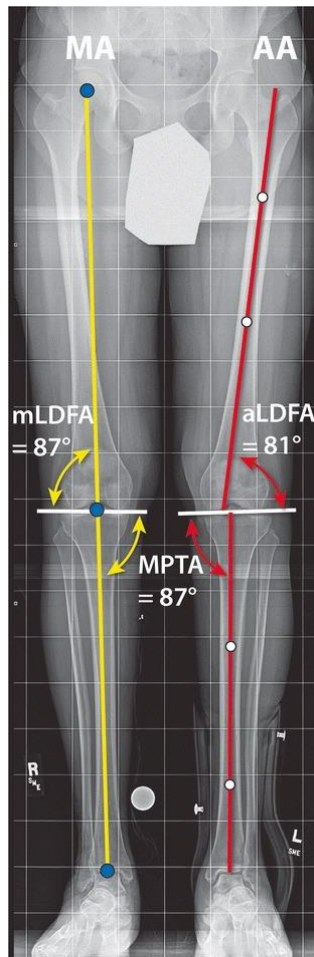
	n = 12
Mean time of follow up (per months)	
Mean $\pm$ SD	18.3 $\pm$ 7.1
Range	12-32
Mean rate of correction in the femur	0.7°/month
Mean rate of correction in tibia	0.5°/month

**Table (6): Complications**

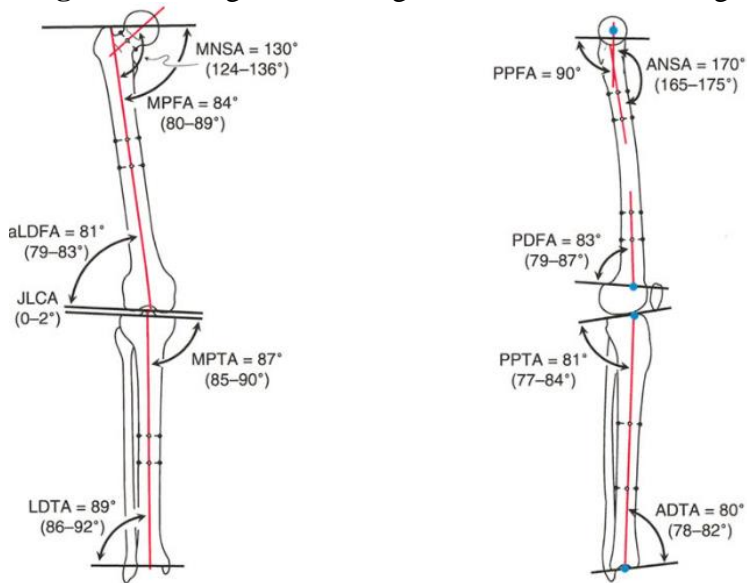
	No	%
Evidence of plate and screw migration	1	8.3
Infection	1	8.3
Rebound deformity	1	8.3

**Table (7) outcome:**

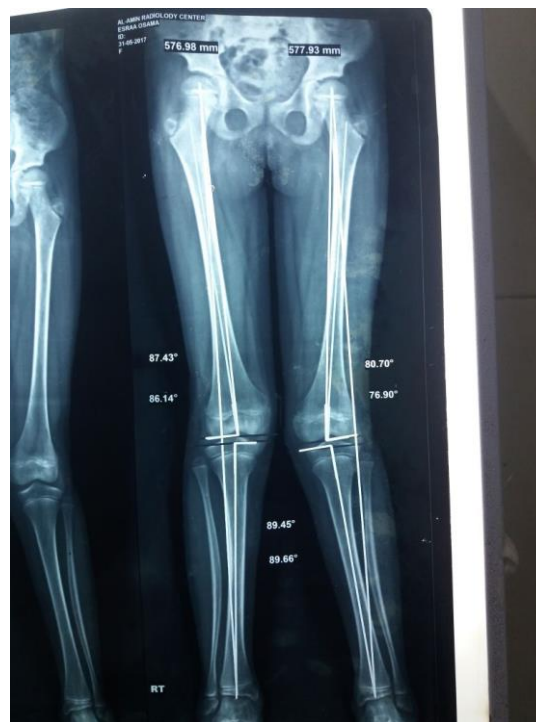	N	%
Excellent	5	41.7
Good	3	25
Fair	1	8.3
Poor	3	25



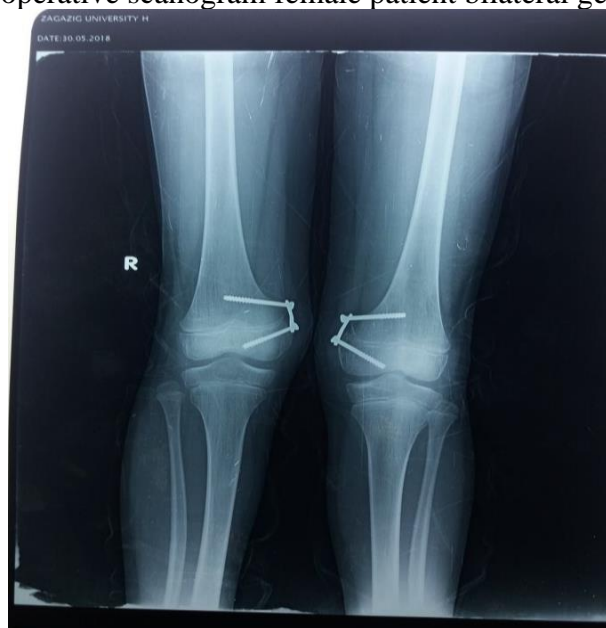**Figure 1:** scanogram showing mechanical axis and angles



**Figure 2:** Joint orientation angles



**Figure 3:** case report pre operative scanogram female patient bilateral genu valgum



**Figure 4:** one year post operative x-ray shows correction of deformity by eight plate

### DISCUSSION

Genu valgum is a common childhood deformity. It improves spontaneously before the age of eight years. Occasionally, deformities extend beyond to be pathological. These may be idiopathic in origin, or related to growth plate or bone forming disorders. Pain and limitation of activity may occur<sup>[3]</sup>.

These deformities may be treated by osteotomy and internal fixation or by gradual correction through external fixation or by hemiepiphyseal arrest using techniques such

as stapling, percutaneous drill hemiepiphyseal arrest or transphyseal screws. However, the risk of creating a permanent growth arrest means that these techniques have to be timed to take account of the size of deformity and remaining growth available.<sup>[4]</sup>

This study describes the guided growth to correct genu valgum deformity in children. To accomplish longitudinal growth retardation, a single 8-plate is applied to either side of a given physis; these plates are made of



titanium, 2 dimensions 12 and 16 mm with solid or cannulated screws.

The average age of the children in this study was  $7 \pm 2.6$  years with a range of 3 to 14 years. There were 5 males and 7 females. There were 5 bilateral and 7 unilateral deformities. Mean deformity of genu valgum was  $10.9 \pm 6.1$  ranging from 3 to 25. This is similar to the study by Stevens [5].

In our study, analysis of the overall rate of correction against the child's age showed a high significant positive correlation between age and rate of correction. When the sample was divided into two groups to reflect an approximate age of onset of puberty, the mean rate of correction for children under the age of 10 years was 1.3, compared with 1 for the older children ( $p = 0.04$ ). The 12 patients in the study had a mean follow-up of 18.3 months (12 to 32) after removal of plate.

Bony deformity may also be corrected by manipulating the growth behaviour of an open physis **Steel et al.** [6]. In experimental and clinical work, **Hass** [7] demonstrated the growth of the physis following surgical instrumentation. He noted growth arrest by placing a wire loop around a canine distal femoral physis and noted that growth resumed when the wire broke.

**Blount, Clarke** [8], techniques have been introduced to guided growth. Hemiepiphysiodesis is well established in children, in particular the use of staples and transphyseal screws. Both methods exert compression on the physis and, when placed wrongly, can retard growth on the side of application and thereby produce asymmetrical growth.

**Aykut et al.** [9] demonstrated clinically that transgression of the periosteum during staple insertion or removal poses a risk of producing a physeal bar. In contrast, Khoury demonstrated that guided growth using transphyseal screws can be a reversible method [10].

The plate concept developed by **Stevens** [5] produces the effect of a focal hinge by tension band. While some compression is applied across the physis, it is not constant owing to the propensity of the screws to diverge as correction proceeds. Once the screws reach their maximum divergence, there is also the

ability within the plate to bend. Both of these features decrease the risk of a permanent physeal tether through prolonged compression across the physis. Also, one plate per physis is needed to produce correction, whereas three staples per physis are needed for the same effect. This clinical study also shows the nature of growth inhibition by the device.

The speed of correction in guided growth is determined by the nature of the growth modulation (staple, transphyseal screw or flexible plate), the age of the child and the physis treated. **Burghardt** [11] described the rate of correction using the plate method. In this case, the rate of improvement in the mechanical axis derived from the tibial part was slower than from the femoral part.

On the contrary, we can report rates of correction from each physis in terms of angular improvement per month, but also show the influence of age on the process. This enables the surgeon to estimate the overall treatment time and provide parents with information. Clinical appreciation of the effect of gradual correction usually occurs towards the end of the treatment period.

Implant migration was noted in one patient, and this has also been documented with the use of staples due to the distal screw was placed very close to the physis and would have been avoided through selection of a longer plate to bridge the growth plate. There were no instances of screw or implant back-out as can occur with staples **Fraser et al.** [12].

In our study, The rate of correction was influenced by the physis treated and the age of the child. There was a mean rate of correction of  $0.7^\circ$  per month in the femur and of  $0.5^\circ$  per month in the tibia. We found the fastest rates of correction were achieved when the distal femoral and proximal tibial physes were treated concurrently, or in children under the age of ten years. This technique is a major advantage and reduces the need for osteotomy for. The only caveat is that the physis itself must be normal and respond to growth guidance through the flexible plate.

Two patients are complicated by plate migration and infection. One patient five years old with unilateral genu valgum had rebound deformity.

**Jochymek et al.**<sup>[14]</sup> reviewed a retrospective study of Nineteen patients (13 male, 6 female) with a diagnosis of genu valgum (or genua valga) underwent temporary medial hemiepiphysodesis; 3 patients (15.8%) only for unilateral genu valgum, two patients (10.5%) with the severe findings of the deformity of genua valga underwent medial hemiepiphysodesis bilaterally at the area of distal femur as well as at the area of proximal tibia. The remaining 14 patients (73.7%) of the group underwent medial hemiepiphysodesis of distal femurs bilaterally.

The most frequent diagnosis was idiopathic genu valgum (or genua valga), 2 patients suffered from epiphyseal dysplasia and 2 patients underwent surgery due to post-traumatic deformity.

Two patients with diagnosis of epiphyseal dysplasia were operated although they were diagnosed with the epiphyseal dysplasia. Average initial preoperative IMD in the standing position was 15.8 cm. The average preoperative LDFA was 81° and MPTA 97°, respectively.

At the time of the hardware removal, average preoperative value of LDFA measured by radiograph raised from 81° (79–84) to the average 89° (87–92), initial average preoperative value of MPTA decreased from 97° (92–98) to the average of 88° (86–89) and preoperative IMD in the standing position decreased to around 0 cm. Correction of genua valga by the 8-figure plates in one of our patients is demonstrated at X-rays of his knee joints. Average difference of LDFA measure in 3-months interval of follow-up in these patients equals 2.1° ( $\pm 0.9$ ) and the difference of MPTA equals 1.5° ( $\pm 0.6$ ) (Table 1). Treatment was successfully completed in all patients and plates were extracted in 9.1 months (6.3–12.1) in average after the surgery.

The mean time of the surgery for unilateral genu valgum was 27 min ( $\pm 7$ ), in patients with bilateral genua valga 43min ( $\pm 5$ ). Patients stayed in the hospital for 2 days in average (1–4 days) and this time was directly dependent on the retreat of post-operative pain and the especially on the effectiveness of post-operative rehabilitation and ability to

walk on crutches. No complications in this patients' group were observed.

**Ballal et al.** treated 25 children (37 legs and 51 segments) with coronal plane deformities around the knee with the extraperiosteal application of a flexible two-hole plate and screws.

**Ballal et al.** found that the mean age was 11.6 years (5.5 to 14.9), the median angle of deformity treated was 8.3° and mean time for correction was 16.1 months (7 to 37.3). There was a mean rate of correction of 0.7° per month in the femur (0.3° to 1.5°), 0.5° per month in the tibia (0.1° to 0.9°) and 1.2° per month (0.1° to 2.2°) if femur and tibia were treated concurrently. Correction was faster if the child was under 10 years of age. The patients followed between six and 32 months after plate removal. One child had a rebound deformity.<sup>[13]</sup>

Finally, we can say that the ability to perform the implantation and removal of the device as day surgery or with overnight stay is an added advantage over correction by osteotomy. Most children were walking confidently without aids by the second post-operative week.

## CONCLUSION

This study has confirmed the reversible nature of growth inhibition on the physis produced by a bridging flexible titanium plate and has demonstrated its value in correcting deformities around the knee. The procedure is simple and effective for treating genu valgum for many children. The technique is simple and economic. It is an excellent choice for angular deformity correction. We recommend that new studies up to date this technique because it is safe and minimally invasive technique for correction of limb deformity.

### Declaration of interest

The authors report no conflicts of interest. The authors alone are responsible for the content and writing of the paper.

### Funding information

None declared

## REFERENCES

1. Stevens PM, Maguire M, Dales MD (1999): Physeal stapling for idiopathic genu valgum. *Journal of Pediatric Orthopaedics*; 19(5): 645.
2. Hecht M (2017): What causes genu valgum (knock-knees) and how is it treated.



- University of Illinois-Chicago, School of Medicine.
3. Salenius P, Vanakka E (1975): The development of the tibio-femoral angle in children. *J Bone Joint Surg Am* 1975; 57: 259.
  4. Metaizeau J-P, Wong-Chung J, Bertrand H, (1998): Percutaneous epiphysiodesis using transphyseal screws (PETS). *J Pediatr Orthop*; 18: 363-9.
  5. Stevens PM (2007): Guided growth for angular correction: a preliminary series using a tension band plate. *J Pediatr Orthop*; 27: 253-9.
  6. Steel HH, Sandrow RE, Sullivan PD (1971): Complications of tibial osteotomy in children for genu varum or valgum: evidence that neurological changes are due to ischemia. *J Bone Joint Surg [Am]*; 53-A: 1629-35.
  7. Haas SL (1948): Mechanical retardation of bone growth. *J Bone Joint Surg [Am]*; 30-A: 506-12.
  8. Blount WP, Clarke GR (1949): Control of bone growth by epiphyseal stapling: a preliminary report. *J Bone Joint Surg [Am]*; 31-A: 464-78.
  9. Yakut US, Yazici M, Kandemir U (2005): The effect of temporary hemiepiphysal stapling on the growth plate: a radiologic and immunohistochemical study in rabbits. *J Pediatr Orthop*; 25: 336-41.
  10. Khoury J, Tavares J, McConnell S (2007): Results of screw epiphysiodesis for the treatment of limb length discrepancy and angular deformity. *J Pediatr Orthop*; 27: 623-8.
  11. Burghardt R, Herzenberg J, Standard S and Paley D (2008): Temporary hemiepiphysal arrest using a screw and plate device to treat knee and ankle deformities in children: a preliminary report. *J Child Orthop* 2(3):187–197
  12. Fraser RK, Dickens DR, Cole WG (1995): Medial physeal stapling for primary and secondary genu valgum in late childhood and adolescence. *J Bone Joint Surg [Br]*; 77-B:733-5.
  13. Ballal MS, Bruce CE and Nayagam S (2010): Correcting genu varum and genu valgum in children by guided growth. *J Bone Joint Surg (Br)*; 92-B: 273-6.14.
  14. Jiri Jochymek, Jakub Turek, Tereza Peterkova, Karel Urbasek (2016): Locomotor System vol. 23, 2016, No. 1 / Pohybove Ustroji , rocnik 23, 2016, č. 1.

#### How to Cite

omar, M., Idris, K., Megahed, R., Mohammed, M. Guided Growth for Genu Valgum Deformity in Children. *Zagazig University Medical Journal*, 2021; (801-809): -. doi: 10.21608/zumj.2021.14025.1280