

Histological effect of high versus low dose isotretinoin and possible protective role of Tiron on skin of adult male albino rat

Original
Article

Maha E. Soliman, Hala El-Haroun, Maisa Kafafy, Doaa M. Mohamed

Department of Histology, Faculty of Medicine, Menoufia University

ABSTRACT

Background: Isotretinoin is one of the most effective drugs in acne treatment. It is retinoic acid derivative. Systemic administration of isotretinoin may induce many adverse effects. Tiron has antioxidant properties and could ameliorate skin damage and cell apoptosis.

Aim of the work: To evaluate the adverse effect of high versus low dose isotretinoin on the skin of adult albino rats and the probable protective effect of tiron.

Material and Method: Sixty adult male albino rats were divided into five groups: control group I (DMSO and saline), tiron treated group II (300 mg/kg orally), isotretinoin treated group III (6 mg/kg /day IP), isotretinoin treated group IV (3 mg/kg / day IP), and protective group V which treated with isotretinoin and tiron. Rats of the last group were subdivided into 2 equal subgroups (V a & V b) which received isotretinoin at a dose of 6mg and 3mg /kg/day respectively with tiron. At the end of the studied period, rats were then sacrificed and the samples were taken for histological, histochemical, immunohistochemical and morphometric studies.

Results: Animals treated with isotretinoin at a dose of 6mg/kg/day showed thinning of all layers of epidermis. Epidermal cells were degenerated, exfoliated with marked reduction in cellular proliferation and associated with ill-defined basement membrane. Sebaceous glands showed a marked reduction in surface area and some cells appeared degenerated and dermis revealed loss of its normal architecture and increased densely packed collagen fibers seen by Mallory trichrome stain. These degenerative changes were less apparent in administration of isotretinoin at a lower dose of 3mg/kg/day.

Concomitant administration of tiron and isotretinoin induced an observable improvement protection against these changes compared to control, especially in low dose.

Conclusion: The pronounced skin damage induced by isotretinoin can be ameliorated by joined therapy of tiron and isotretinoin.

Received: 28 December 2018, **Accepted:** 30 January 2019

Key Words: Isotretinoin; skin; tiron.

Corresponding Author: Doaa M. Mohamed, MSc, Department of Histology, Faculty of Medicine, Menoufia University, Egypt, **Tel.:** +20 482313855, **E-mail:** doaamostafa189@yahoo.com

ISSN: 1110-0559, Vol. 42, No. 2

INTRODUCTION

Isotretinoin is one of the most effectively used retinoids in the treatment of acne.

It is a vitamin A derivative. Isotretinoin (13-cis-retinoic acid) suppress the activity of sebaceous gland and downregulate sebum production. It inhibits oxidation of 3- α -hydroxysterol dehydrogenase activity of retinol dehydrogenase-4^[1]. Effect of isotretinoin is not restricted to skin and hair follicles but also induces adverse effects on different organs and tissue in the body^[2]. Isotretinoin is a prodrug mediating its activity through isomerization to all-trans-retinoic acid (ATRA)^[3]. Adverse effects of isotretinoin on the skin are dose-dependent and mainly induced a reduction in sebum production, decreased stratum corneum thickness and affected the function of the skin barrier^[4]. Pioneering researchers detected the anti-keratinizing effect for retinoid which constituted changes in the water loss from epidermis associated epidermal loosening and loss of epidermal adhesion which was dose-

dependent^[2]. All trans-retinoid acid (ATRA) was proved to regulate cell cycle and apoptosis. Lately, ATRA has been shown to inhibit gene responsible for the synthesis of epidermal lipids, long-chain fatty acids, cholesterol and sphingolipids in primary human keratinocytes^[5].

Tiron, 4, 5-dihydroxy-1, 3-benzene disulfonic acid is an effective antioxidant capable of scavenging a variety of radicals^[6]. Tiron is a mitochondrial localized antioxidant which can penetrate the organelle membrane and pile up inside^[7], is also able to remove iron and other metals and manifest ROS hunting properties^[8,9].

Tiron is also a vitamin E analog and acts as a direct hydroxyl radical (HO) and superoxide scavenger. Tiron totally reduced the damage of mitochondria and nuclear DNA induced by ultraviolet radiation in the skin. The tiron's consequence against oxidative damage was rendered to its antioxidant and metal chelating properties^[7]. Tiron elevation the percentage of cells in the interphase especially G and S phase of the cell cycle^[10]. The present

research is a trial to assess the consequences of isotretinoin on the skin and the feasible protective and curable role of tiron.

MATERIALS AND METHODS

Animals

The study was carried out in the Animal House of Faculty of Medicine, Menoufia University. It included sixty adult male albino rats of average weight (180-200 grams). They were kept under good hygienic conditions and left to acclimatize for one week. They were fed on ordinary food and housed under standard laboratory conditions.

Drugs and chemicals

Isotretinoin was purchased from (Sigma Aldrich Chemical Co., St. Louis, MO, USA) in the form of soft gelatin capsules (200 mg) then dissolved in 1 ml dimethyl sulfoxide solvent (DMSO) and 39 ml saline and given at a dose of 3 mg/kg/day and 6 mg/kg/day intraperitoneal^[11].

Tiron (Sigma Aldrich Chemical Co., St. Louis, MO, USA) was suspended in 0.5 % carboxymethyl cellulose (CMC) and taken orally at a dose of (300mg/kg)^[12].

Design and experimental groups

The animals were divided into five groups.

Group I (control group) composed of 10 rats were given the vehicle (DMSO and saline) IP daily for 4 weeks.

Group II (Tiron treated group) composed of 10 rats (300mg/kg orally for 4 weeks).

Group III was received isotretinoin at a dose of 6mg/kg/day by intraperitoneal injection daily for 4 weeks.

Group IV was received isotretinoin at a dose of 3mg/kg/day by intraperitoneal injection daily for 4 weeks.

Group V was 20 rats treated with isotretinoin and tiron for 4 weeks. Half of the rats (subgroup Va) was received tiron joined with isotretinoin at a dose of 6mg/kg/day and the other half (subgroup Vb) was received tiron joined with isotretinoin at a dose of 3mg/kg/day.

Histological and Histochemical study

Rats were anesthetized using ether inhalation then were sacrificed, and then the abdominal skin of each animal was shaved and excised.

A- Haematoxylin & Eosin (H&E)

Small pieces samples were immediately immersed in 10% buffered formalin fixative for 48 hours. The specimens were processed as paraffin blocks. Five-micron thick sections were cut and stained with hematoxylin and eosin (H&E)^[13]. Histological assessment was performed under light microscopy.

B-Mallory trichrome (MT) stain

In these sections the nuclei appear black, muscle appears red, blood cells, fibrin appear red and collagen, amyloid, and mucin appear blue^[14].

C-Periodic acid Schiff (PAS) stain

PAS-positive materials have Magenta red color and Harris' hematoxylin was used to counterstain the nuclei.^[14]

II-Immunohistochemical study

immunohistochemical staining using

- Epithelial membrane antigen (EMA) antibody (Thermo Fisher Scientific, USA) It stained cytoplasm and plasma membrane of all cells in sebaceous gland alveoli^[15].
- Cytokeratin 5/6 (Santa Cruz Biotechnology, USA) It showed the intermediate filament exhibited in the basal and suprabasal layers of the epidermis and epithelium of skin appendages^[16].
- Ki 67 (Santa Cruz Biotechnology, USA) It showed the proliferative capacity of keratinocytes. Proliferating nuclei are brown^[17].

Morphometric and Statistical analysis

Ten non-overlapping fields from slides of each group stained by Haematoxylin & Eosin stain were examined to measure the epidermal thickness (μm) and sebaceous gland surface area (mm^2).

Slides were examined using computerized image analyzer (Leica Imaging System Ltd., Cambridge, England).

Data were collected (epidermis thickness, sebaceous gland surface area) and tabulated by Statistical Package for Social Sciences (SPSS), a program for Windows, version 17, SPSS, INC., Chicago, Illinois, USA. Mann-Whitney test (nonparametric test) was used. *P values of ≤ 0.01* were considered statistically significant and highly significant when *P value ≤ 0.001*

RESULTS

Histological, histochemical results

Group I (control group)

Skin sections from control normal rats revealed normal structure (epidermis, dermis). The epidermis of the skin was stratified squamous keratinized epithelium. The epidermis contains several strata. The strata are basale, spinosum, granulosum, and corneum. There was an acidophilic layer; basement membrane beneath the epithelium. Dermis considers about 90% of skin weight. Two definite regions are recognized in the dermis. An external papillary dermis underlying to the basement membrane seems like a loose network of thin collagen fibrils and blood vessels. Underneath this layer is a deeper reticular layer, consisting of thick irregular order bundles of fibrils of dense collagen and is less cellular. Bundles of collagen fibers are best seen by Mallory trichrome stain. The Main cell type in the dermis is fibroblasts noticed between the collagen fibers as flat cells with spindle-shaped nuclei. The dermis also contains blood vessels that supply the epidermis. There were hair follicles, sweat glands, and sebaceous glands. (Figures 1,a-b). Histochemically, PAS reaction of the

skin revealed moderate positive reaction in the basement membrane (Figure 1,c). Immunohistochemically, Group I revealed intense positive cytoplasmic immunoreaction for EMA in the sebaceous glands (Figure 1-d), strong positive immunoreactivity for CK 5/6 in the cytoplasm of the basal and suprabasal cells (Figure 1-e) and moderate positive immunoreactivity for Ki 67 in basal cell layer nuclei (Figure 1-f)

Group II (Tiron group) revealed the same histological and histochemical microscopic appearance similar to that of the control (Figures 2, a,b,c). Immunohistochemically, it exhibited intense positive immunoreactivity for EMA in the cytoplasm of the sebaceous glands (Figure 2,d), intense positive immunoreactivity for CK 5/6 in the cytoplasm of the basal and suprabasal cells (Figure 2,e) and strong positive immunoreactivity for Ki 67 in basal cell layer nuclei (Figure 2,f).

Group III

Administration of isotretinoin at a dose of 6mg/kg/day caused severe degenerative changes. Irregular skin surface was observed in sections of isotretinoin treated animals. Some epidermal cells showed marked degeneration and vacuolation which give bubble-like appearance. Degenerated cells had small, shrunken and peripheral nuclei. Overall reduction in the thickness of epidermis was markedly observed to be 2-3 layers thick. Stratum corneum was loose, disordered and demonstrated isolated areas of diminished thickness and there is a basket weave appearance (Figure 3, a). Dermis revealed disturbance of its architecture and increased densely packed collagen fibers seen by Mallory trichrome stain (Figure 3, b).

PAS reaction showed a marked reduction in the basement membrane in some patches while it was ill-defined in other patches, PAS was weakly positive in certain areas and ill-defined in other areas (Figure 3, c).

Immunohistochemically, it showed weak positive immunoreactivity for EMA in sebaceous glands (Figure 3,d) and it appeared smaller in size, weak positive immunoreactivity for CK 5/6 in the cytoplasm of the basal and suprabasal cells (Figure 3,e) and weak positive immunoreactivity for Ki 67 in basal cell layer nuclei (Figure 3,f).

Group IV

Reception of isotretinoin at a dose of 3mg/kg/day revealed regression in the degenerative changes in the skin than treatment with a dose of 6mg/kg/day with evidenced week positive PAS reaction in the basement membrane (Figures 4, a, b, c). Immunohistochemically, it showed a moderate cytoplasmic positive reaction for EMA in sebaceous glands (Figure 4,d), moderate positive immunoreactivity for CK 5/6 in the cytoplasm of the basal and suprabasal cells (Figure 4,e) and mild positive immunoreactivity for Ki 67 in basal cell layer nuclei (Figure 4,f).

Group V

Treatment with tiron and isotretinoin as 6mg /kg/day for 4 weeks (group Va) showed apparently reduced thickness of the epithelium as compared to control. Sebaceous gland showed nearly normal size compared to control (Figure 5, a). Dermis showed nearly normal irregular arrangement and density of collagen fibers seen by Mallory trichrome stain (Figure 5, b). Basement membrane showed well defined positive reaction (Figure 5, c). Immunohistochemically, it showed moderate positive immunoreactivity for EMA in sebaceous glands (Figure 5, d), moderate positive cytoplasmic immunoreactivity for CK 5/6 in the basal and suprabasal cells (Figure 5, e) and mild positive immunoreactivity for Ki 67 in basal cell layer nuclei (Figure 5, f).

Whereas, skin sections of rats treated by tiron and isotretinoin at a dose of 3mg /kg/day (group Vb) showed nearly normal skin structure compared to control (Figures 6, a, b, c). Immunohistochemically, it showed intense positive cytoplasmic immunoreaction for EMA in the sebaceous glands (Figure 6-d), strong positive immunoreactivity for CK 5/6 in the cytoplasm of the basal and suprabasal cells (Figure 6-e) and moderate positive immunoreactivity for Ki 67 in basal cell layer nuclei (Figure 6-f).

Quantitative results

Isotretinoin reception at a dose of 6mg/kg/day or 3mg/kg/day led to a highly significant decrease (P -value < 0.001) in the epidermal thickness when compared to the normal control animals. Tiron treated animals showed non-significant differences (P -value > 0.05) and were nearly similar to normal control group. Concomitant treatment with tiron and isotretinoin revealed also revealed non-significant differences as compared to control (P -value > 0.05) (Tables 1 and 2, Figure 6, Histogram I).

The sebaceous gland surface area of 6mg/kg/day or 3mg/kg/day treated with isotretinoin revealed highly significant reduction (P -value < 0.001) compared to control and there was non-significant differences as compared to control (P value > 0.05) in tiron treated group as well as groups treated with tiron and isotretinoin (Tables 1 and 3, Figure 6, Histogram II).

- Group I: (control group)
- Group II: (Tiron only for 4 weeks).
- Group III: (isotretinoin as 6mg/kg/day for 4 weeks)
- Group IV (isotretinoin as 3mg/kg/day for 4 weeks)
- Group Va: (tiron and isotretinoin as 6mg/kg/day for 4 weeks).
- Group Vb: (tiron and isotretinoin as 3mg/kg/day for 4 weeks)

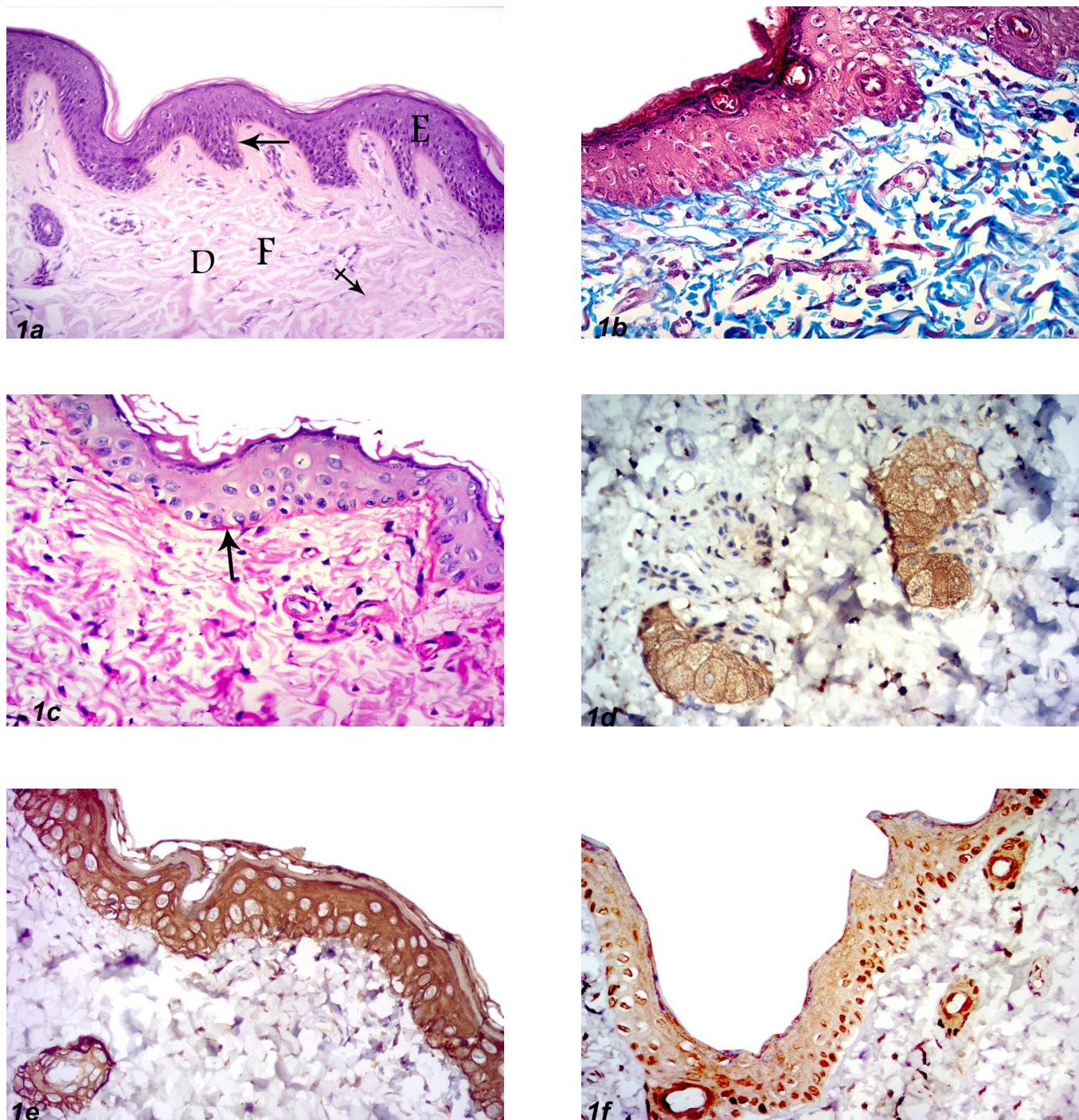


Fig. 1: Skin sections of control group I (a) Skin of control albino rat demonstrate normal skin structure as stratified squamous keratinized epithelium (E) resting on basement membrane (↓), normal dermis (D) with fibroblast (F) and collagen fibers (crossed arrow) (H&E X200), (b) normally appeared loosely irregularly arranged collagen fibers (Mallory trichrome X400), (c) moderate positive PAS reaction in the basement membrane (arrow) (PAS reaction X 400), (d) intense cytoplasmic immunoreactivity for EMA in sebaceous gland (EMAX 400), (e) strong positive cytoplasmic immunoreactivity for CK 5/6 in the basal and suprabasal cells (CK5/6 X 400). (f) control skin revealed moderate positive immunoreactivity for Ki 67 in the basal cell layer (Ki 67 X 400).

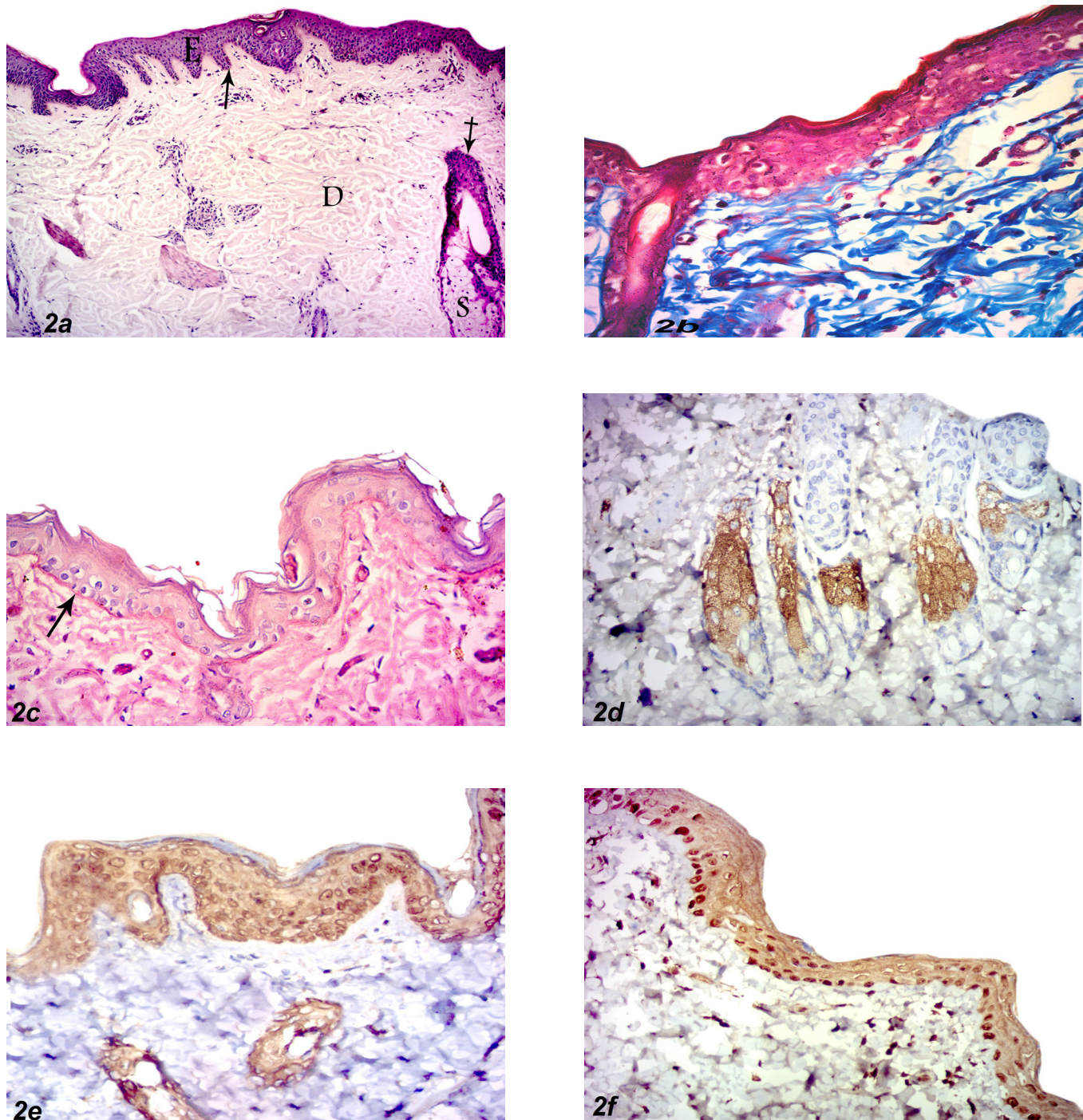


Fig. 2: Skin sections of group II (a) Skin of albino rat treated with tiron only showing skin structure as a normal appearance of skin epidermis (E). There is intact basement membrane (↓). Dermis (D) shows hair follicle (crossed arrow) with sebaceous gland (S) (H&E X100). (b) normally appeared collagen fibers (Mallory trichrome X400). (c) moderate positive PAS reaction in the basement membrane (arrow) similar to the control (PAS reaction X 400) (d) intense cytoplasmic immunoreactivity for EMA in sebaceous gland (EMAX 400) (e) strong positive cytoplasmic immunoreactivity for CK 5/6 in the basal and suprabasal cells (CK5/6 X 400) (f) strong positive immunoreactivity for Ki 67 in basal cell layer (Ki 67 X 400).

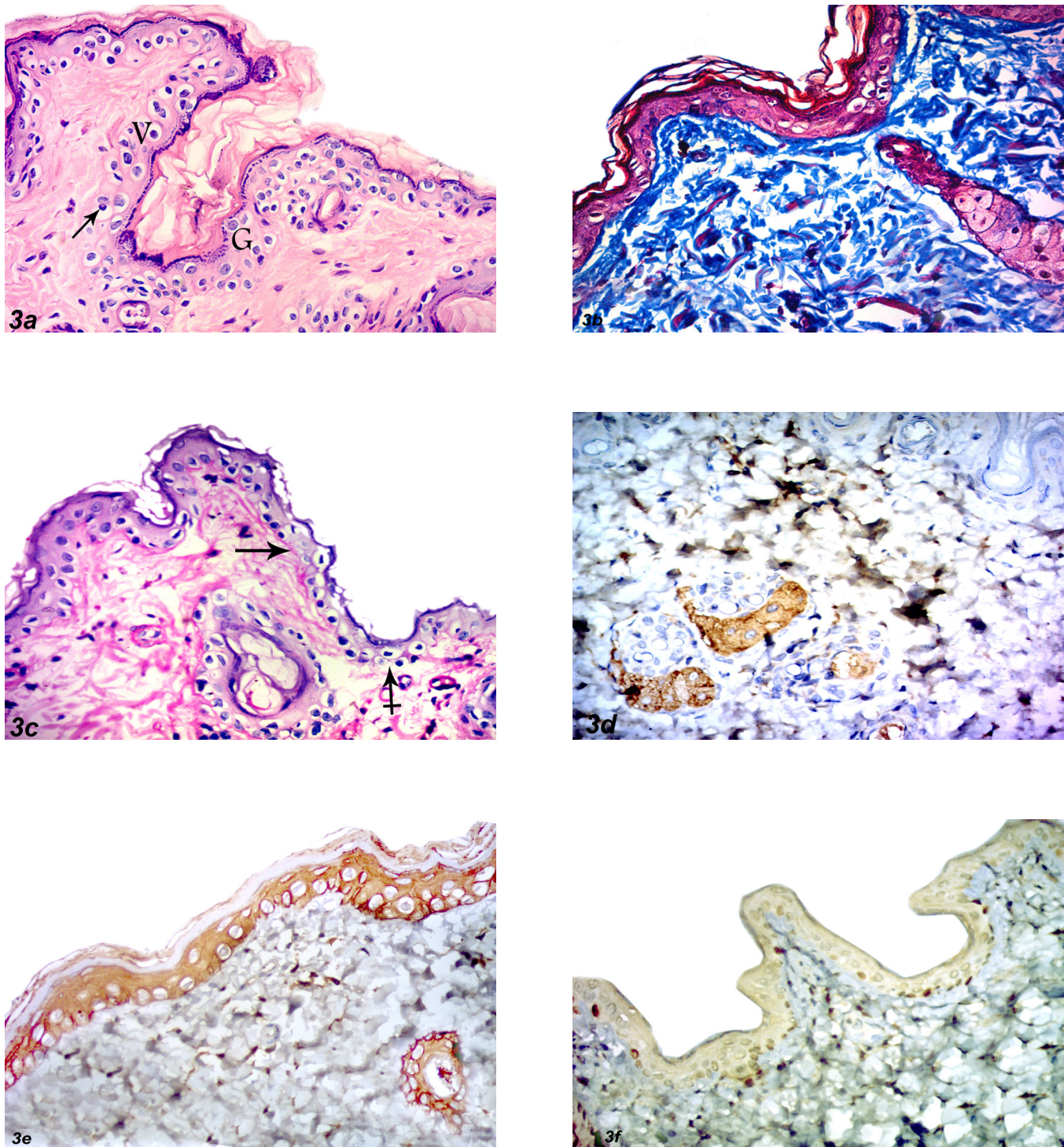


Fig. 3: Skin sections of group III (a) Skin of albino rat treated with isotretinoin at a dose of 6 mg/kg/day showing degenerative changes of skin there is degenerated, vacuolated (V) epithelial cells. Some cells show small, shrunken and peripheral nuclei (↓), others are completely degenerated leaving cell ghost (G) (H&E X400). (b) increased densely arranged of collagen fibers in the dermis (Mallory trichrome X 400). (c) PAS was weakly positive in certain areas (arrow) and ill-defined in other areas (crossed arrow) (PAS reaction X 400). (d) Weak positive cytoplasmic immunoreactivity for EMA in small-sized sebaceous gland (EMAX 400). (e) Weak positive cytoplasmic immunoreactivity for CK 5/6 in the basal and suprabasal cells (CK5/6 X 400). (f) Weak positive immunoreactivity for Ki 67 in the basal cell layer (Ki 67 X 400).

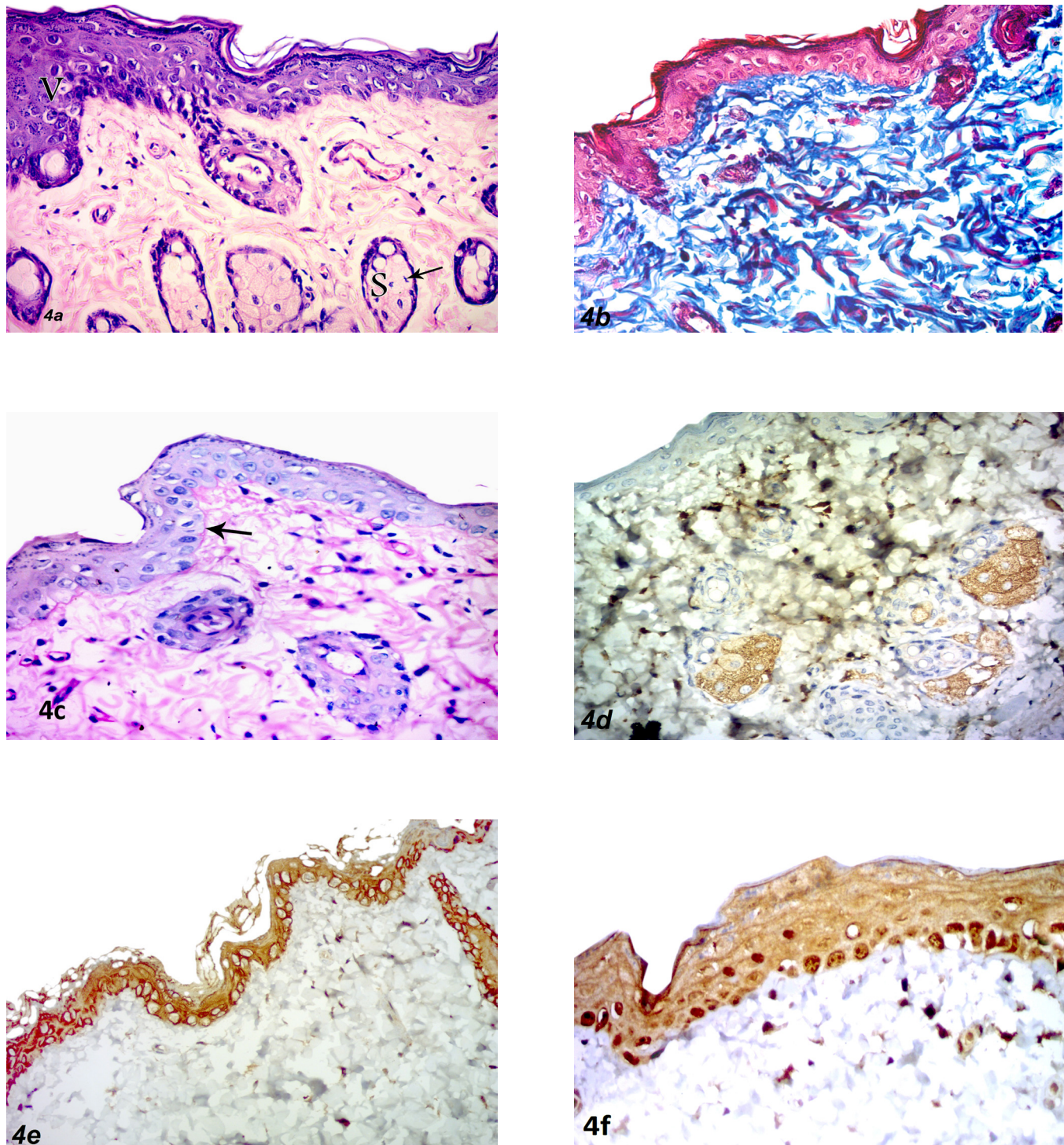


Fig. 4: Skin sections of group IV (a) Skin treated with isotretinoin at a dose of 3 mg/kg/day showing regression in the degenerative changes. There are vacuolated epithelial cells (V). Sebaceous glands(S) show a moderate decrease in size and some cells appeared degenerated (l) (H&E X400). (b) increased dense collagen fibers in the dermis (Mallory trichrome X 400). (c) Weak positive PAS reaction in the basement membrane (arrow) (PAS reaction X 400). (d) Moderate positive cytoplasmic immunoreactivity for EMA in sebaceous gland (EMAX 400). (e) Moderate positive cytoplasmic immunoreactivity for CK 5/6 in the basal and suprabasal cells (CK5/6 X 400). (f) Mild positive immunoreactivity for Ki 67 in the basal cell layer (Ki 67 X 400).

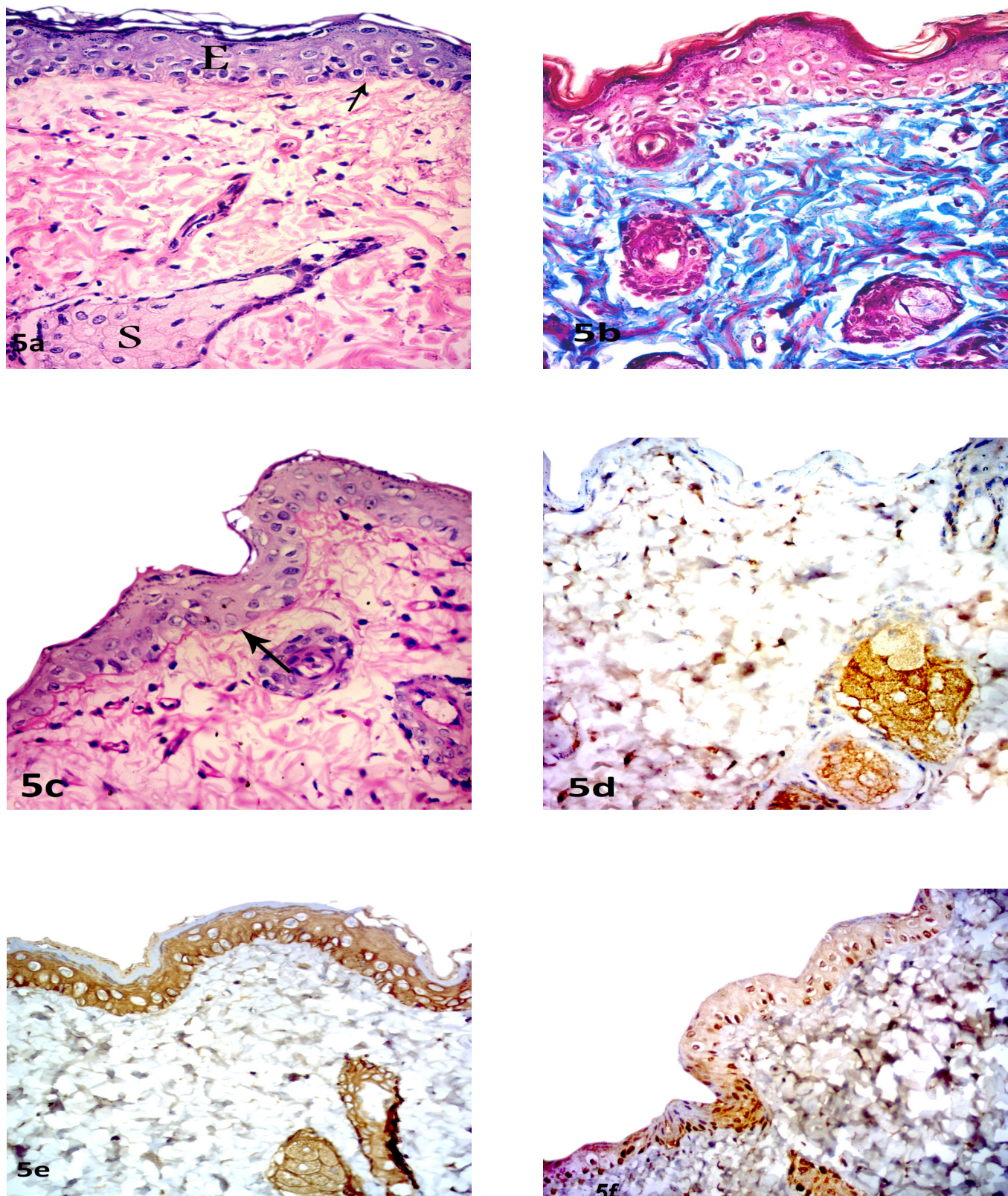


Fig. 5: Skin sections of group Va (a) Skin of albino rat treated with tiron and isotretinoin at a dose of 6 mg/kg/day showing a slightly reduced thickness of the epidermis (E). Basement membrane was intact (↓). Sebaceous gland showed nearly normal size (S) (H&E X400). (b) nearly normal collagen fibers in the dermis (Mallory trichrome X400). (c) moderate positive PAS reaction in the basement membrane (arrow) (PAS reaction X 400). (d) moderate positive cytoplasmic immunoreactivity for EMA in sebaceous gland (EMAX 400). (e) moderate positive cytoplasmic immunoreactivity for CK 5/6 in the basal and suprabasal cells (CK5/6 X 400). (f) mild positive immunoreactivity for Ki 67 in the basal cell layer (Ki 67 X 400).

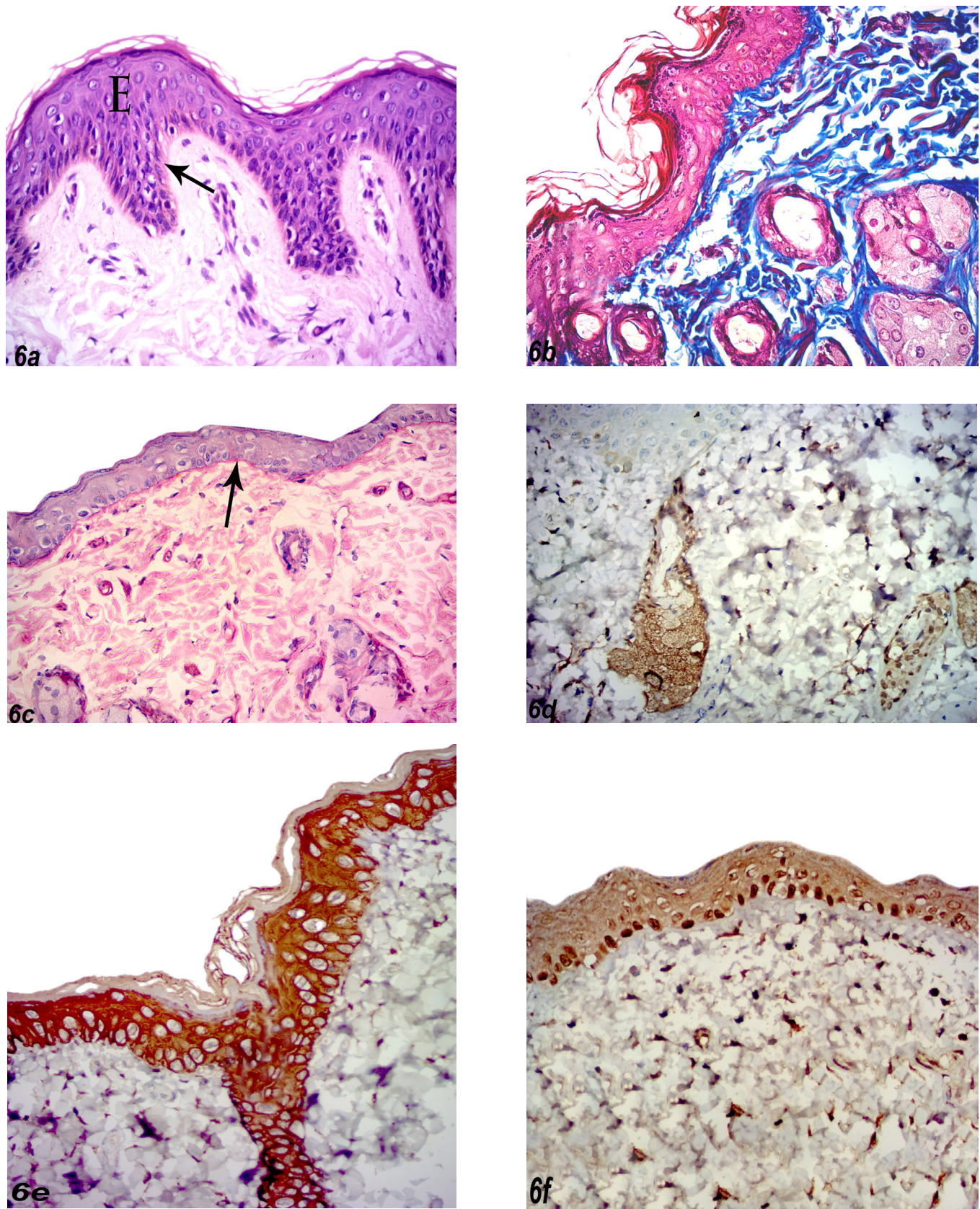


Fig. 6: Skin sections of group Vb (a) Skin of albino rat treated with tiron and isotretinoin at a dose of 3 mg/kg/day showing nearly normal epidermis (E). Basement membrane appeared intact (\downarrow) (H&E X400). (b) normally appeared collagen fibers in the dermis (Mallory trichrome X400). (c) strong positive PAS reaction in the basement membrane (arrow) (PAS reaction X 400). (d) strong positive cytoplasmic immunoreactivity for EMA in sebaceous gland (EMAX 400). (e) strong positive cytoplasmic immunoreactivity for CK 5/6 in the basal and suprabasal cells (CK5/6 X 400). (f) moderate positive immunoreactivity for Ki 67 in the basal cell layer (Ki 67 X 400).

Table 1: Descriptive statistics for the mean (X) and SD of different parameters in different groups

	Epithelium thickness	Sebaceous gland surface area
	$\bar{X} \pm SD$	$\bar{X} \pm SD$
Group I	102.7±1.06	0.27±0.34
Group II	102.1±1.02	0.26±0.105
Group III	77.2±11.28	0.11±0.12
Group IV	87.34±7.2	0.18±0.14
Group Va	101.07±0.25	0.24±0.11
Group Vb	101.2±0.9	0.248±0.12

Table 2: Comparison between the control group and other studied groups as regards epidermis thickness

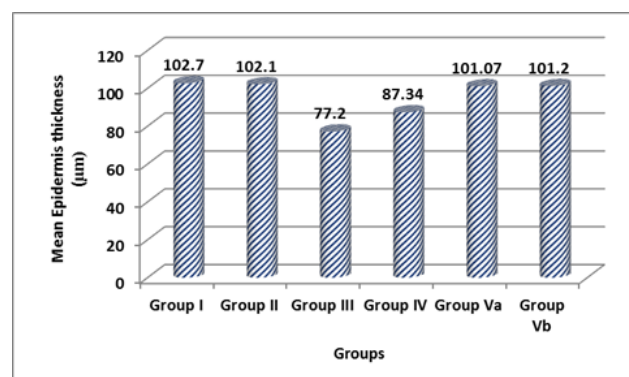
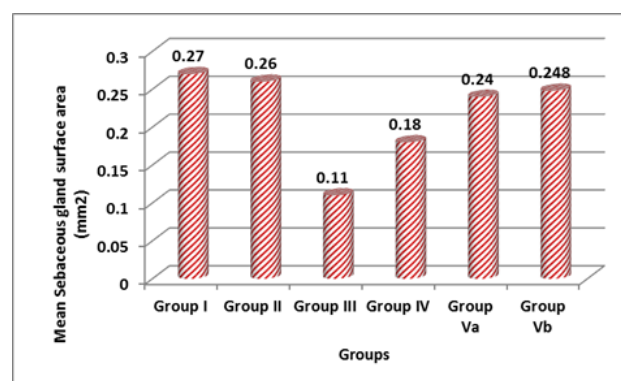
Comparison between control group and other studied groups			
Reference group	Epidermal thickness		
	Other groups	T.test	P.value
Group I	Group II	1.54	0.8
	Group III	6.99	0.001
	Group IV	7.12	0.006
	Group Va	1.28	0.41
	Group Vb	1.51	0.71

- *P* value > 0.05 means "non - significant"
- *P* value < 0.01 means "significant"
- *P* value < 0.001 means "highly - significant"

Table 3: Comparison between the control group and other studied groups as regards sebaceous gland surface area

Reference group	Sebaceous gland surface area		
	Other groups	T.test	P.value
Group I	Group II	1.3	0.78
	Group III	4.3	0.000
	Group IV	5.12	0.004
	Group Va	1.54	0.45
	Group Vb	1.56	0.69

- *P* value > 0.05 means "non - significant"
- *P* value < 0.01 means "significant" (*)
- *P* value < 0.001 means "highly - significant" (**)

**Histogram I:** For measuring the epidermal thickness (µm) in all groups.**Histogram II:** For measuring sebaceous gland surface area (mm²) in all groups.

DISCUSSION

The skin is the largest organ in the body. It protects the body against ultraviolet radiation, fighting microbe attack, and regulates water and electrolytes^[18]. Isotretinoin is an effective medication for the treatment of severe acne^[19].

Previous researches have highlighted the harmful adverse effects of isotretinoin treatment^[20]. Many undesired effects including sparse hair and hair thinning, conjunctivitis, mucous dryness and sensitivity to ultraviolet radiation^[21]. Isotretinoin reduces sebaceous gland surface area and suppresses sebum production by inhibiting sebaceous lipid synthesis^[22].

The present study revealed that administration of isotretinoin at a high dose induced various morphological and morphometric changes in the skin; these changes were in the form of overall reduction in the thickness of the epidermis, disorganized epithelial cells with abnormal shaped nuclei. Stratum corneum appeared loose, disorganized and fragmented. Basement membrane was ill-defined. Sebaceous glands revealed a marked reduction in surface area and some cells appeared degenerated. Disturbance of normal architecture of dermis and increased densely packed collagen fibers were observed. On the other hand, low dose of isotretinoin was associated with less obvious changes than the higher dose. These data were in agreement with those reported by others^[13,23,24], who observed that in the skin of rats and mice after 3 and 6mg/kg/day isotretinoin there is desquamation and considerably thin epidermis, thin or ill-defined basement membrane, disarranged stratum corneum and diminished the surface area of the sebaceous gland.

Epidermal cells and sebaceous gland cells degeneration were observed. These results were supported by previous studies that referred to skin pathologies after isotretinoin to oxidative damage^[25-27]. This could be explained by the fact that isotretinoin activates neutrophils which induce tissue injury via the release of ROS into the extracellular fluid. Isotretinoin induces production of free radicals (such as superoxide anion and hydroxyl radicals) and

reactive oxygen species (ROS) (such as hydrogen peroxide and singlet oxygen). It is documented that excessive production of ROS may induce extreme injury to cellular deoxyribonucleic acid (DNA) through dysfunction of the mitochondria which activate apoptogenic proteases and secondary endonuclease and lead to apoptosis^[25-27].

Isotretinoin also has an impact on cell membrane permeability resulting in lysis of cells and allowing vital substances to escape^[28].

Isotretinoin causes a loss of desmosomes and decreases tonofilaments and glycocalyx cohesion of the cell^[23].

Disorganized epidermal cells with abnormal shaped nuclei observed after isotretinoin could be explained by DNA damage in the skin following exposure to isotretinoin as reported by *Nelson et al*^[24].

Reduction in epidermal thickness noted in the current study could be owing to a deprivation of degenerated cells and abortion of cellular proliferation and regeneration as revealed *Goodfield et al*^[26].

Stratum corneum appeared loose, disorganized and fragmented as isotretinoin has high lipophilic features; isotretinoin inclines to concentrate in the top of stratum corneum^[29]. *Kmieć et al*^[30] also reported a disturbance of the epidermal barrier, leading to interference of stratum corneum hydration.

Interrupted or ill-defined basement membrane could be explained by the failure of damaged epithelial cells to synthesize collagen fibers of this layer. Histochemically, the basement membrane was ill-defined in certain areas. This is in harmony with *Pappas*^[31] who reported that collagen fibers of basement membrane were synthesized and secreted by keratinocyte which was degenerated after isotretinoin.

Increased arrangement of collagen fibers might be explained by increased expression of individual genes that stimulate synthesis of structural proteins of the extracellular matrix such as collagens, fibulin, and fibronectin. Increase in these protein domains production back the distinguishing fact that retinoids stimulate extracellular matrix deposition in wound healing and in aging skin^[13]

Isotretinoin affected the interphase especially G1 and S phase of the cell cycle, in the form of reduced DNA synthesis, stimulated p21 protein, and reduced cyclin D1 protein which leads to cell cycle arrest^[24]. This processes sebocytes; give a clarification for the histological data that revealed a severe decrease in the surface area, shape, and lipid components of sebaceous glands in skin treated with isotretinoin^[24]. Isotretinoin inhibits cell proliferation in sebocytes after subjected to tretinoin by a RAR-mediated pathway and cell cycle arrest and apoptosis. RAR-independent mechanism promotes suppression effect of sebocytes. Cell cycle arrest and apoptosis induced by isotretinoin provide suppression of sebum. Furthermore, isotretinoin suppresses sebaceous lipid synthesis by a RAR-

and RXR-mediated pathway^[32]. Retinoids may inhibit lipid synthesis in sebocytes either directly by inhibiting enzymes of lipogenesis or indirectly by decreasing the division rate of sebocytes^[33].

Immunohistochemically, there was weak positive cytoplasmic immunoreaction for EMA in the sebaceous glands and for CK 5/6 in the cytoplasm of the basal and suprabasal cells of epidermis 4weeks after isotretinoin treatment at a dose of 6 mg/kg/day. This might explain by apoptosis of these cells^[24].

Rats treated with low dose isotretinoin showed less degenerative changes than high dose. There was variation in thickness of the epithelium with disorganized cells and severe irregular skin surface. Basement membrane was interrupted. Sebaceous glands revealed a moderate decrease in surface area and some cells had small, shrunken and peripheral nuclei. Dermis showed increased collagen fibers. Immunohistochemically, there was a moderate positive reaction for EMA and C K 5/6. There is mild positive immunoreactivity for Ki 67 in basal cell layers. These data were in agreement with *Charakida et al*^[11].

Tiron, 4,5-dihydroxy-1,3-benzene disulfonic, binds and removes iron and other metals^[34] and reveals anti-oxidant properties^[9,34-35], is also able to pass through the mitochondrial membrane^[9,35]. Tiron act as a protective agent against the pathological conditions of oxidative stress, as it is able to hunt various radicals^[36]. Tiron totally diminishes mitochondria and DNA injuries in skin cells exposed to ultraviolet radiation^[7]. The effect of tiron is not limited to the mitochondria but also gives broad cellular protection through radical scavenging and metal chelating antioxidant effects^[7,37].

In the current study, joined uses of tiron and isotretinoin at a high dose showed a slightly reduced thickness of the epithelium. Basement membrane appeared intact. Sebaceous gland showed nearly normal surface area. Dermis regained normal arrangement and density of collagen fibers. These results were confirmed by image analysis. Skin sections of rats treated with tiron and isotretinoin at a low dose revealed nearly normal skin structure. These findings were supported by *Oyewole et al*^[38] who reported that epidermis was normally arranged and sebaceous gland showed nearly normal surface area in skin sections of rats protected with tiron than those exposed to isotretinoin without protection.

The weak positive immunoreaction for Ki 67 in the basal cell layer of epidermis 4weeks after treated with isotretinoin at a high dose. This could be referred to that isotretinoin causes inhibition of cell proliferation. This agreed with *Nelson et al*.^[24]

From the foregoing, it was obvious that isotretinoin may induce many hazardous morphological effects on the skin. Such deleterious effects might be improved with the concomitant use of tiron. So, we advocate the use of isotretinoin in a relatively low dose and supplemented with

tiron as a protective measure against skin damage. Tiron had antioxidant properties and had no toxic effect on skin and can decrease the DNA damage and cell apoptosis induced by isotretinoin. These benefits might be more appraised in the future.

CONFLICTS OF INTEREST

The authors have no conflicts of interest to declare.

REFERENCES

1. Gu'rbu'z A, O' zhan G, Gu'ngo'r S, Erdal M S: " Colloidal carriers of isotretinoin for topical acne treatment: Skin uptake, ATR-FTIR and in vitro cytotoxicity studies" *Arch Dermatol Res*, 2015;307:607–615.
2. Melnik B C: "Isotretinoin and FoxO1 A scientific hypothesis". *Dermato-Endocrinology*, 2011;3:3:141-165.
3. Zouboulis CC: "Isotretinoin revisited: Pluripotent effects on human sebaceous gland cells". *J Invest Dermatol*, 2006;126:2154-6.
4. Ganceviciene R, Zouboulis CC: Isotretinoin: state of the art treatment for acne vulgaris. *Expert Rev Dermatol*, 2007; 2:693-701.
5. Lee DD, Stojadinovic O, Krzyzanowska A, Vouthounis C, Blumenberg M. and Tomic-Canic M.: Retinoidresponsive transcriptional changes in epidermal keratinocytes. *J Cell Physiol*, 2009; 220:427-39.
6. Shibayama-Imazu T, Sonoda I, Sakairi S, Aiuchi T, Ann WW, Nakajo S, *et al.*:" Production of superoxide and dissipation of mitochondrial transmembrane potential by vitamin K2 trigger apoptosis in human ovarian cancer TYK-nu cells". *Apoptosis* 2006; 11: 1535–43.
7. Oyewole AO, Birch-Machin MA: Mitochondria-targeted antioxidants. *FASEB J*, 2015; 29:4766–4771.
8. McArdle, F., Pattwell, D. M., Vasilaki, A., McArdle, A., and Jackson, M. J. Intracellular generation of reactive oxygen species by contracting skeletal muscle cells. *Free Rad. Biol. Med*, 2005; 39, 651–657.
9. Silveira, L. R., Pereira-Da-Silva, L., Juel, C., and Hellsten, Y. Formation of hydrogen peroxide and nitric oxide in rat skeletal muscle cells during contractions. *Free Rad. Biol. Med*, 2003; 35, 455–464.
10. Monticone M, Taherian R, Stigliani S, Carra E, Monteghirfo S, Longo L, *et al.*:" NAC, Tiron and Trolox Impair Survival of Cell Cultures Containing Glioblastoma Tumorigenic Initiating Cells by Inhibition of Cell Cycle Progression". *PLoS ONE*, 2014; 9 (2).
11. Charakida A, Mouser PE,Chu AC:" Safety and side effect of the acne drug, oral isotretinoin". *Expert Opin.Drug Saf*, 2014;3(2):119-129.
12. Shoeib AM, Said E, Ammar EM:"Cytoprotective potential of tiron and methyl palmitate against acetaminophen-induced acute liver injury". *Canadian journal of physiology and pharmacology*, 2015:94(2), 147-154.
13. Nelson AM, Zhao W, Gilliland KL, Zaenglein AL, Liu W, Thiboutot DM. Temporal changes in gene expression in the skin of patients treated with isotretinoin provide insight into its mechanism of action. *Dermatoendocrinol*, 2009; 1:177-87.
14. Bancroft,J.D., Gamble,M.: *Theory and Practice of Histological Techniques*,5th ed.Churchill Livingstone,Edinburgh, London, New York, Tokyo, 2002;139.
15. Warren, K. J.,Cruz,P.D.: *Clinical Outcome and Cost Analysis of Isotretinoin Versus Conventional Regimenes in the Treatment of Moderate Acne Vulgaris in Male Patients*, *pediatric dermatology*, 1998;15(4), 329-331.
16. Frade MAC, Andrade TAM, Aguiar AFCL, Guedes FA, Leite MN, Passos WR, Coelho EB, Das PK.: Prolonged viability of human organotypic skin explant in culture method (hOSEC). *An.Bras. Dermatol.*, 2015;90(3):347-50.
17. Piattelli, A., Carinci,F., Iezzi,G., Perrotti,V., Goteri, g., Fioroni, M.: Oral lichen planus treated with 13-cis-retinoic acid (isotretinoin): effects on the apoptotic process, *Clin Oral Invest*, 2007;11: 283–288.
18. Firooz A, Sadr B, Babakoochi S, Sarraf-Yazdy M, Fanian F, Kazerouni-Timsar A, *et al.*: Variation of biophysical parameters of the skin with age, gender, and body region. *ScientificWorldJournal*, 2012; 2012:386936.
19. Zaenglein AL, Graber EM, Thiboutot DM, Strauss JS. Acne vulgaris and acneiform eruptions. In: Wolff K, Goldsmith LA, Katz SI, Gilchrist BA, Paller AS, Leffell DJ, editors. *Fitzpatrick's Dermatology in General Medicine*. 7th ed. New York, NY, USA: McGraw Hill, 2008; 690-703.
20. Cyrulnik AA, Viola K V, Gewirtzman AJ, Cohen S R. High-dose isotretinoin in acne vulgaris: improved treatment outcomes and quality of life. *Int J Dermatol*, 2012; 51:1123-1130.
21. Karadag A S, Çalka Ö, Akdeniz N. Evaluation of

- Side Effects of Isotretinoin in 150 Patients with Acne Vulgaris. *Türkderm*, 2011; 45: 37-42.
22. Zouboulis CC, Orfanos CE.:Retinoids. In: Millikan LE (ed). *Drug Therapy in Dermatology*. Marcel Dekker: New York/Basel, 2000; 171–233.
 23. Baert A L.: " The Retinoids." Academic Press, 2014; 394-395.
 24. Nelson AM, Gilliland KL, Cong Z. and Thiboutot D.M.: 13-cis Retinoic acid induces apoptosis and cell cycle arrest in human SEB-1 sebocytes. *J Invest Dermatol*, 2006; 126:2178–2189.
 25. Georgala S, Papassotiriou I, Georgala C, Demetriou E, Schulpis KH. Isotretinoin therapy induces DNA oxidative damage. *Clin Chem Lab Med* 2005; 43: 1178–1182.
 26. Goodfield MJ1, Cox NH, Bowser A, McMillan JC, Millard LG, Simpson NB, *et al.*: Advice on the safe introduction and continued use of isotretinoin in acne in the U.K.. *Br J Dermatol* 2010; 162: 1172–1179.
 27. Sahin M, Uğuz AC, Demirkan H. and Nazıroğlu M.: Colchicine modulates oxidative stress in serum and leucocytes from remission patients with Family Mediterranean Fever through regulation of Ca²⁺ release and the antioxidant system. *J Membr Biol*, 2011; 240: 55–62.
 28. Penzer R. and Ersser S.: " Principles of Skin Care: A Guide for Nurses and Health Care Practitioners." John Wiley and Sons, 2010; 10:189.
 29. Gurbuz A, Ozhan G, Gungor S. and Erdal M.S.: " Colloidal carriers of isotretinoin for topical acne treatment: skin uptake, ATR-FTIR and in vitro cytotoxicity studies". *Arch Dermatol Res*, 2015; 307:607–615.
 30. Kmiec ML, Pajor A, Broniarczyk-Dyla G.: " Evaluation of biophysical skin parameters and assessment of hair growth in patients with acne treated with isotretinoin." *Postępy DermatolAlergol*, 2013; 30:343-349.
 31. Pappas A.: *Lipids and Skin Health*. Springer. 2014; 2:16-21.
 32. Tsukada M, Schröder M, Roos TC, Chandraratna RAS, Reichert U, Merk HF *et al.*: 13- cis Retinoic acid exerts its specific activity on human sebocytes through selective intracellular isomerization to all-trans retinoic acid and binding to retinoid acid receptors. *J Invest Dermatol* 2000;115:321–7
 33. Zouboulis CC, Korge B, Akamatsu H, Xia L, Schiller S, Gollnick H, *et al.*: Effects of 13-cis-retinoic acid, all-trans-retinoic acid and acitretin on the proliferation, lipid synthesis and keratin expression of cultured human sebocytes in vitro. *J Invest Dermatol*, 1991; 96:792-7.
 34. Krishna, C. M., Liebmann, J. E., Kaufman, D., DeGraff, W., Hahn, S. M., McMurry, T., *et al.*: The catecholic metal sequestering agent 1,2-dihydroxybenzene-3,5-disulfonate confers protection against oxidative cell damage. *Arch. Biochem. Biophys*, 1992; 294, 98–106.
 35. McArdle, F., Pattwell, D. M., Vasilaki, A., McArdle, A., and Jackson, M. J. Intracellular generation of reactive oxygen species by contracting skeletal muscle cells. *Free Rad. Biol. Med*, 2005; 39, 651–657.
 36. Kim JS, Cho EW, Chung HW. and Kim I.G.: Effects of tiron, 4,5-dihydroxy-1,3-benzene disulfonic acid, on human promyelotic HL-60 leukemia cell differentiation and death. *Toxicology* 2006; 223:36–45.
 37. Cantu D, Schaack J. and Patel M.: Oxidative inactivation of mitochondrial aconitase results in iron and H₂O₂-mediated neurotoxicity in rat primary mesencephalic cultures. *PLoS One*, 2009; 18:7095.
 38. Oyewole A.O, Wilmot M.C, Fowler M. and Machin M.A.B.: " Comparing the effects of mitochondrial targeted and localized antioxidants with cellular antioxidants in human skin cells exposed to UVA and hydrogen peroxide" *The FASEB Journal*, 2017; 28,1 :485-494.

التأثير الوقائي المحتمل لعقار التيرون على جلد ذكور الجرذان البيضاء البالغة المعرضة للإيزوتريتينوين بجرعات مختلفة

مها السيد سليمان، هالة محمد الحرون، مايسه كفاقي، دعاء مصطفى محمد

قسم الهستولوجيا وبيولوجيا الخلية - كلية الطب - جامعة المنوفية

يعتبر الإيزوتريتينوين من الأدوية الأكثر فعالية في علاج حب الشباب، فهو مشتق من حمض الريتينويك. استخدام الإيزوتريتينوين قد يحفز العديد من الآثار السلبية. التايرون له خصائص مضادة للأكسدة ويمكن أن يحسن تلف الجلد وموت الخلايا المبرمج.

الهدف من البحث: تقييم التأثير السلبي للجرعة العالية للإيزوتريتينوين مقابل الجرعة المنخفضة على جلد الفئران والتاثير الوقائي المحتمل للتيرون.

المواد والطرق: تم تقسيم ستين جرد من الذكور البيضاء البالغين إلى خمس مجموعات متساوية: المجموعة الأولى (الضابطة) تم حقنها يوميا في الغشاء البريتوني بمحلول ملح (0.9%)، والمجموعة الثانية تم اعطائها التيرون (300 ملجم/كجم بالفم)، والمجموعة الثالثة تم حقنها يوميا ايزوتريتينوين في الغشاء البريتوني (6 ملجم /كجم/يوم)، المجموعة الرابعة (3 ملجم ايزوتريتينوين / كجم / يوم)، والمجموعة الواقية الخامسة التي اعطيت الإيزوتريتينوين و التيرون وقسمت الفئران من المجموعة الأخيرة إلى مجموعتين فرعيتين متساويتين المجموعة الفرعية (أ و ب) تلقت ايزوتريتينوين بجرعة 6 ملجم و 3 ملجم/كجم/يوم على التوالي مع التايرون. و في نهاية التجربة تم تشريح الحيوانات وأخذت العينات لتحضيرها للدراسة النسيجية والمناعية.

النتائج: أظهرت الحيوانات المعالجة بالإيزوتريتينوين بجرعة 6 ملجم/كجم/يوم تكسير في خلايا النسيج الطلائي ونقصان في عدد طبقاته وظهرت طبقة الغشاء السفلى غير محددة. كما أظهرت الغدد الدهنية انخفاض ملحوظ في الحجم كما ظهرت الأنوية داكنة وصغيرة ومنكمشة وقد تأثر النسيج الضام بشكل بالغ فكانت ألياف الكولاجين غير منتظمة وزادت كثافة ترتيب الكولاجين التي ظهرت بوضوح في صبغة المألوري تراي كروم وكانت هذه التغيرات أقل وضوحاً مع الإيزوتريتينوين بجرعة أقل (3 ملجم / كجم / يوم). استخدام الإيزوتريتينوين والتايرون تسبب في تحسن ملحوظ ضد هذه التغيرات لا سيما في الجرعة المنخفضة.

الاستنتاج: : مما سبق يتضح أن التايرون يمكن استخدامه في الوقاية وكذلك علاج التلف الحادث في الجلد نتيجة التعرض للإيزوتريتينوين.