

Pachyonychia Congenita: A Case Report

Marwa A. Abo Elmagd, and Rasha I. Mohamed

Department of Dermatology, Venereology and Andrology, Faculty of Medicine,
Sohag University

Introduction

Pachyonychia congenita (PC) is a rare autosomal dominant disorder of keratinization.^[1] It was first documented by Muller in 1904^[2] followed by Jadassohn and Lewandowsky in 1906.^[3] It is classified into four types, of which the two important ones include type-1 (Jadassohn–Lewandowsky type) and type-2 (Jackson–Lawler type). These are characterized by subungual hyperkeratosis, focal palmoplantarkeratoderma, oral leukokeratosis, which are usually present since birth.^[4]

Case Report

An 7-year-old boy born of consanguineous parentage, with normal developmental milestones for his age except for natal teeth ; also presented with nail defects since birth along with numerous skin lesions. Family history was unremarkable. Cutaneous examination revealed dystrophic, discolored, and thickened toenails and one fingernail along with massive subungual hyperkeratosis producing a distal elevation of nail

plates and wedge-shaped deformity of the nails. This resulted in the upward growth of the distal edge of the nail plates^{[Figure 1],[Figure 2],[Figure 3]}. Besides, there were numerous, hyperkeratotic lesions over the entire body, concentrated over both knees, legs and flanks ^{[Figure 4],[Figure 5]}. Marked hyperhidrosis of the palms and soles was observed. Palmoplantarkeratoderma was present, along with painful ulcerated plaques^[Figure 6]. Routine laboratory investigations including complete hemogram, hepatic profile, and renal profile were within normal limits. KOH microscopy and culture of nail clippings was negative. Skin biopsy from a hyperkeratotic lesion from the leg, showed orthokeratosis and acanthosis^[Figure 7]. No evidence of any malignancy was found during the thorough work up. Genetic and molecular biological studies could not be carried out due to lack of infrastructure facilities. Based on the above findings, he was diagnosed as pachonychia congenita type II.

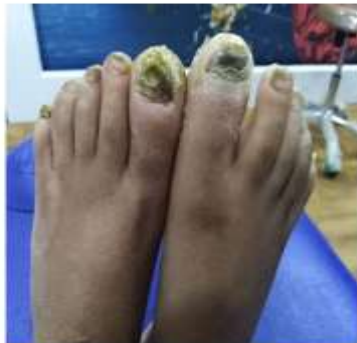

Figure 1
Dystrophic toe nails with subungual hyperkeratosis

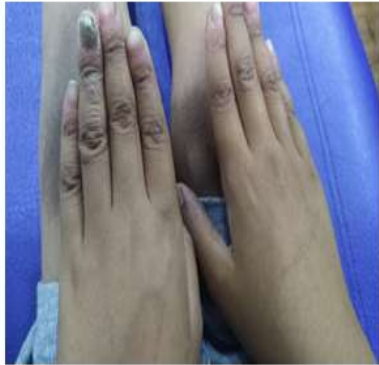

Figure 2 Dystrophic finger nail with wedge-shaped deformity

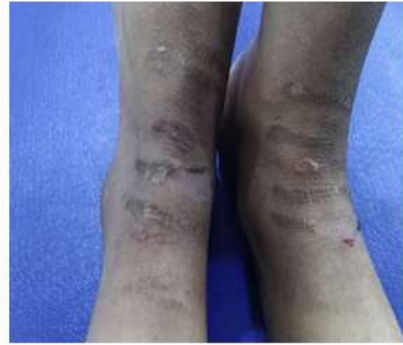

Figure 5 hyperkeratotic plaque

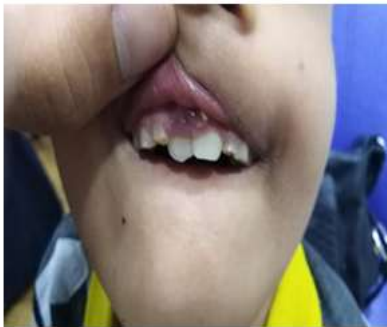

Figure 3 Natal teeth

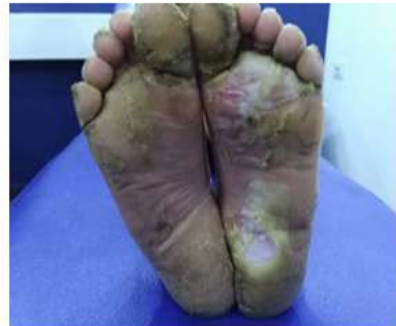

Figure 6 plantar keratoderma

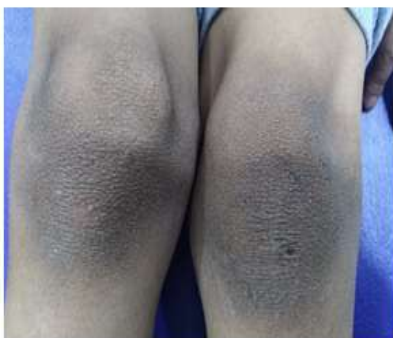

Figure 4 Follicular hyperkeratosis of knees

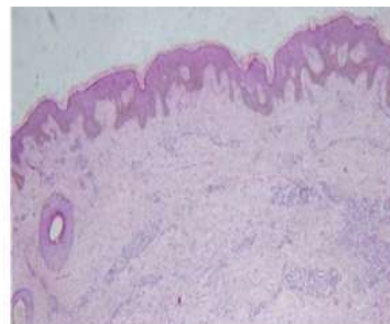


Figure 7 showing orthokeratosis and acanthosis (H and E, $\times 10$)

Discussion

Pachyonychia congenita (PC) is a rare, but well characterized autosomal dominant disorder of keratinization characterized by a triad of sub-ungual hyperkeratosis with accumulation of hard keratinous material beneath the distal portion of the nails, lifting the nails from the nail bed, keratosis palmaris et plantaris with thick callosities, especially on the soles and thick white areas on the oral mucosa [5]. According to these mutations, various clinical variants have been described.

PC type I (Jadassohn-Lewandowsky, PC-I) consists of palmoplantar hyperkeratosis, follicular hyperkeratosis, and oral leukokeratosis. Occasionally, bullous lesions, hoarse voice due to laryngeal involvement, warty lesions on knee and elbow, and hyperhidrosis may occur.

In PC type II (Jackson-Lawler, PC-II) the palmoplantar keratoderma and oral changes are of less importance or may be absent. In addition, history of natal teeth and the development of epidermal cysts or steatocysts are remarkable [6].

PC type III (Schafer-Brunauer, PC-III) includes combined features of types 1 and 2 with angular cheilitis, corneal dyskeratosis, and cataracts. Type IV includes features of type 1 and type 3 with laryngeal lesions, hoarseness of voice with mental retardation, hair

abnormalities and alopecia. Rare variants include

pachyonychia congenita tarda, characterized by isolated nail changes that usually begin in the second and third decades of life [7]. These different presentations are currently known to be due to mutations in variable genes encoding one of the paired epidermis keratins, K6a/K16 in PC-I and K6b/K17 in PC-II [8]. Complications like respiratory distress due to laryngeal leukokeratosis and acroosteolysis, malignant changes in palmoplantar lesions can occur in pachyonychia congenita [9]. In milder forms of pachyonychia congenita, local emollients and keratolytics have been used with considerable improvement. Oral retinoids have been demonstrated to improve the hyperkeratotic skin lesions. Retinoids given for long periods produce a reasonable degree of flattening of the nails [10]. The only effective treatment for nail lesions is surgery with radical excision of the nail, nail bed and nail matrix and skin implantation at the site of improved nail. Surgical treatment is also important in case of oral lesions with hoarseness or respiratory problems. When the familial mutation is known, genetic counseling can be done and if required, prenatal diagnosis can be done at early stage of pregnancy by chorionic villi biopsy [11].

References

1. Strober BE. Pachyonychia congenita: type II. *Dermatol Online J* 2003;9:1.
2. Muller C. On the causes of congenit onychogryphosis. *Mcn Med Woher* 1904;49:2180-2.
3. Jadassohn J, Lewandowsky F. *Jacoli Konographia Dermatologica*. 1st ed. Berlin: Urban und Schwarzenberg. Pachyonychia congenita. Keratosis disseminata circumscripta (follicular

Tylomata. Leukokeratosis linguae; 1 p. 29-31. †

4. Agarwal P, Chhaperwal MK, Sin A, Verma A, Nijhawan M, Singh al. Pachyonychia congenita: A rare genodermatosis. *Indian Dermatol Online J* 2013;4:225-7. †

[PUBMED]  Full Text .

5. Johnson BL Jr, Yan AC. Congenital diseases (Geno-

- dermatosis). In: Elder DE (Lever's Histopathology of the Skin, 10th ed Philadelphia, Lippincott Williams & Wilkins, 2009: P 138
6. Su WP, Chun SI, Hammond Gordon H. Pachyonychia congenita: A clinical study of 12 cases and a review of the literature. *Pediatr Dermatol* 1990; 7: 33-38. PMID: 2140447
7. Bansal A, Sethuraman G, Shrivastava VK. Pachyonychia congenita with only nail involvement. *J Dermatol* 2006; 33: 437-438. PMID: 167008
8. Munro I. Pachyonychia congenita: Multiple and unusual clinical presentations. *Br J Dermatol* 2001; 144: 929-930. PMID: 11359376
9. Murugesu SB, Reddy Ragunatha S, et al. Acro-osteolysis: a complication of Jadasohn-Lewandowsky syndrome. *Int J Dermatol* 2007; 46: 202-205. PMID: 17269978
10. Lim TW, Paik JH, Kim N. A case of pachyonychia congenita with oral leukoplakia and steatocystoma multiplex. *J Dermatol* 1999; 26: 677-681. PMID: 10554435
11. Smith FJ, McKusick VA, Nikolic M et al., Cloning of multiple keratin 16 genes facilitates prenatal diagnosis of pachyonychia congenita. *Prenat Diagn* 1999; 19: 941-946. PMID: 105211