

Standard versus Accelerated Collagen Cross-Linking in Treatment of Keratoconus: Visual, Refractive, and Topographic Outcomes

Ibrahim M. Amer* and Asaad Nooreldin

Department of Ophthalmology, Faculty of Medicine, Al-Azhar University, Assuit, Egypt

*Corresponding author: Ibrahim M. Amer, E-Mail: amer_eye_80yahoo, Mobile: (+2)01011168920

ABSTRACT

Background: collagen cross-linking (CXL) is an effective, safe and rapidly progressive treatment modality for treatment of mild to moderate keratoconus not only in hindering the progression of the disease but also in improving the visual, refractive and topographic results. **Objective:** the study aims to compare the outcomes of standard and accelerated cross-linking in treatment of keratoconus. **Patients and Methods:** the present prospective study evaluated 99 eyes of 52 patients with keratoconus. They were classified into two groups; group (1) included 50 eyes (received standard CXL; 3Mw/cm², 30 min) (SCXL group) and group (2) 49 eyes (treated by accelerated CXL; 9Mw/cm², 10 min) (ACXL group). Spherical equivalent, uncorrected visual acuity, best-corrected visual acuity, and topographical analysis of the cornea were assessed at baseline and within 3 years postoperative. Simulated keratometry was measured in terms of Sim K-1, Sim K-2, K-max, cylindrical value, thickness of the cornea (at the thinnest point) and Q-value were evaluated. **Results:** postoperative uncorrected distance visual acuity and corrected distance visual acuity didn't significantly changed in both groups. Postoperative spherical equivalent significantly decreased in standard CXL compared to accelerated CXL. Standard CXL had a greater effect in decreasing Simk-1, Simk-2, k-max and k-mean. K-max decreased from 52.33±5.55 to 50.35±5.14; P=0.07 and in accelerated group from 54.58±4.35 to 52.74±4.41; P=0.04. Also, postoperative corneal pachymetry (at thinnest location) was found to be more stable in standard CLX group. **Conclusion:** both standard and accelerated CXL are effective in early keratoconus management with better results in standard CXL procedure.

Keywords: Standard, Accelerated, Collagen Cross-Linking, keratoconus.

INTRODUCTION

Keratoconus (KC) is the dystrophy of the cornea characterized by thinning of the corneal stroma accompanied by secondary ectasia⁽¹⁾. Consequently, this could lead to abnormal astigmatism and myopia and is strongly related to gradual impairment of vision⁽²⁻⁴⁾. KC is one of the commonest corneal disorders that affect about 3/1000 person of all races⁽⁵⁾ and it is frequently widespread among adolescents and has usually variable presentation⁽⁶⁾. This disorder is usually progressive for nearly 2 decades⁽⁷⁻⁹⁾. Later on, what happens to keratoconus patients remains unknown⁽¹⁰⁾. Keratoconus pathogenesis is multifactorial, these include environmental and genetic causes and atopy^(11,12). The main risk factors of KC include eye rubbing, ultraviolet rays and contact lens usage for a long period⁽¹³⁻¹⁵⁾. The management of keratoconus depends on the its severity; in mild cases, glasses or soft contact lenses may be sufficient however, in severe cases rigid and scleral lenses are required. Furthermore, keratoplasty is confined for severe and advanced cases with impaired vision who could not use contact lenses^(2,16-18).

Corneal collagen cross-linking (CXL) was first described by Wollensak *et al.*⁽¹⁹⁾ using an ultraviolet-A protocol with an intensity of 3 mW/cm² at 370 nm for 30 minutes (Dresden protocol), here, the UVA photochemical interaction and riboflavin (vitamin B2) induces cross-linking between the macromolecules of the corneal stroma. Many studies have demonstrated that the absorption coefficient of UVA is linearly correlated with riboflavin concentrations (from 0:0.5%), this reflects that the clinical outcomes may be

affected by riboflavin concentrations⁽²⁰⁻²²⁾. Many studies proved that CXL is effective and safe in avoidance of the progression of keratoconus and improving topographic and visual variables⁽²³⁻²⁶⁾. Standard CXL (SCXL) protocol has a major drawback which is the prolonged irradiation duration with a total treatment duration of > 60 minutes, this pushed the researchers to develop accelerated CXL (ACXL) protocols to be more suitable and comfortable for patients. ACXL protocols aim to lower the time of UVA exposure through increasing the fluency of it to ensure the same total dosage. In accordance with Bunsen and Roscoe rule, the photochemical reaction is correlated frankly with the total energy dose regardless of the duration of the dose⁽²⁷⁾. Nowadays, the ACXL protocols can be done in a shorter duration such as 3, 5 or 10 min using different energy doses, this short duration of exposure might decrease the adverse effects on the cornea such as corneal haze, thinning, and infection, but on the other hand, this might affect CXL efficacy⁽²⁸⁾.

AIM OF THE STUDY

This study aims to compare between the clinical results outcomes of standard and accelerated cross-linking in management of keratoconus and to follow-up the patients up to 3 years.

PATIENTS AND METHODS

This is a single-center prospective (follow-up) study. It was conducted in a private center (Modern Eye Center) in Assiut city, in Upper Egypt; during the period from January 2016 to January 2019. The study

included a total of 99 eyes of 52 keratoconic patients, they were classified to two groups; group (1) included 50 eyes underwent standard CXL (3 Mw/cm², 30 min) and group (2) included 49 eyes underwent accelerated CXL (9 mW/cm², 10 min). Most of keratoconic eyes were discovered during pre-Lasik evaluation and diagnosed by topographic appearance of the map. We exclude patients with corneal thickness < 400 μm, corneal scars, any ophthalmic infection or inflammation and patients with previous herpetic keratitis. Two complications were reported and excluded from the study, one with early progression in accelerated CXL group and another one developed autoimmune keratitis in standard CXL group.

Ethical and approval considerations:

The study protocol was approved by The Local Ethical Committee of Faculty of Medicine, Al-Azhar University, Assiut, Egypt. Written informed consent was obtained from each patient.

Methods:

Complete ophthalmological examinations were done for all the included patients. These examinations included spheric equivalent (SE), both uncorrected and best-corrected visual acuity (UCVA & BCVA), examination of slit-lamp, intraocular pressure (IOP) evaluation and fundoscopic examination. In addition, the corneal topographic analysis was done including measuring simulated keratometry (Sim K-1, Sim K-2, K-max, cylindrical "CYL" value, and thickness of the cornea (at the thinnest location, thCT) by using Alcon Wave Light AllergoOculus, Wave Light, Germany, at baseline and within 3 years postoperative. Also, Q-value was evaluated. Snellen chart was used for measuring visual acuity, then values were transformed to Logarithm of the Minimum Angle of Resolution (logMAR) to be suitable for statistical analysis.

Technique:

All used procedures were carried out under sterilized conditions, topical anesthesia by eye drops of proxymetacaine HCL 0.5% (Alcaine, Alcon Laboratories Inc) was used. In both types of CXLs, 20% alcohol solution was used for 20 seconds for releasing the corneal epithelium then, a Paton hook was used for the mechanical removing of the epithelium at an intended 8.5 mm zone. Riboflavin eye drop (Peschke D Peschke Trade GmbH, Huenenberg, Switzerland) was applied every 3 minutes lasting for a period of 30 minutes and to make the cornea stained yellow and had swollen to more than 400 μm. The used UVA irradiation system was VEGA CBM X-Linker, CSO Italia, Italy.

Before the treatment with UVA irradiation and by using a UVA meter, we calibrated the intended 3 mW/cm² surface irradiance "5.4 J/cm² for 30 min" in the standard CXL procedure while, in accelerated CXL procedure 9 mW/cm² irradiance was calibrated and applied for 10 min (5.4 J/cm² for 10 min). The riboflavin solution was applied every 2 min and the cornea was moisturized by a balanced salt solution every 1 minute. Before finishing the surgery, a contact lens of silicone hydrogel bandage was applied until complete corneal reepithelization. Postoperatively, eye drops of Gatifloxacin q.i.d. were used for 7 days, fluorometholone eye drops q.i.d. for 30 days and artificial tears q.i.d. was applied for 6 months.

Statistical analysis

Data were statistically analyzed using SPSS program version 21. Quantitative data were expressed as mean ± standard deviations and ranges, while qualitative data were expressed in the form of frequency (%). Paired t-test was used to compare between the two CXL procedures in continues data while, Chi-square (χ²) test was used for qualitative data. A probability value of less than 0.05 was considered significant however, that of more than 0.05 was considered as nonsignificant.

RESULTS

Table (1): Demographic distribution of the studied groups

Variables	Group (1) N=50		Group (2) N=49		Test of significance	
	No.	%	No.	%	χ ²	P-value
Gender						
● Males	21	42.0	17	34.7	0.29	0.588*
● Females	29	58.0	32	65.3		
Age (years)						
	Mean ± SD		Mean ± SD		t-test	p-value
● Range	14–46		9–37		---	---
● Mean± SD	24.26±8.56		24.65±7.49		0.05 18	0.384*

χ²=Chi square, t=paired t-test, *: P>0.05=insignificant, SD=standard deviation

This study contains 52 patients with keratoconus classified into two groups according to the method of cross-linking used: group (1) contained 26 patients treated by standard method of CXL, they were 11 males and 15 females and group (2) accelerated method contained 26 treated by method of CXL, they were 9 males and 17 females. The ages of group (1) ranged from 14 to 46 years (mean± SD= 24.26±8 56 years), while ages of group (2) ranged from 9 to 37 years (mean± SD= 24.65±7.49 years). The demographic distribution of both age and sex (Table 1) showed that there are matched in the two groups, there are no statistically significant differences.

Table (2): Refractive and visual parameters pre- and postoperative in both groups at end of follow-up

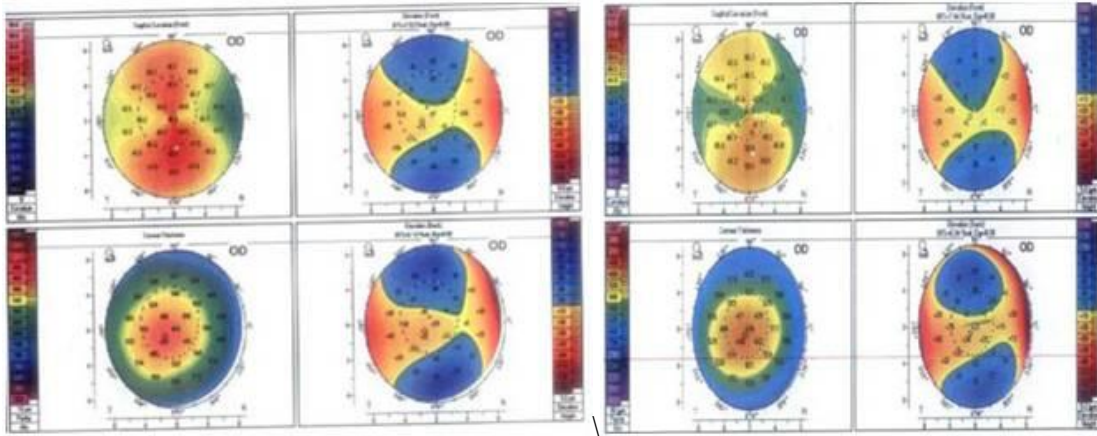
	Variables	STANDERED CXL		ACCELERATED CXL		P-value
		Range	Mean± SD	Range	Mean± SD	
Sphere	Preoperative	-14 - 2.75	-3.43±3.77	-20 - 3.25	-4.89±4.93	0.100
	Postoperative	-15 - 2.75	-3.45±3.97	-20 - 3.25	-5.12±5.12	0.071
	P-value	---	0.979	---	0.821	---
Cylinder	Preoperative	-8.5 - 2	-3.5±2.37	-9.25 - 3	-3.57±2.48	0.884
	Postoperative	-8.5 - 2.75	-3.57±2.42	-9.75 - 3	-3.6±2.75	0.959
	P-value	---	0.884	---	0.954	---
Spherical equivalent (SE)	Preoperative	-15 - 17	-3.12±5.23	-18.5 - 6.5	-4.51±4.33	0.178
	Postoperative	-19 - 9.25	-3.7±5.06	-18.5 - 6.5	-5.07±4.45	0.158
	P-value	---	0.574	---	0.529	---
Uncorrected distant visual acuity (UDVA)	Preoperative	0.01 - 1	0.23±0.26	0.05 - 1	0.24±0.21	0.833
	Postoperative	0.01 - 1	0.25±0.26	0.01 - 1	0.23±0.2	0.616
	P-value	---	0.701	---	0.809	---
Corrected distant visual acuity (CDVA)	Preoperative	0.01 - 1	0.53±0.26	0.02 - 1.2	0.54±0.28	0.813
	Postoperative	0.02 - 1	0.55±0.26	0.01 - 1.2	0.52±0.29	0.588
	P-value	---	0.701	---	0.729	---

All refractive and visual parameters (pre- and postoperative) in standard CXL and accelerated CXL are statistically insignificant. Also, all refractive and visual parameters (pre- and postoperative) in accelerated CXL are statistically insignificant except decrease in postoperative of sphere and SE in postoperative accelerated CXL group, P-value=0.027 and 0.047 respectively (Table 2).

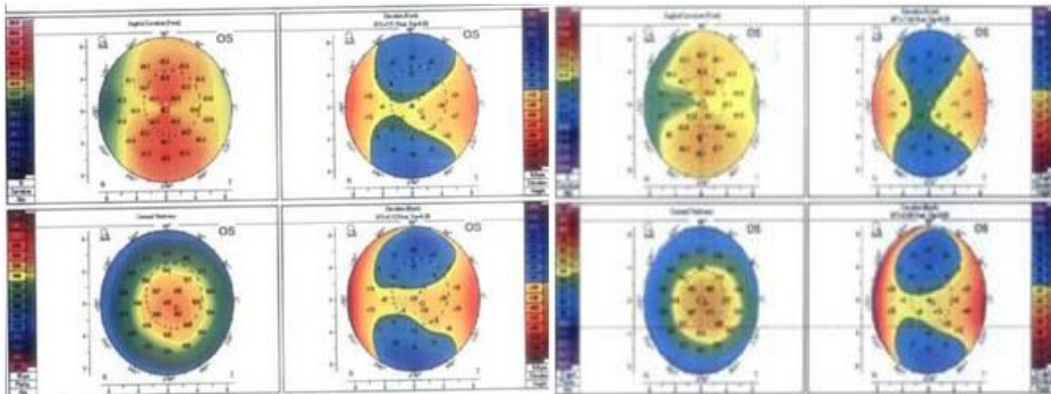
Table (3): Topographic parameters pre- and postoperative in both groups at end of follow-up

Variables	STANDERED CXL		ACCELERATED CXL		P-value
	Range	Mean± SD	Range	Mean± SD	
Keratometry in diopters (K1 D)					
Preoperative	40.5 - 51.9	45.24±2.65	40.2 - 77.8	46.64±6.08	0.143
Postoperative	38.1 - 52.1	44.75±2.95	40.2 - 434	62.66±76.91	0.103
P-value	---	0.384	---	0.153	---
Keratometry in diopters (K2 D)					
Preoperative	40.6 - 59.4	47.66±7.75	43.1 - 832	74.07±126.15	0.150
Postoperative	40.1 - 58	47.14±7.74	43.1 - 832	74.27±126.12	0.139
P- value	---	0.734	---	0.869	---
Maximum keratometry (K Max D)					
Preoperative	44.2 - 60.4	52.33±5.55	44.1 - 59.3	54.58±4.35	0.02*
Postoperative	42.6 - 59.6	50.35±5.14	44.1 - 57.3	52.74±4.41	0.017*
P- value	---	0.067	---	0.04	---
Average keratometry (K Avg D)					
Preoperative	41.6 - 55.4	46.95±2.97	41.7 - 56.4	47.45±6.28	0.612
Postoperative	39.5 - 54.9	46.53±3.21	41.7 - 56.4	47.66±6.37	0.26
P-value	---	0.498	---	0.869	---
Pachymetry (At Thinnest Location)					
Preoperative	401 - 577	452.64±47.4	405 - 566	457.31±45.19	0.617
Postoperative	396 - 577	439.38±51.15	380 - 539	440.61±45.9	0.9
P-value	---	0.181	---	0.07	---
Q value (6mm)					
Preoperative	-1.46 - 1.52	0.59±0.54	-0.8 - 10.3	0.86±1.49	0.242
Postoperative	-1.46 - 1.59	0.57±0.54	-0.46 - 10.3	0.92±1.46	0.115
P-value	---	0.853	---	0.84	---

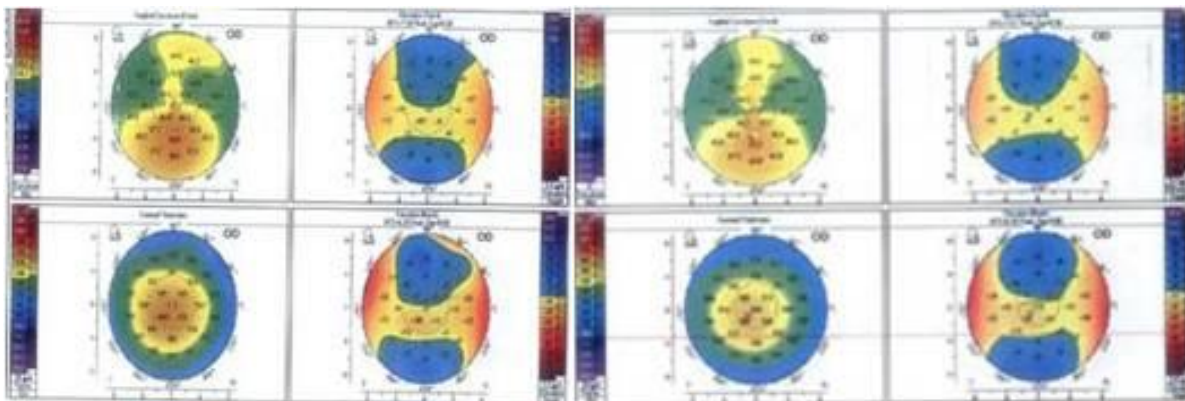
*: statistically significant. All topographic parameters (pre- and postoperative) in standard CXL and accelerated CXL are statistically insignificant except increase in postoperative K max (D), P-value=0.02 and 0.017 respectively. Also, all topographic parameters (pre- and postoperative) in standard CXL are statistically insignificant except decrease of K max (D) in postoperative standard CXL group, P-value=0.004 (Table 3).



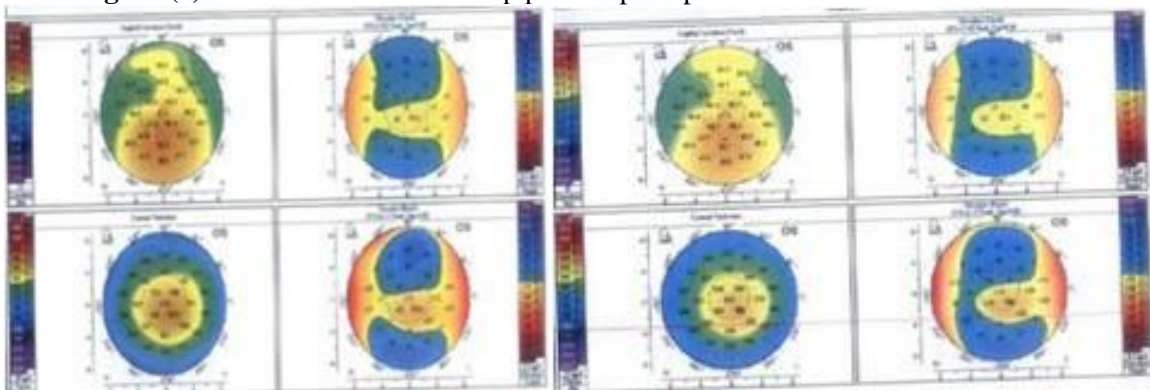
(A) Preoperative (B) Postoperative (8 months)
Figure (1): Pentacam difference map pre and postoperative underwent standard CXL.



(A) Preoperative (B) Postoperative (18 months)
Figure (2): Pentacam difference map pre and postoperative underwent standard CXL.



(A) Preoperative (B) Postoperative (10 months)
Figure (3): Pentacam difference map pre and postoperative underwent standard CXL



(A) Preoperative (B) Postoperative (10 months)

Figure (4): Pentacam difference map pre and postoperative underwent standard CXL

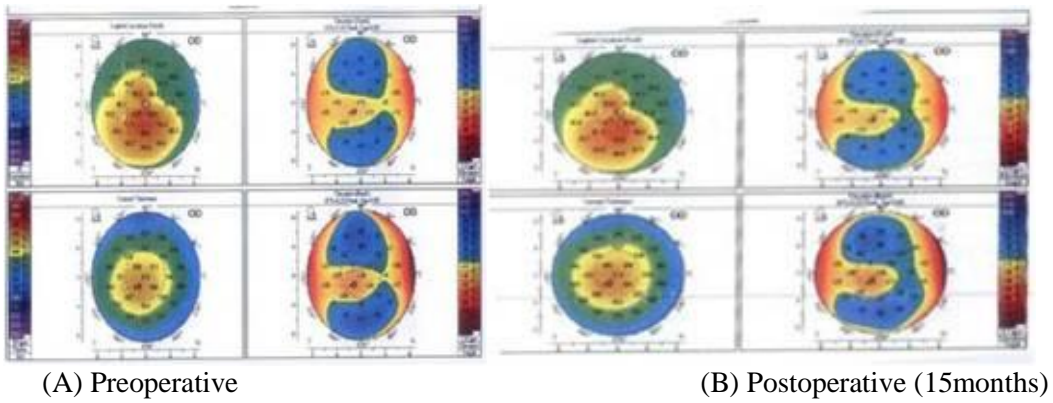


Figure (5): Pentacam difference map pre and postoperative underwent standard CXL.

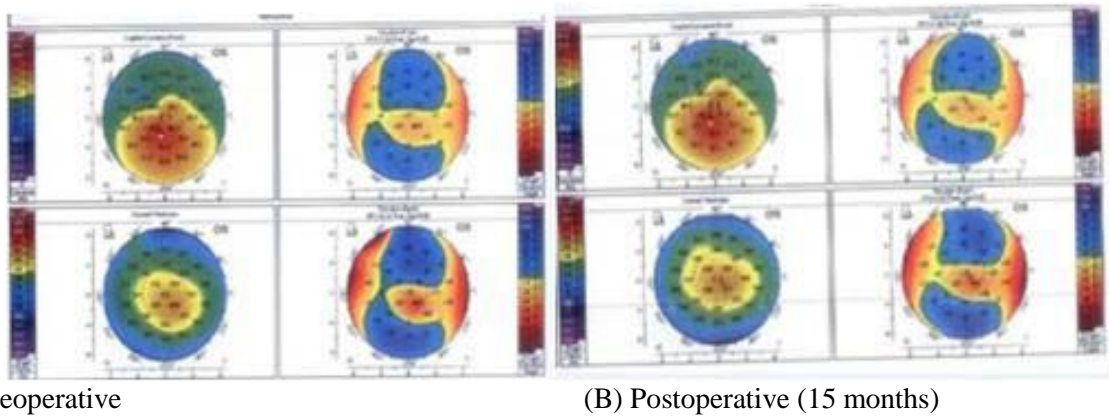


Figure (6): Pentacam difference map pre and postoperative underwent standard CXL.

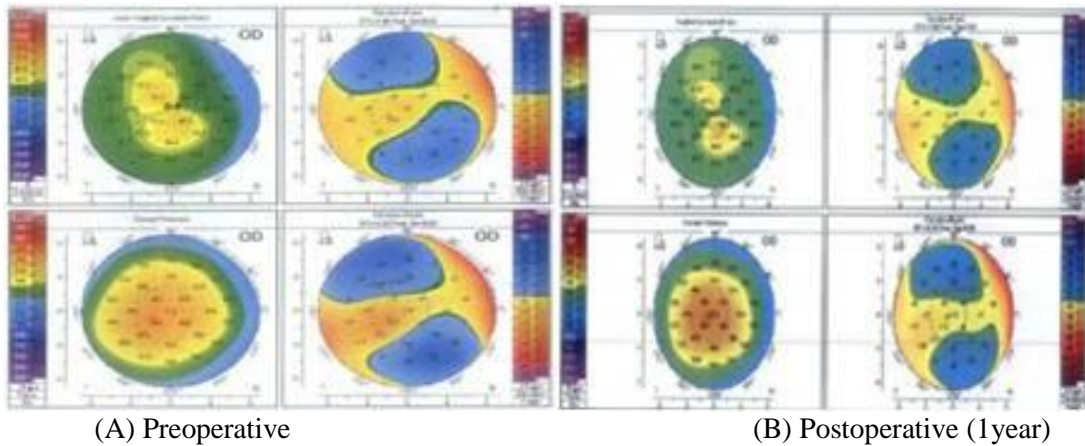


Figure (7): Pentacam difference map pre and postoperative underwent accelerated CXL.

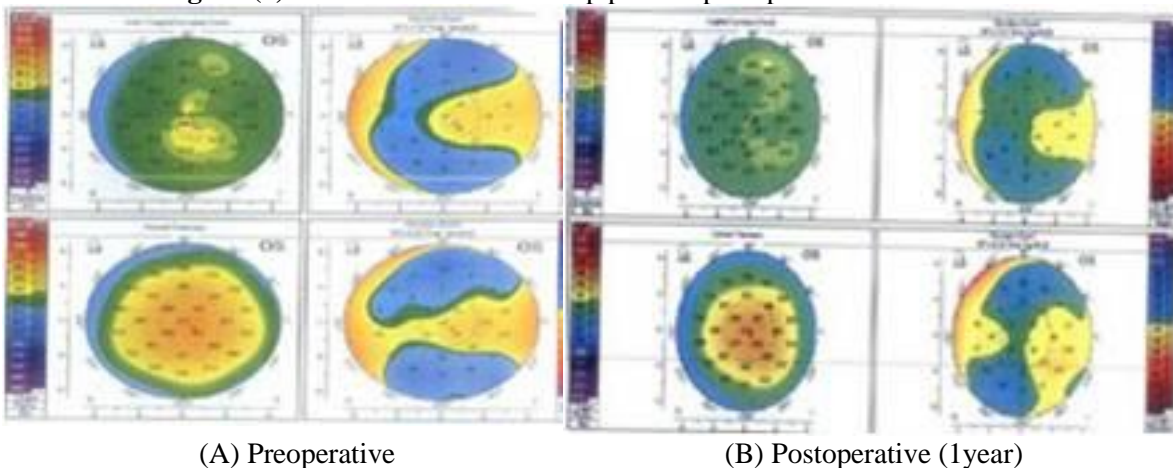
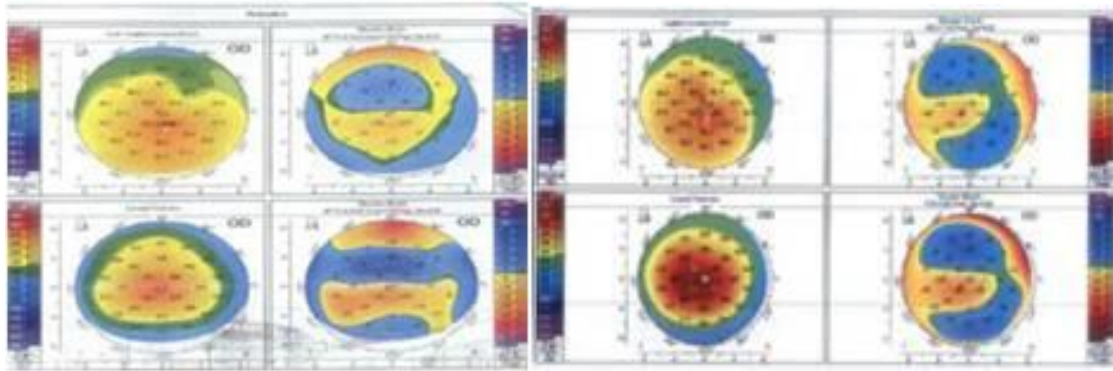


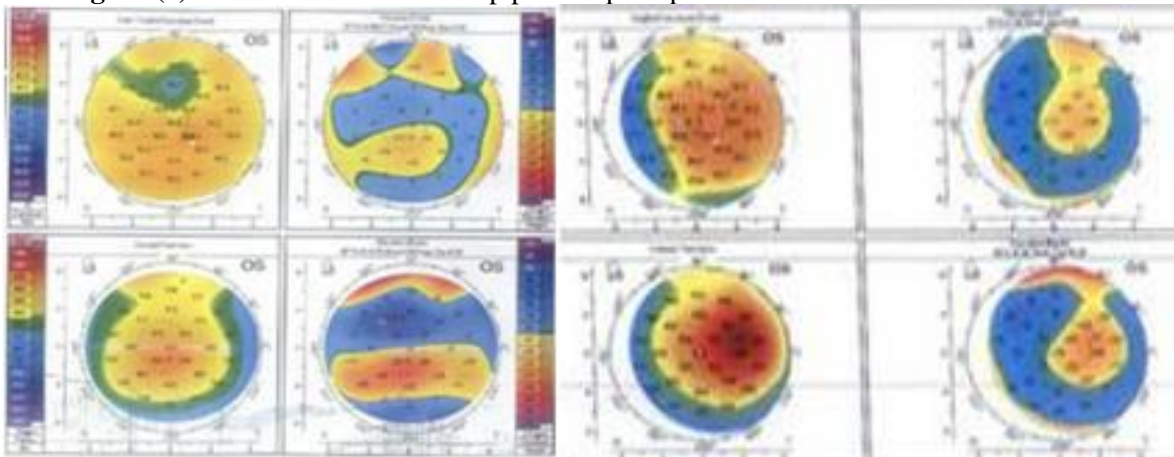
Figure (8): Pentacam difference map pre and postoperative underwent accelerated CXL.



(A) Preoperative

(B) Postoperative (1 year)

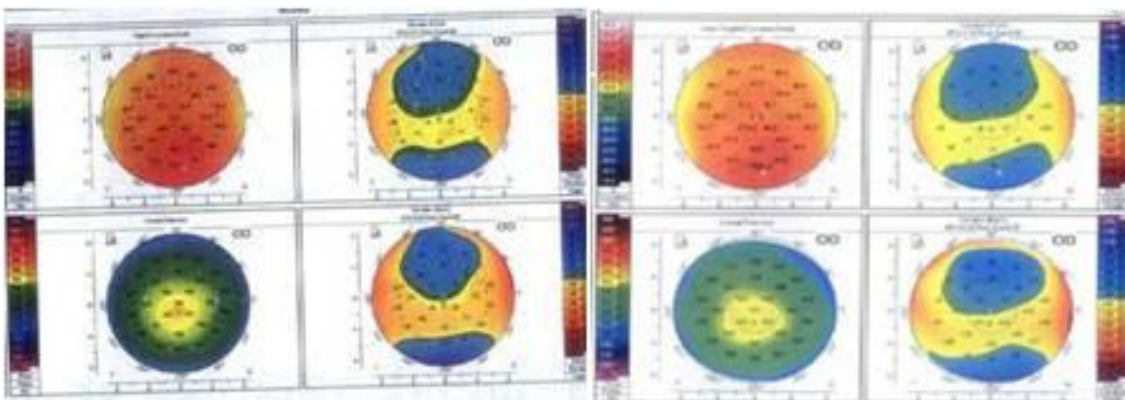
Figure (9): Pentacam difference map pre and postoperative underwent accelerated CXL.



(A) Preoperative

(B) Postoperative (1 year)

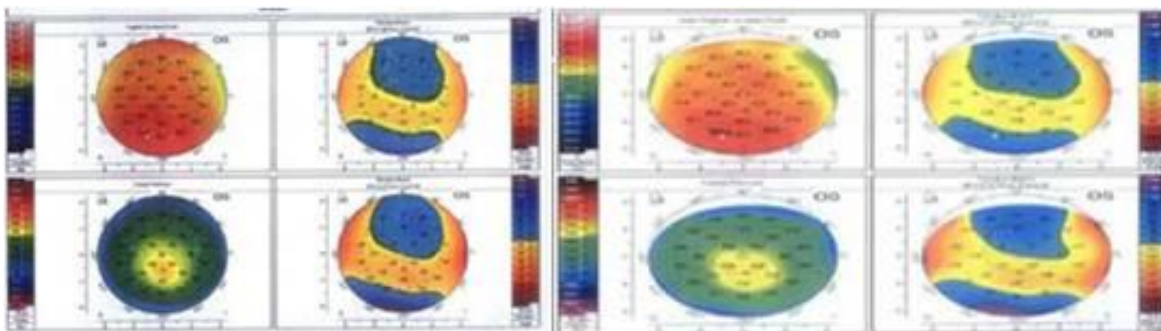
Figure (10): Pentacam difference map pre and postoperative underwent accelerated CXL.



(A) Preoperative

(B) Postoperative (1 year)

Figure (11): Pentacam difference map pre and postoperative underwent accelerated CXL.



(A) Preoperative

(B) Postoperative (36 month)

Figure (12): Pentacam difference map pre and postoperative underwent accelerated CXL.

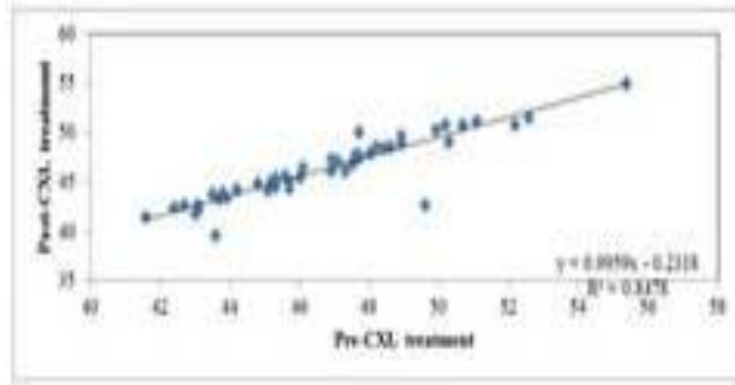


Figure (13): Correlation coefficient (r) between pre- and post-treatment in patients treated with accelerated cross linking; group (1) as regard keratometry (K_{avg}).

The figure shows that there is a positive significant correlation ($r=0.9207$, $P < 0.001$).

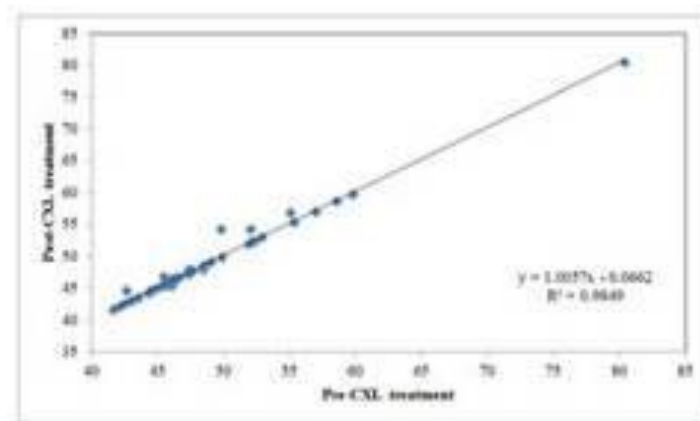


Figure (14): Correlation coefficient (r) between pre- and post-treatment in patients treated with conventional cross linking; group (2) as regard keratometry (K_{avg}).

The figure shows that there is a positive significant correlation ($r=0.9924$, $P < 0.001$).

DISCUSSION

Collagen cross-linking is well-established management modality for keratoconus and ectatic corneal disorders with proven efficacy for preventing the advancement of keratoconus (29-31).

In the current study we compared the efficacy of two protocols of CXL in management of keratoconus; standard CXL 3mW/cm for 30 min and accelerated CXL 9 mW/cm for 10 min. Many studies e.g. **Sherif**(32) and **Toker et al.**(33) studies reported similar findings regarding visual acuity and both refractive and topographic outcomes. On the contrary, in a study done by **Brittingham et al.**(34) have showed the effect of ACXL to be restricted. In the present study the two procedures had very good effect in disease stability with good compliance in accelerated procedure and slightly better results in standard procedure.

In the present study, there is no significant difference between UCDVA and CDVA in the two groups; the only difference was improvement in the baseline postoperative UCDVA from 0.05 to 0.01 and in CDVA from 0.01 to 0.02 in accelerated group other with pre- and postoperative UCDVA and CDVA nearly similar on both groups (Table 2). It's a great success; VA is an important index and dependable

factor in keratoconus patients together with topographic changes.

In the current study, SE was stable in standard cross-linking -3.12 ± 5.23 to -3.7 ± 5.06 ; P -value=0.574, while decrease in accelerated cross-linking group from -4.51 ± 4.33 to -5.07 ± 4.45 ; P -value=0.529 (Table 2).

One of successful indicator of the present study topographic changes there are obvious flattening in the postoperative topography in the most of the cases in both groups and more in standard group K_{max} 52.33 ± 5.55 to 50.35 ± 5.14 ; P -value=0.067 nearly two diopter and to lesser extent in accelerated group 54.58 ± 4.35 to 52.74 ± 4.41 ; P -value=0.04 and nearly one and half diopter (Table 3).

In a recent study by **Sherif**(32), he compared an accelerated CXL protocol of 30 mW/cm for 4 min with the standard one. He found that the reduction in K_{max} was 1.096 0.85D, and 0.846 0.54D in ACXL and SCXL, respectively with no significant difference between both procedures. Also, he found that central corneal thickness (CCT) was significantly decreased postoperatively (at 12 months) in both procedures with insignificant difference between them. In addition, CDVA improved significantly postoperatively in both procedures. These findings are in agreement with ours,

but more flattening in the present study may be due to longer period of study.

In another study done by **Toker *et al.***⁽³³⁾, they found that visual acuity (both UDVA & CDVA), SE, and CCT did not change significantly postoperatively (at 12 months) in both SCXL and ACXL groups. They added that both K mean and K-max was decreased to a lesser extent in the ACXL group compared to the SCXL group (but, this reduction was significant in both CXLs, $P < 0.01$).

In the current study, this occurred in early follow-up but most cases with late follow-up (after 20 months) both refractive and topographic parameters became more stable. Some cases showed marked flattening (figures 1,2,7,8). On the other hand, **Konstantopoulos and Mehta**⁽²⁹⁾ found that both ACXL protocols (9 mW/cm for 10 min and of 7 mW/cm for 15 min) may have the same efficacy of standard CXL. **Bunsen and Roscoe** rule revealed that both SCXL and ACXL efficacy should be comparable. However, CXL process is a biological change beside to it is a photochemical reaction⁽²⁷⁾.

Shetty *et al.*⁽³⁵⁾ observed a lesser reduction in both CCT and thCT in ACXL group compared to SCXL one. Nevertheless, in present study pachymetry (At Thinnest Location) more stable in standard CXL (from 452.64 ± 47.4 to 439.38 ± 51.15) with P -value = 0.181 than accelerated CXL from 457.31 ± 45.19 to 440.61 ± 45.9 with P -value = 0.07 we also observed that there are early decrease in pachymetry (At Thinnest Location) but in cases with late follow-up pachymetry very stable.

Study advantages and limitation:

There are many advantages in our study; long duration of study follow-up (3 years) and most of the cases were discovered accidentally during pre LASIK evaluation with high visual expectation that reflected on the patient compliance. On the contrary, the major study limitation is that the postoperative follow up was not at fixed intervals within the three years.

CONCLUSION

The results of this study revealed that the efficacy of both procedures were comparable in keratoconus patients. Stabilization of parameters with slight regression was more obvious in standard CXL than accelerated CXL.

REFERENCES

- Guber I, McAlinden C, Majo F, Bergin C (2017):** Identifying more reliable parameters for the detection of change during the follow-up of mild to moderate keratoconus patients. *Eye Vis. (Lond)*, 4:24-28.
- Rabinowitz YS (1998):** Keratoconus. *Surv Ophthalmol.*, 42: 297-319.
- Krachmer JH, Feder RS, Belin MW (1984):** Keratoconus and related noninflammatory corneal thinning disorders. *Surv Ophthalmol.*, 28:293-322.
- McAlinden C, Khadka J, de Freitas Santos Paranhos J, Schor P, Pesudovs K (2012):** Psychometric properties of the NEI-RQL-42 questionnaire in keratoconus. *Invest Ophthalmol Vis Sci.*, 53:7370-7374.
- Godefrooij DA, de Wit GA, Uiterwaal CS, Imhof SM, Wisse RP (2017):** Age-specific Incidence and prevalence of keratoconus: a nationwide registration study. *Am J Ophthalmol.*, 175: 169-172.
- Bron AJ, Rabinowitz YS (1996):** Corneal dystrophies and keratoconus. *Curr Opin Ophthalmol.*, 7:71-82.
- Wilson SE, Klyce SD (1994):** Screening for corneal topographic abnormalities before refractive surgery. *Ophthalmology*, 101:147-152.
- Binder PS, Lindstrom RL, Stulting RD *et al.* (2005):** Keratoconus and corneal ectasia after LASIK. *J Cataract Refract Surg.*, 31: 2035-2038.
- Randleman JB, Woodward M, Lynn MJ, Stulting RD (2008):** Risk assessment for ectasia after corneal refractive surgery. *Ophthalmology*, 115:37-50.
- Rahman W, Anwar S (2006):** An unusual case of keratoconus. *J Pediatr Ophthalmol Strabismus*, 43:373-375.
- Li X, Rabinowitz YS, Rasheed K, Yang H (2004):** Longitudinal study of the normal eyes in unilateral keratoconus patients. *Ophthalmology*, 111:440-446.
- McMonnies CW (2013):** Quo vadis older keratoconus patients: do they die at younger ages? *Cornea*, 32:496-502.
- Mas Tur V, MacGregor C, Jayaswal R, O'Brart D, Maycock N (2017):** A review of keratoconus: diagnosis, pathophysiology, and genetics. *Surv Ophthalmol.*, 62:770-783.
- Nielsen K, Hjortdal J, Pihlmann M, Corydon TJ (2013):** Update on the keratoconus genetics. *Acta Ophthalmol.*, 91:106-113.
- Wilson SE, Chaurasia SS, Medeiros FW (2007):** Apoptosis in the initiation, modulation and termination of the corneal wound healing response. *Exp Eye Res.*, 85:305-311.
- McMonnies CW (2007):** Abnormal rubbing and keratectasia. *Eye Contact Lens*, 33:265-271.
- Ubels JL, Schotanus MP, Bardolph SL *et al.* (2010):** Inhibition of UV-B induced apoptosis in corneal epithelial cells by potassium channel modulators. *Exp Eye Res.*, 90:216-222.
- Romero-Jimenez M, Santodomingo-Rubido J, Wolffsohn JS (2010):** Keratoconus: a review [quiz in *Cont Lens Anterior Eye*. 2010; 33:205]. *Cont Lens Anterior Eye*, 33:157-166.
- Kok YO, Tan GF, Loon SC (2012):** Review: keratoconus in Asia. *Cornea*, 31:581-593.
- Mandathara PS, Stapleton FJ, Willcox MDP (2017):** Outcome of keratoconus management: review of the past 20 years' contemporary treatment modalities. *Eye Contact Lens*, 43:141-154.
- Wollensak G, Spoerl E, Seiler T (2003):** Riboflavin/ultraviolet-a- induced collagen cross linking for the treatment of keratoconus. *Am J Ophthalmol.*, 135:620-627.
- Spoerl E, Mrochen M, Sliney D, Trokel S, Seiler T (2007):** Safety of UVA-riboflavin cross-linking of the cornea. *Cornea*, 26: 385-389.
- Wollensak G, Aurich H, Wirbelauer C, Sel S (2010):** Significance of the riboflavin film in corneal collagen cross linking. *J Cataract Refract Surg.*, 36:114-120.

- 22. Schumacher S, Mrochen M, Wernli J, Bueeler M, Seiler T (2012):** Optimization model for UV-riboflavin corneal cross-linking. *Invest Ophthalmol Vis Sci.*, 53:762–769.
- 23. Wollensak G (2006):** Cross linking treatment of progressive keratoconus: new hope. *Curr Opin Ophthalmol.*, 17:356–360.
- 24. Hoyer A, Raiskup-Wolf F, Sporl E, Pillunat LE (2009):** Collagen cross-linking with riboflavin and UVA light in keratoconus: results from Dresden. *Ophthalmologe*, 106:133–140.
- 25. Meiri Z, Keren S, Rosenblatt A *et al.* (2016):** Efficacy of corneal collagen cross-linking for the treatment of keratoconus: a systematic review and meta-analysis. *Cornea*, 35:417–428.
- 26. McAnena L, Doyle F, O’Keefe M (2017):** Cross-linking in children with keratoconus: a systematic review and meta-analysis. *Acta Ophthalmol.*, 95:229–239.
- 27. Schindl A, Rosado-Schlosser B, Trautinger F (2001):** Reciprocity regulation in photobiology: an overview. *Hautarzt.*, 52:779–785.
- 28. Dhawan S, Rao K, Natrajan S (2011):** Complications of corneal collagen cross-linking. *J Ophthalmol.*, 2011:869015.
- 29. Konstantopoulos A, Mehta JS (2017):** Conventional versus accelerated collagen cross-linking for keratoconus. *Eye Contact Lens*, 41(2): 65-71. Available at: <http://dx.doi.org/10.1097/ICL.0000000000000093>
- 30. Mastropasqua L (2015):** Collagen cross-linking: When and how? A review of the state of the art of the technique and new perspectives. *Eye Vis. (Lond)*, 2: 19-23.
- 31. McGhee CN, Kim BZ, Wilson PJ (2015):** Contemporary treatment paradigms in keratoconus. *Cornea*, 34(Suppl 10): S16-23. Available at: <http://dx.doi.org/10.1097/ICO.0000000000000504>
- 32. Sherif AM (2014):** Accelerated versus conventional corneal collagen cross-linking in the treatment of mild keratoconus: a comparative study. *Clin Ophthalmol.*, 8:1435–1440.
- 33. Toker E, Cerman E, Ozcan DO, Seferoglu OB (2017):** Efficacy of different accelerated corneal cross linking protocols for progressive keratoconus. *J Cataract Refract Surg.*, 43: 1089–1099.
- 34. Brittingham S, Tappeiner C, Frueh BE (2014):** Corneal cross-linking in keratoconus using the standard and rapid treatment protocol: differences in demarcation line and 12-month outcomes. *Invest Ophthalmol Vis Sci.*, 55(12): 8371-6.
- 35. Shetty R, Pahuja NK, Nuijts RM *et al.* (2015):** Current protocols of corneal collagen cross-linking: Visual, refractive, and tomographic outcomes. *Am J Ophthalmol.*, 160(2): 243-9.